

# First practical session

2020

## BONES OF THE GLUTEAL REGION

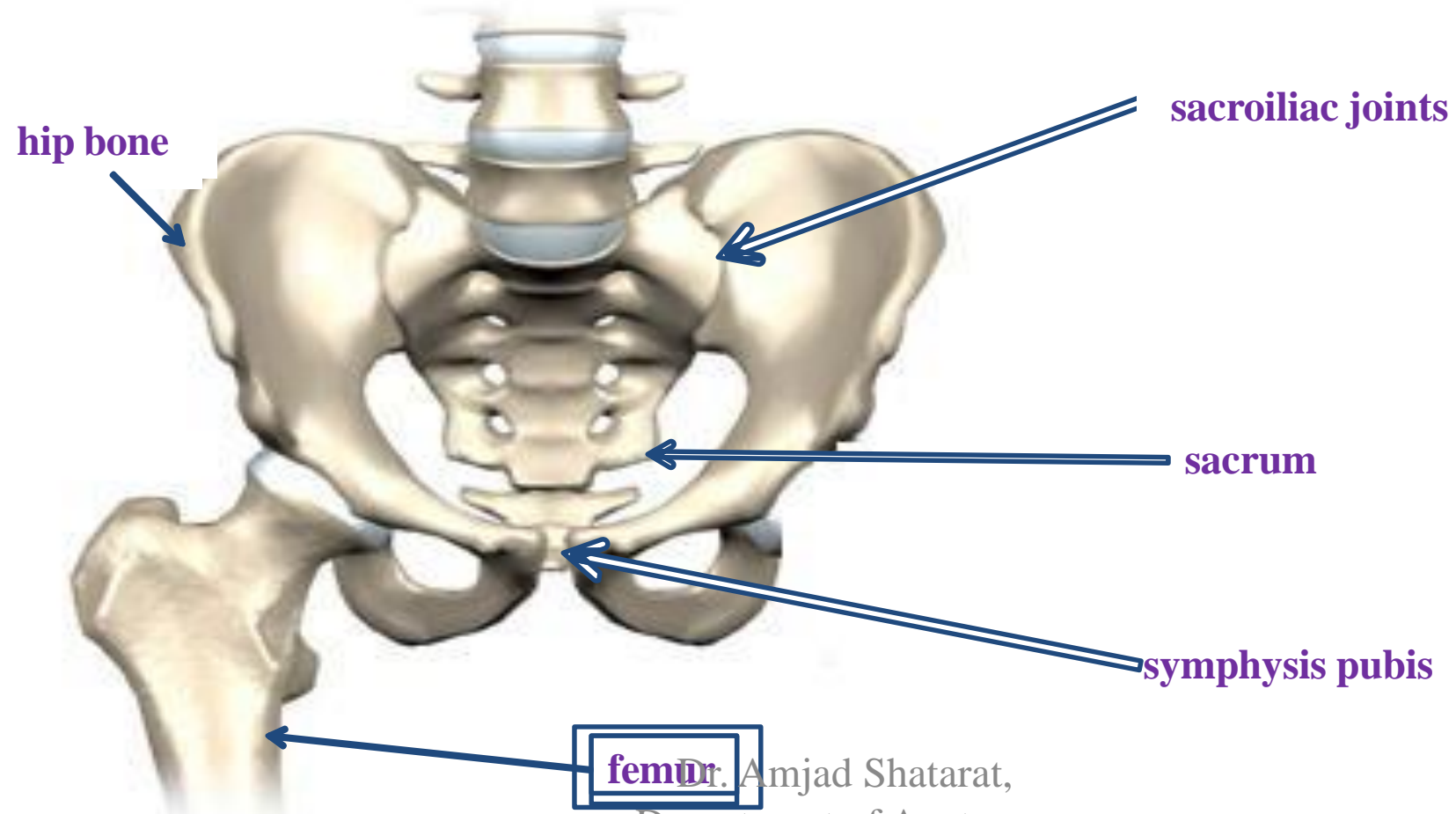
Dr. Amjad Shatarat, Department of Anatomy, School of Medicine, The Uni. of Jordan

## The pelvic girdle

The hip bones articulate with the **sacrum**

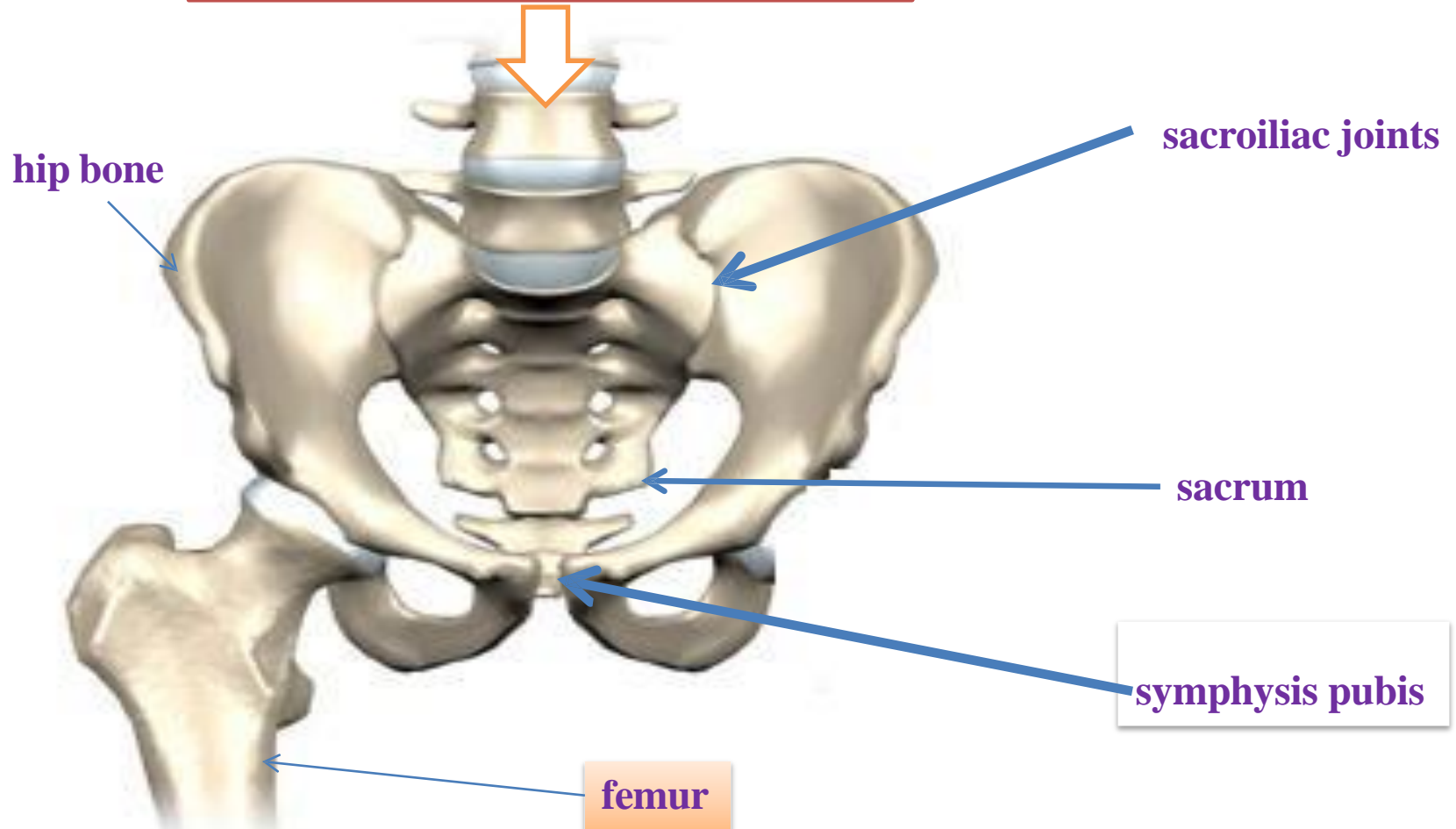
at the **sacroiliac joints posteriorly**

while **anteriorly** they articulate with one another at the **symphysis pubis**



The 2 hip bones with the sacrum form the pelvis

Now look! where does the pelvis look?  
It is looking right at you! Never upwards



During your first practical session, make sure to have a look at the anatomical position of the pelvis

Dr. Amjad Shatarat,  
Department of Anatomy

# THE HIP BONE

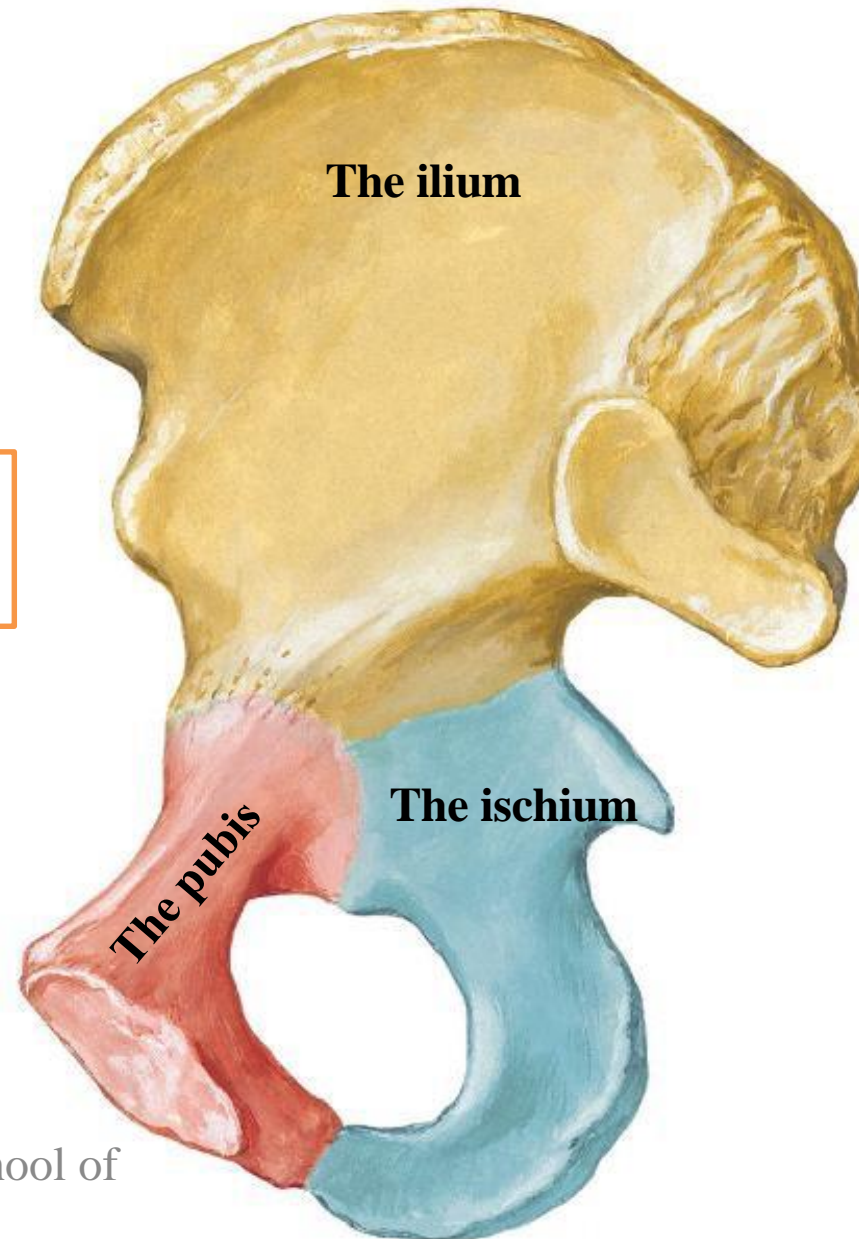
Hip (Coxal) Bone  
Medial View



The hip bone is made of:

- 1 The ilium: superior in position
- 2 The ischium: postero-inferior in position
- 3 The pubis: antero-inferior in position

However!!!!!!!



## The ilium , ischium and pubis

meet one another by means of

**triradiate (Y-shaped)**

**cartilage** at the **Acetabulum**.

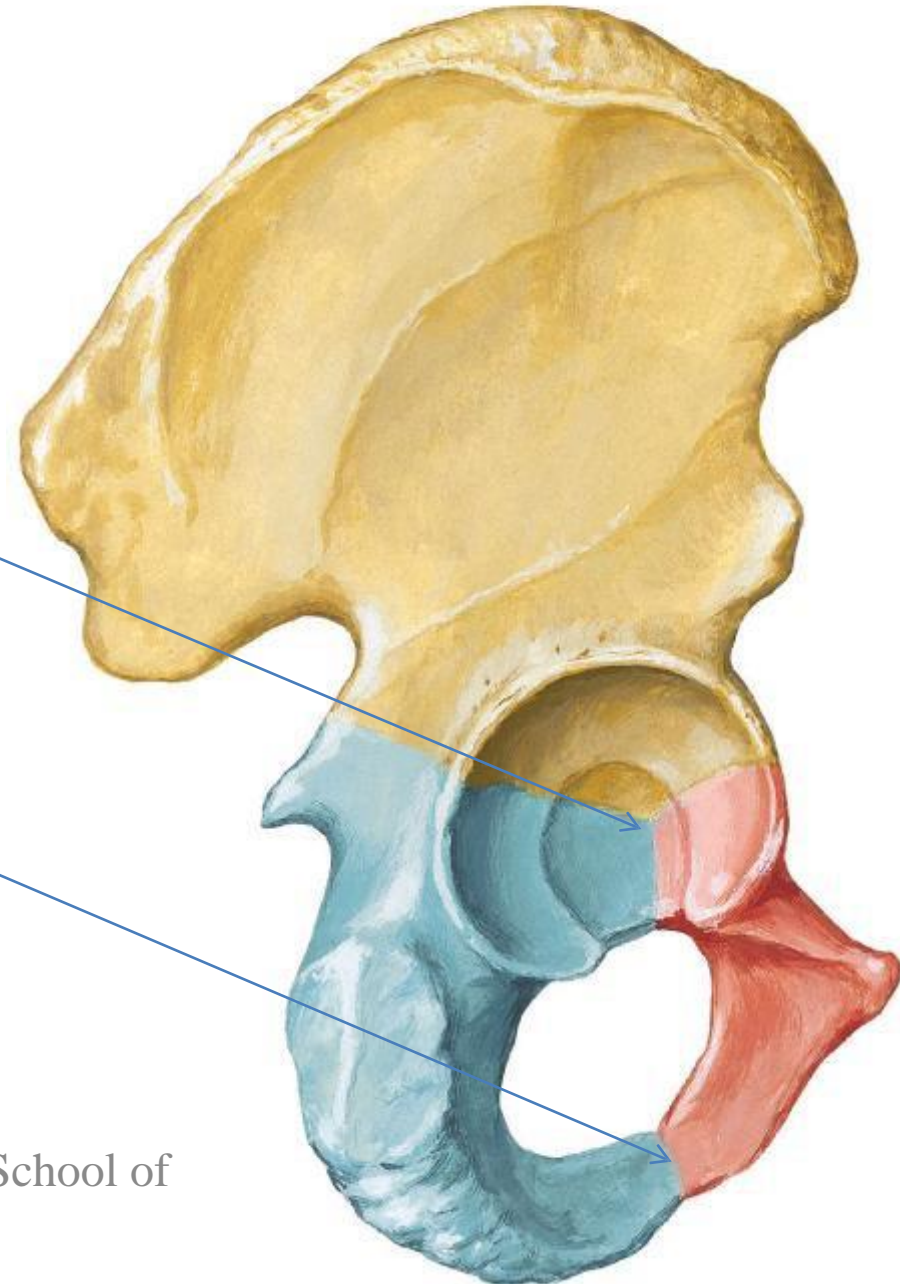
While *the inferior ramus of the pubis meets with the ramus*

*of the ischium by*

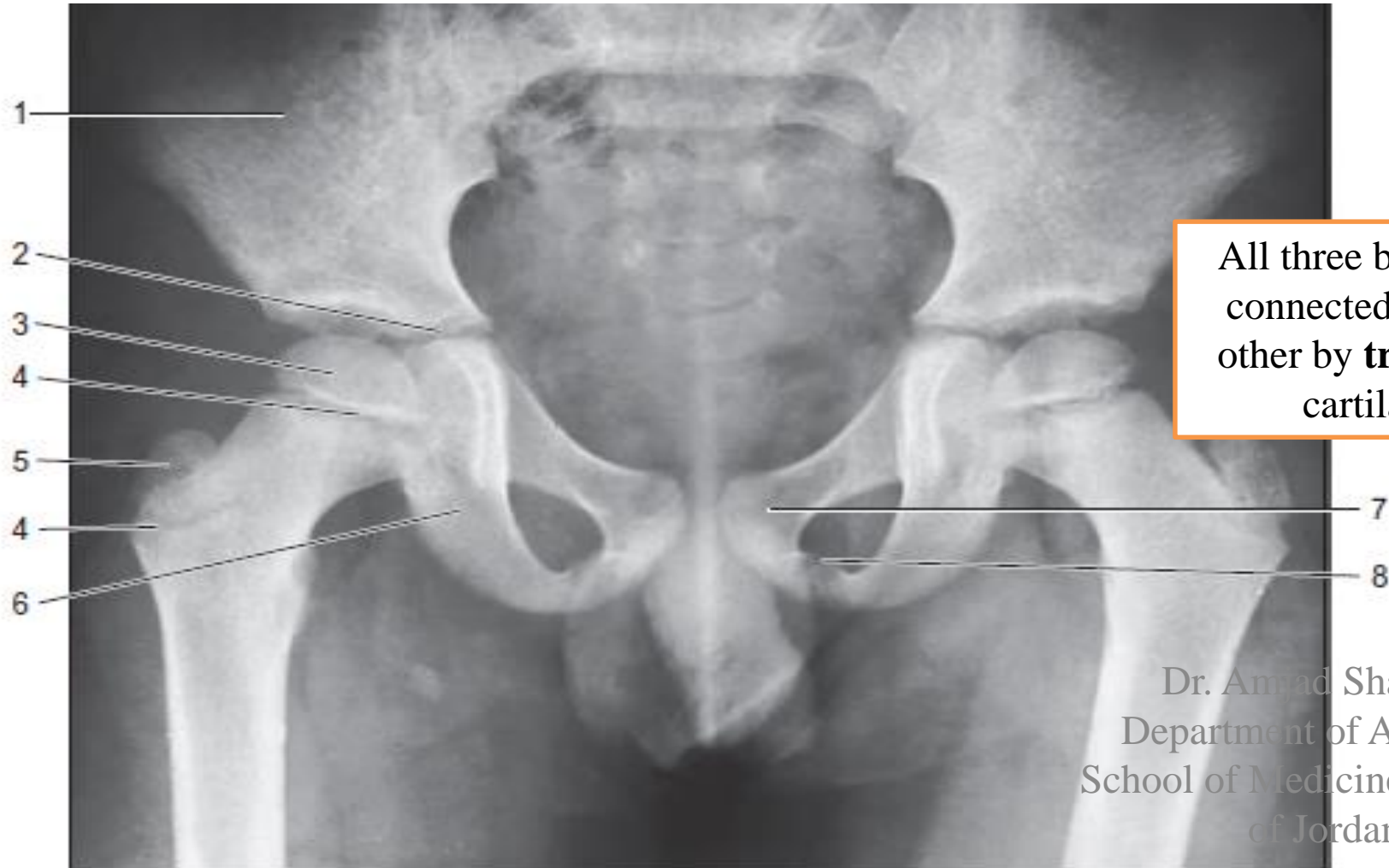**cartilaginous union**

**Ossifies near the age of 7 years**

What is the idea here?



at puberty the triradiate cartilage starts to ossify and near the age of 17 the triradiate cartilage will be replaced by bony union



All three bones are connected to each other by **triradiate** cartilage

Dr. Amad Shatarat,  
Department of Anatomy,  
School of Medicine, The Uni.  
of Jordan

Anteroposterior radiograph of the pelvis of a boy aged 7.

Read only

**1. Ilium. 2. Part of triradiate growth cartilage. 3. Superior femoral epiphysis. 4. Cartilaginous growth plates. 5. Ossifying greater trochanter. 6. Ischium. 7. Pubis. 8. Cartilage between pubic and ischial rami.**

# 1-The Ilium

Hip (Coxal) Bone  
Lateral View

Two parts:

- 1- Ala
- 2- Body

Right hip bone

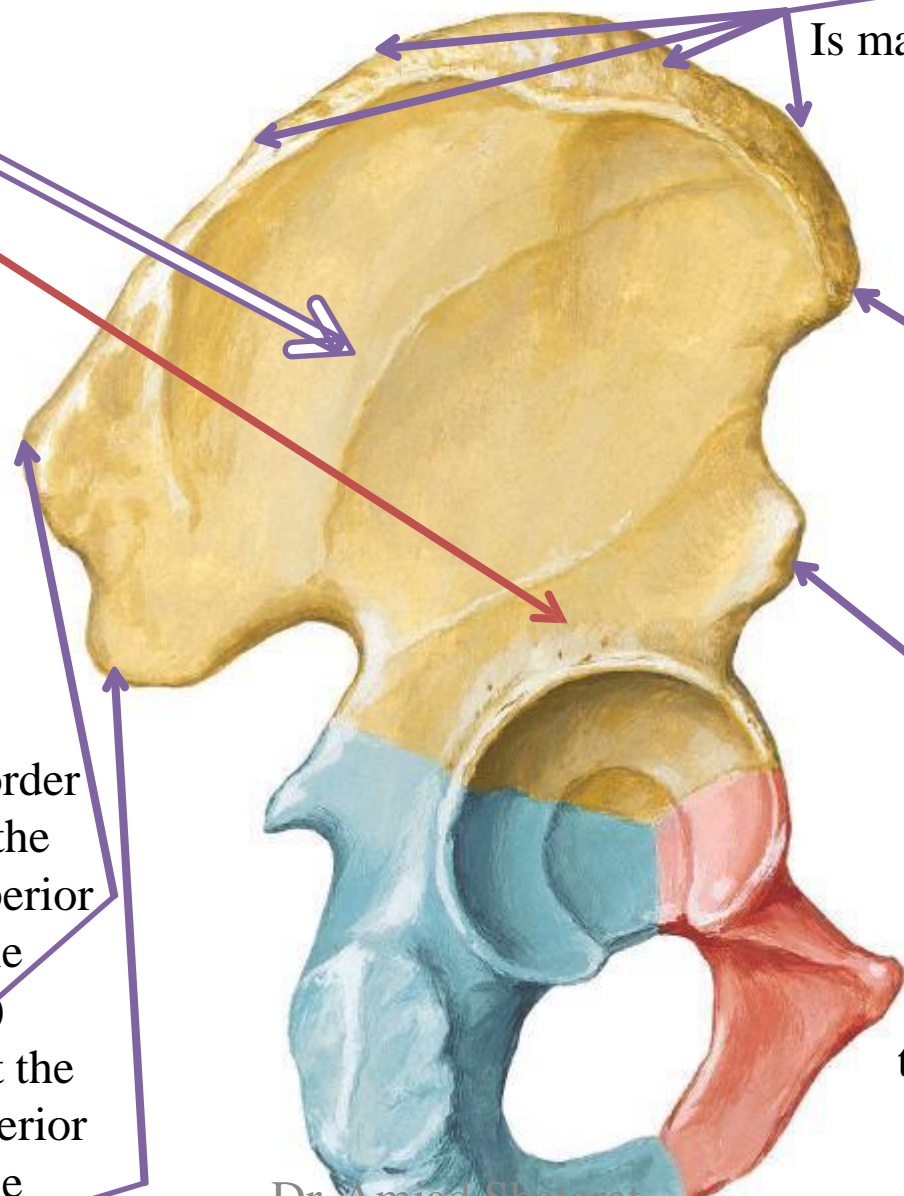
Superior border  
Is made by the iliac crest

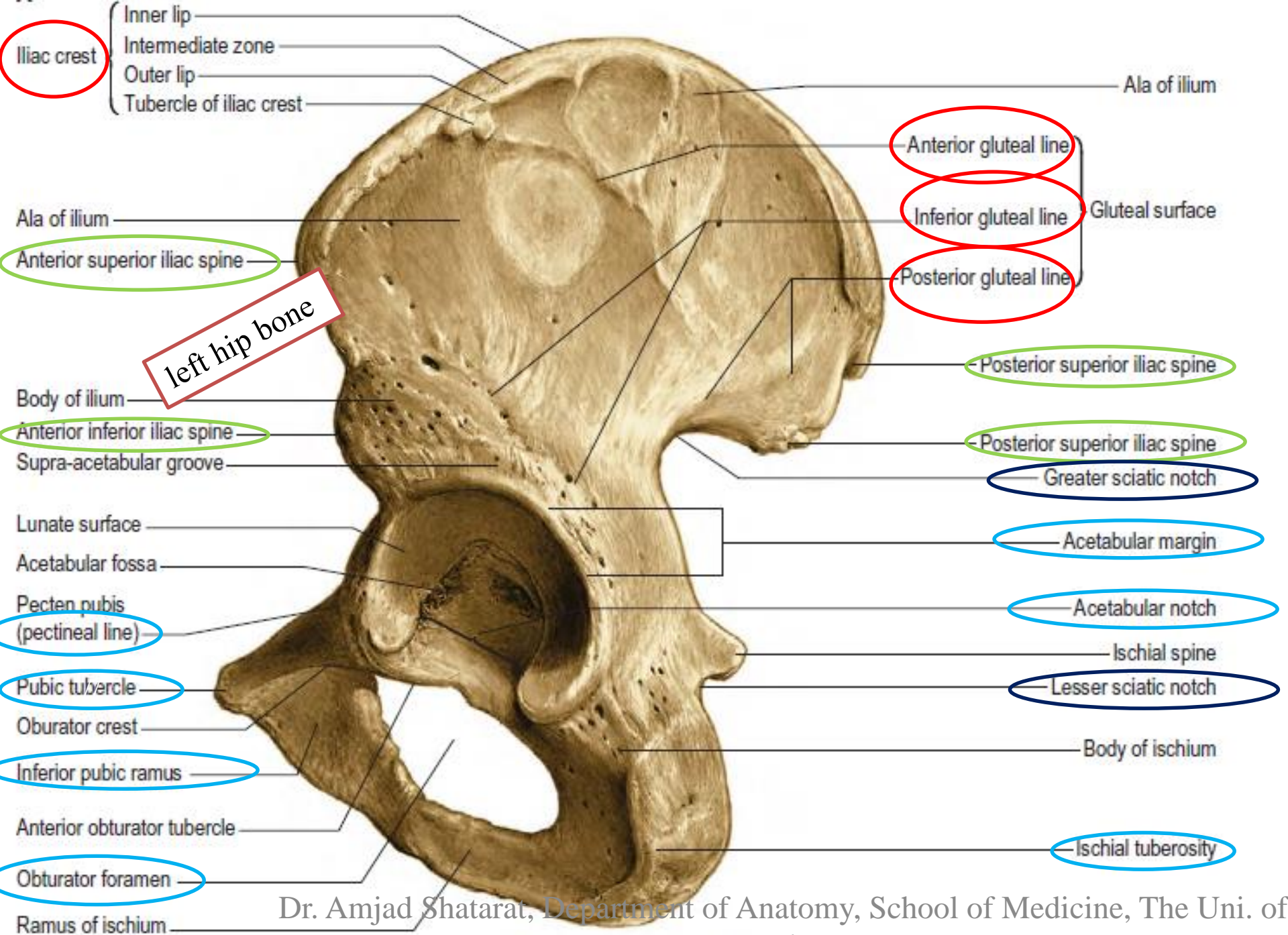
Anterior border  
Begins at the anterior superior iliac spine (A.S.I.S) and ends at the anterior inferior iliac spine (A.I.I.S)

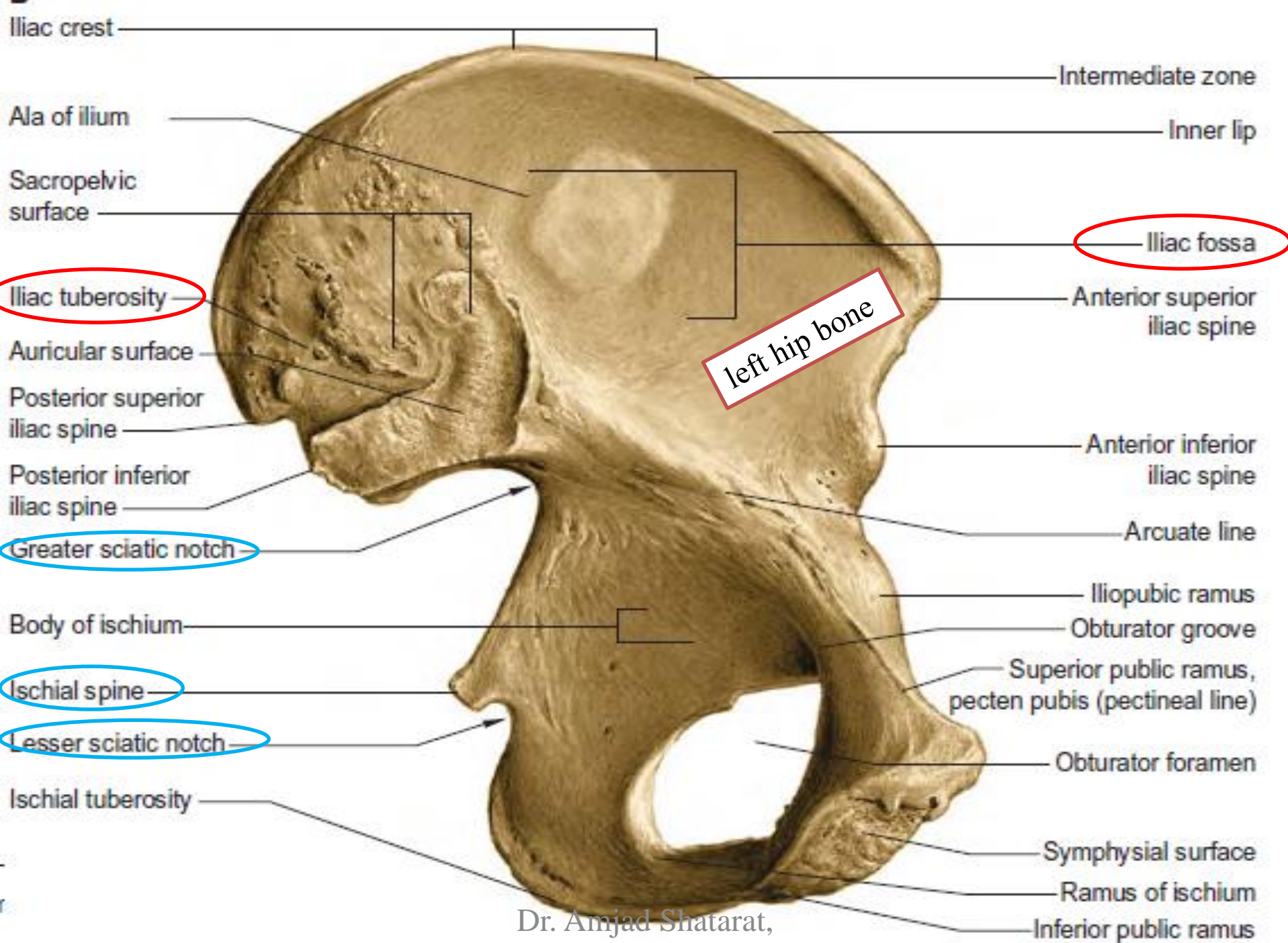
Three surfaces  
1-gluteal surface  
2-iliac fossa  
3-sacropelvic surface

Posterior border  
Begins at the posterior superior iliac spine (P.S.I.S) and ends at the posterior inferior iliac spine (P.I.I.S)

*the anterior superior spine of the ilium is easily felt and may be visible in the thin subject*







Dr. Amjad Shatarat,  
 Department of Anatomy

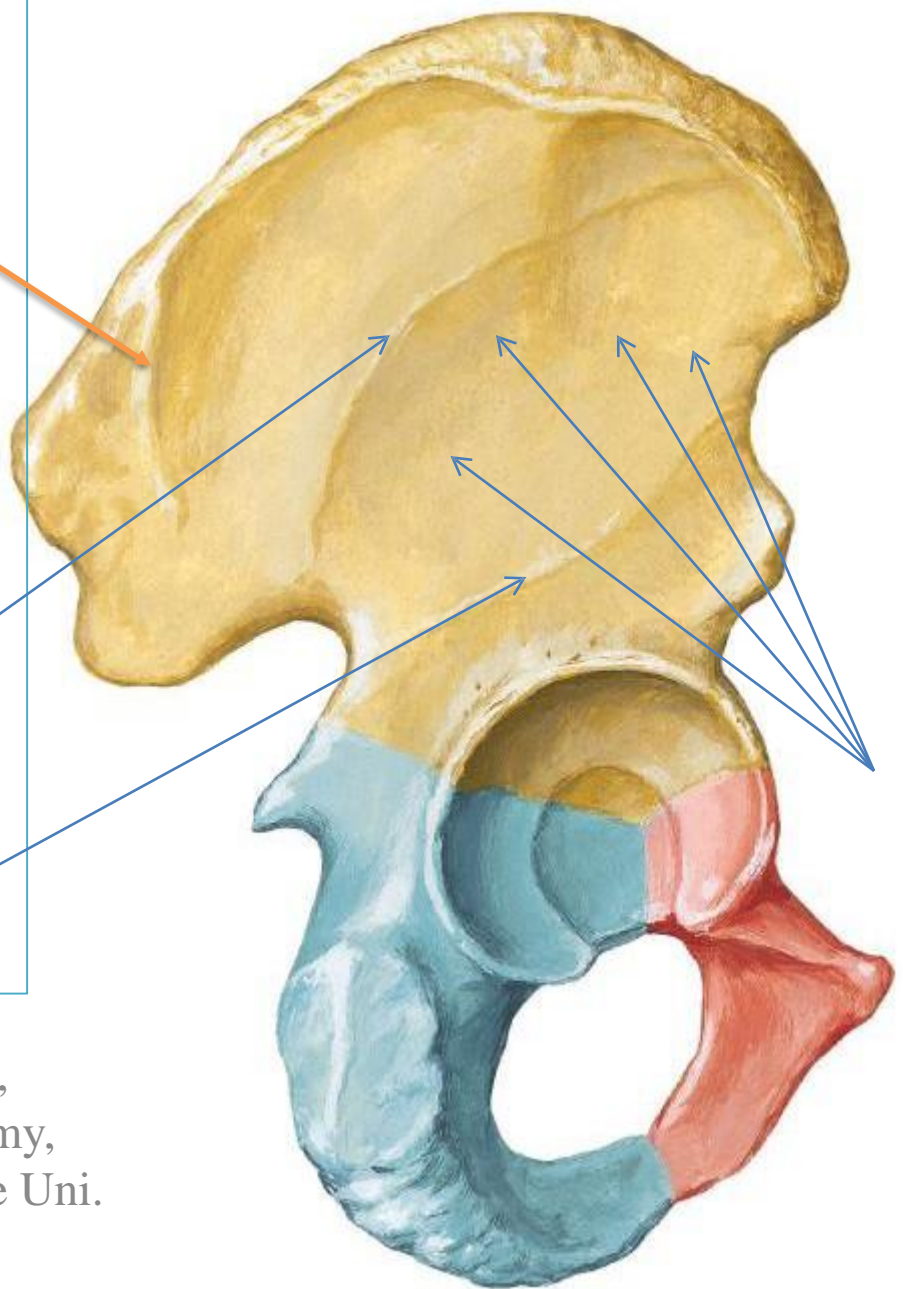
# Hip (Coxal) Bone Lateral View

The gluteal surface is divided into 4 parts by three lines:

1- Posterior gluteal line

2- Middle gluteal line  
Or anterior

3- Inferior gluteal line

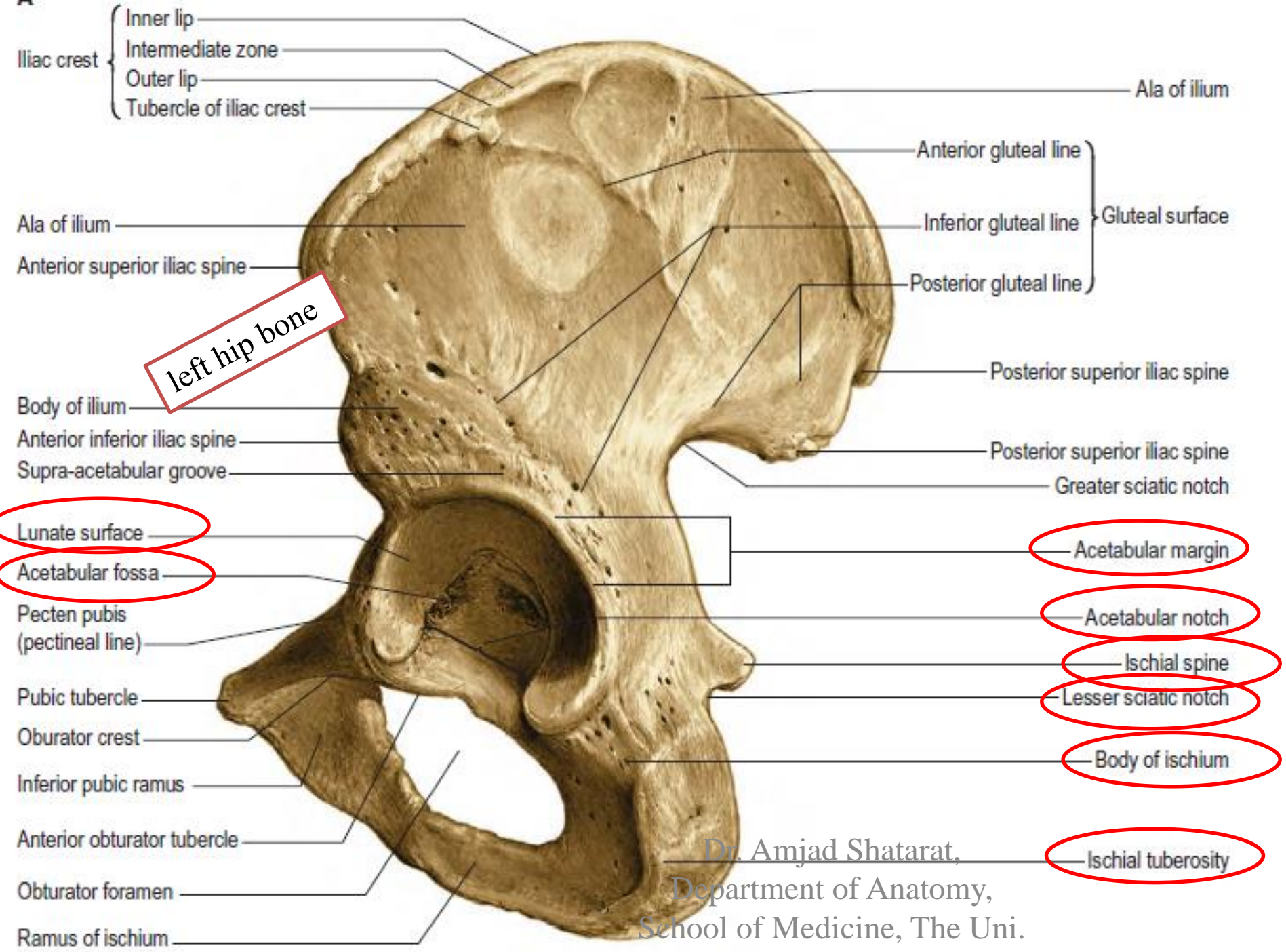


**MAKE SURE**  
you know the names of the muscles that are attached to the areas between these lines



Which muscle is attached to the area between the inferior and middle gluteal lines?

Dr. Amjad Shatarat,  
Department of Anatomy,  
School of Medicine, The Uni.  
of Jordan



Dr. Amjad Shatarat,  
 Department of Anatomy,  
 School of Medicine, The Uni.  
 of Jordan

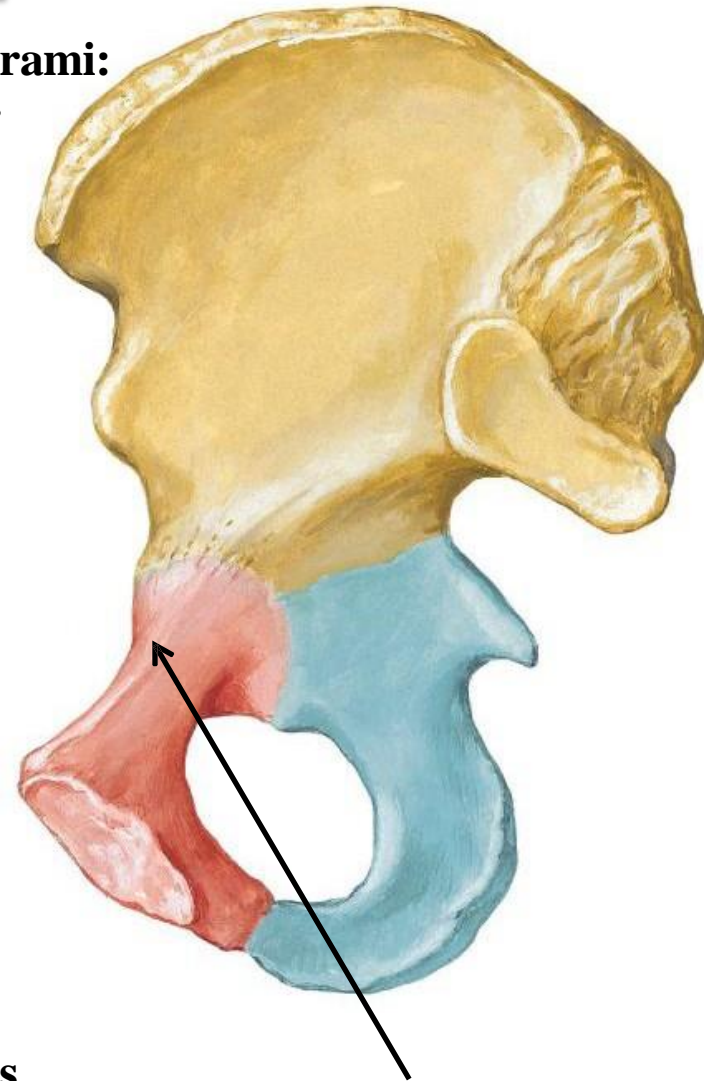
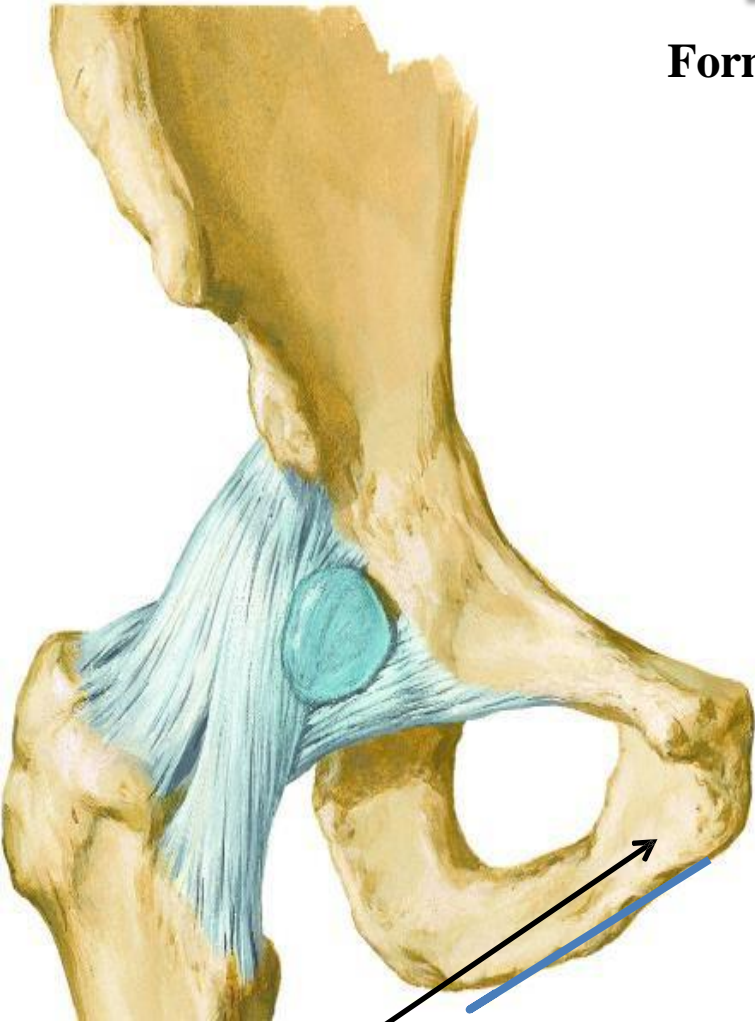
Hip Joint  
Anterior View

# Pubic bone

Hip (Coxal) Bone  
Medial View

Formed of a body and two rami:  
superior and inferior

The body is flattened and has:  
1- an upper border called pubic crest that ends laterally by the pubic tubercle  
2- symphyseal surface which articulates with the opposite pubis to form the pubic symphysis

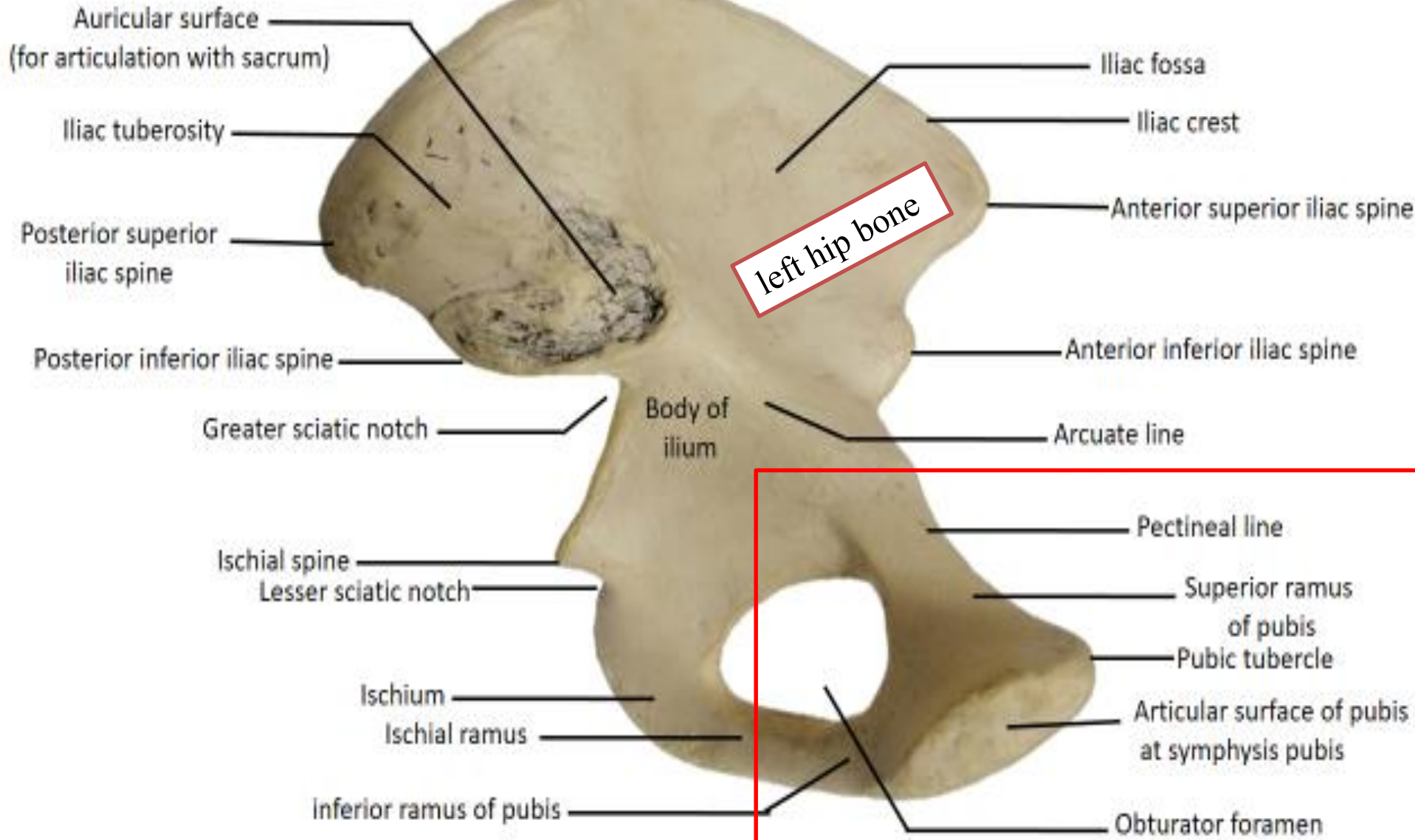


## Pectineal line

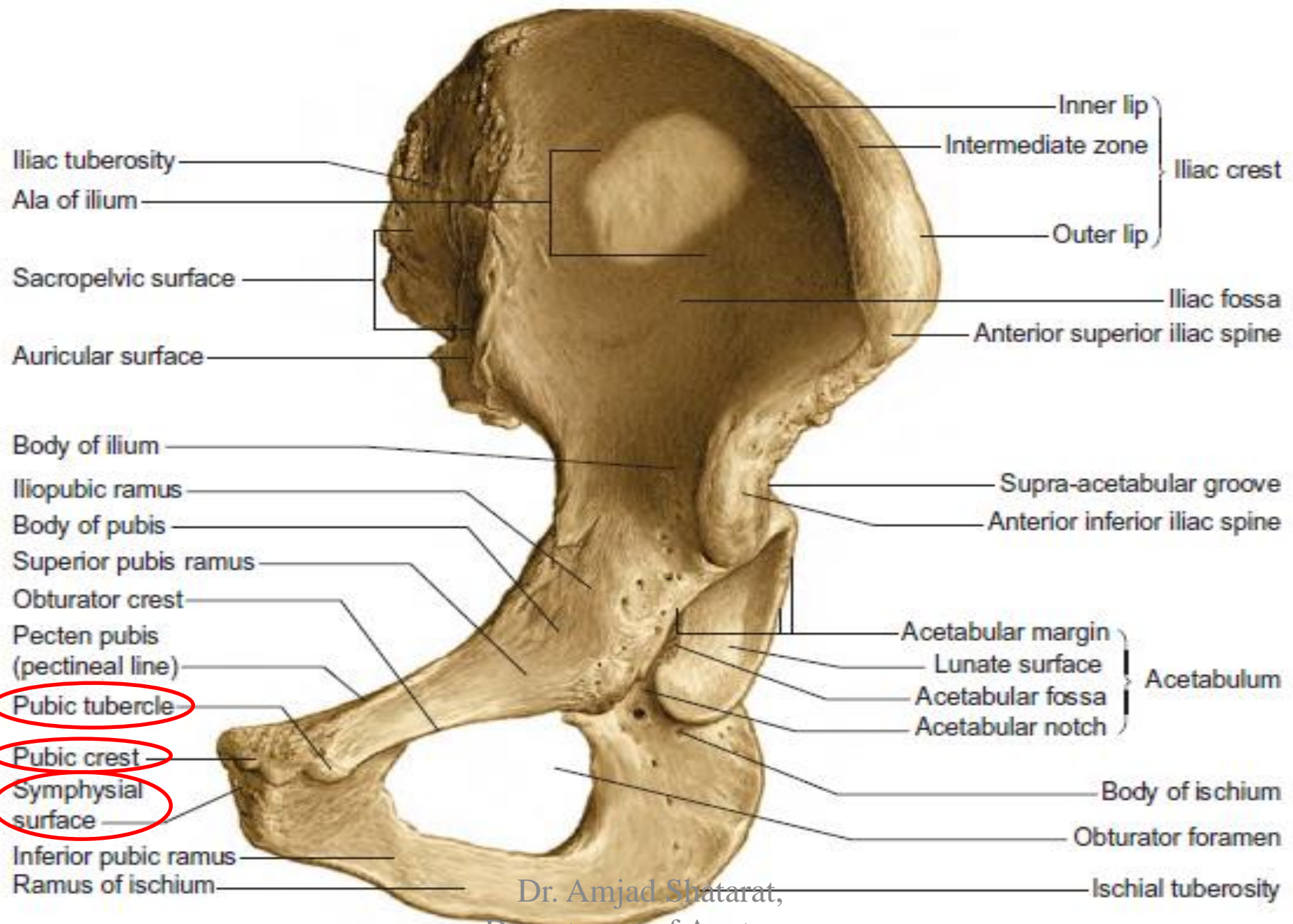
The inferior ramus of the pubic bone joins the ischial ramus to form the conjoint tendon.

The superior pubic ramus has a pectineal line on its medial surface

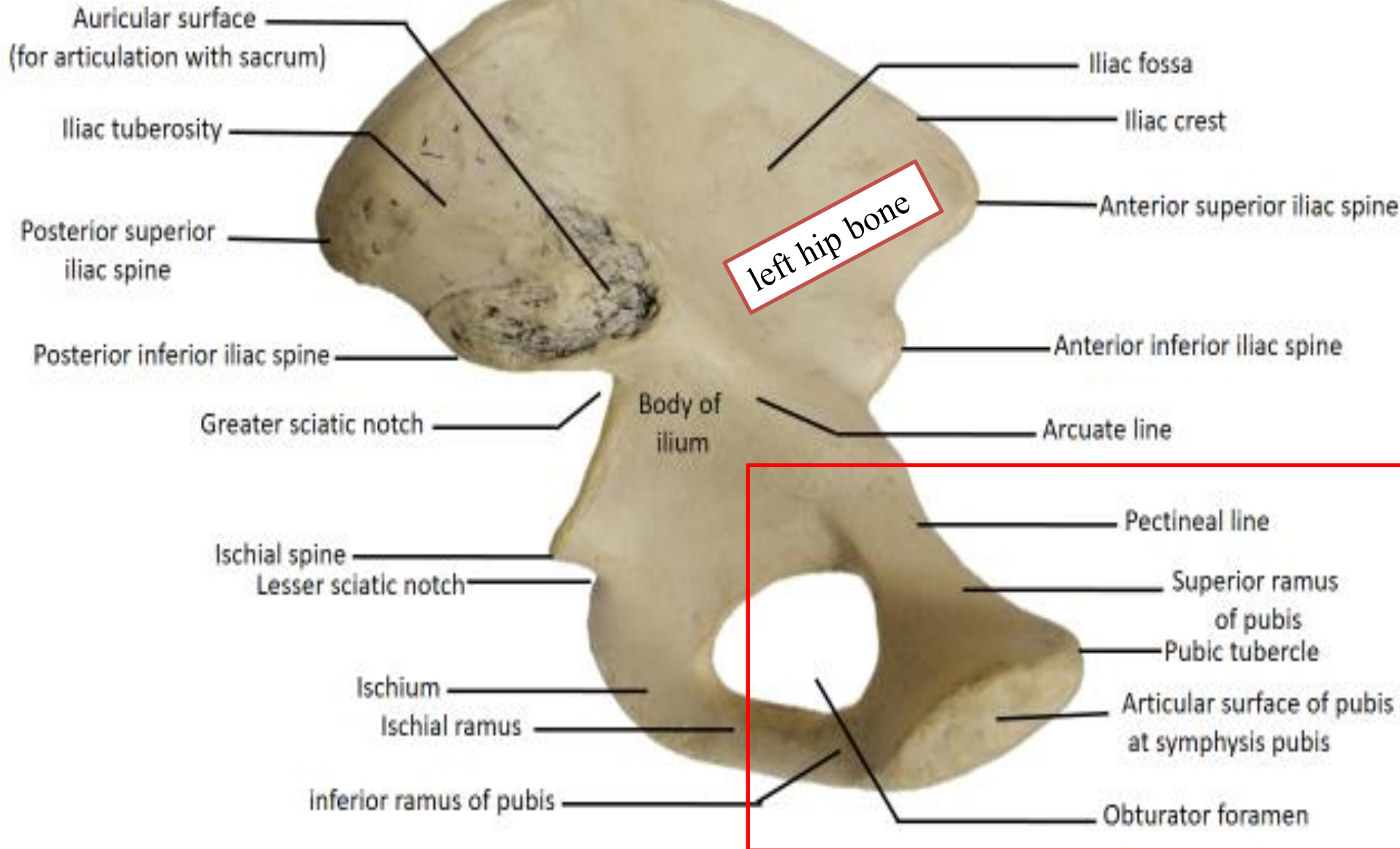
# Hip bone



Dr. Amjad Shatarat,  
Department of Anatomy



# Hip bone



Dr. Amjad Shatarat,  
Department of Anatomy

Hip (Coxal) Bone  
Lateral View

The ischium

Body

Ischial ramus

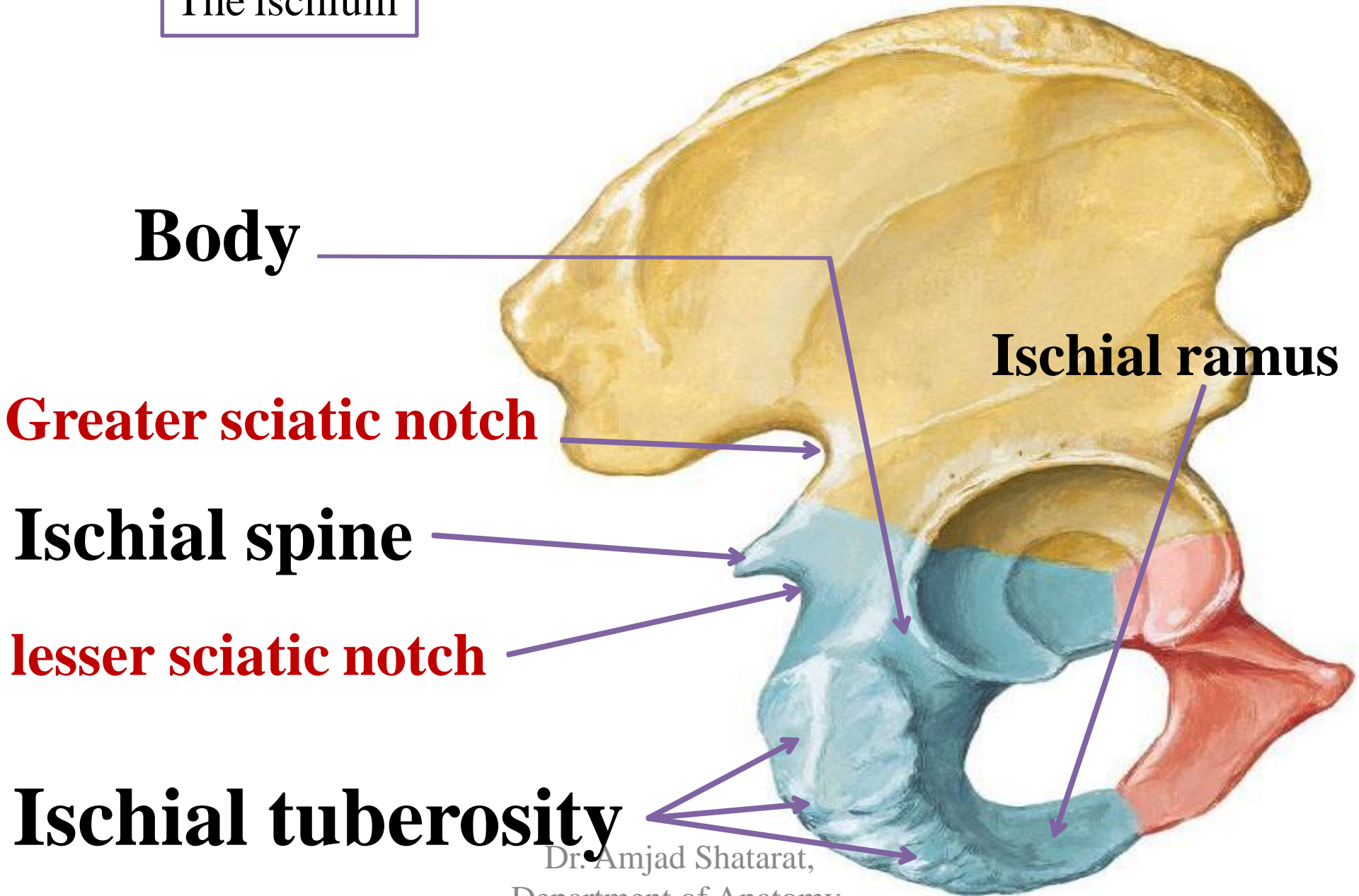
Greater sciatic notch

Ischial spine

lesser sciatic notch

Ischial tuberosity

Dr. Amjad Shatarat,  
Department of Anatomy.



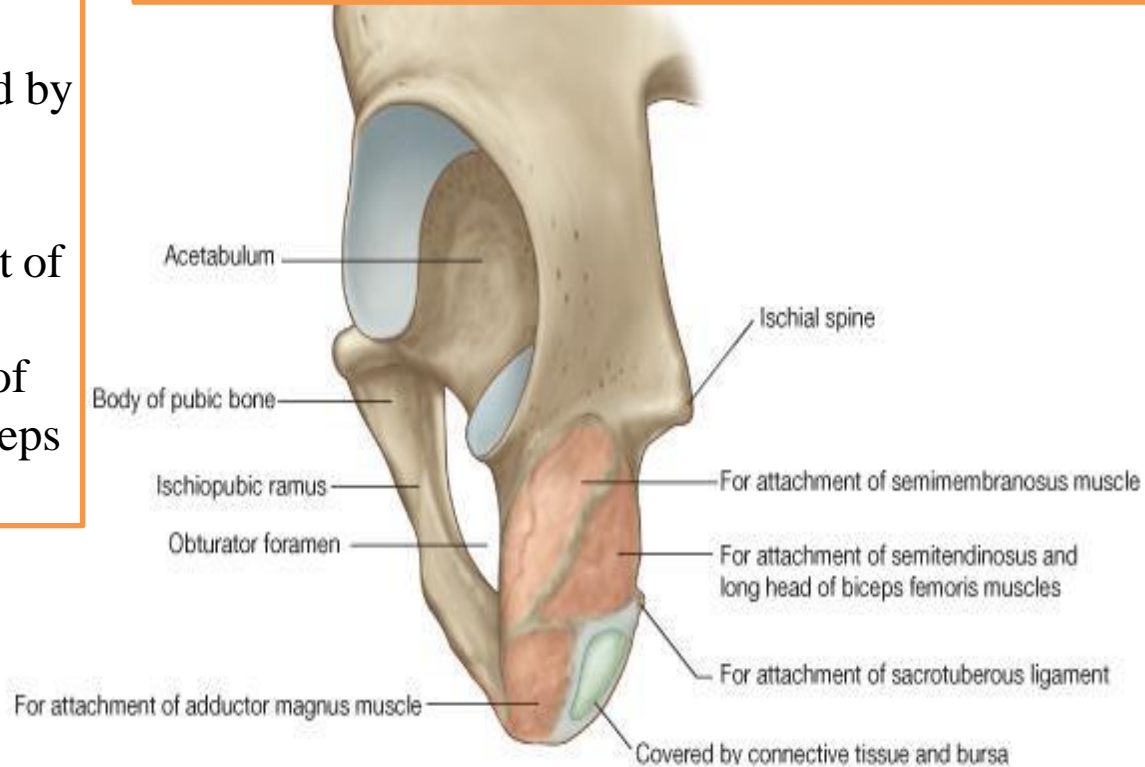
# Ischial tuberosity

Divided by a transverse ridge into:  
An upper quadrangular and a lower  
triangular parts

**The upper** quadrangular part is divided by  
an oblique ridge  
into:

- 1 :Upper lateral part for the attachment of semimembranosus
- 2 :lower Medial for the attachment of semitendinosus and long head of biceps

These divisions are of no clinical value,  
Therefore, they are not exam material.  
You can read them as general information



The lower triangular part is divided by a longitudinal ridge into:

1-lateral part that gives attachment  
to the adductor part of the adductor

magnus muscle 2-medial part ( subcutaneous part)

# The Acetabulum

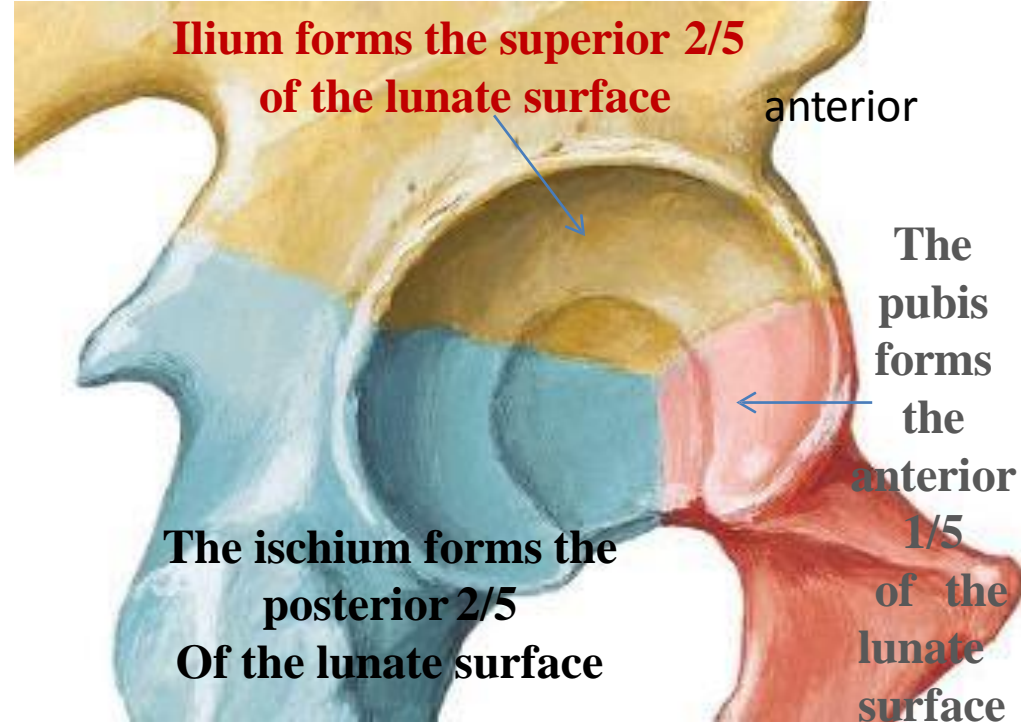
➤ It is a C-shaped cavity located on the lateral aspect of the hip bone

➤ It is notched inferiorly by the acetabular notch which is bridged by the **transverse acetabular ligament** ( part of the acetabular labrum)

➤ The ***acetabular ligament converts the acetabular notch into foramen***

➤ Its cavity presents a **horse-shoe shaped articular surface called Lunate surface**

➤ The Lunate surface surrounds a non articular depression called **acetabular fossa** which is occupied by fat tissue in living



# THE HIP BONE

Hip (Coxal) Bone  
Medial View



## Anatomical position of the hip bone

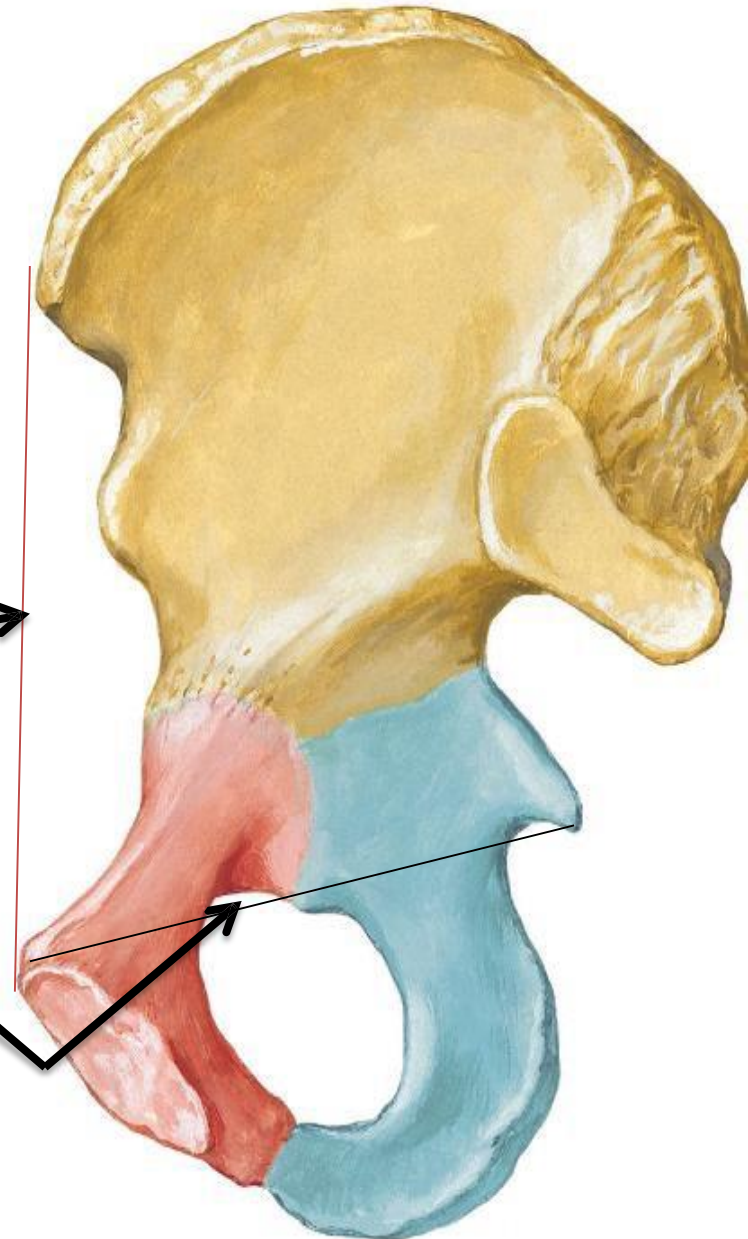
It is very important to understand the anatomical position of the hip bone,  
in anatomical position:

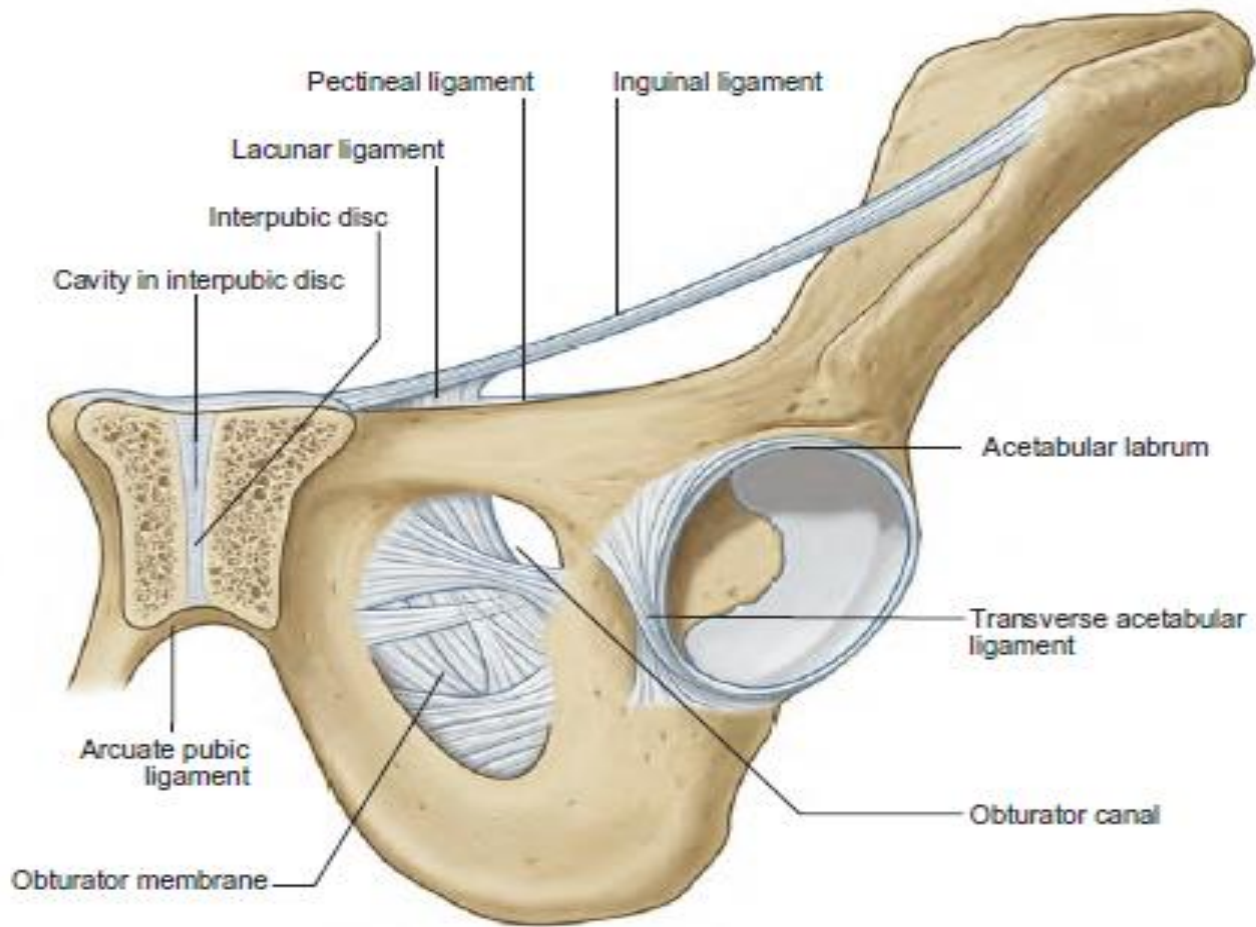
- 1-The **Anterior superior iliac spine** and the **pubic tubercle** **lie in the same vertical plane**.
- 2-The **ischial spine** and the **upper border of the symphysis pubis** **lie in the same horizontal plane**.

What does this mean?

It means that the pelvis is looking forward in the anatomical position

Dr. Amjad Shatarat,  
Department of Anatomy



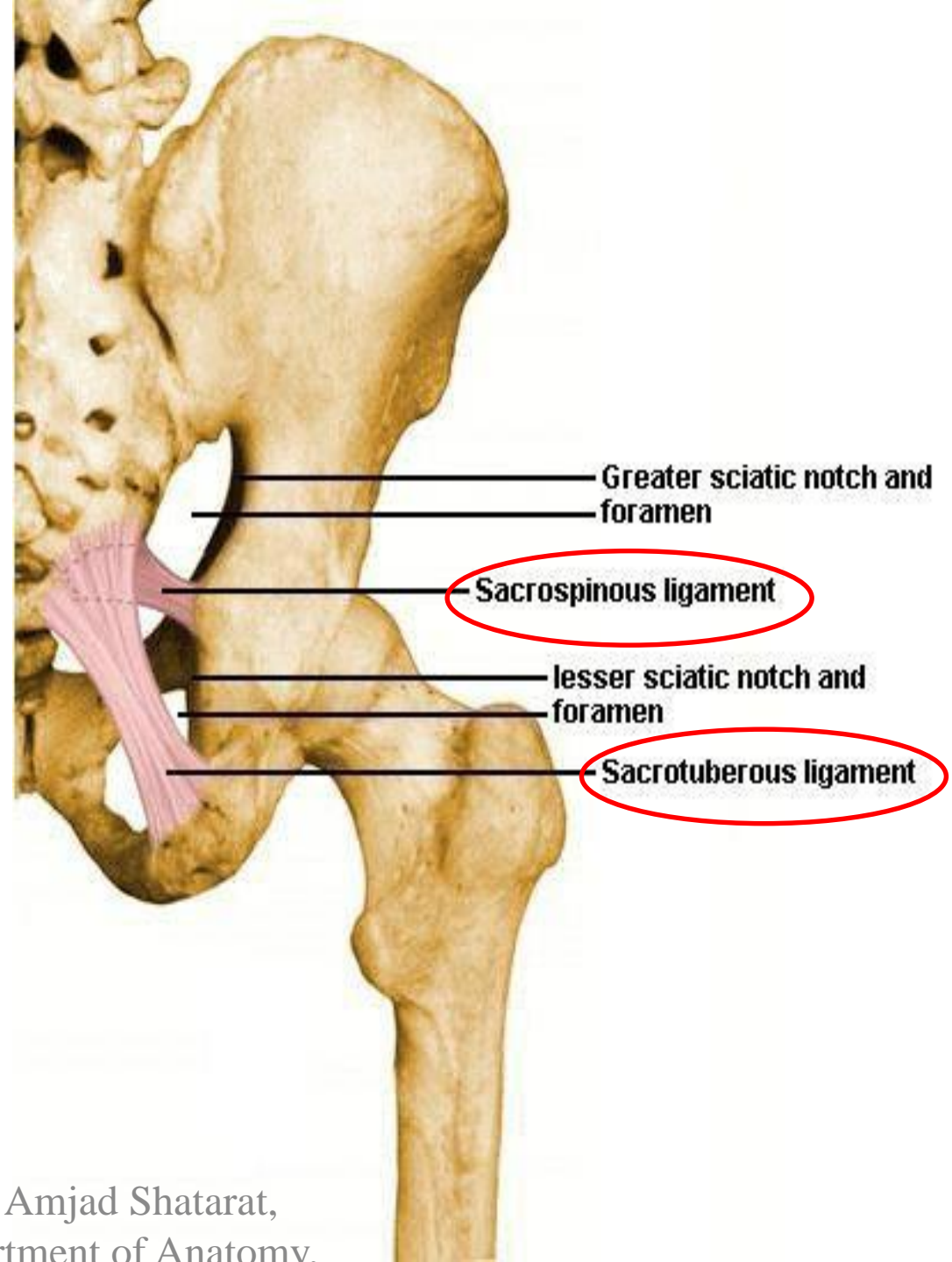


**OBTURATOR**  
foramen Covered by a  
membrane in living subjects

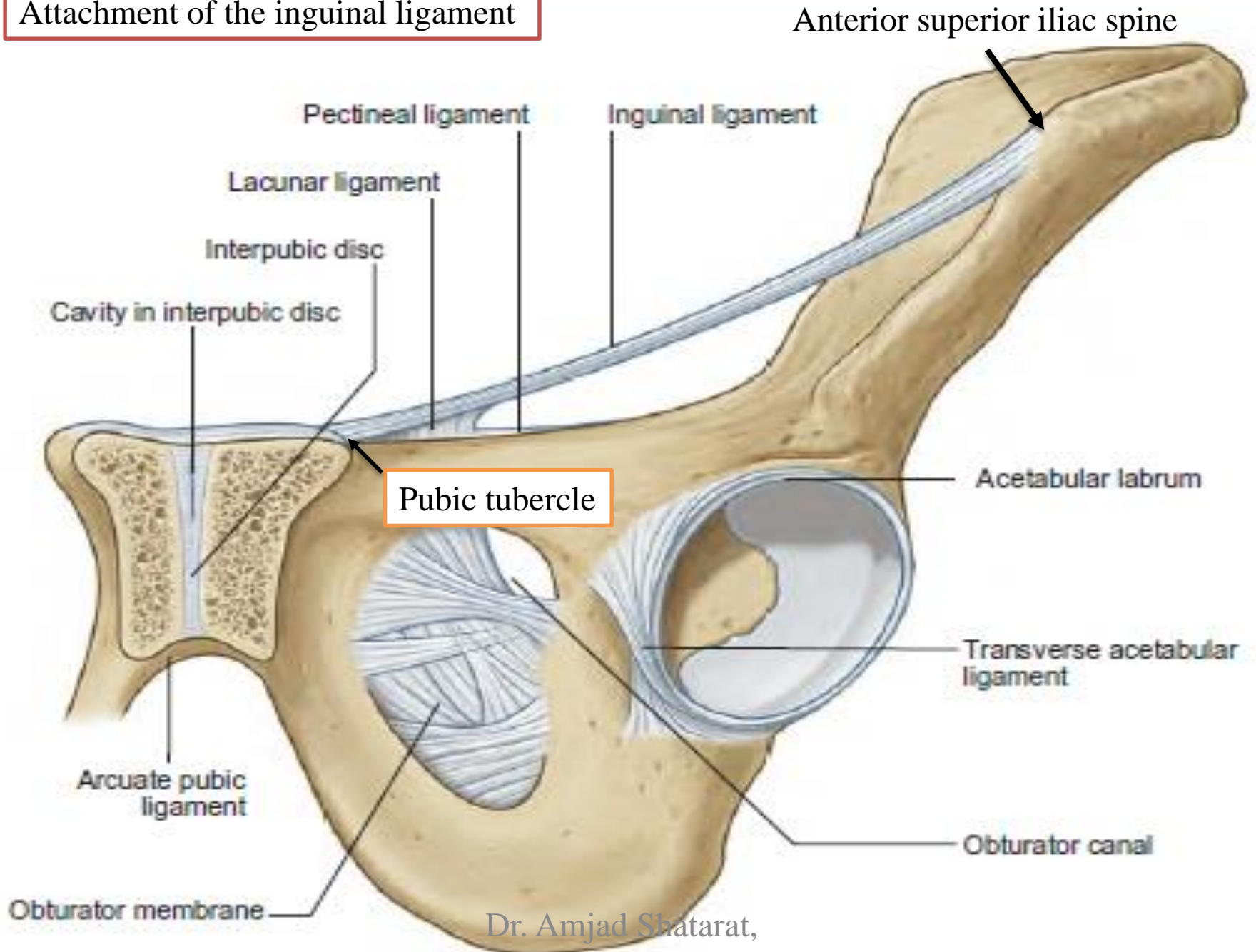
ligaments in the gluteal region

**1- SACROTUBEROUS  
LIGAMENT**

**2- SACROSPINOUS LIGAMENT**

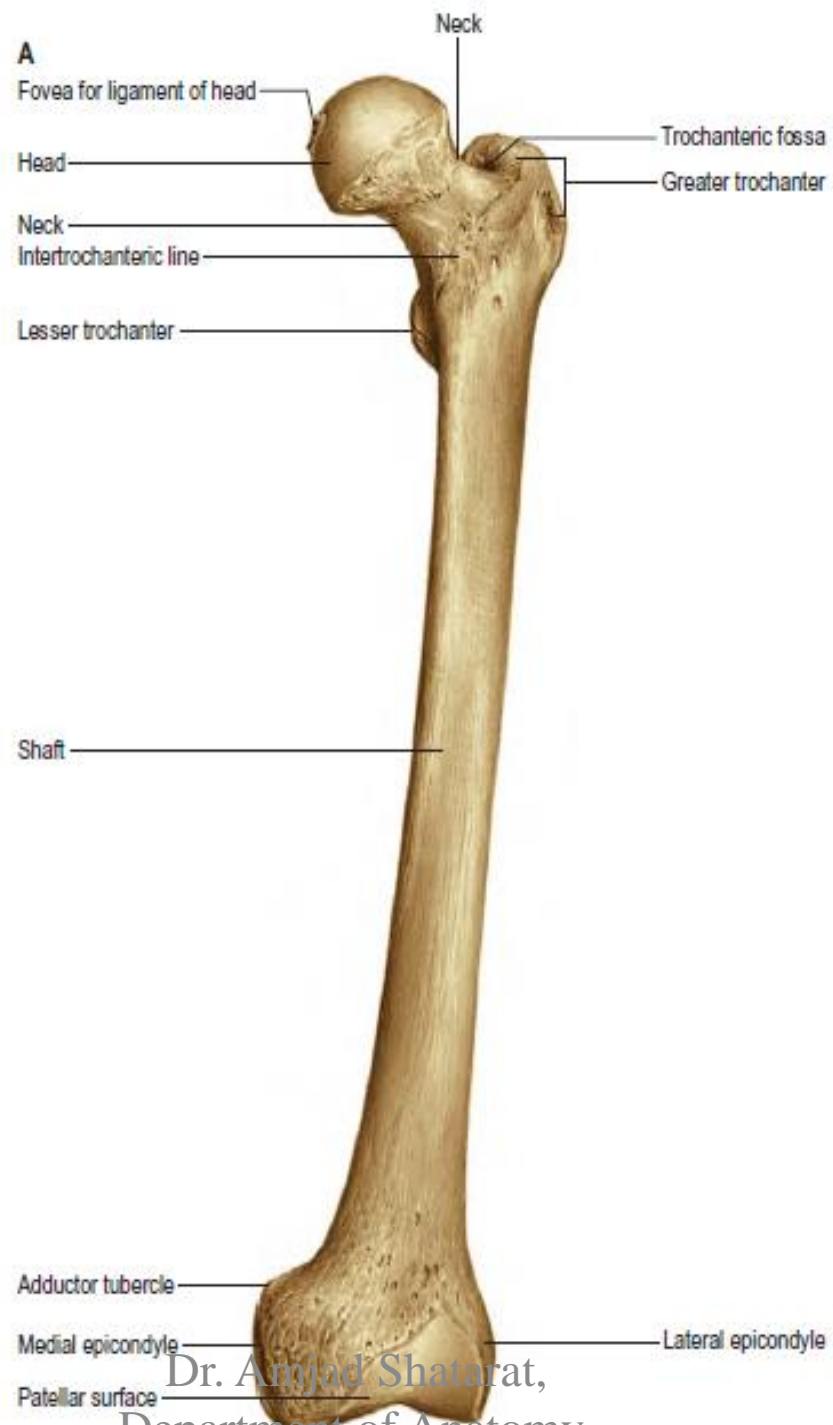


# Attachment of the inguinal ligament



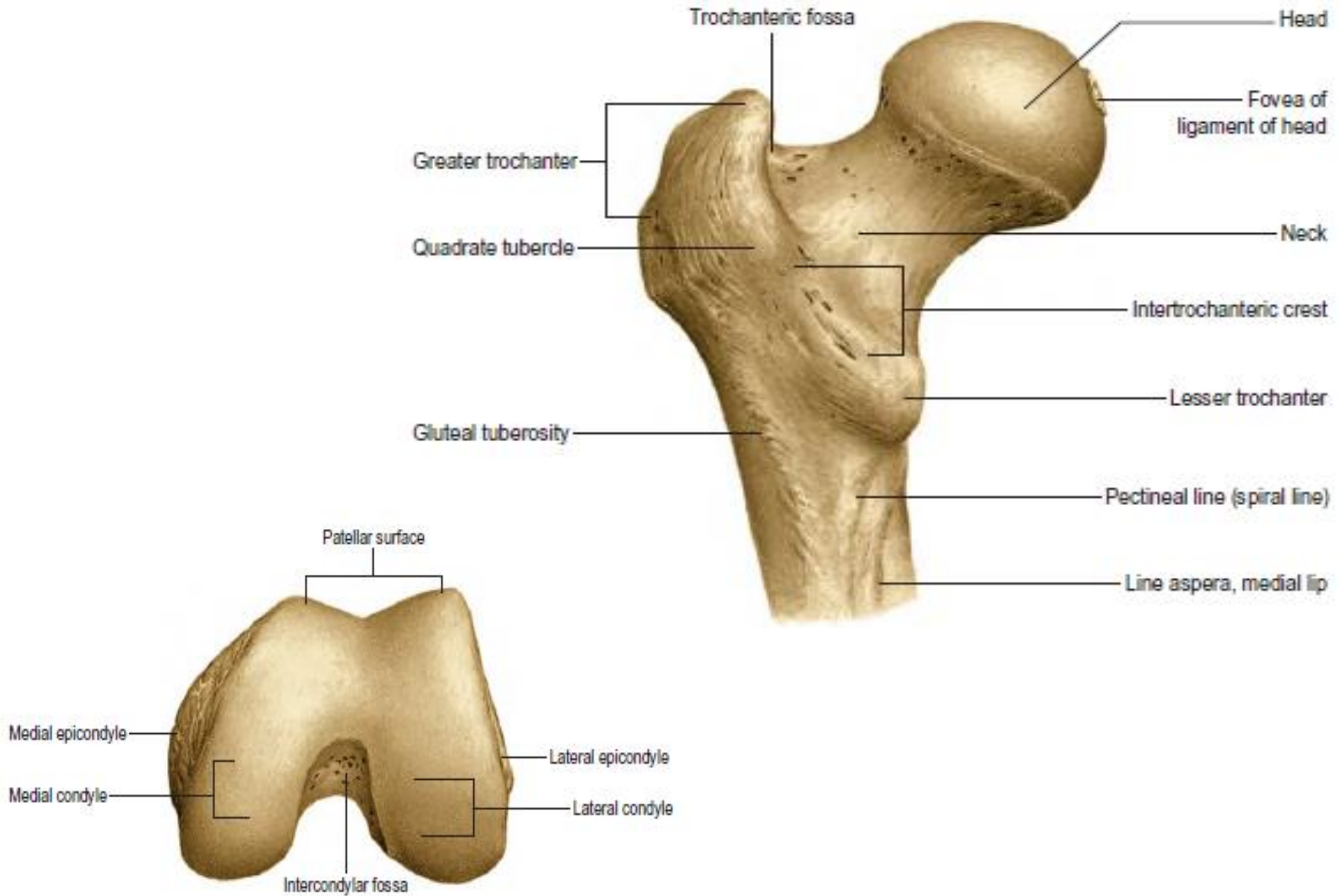
# BONES OF THE THIGH

Dr. Amjad Shatarat,  
Department of Anatomy



Dr. Amjad Shatarat,  
Department of Anatomy.

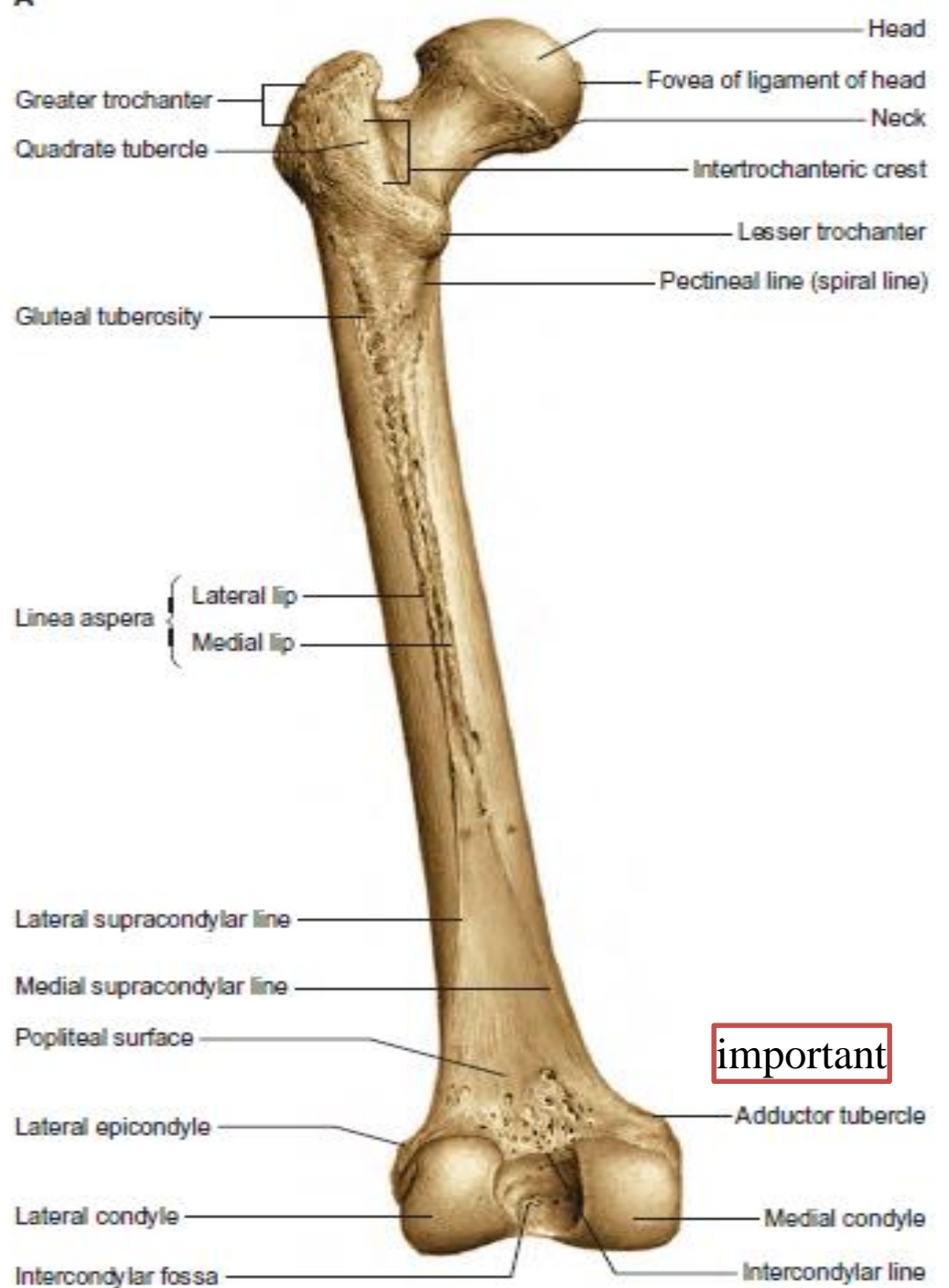




Distal end of femur: articular surface

Dr. Amjad Shatarat,

Department of Anatomy



**important**

Dr. Amjad Shatarat,  
 Department of Anatomy,  
 School of Medicine, The Uni.  
 of Jordan

# Left femur (posterior view)

greater trochanter

intertrochanteric crest

Lesser trochanter

Spiral line

Gluteal tuberosity

Medial lip of linea aspera

lateral lip of linea aspera

linea aspera

lateral surface

medial surface

medial supracondylar line

Adductor tubercle

lateral supracondylar line

lateral condyle

medial condyle

Intercondylar notch

