SHEET NO.

2

PATHOLOGY

DOCTOR 2019 | MEDICINE | JU

DONE BY : Rawan Fratekh

SCIENTIFIC CORRECTION :

GRAMMATICAL CORRECTION :

DOCTOR : Manar Hajeer

الازرق مهم ،الاحمر اضافة او تاكيد ،الاسود كلام الدكتورة+السلايدات

Quick revision

Last lecture was about cell and how the cell deal with stress and physiologic/pathologic changes. Adaptation : when the stress is mild or not enough to cause cell injury and it can happen in many forms .. hypertrophy, hyperplasia, atrophy and metaplasia. If the stress increased the adaptation can progress to cell injury.

In this lecture we will discuss the different patterns of cell injury, reversible and irreversible , their morphologic and ultra structural alterations, the affected cells and the different patterns of necrosis(a type of cell death)

Explanation of the figure

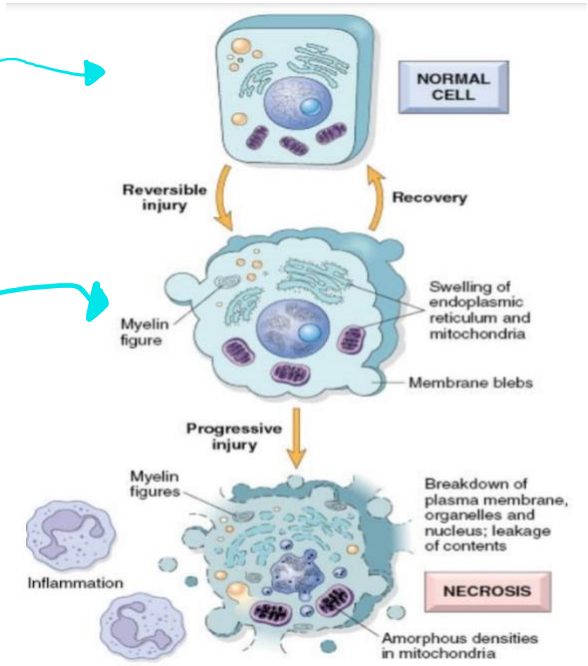

Here you can see the normal cell with its normal organelles .When the cell is exposed to stressful events or any injurious stimulus (more than what the cell can adapt to) it will first go in the "Reversible cell injury"

NOTICE the morphologic changes: The cell is larger in size ,it's swollen like a balloon. But the plasma membrane is still intact however it has these blebs. Also the organelles in the cell are swollen and large notice the mitochondria and ER. Some micro densities appear also , in the addition of the accumulation of damaged phospholipids which are called myelin figures.

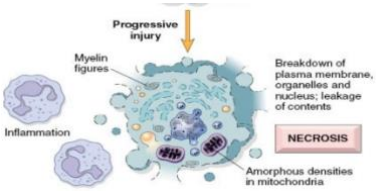

If the cell was exposed to a much higher stress and a more severe injury, it won't be able to tolerate that stress and the reversible injury will progress to an irreversible one or the "Necrotic" type of cell death . In this case the plasma membrane raptures because of the increased stress and "swelling" of the cell and this is when the cell death happens. The organelles keep swelling and we can see changes in the nucleus .Then when the cell rapture, inflammatory cells come to the area to engulf and digest the necrotic dead cell. So when the cell dies because of irreversible injury or mostly pathogenic reasons this is what we call "Necrosis".

The other type of cell death is “Apoptosis” which will be discussed in the next lecture. But for now you should know that necrosis and apoptosis are two different patterns of cell death. Necrosis is the uncontrolled type of cell death and apoptosis is the programmed or controlled.

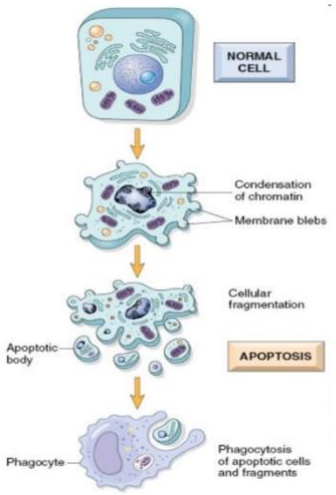

The reversible injury

What does it mean? When the cell is exposed to a certain stress it can get back to normal when the stress is removed, this is because the plasma membrane is still intact ,the organelles are swollen but nit damaged and the nucleus hasn’t really changed that much .One important thing to know is that during the reversible or the irreversible injury the cell is malfunctioning but it’s still alive in during the reversible injury.

So ..in reversible injury the cell can get back to normal and none if its compartments is damaged. It’s non-functional but alive .

Morphologic changes

Many changes happen to the cell, morphologic injuries which can be seen by the light microscope and ultra-structural alterations can be seen by the electron microscope. These changes are mainly cell swelling and fatty change.

Cellular swelling can be seen by the naked eye as the swelling of the whole organ. When the cells are swollen the organ will look larger and more watery.

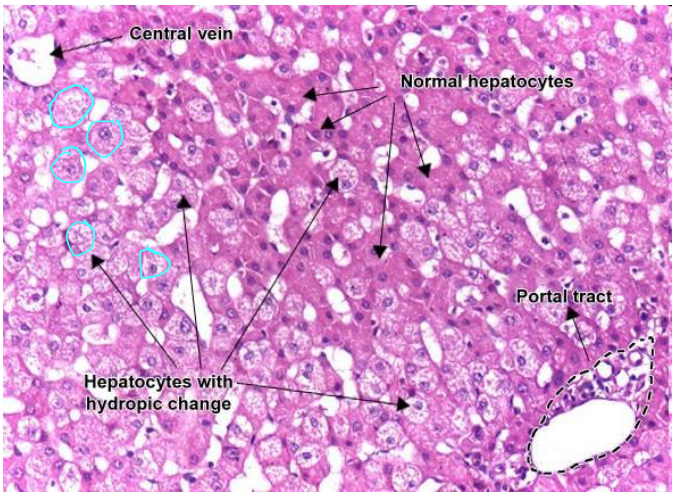

In this light microscopic image, we took a biopsy of an injured tissue and we can indicate the swelling of the cells from the whitish colour which represents water that is present in high amounts in the cells. The swelling occur because the pumps aren’t working since the cell in not functioning at all. Na^+ enter the cell followed by water which increases the size of the cell and this is called “Hydropic change".

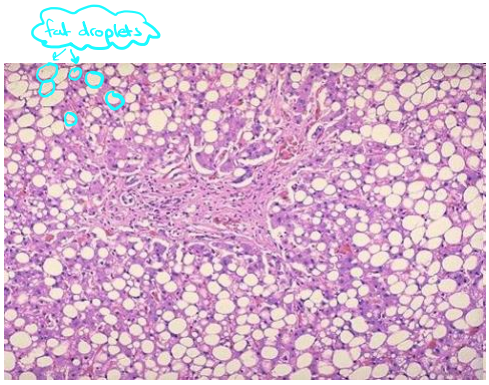

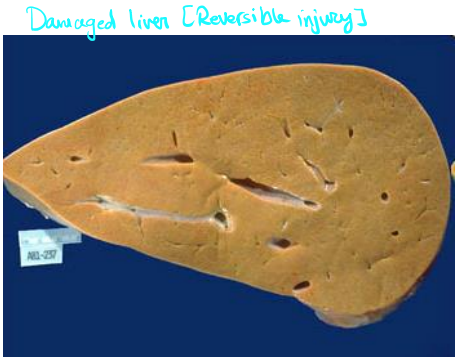

Now the other morphologic change is the "fatty change" and we can see it by the naked eye (the yellow colour of the liver cut surface), this means the accumulation of fat. In the microscopic image we can see fatty droplets so it looks like an adipose tissue. The fatty change happen due to the damage of membranes phospholipids so they accumulate in the cytoplasm forming these fat droplets.

Using the electron microscope, we can see ultra-structural changes that cannot be seen by the naked eye. The main changes are:

1. The occurrence of blebs in the plasma membrane, but it's not damaged and still intact
2. Swelling of the mitochondria and the appearance of black densities because of the damaged phospholipids
3. Swelling of the endoplasmic reticulum and clumping of the chromatin in the nucleus
4. The occurrence of myelin figures.

So ..many changes are seen in the reversible injury mainly cell and organelles swelling. Keep in mind, the plasma membrane is still intact and the nucleus hasn't changed much.

The irreversible injury

If the injury is very severe and the cell couldn't deal with it and get back to its normal state it will progress into an irreversible injury and that's what is called cell death or necrosis.

Features of irreversible cell injury

The main characteristic feature of necrosis at the ultra-structural level is the irreversible mitochondrial dysfunction.

The mitochondrion is the energy house of the cell, so when the mitochondria isn't able to function normally (can't deal with the stress in the reversible injury), it won't produce energy and cell will die.

The second feature is the loss of the plasma membrane and the organelles membranes (rupture). When some organelles like mitochondria or lysosomes lose their membranes, their enzymes will be leaked and lost.

The other feature is the disappearance of DNA, and it becomes IMPOSSIBLE for the cell to get back to normal.

Morphologic changes

The first thing we notice is increased eosinophilia, when we stain the slide with haematoxylin and eosin, the cytoplasm appears pinkish due to the increased binding of eosin to the denatured proteins and the disappearance of the RNA.

NOTE... in the reversible injury the cells appear whitish because of the increased amounts of water inside cells.

Other changes are similar between the reversible and irreversible injuries but more severe in the latter.

The ER and mitochondria dilatation, the loss of the membranes and the accumulation of the black densities and myelin figures

And the nuclear changes which are very important in the irreversible injury, it starts with “pyknosis” or the shrinkage of the chromatin and increased basophilia so it looks like a dark blue spot. Then it goes into “karyorrhexis” (chromatin fragmentation) and “karyolysis” (chromatin disappearance/basophilia fades)

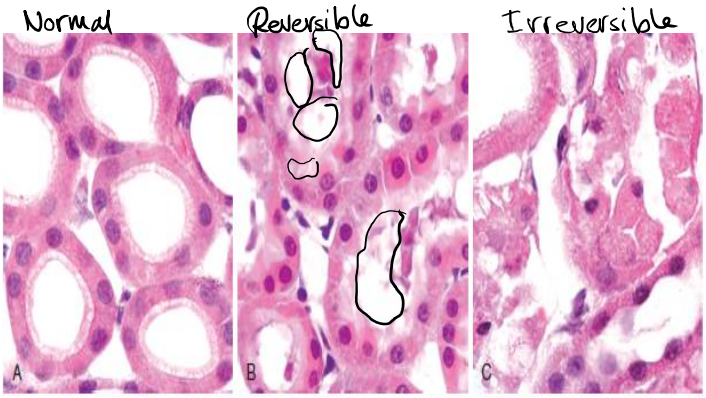

You can see at the microscopic level this section of the kidney comparing the cell status change from normal to reversible injury to irreversible injury (left to right)

On the left: the cells are normal and you can see normal nuclei inside

In the middle: the cells are swollen and you can see the whitish colour they’ve turned into. Some cells will look very eosinophilic preparing to enter the irreversible injury status.

On the right: some cells have lost their nucleus and got ruptured.

Types of cell death

We’ve mentioned before the two types of cell death, necrosis and apoptosis, each one occurs depending on the nature and severity of the injury.

Necrosis usually happens when the injury is rapid, uncontrollable and lead to severe disturbances. Mostly because of ischemia, toxins, infection or trauma.

Apoptosis is controlled and regulated by genes and regulatory pathways and it happens in less severe situations like sun induced injury or a growth factor deficiency.

Apoptosis can be modified by certain substances and it’s the basic mechanism of some chemotherapeutic agents that are used to treat cancer.

Sometimes, necrosis and apoptosis occur at the same time and in this case, it’s called “Necroptosis”, so for example when ischemia happen some cells die of necrosis while others die by apoptosis.

This table summarises the important differences, notice the necrosis is almost always pathologic.

Table 1-1 Features of Necrosis and Apoptosis

Feature	Necrosis	Apoptosis
Cell size	Enlarged (swelling)	Reduced (shrinkage)
Nucleus	Pyknosis → karyorrhexis → karyolysis	Fragmentation into nucleosome size fragments
Plasma membrane	Disrupted	Intact; altered structure, especially orientation of lipids
Cellular contents	Enzymatic digestion; may leak out of cell	Intact; may be released in apoptotic bodies
Adjacent inflammation	Frequent	No
Physiologic or pathologic role	Invariably pathologic (culmination of irreversible cell injury)	Often physiologic; means of eliminating unwanted cells; may be pathologic after some forms of cell injury, especially DNA and protein damage

DNA, deoxyribonucleic acid.

Reversible cell injury... cell death, rupture of membranes, loss of organelles and chromatin. And cell death is 2 types: necrosis (sudden and uncontrolled), apoptosis: (programmed).

Clinical implications

Why do we study cell injury and learn about these mechanisms? Because they help us diagnose certain diseases.

For example, we know the cell and organelles damage means that enzymes will be leaked and they'll end up in the blood stream. So, when test a blood sample the measurements of these enzymes help us detect the occurrence of necrosis and where.

1. When we suspect a myocardial infarction or myocardial muscle necrosis, it can be detected by measuring the cardic enzymes in the laboratory.
2. Or detect hepatitis provided that we know that the damage of hepatocytes means spillage of hepatic enzymes to the blood.

Morphologic patterns of tissue necrosis

When necrosis affects great portions of the tissue it will result in certain gross morphologic patterns (gross = seen by the naked eye). These patterns can give us a clue about the etiology of necrosis (the cause of it).

All morphologic patterns of necrosis can be seen grossly except for fibrinoid necrosis which can only be seen under the microscope.

Coagulative necrosis

The first type the of morphologic patterns is called coagulative necrosis and it's usually caused by ischemia to all solid organs except in the brain characterised by a wedge-shaped pale area corresponding to the decrease in blood supply.

Under the microscope, the tissue will look pale, however it's preserved for many hours or sometimes days. The decrease of blood supply to the area cause the proteins and the enzymes to denature, so the enzymatic digestion won't happen. After few hours, the inflammatory cells will rush to the area and clean these eosinophilic dead cells.

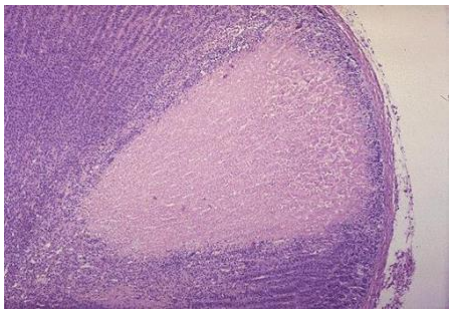



Liquefactive necrosis

The second pattern is called liquefactive necrosis, a viscous fluid like material appears on the affected area. It's may be caused by bacterial or fungal infections which lead to the formation of a creamy yellowish fluid called pus, or by ischemia or infractions to the CNS.

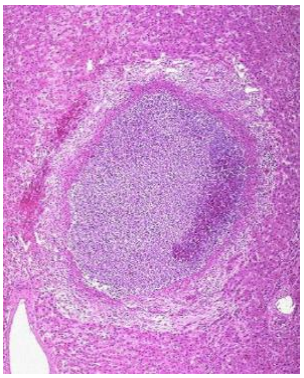

In this section of the lung we have this cavity filled with the yellowish fluid, and microscopically it is characterised by the rapid accumulation of inflammatory cells like neutrophils.

Here in the brain this is a focal area containing a liquefactive viscous fluid corresponds to an area on infarction in the brain

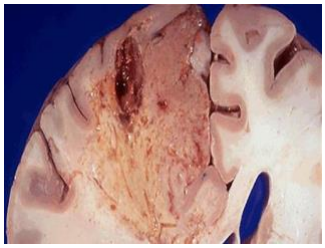

Gangrenous necrosis

Gangrenous necrosis is a coagulative necrosis but this is a medical term. It occurs because tissues at different planes of the organ get affected by coagulative necrosis. We see this a lot in diabetic patients.

The black colour appears because of the ischemic necrosis of the skin, underlying tissues and the bones. It can be dry or wet if there's a super imposed infection on it.

Caseous necrosis

Caseous necrosis appear as a cheese like yellow material in the area of infarction. In this case the tissue isn't preserved at all so it's characterised by an acellular centre that stains pink (eosinophilic) surrounded by macrophages and inflammatory cells and we call this granuloma

This type of necrosis is seen associated with tuberculosis. (an infection caused by myocabaterium TB)

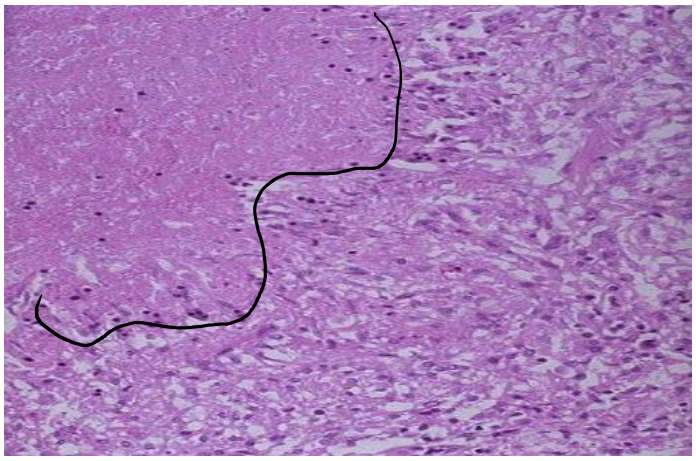

Fat necrosis

Fat necrosis is associated with acute pancreatitis, which is considered a top emergency. In this case the pancreatic enzymes mainly lipasesnwill be released to the peritoneum and will digest the fat in the abdomen releasing fatty acids from triglycerides so there's fat destruction and they can bind to Ca^{2+} which leads to the appearance of these whitish foci that look like a chalky material (saponification) which helps the surgeon to identify fat necrosis.

Under the microscope, we see shadows of these fatty cells with lost nucleus

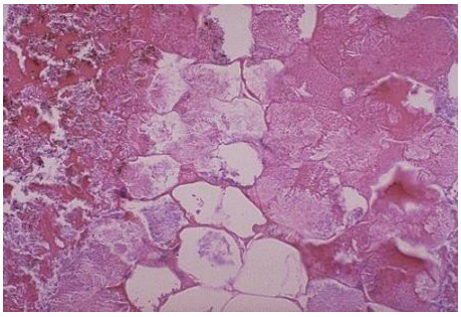

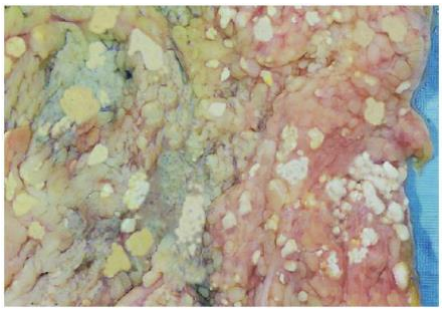

Fibrinoid necrosis

Fibrinoid necrosis can be seen only under the microscope. It happens because of the deposition of fibrin that contain pink material in the walls of blood vessels, which occur due to an antigen-antibody reaction in the wall of blood vessels leading to this deposition.

Usually associated with vasculitis.

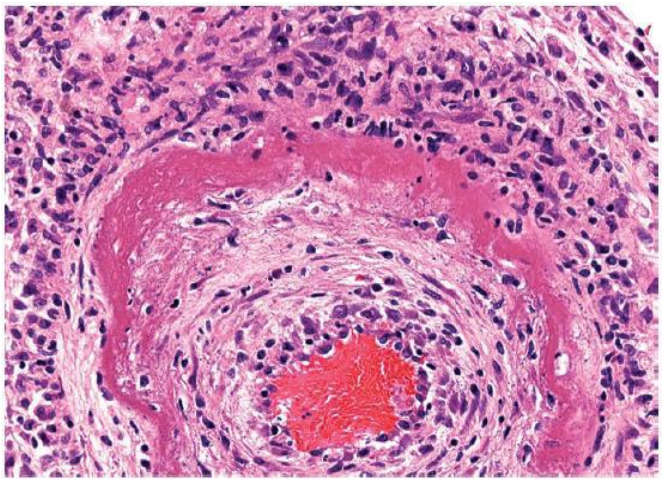

Morphologic patterns:

Coagulative: ischemia to solid organs, wood shaped

Liquefactive: bacterial or fungal infections, ischemia to CNS , pus

Gangrenous: necrosis on different tissue planes, black

Caseous : yellow area ,not preserved tissue, granuloma

Fat: release of fatty acids ,saponification, chalk like area

Fibrinoid : fibrin attachment to blood vessels wall ,under the microscope.