Q. + Short answers

1- The skin of the Face is:- Elastic, vascular (Bleed profusely + heals Rapidly.
2- presence of Ache due to :- sweat + sebaceous gland.
3- superficial Facia contains:- muscles, Fat tissue, N+A+V.
4- deep Facia:- No deep Facica / Except over the parotid Gland
5- General feature of muscles of Facial Expression:-
a- lies within → Superficial Fascia
b- take their origin From → Facial Bones
c- inserted into → Skin
d- arranged arround 3 opening → mouth, Nose, orbit
e- supplied by → Facial Nerve
f- divided to → 3 large ms. + Many small ms
6- A large muscle that compeletly surround each orbit and Extends into each eyelid → orbicularis oculi
↳ Note:- has 2 major part → 1- outer orbital 2- inner palpebral.
7- Action of palpebral part:- Close the Eye gently. ↳ Eyelid
8- Action of orbital part:- close the Eye Forcefully + produces wrinkling.
9- Nerve supply For 2 parts → Branches of Facial Nerve
10- orbital part:- 1- origin From:- medial palpebral Ligament
2- insertion:- loops Return to origin.
11- palpebral part:- 1- origin:- medial palpebral Ligament
2- insertion:- Lateral palpebral Ligament
12- which part of orbicularis oculi Aids in the Flow of tears → Lacrimal part.
13- orbicularis oris muscle:- 1- Nerve supply:- Branch of Facial Nerve
* origin → alveolar process of maxilla, Mandible and From the pterygomandibular Ligament. 2- Action:- Compresses the Lips together 3- Form the substance of:-
14- muscle of cheek (Buccinator):- 1- Nerve supply:-
2- Action + origin + insertion
15- Buccinator pierced by the :- parotid Gland
16- Forceful Expulsion of air From the cheek → is Related to 2 masceles → ① Buccinator ② orbicularis oris
17- platysma :- 1- Nerve supply:- Facial Nerve Branches
2- Drigin :- Deep Fascia over pectoralis Major + deltoid.
3- Insertion:- Body of Mandible + Angle of Mouth
4- Action:- Depresses the Mandible + lower Lip + Angle of Mouth
Note:- platysma compeletly corers the Anterior + lateral aspect of the Neck.
18- the pathway of Facial Nerve:-
originate from brain stem → leaves cranial cavity through internal acoustic is Give posterior Auricular N. ← Exit From Stylomastoid ← Runs in facial canal
↳ pass through Parotid Gland (without innervate it) → split into 5 Branches innervate ms. of Face

الممسوحة ضوئيا بـ CamScanner

Face - Anatomy 6

Note:- Bell's palsy → Facial Nerve paralysis.

19- Damage to Facial Nerve in

a. The internal acoustic meatus by → tumor

b. The middle ear by → infection

c. the facial Nerve canal → perineuritis

d. The parotid Gland by → tumor

e. laceration of the face / laceration mean's deep cut

→ to check if there is any damage in 7th CN (Bell's palsy) ask Patient to open his mouth and Raise the brows

* هلا هون هي الامراض او الاسباب إلي ادت لـ damage in 7th CN بس إلي مفروض نحفظه هي النقاط الرئيسة a+b+c+d+e الباقي امثلة عالحالة يعني

والمنطقة إلي ما فيها تجاعيد بكون صار فيها شل + لانه ما بقدر يسكر عينه ممكن يصير في جفاف بالعين وفشل.

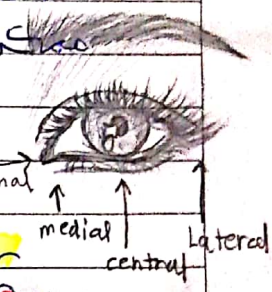

* مخطط شامل كل الـ Branches إلي اصلها الـ 5th CN *

* Trigeminal Nerve * (5th CN.)

① ophthalmic
- ① Frontal
  - ① supraorbital N.
  - ② supratrochlear N.
- ② lacrimal
- ③ Nasocilliry
  - ① infratrochlear N.
  - ② External Nasal N.

② Maxillary
- ① infra orbital
- ② zygomaticotemporal
- ③ zygomaticofacial

③ Mandibular
- ① Mental N.
- ② buccal N.
- ③ auriculotemporal

20- Frontal Nerve → supratrochlear → supply :- skin of medial part of Eyelid

21- Frontal Nerve → supra orbital → supply :- skin on the central part of Eyelid

22- Lacrimal Nerve → supply :- lacrimal Gland + Lateral part of upper Eyelid

23- Naso cilliry Nerve → infratrochlear → supply :- medial part of upper Eyelid

24- Naso Cilliary Nerve → External Nasal Nerve → supply :- dorsum of the Nose

25- Maxillary N → infra orbital N. → direct continuation of → Maxillary N.
- ↳ Enters the orbit through → inferior orbital Fissure
- ↳ Appears on the face through → infra orbital Foramen
- ↳ supply → skin of lower Eyelid + side of Nose + upper lip + cheek

26- Maxillary N. → Zygomatico Facial N → branch of the → Zygomatic N.
- ↳ pass through → Zygomatico Facial Foramen
- ↳ supply → skin of prominence of the cheek

27- Maxillary N. → zygomatico temporal N. → branch of the → Zygomatic N.
- ↳ pass through → zygomatico temporal
- ↳ supply → skin over the temple

الممسوحة ضوئيا بـ CamScanner

28- Mandibular Nerve → Mental N. → Emerges from → Mental Foramen
→ supply → Lower Lip + Chin

29- buccal Nerve (Sensory) From Mandibular → supply → Skin over buccinator ms.

30- Mandibular Nerve → Auriculatemporal Nerve → supply →
1- auricale + skin over temporal Region + External Auditory meatus

31- Mandibular foramin transmits → inferior alveolar N + vessels

32- Mental foramen transmits → Mental Nerve + vessels

33- Greater Auricular N. → branch of the → cervical plexus ($C_2 + C_3$)
↳ supply → Angle of Mandible + Parotid Gland
Lower half of auricle

34- lesser occipital N. → Branch of the → Ant. Rami C_2 / cervical
↳ supply → lateral part of scalp / behind the auricale
↳ Emerges behind → post. borden of sternocliodmastoid ms.

35- Greater occipital N. → Branch of the → post. Rami C_2 / cervical
↳ ascends over the back of scalp.
↳ supply → Back of scalp as far Forward vertex

36- Clinical condition → Trigeminal neuralgia → patient pain in the distribution of Maxillary + Mandibular division with ophthalmic division

* Arterial supply of the face *

a- Main Blood supply → Facial A. + superficial Temporal A. From → ECA

b- ophthalmic Artery → Branch of → Internal carotid A.
→ Enters orbit through → optic canal along with optic N.
(Terminal Branches) → then Gives 2 Branches → supra orbital + supratrochlear

c- External carotid Artery terminates as two Branches (within Parotid)

d- 1- Maxillary A. → Deep to the Neck of Mandible
2- superficial temporal A → From upper border of parotid Gland
↳ this Artery Give Branch within parotid Gland, Runs across the cheek above parotid duct → transverse Facial A.

e- superficial temporal A. supply → the scalp + palpated in Front the Auricle.

f- Facial A. terminats as → angular A.
↳ At the middle corner of the Eye.

g- ascends deep to submandibular Gland → Facial Artery

h- ascends superficial to submandibular Gland → Facial vein.

i- Angular A. anastomoses with terminal Branches of ophthalmic A.

j- superficial temporal A → divides into Frontal (Ant.) & parietal (post.) A.

الممسوحة ضوئيا بـ CamScanner

Follow face – lecture 6

* Venous Drainage of the face

37- Facial vein Formed at the → medial Angle of the eye
↳ union of → supra orbital + supra trochlear veins
↳ descends post. to the Facial Artery to the lower margin of the body of Mandible.
↳ joined by Ant. division of Retromandibular vein.
↳ Drains into Internal jagular vein.

38- Retromandibular vein → Formed in the substance of → parotid Gland
→ Formed by union of → Maxillary + temporal veins
→ divided to Ant + post. division below → inf. border of Gland

39- deep Facial vein connect → Facial vein to pterygoid venous plexus.

40- Danger triangle of the face.
↳ it's communication ⇝ 1- deep facial vein → btw Facial vein + ptregyoid plexus

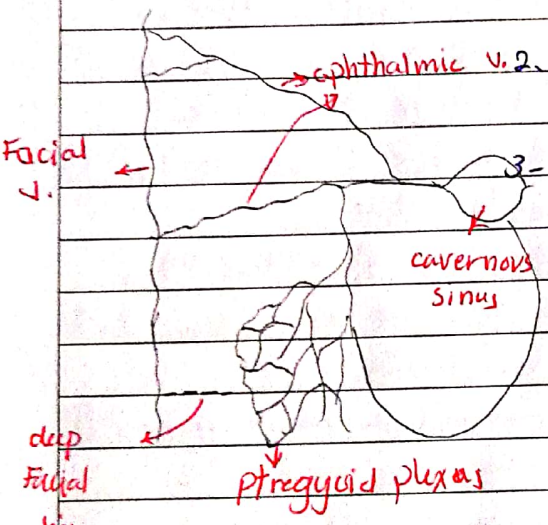

2- ophthalmic veins → btw Facial vein + cavernous sinus

3- ptregyoid plexus communicate with cavernous sinus

this connection provides the pathway for spread the infection to the cavernous sinus.

Clinical condition →
cavernous Sinus syndrom →
↳ due to sepsis From Central portion of the Face + paranasal sinus.
↳ Clinical manifestation → ophthalmoplegia + Exophthalmos
pain in face, venous congestion (periorbital Edema)
↳ ophthalmoplagia → paralysis + weakness of Eye muscles.
↳ Exophthalmos → bulging of the Eye Anteriorly out of the orbit
↳ cavernous sinus infection → Result in Damage to Any of CN that pass through it.

الممسوحه ضوئيا بـ CamScanner