MSS

Musculoskeletal System

Doctor 2019 | Medicine | JU

NO.

PBL

Writer	Omar Rashdan & Dina Adel
Scientific correction	
Grammatical correction	
Doctor	

- ✓ As you can see in the pictures below , **trepanation, craniotomy**, **craniectomy**, and getting into the skull and performing procedures inside it are things known from a long time ago , they were discovered among the Maya people of Peru.
- ✓ The skull shown in picture 2 has undergone craniectomy by the Maya people of Peru in which they entered the skull and performed a procedure inside.
- ✓ It was also discovered that the pharaohs applied the same procedures to the skulls of the mummies.
- ✓ The tools we use now to perform certain procedures on the skull don't differ a lot from the tools that were used hundreds or even thousands of years ago.



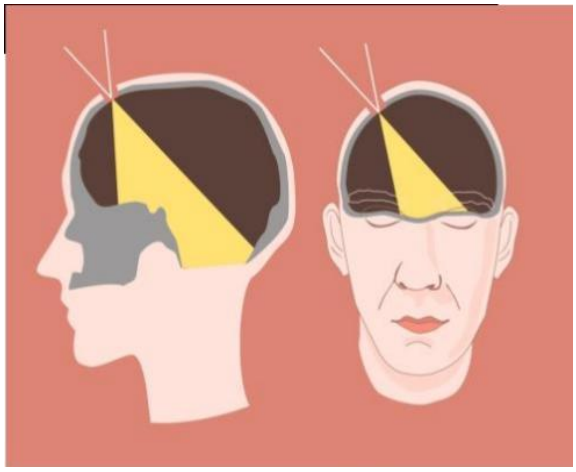

Now , what is the meaning of **Burr hole**?

Burr hole means a hole done using a drill , we need to do Burr holes in certain operations which require drainage of liquid blood (old non-clumped blood) such as subdural hematomas. The procedure occurs by making a hole in the skull (we open the meninges) and then we drain the blood that is described to be similar to motor oil -this operation is similar to the renewing of motor oil that occurs in car garages –. (During the procedure we might use an internal drainer or not).

This operation is called **Trepanation**: drilling a hole into the skull to expose dura and brain and treat related problems like drainage of a subdural hematoma. (Same as **Burr hole).**

Craniotomy: removing a bone flap (like a window) from the skull in order to perform surgery on dura or brain **and fixing it back .**

While **craniectomy** means: removing a bone flap away from the skull **and not putting it back again** in order to decompress the brain (we return the skin on top of the site of operation without returning the bone).

Craniectomy is also referred to as decompressive craniectomy because in cases of severe cerebral (brain) swelling due to severe traumas (strong hits) that cause high intracranial pressure , we open a large window in order to relieve the pressure on the brain and when the pressure is relieved, we return the bone back. (**Important note :** we keep the removed bone in a specialized refrigerator in order to preserve it and return it back).

Cranioplasty: putting back something else than the bone flap like titanium mesh (plate) or bone cement .

Why? The bone might be broken, or it isn't suitable to return it back because it rotted and hasn't been well preserved, so we use a substitute instead of the bone.

Brain injuries can result in several consequences , the simplest of which is the **concussion** (it can result from a car accident for example) , concussion means: a temporary loss of consciousness without any evidence on the CT scan , so the injured person lost consciousness for seconds or minutes, but the CT scan didn't

show any damage or bleeding , so we explain the reason of unconsciousness to be due to the **concussion.**

Another brain injuries that are important are the **extradural (epidural) hematoma** and **subdural hematoma .**

The **extradural (epidural) hematoma** is bleeding above the dura and it is usually **arterial (tearing of an artery)** and usually this injury occurs in the **pterion** which is an area where the skull bones meet (frontal , parietal , temporal and sphenoid bones) and this area is called in **Arabic** (**منطقة المقتل**) (Fatal zone) because it is fatal.

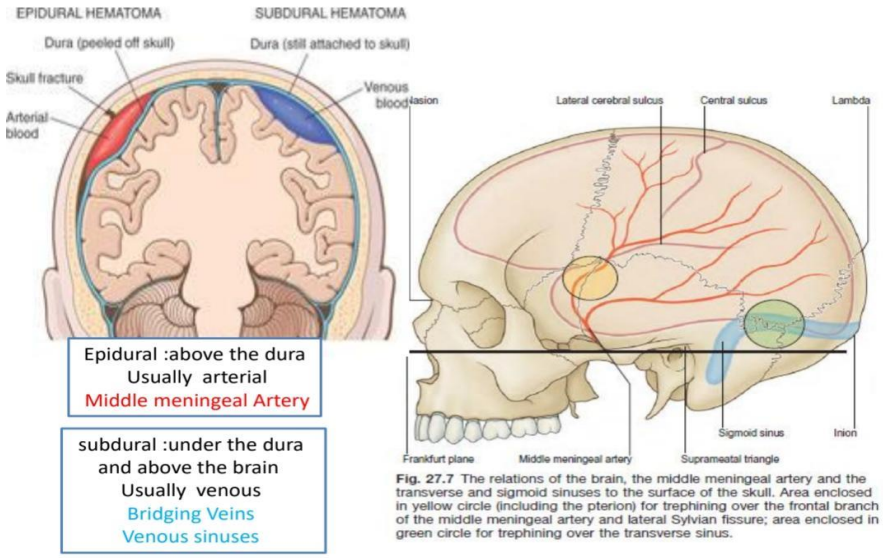

Fig. 27.7 The relations of the brain, the middle meningeal artery and the transverse and sigmoid sinuses to the surface of the skull. Area enclosed in yellow circle (including the pterion) for trephining over the frontal branch of the middle meningeal artery and lateral Sylvian fissure; area enclosed in green circle for trephining over the transverse sinus.

The anterior branch of the middle meningeal artery runs beneath the pterion. (Note : there are anterior and posterior branches of the middle meningeal artery which are branches of the external carotid artery- the maxillary branch of the external carotid artery specifically , only the anterior branch of the **middle meningeal artery** runs beneath the pterion.).

This bleeding (the **epidural bleeding**) is arterial, so it is very fast, but since it is above the meninges , and because the meninges are continuous with the sutures (the periosteal layer of the dura mater is continuous with the sutural ligament), there isn't much space for the bleeding to expand, so it takes the shape of a biconvex lens .

✓ How to deal with this condition? (treatment of epidural bleeding)

By **craniotomy**, we have to remove a bone flap (opening a window in the skull) and drain the blood , then return the bony flap again.

Now , because fresh and recent bleeding acquires the nature of jelly, so it is lumpy and not liquid, so we can't drain it by applying a Burr hole (small hole) and we need to remove it as a whole mass by **craniotomy** (we remove the bone then we remove the blood clot and then we return the bone back after the operation).

Typical EDH on CT scan :

- Bi convex lens shaped
- Always acute
- Arterial bleeding

- Arterial bleeding due to injury to anterior branch of middle meningeal artery.
- Usually due to trauma over the pterion (weak point)
- Treatment: craniotomy and evacuation of blood clot as it cannot be sucked out through a burr hole .

Now , while epidural hematomas are always acute, subdural hematomas that result from venous bleeding due to rupture of the bridging veins which connect the dura to the brain (they are multiple veins) , are either acute or chronic.

So when one of the bridging veins ruptures and starts to bleed slowly, and the bleeding starts to dissolve with time (NOT jelly like) , it becomes chronic.

Now , the **chronic subdural hematoma** appears on the CT scan with hypodense color. The bleeding presses on the brain and it takes a lunar shape like the shape of the surface of the brain, also this bleeding is described to be laminar which means that it is so thin.

Sometimes the bleeding is very severe especially in elderly who take anti-coagulants, so the color of the bleeding on the CT scan is white like the color of the bone(hyperdense) as you can see in the picture , and it is pressing on the brain. **(acute subdural bleeding)**

Now , an **acute** venous subdural bleeding in which the blood is **clumpy and didn't dissolve yet** , an operation similar to the one that was done for epidural hematoma, which is **craniotomy,** is needed (in order to remove the acute bleeding as a mass).

Meanwhile , chronic venous bleeding is **liquid, since it has dissolved** and it is similar to the motor oil, so we drain it using **trepanation** or **Burr hole**.

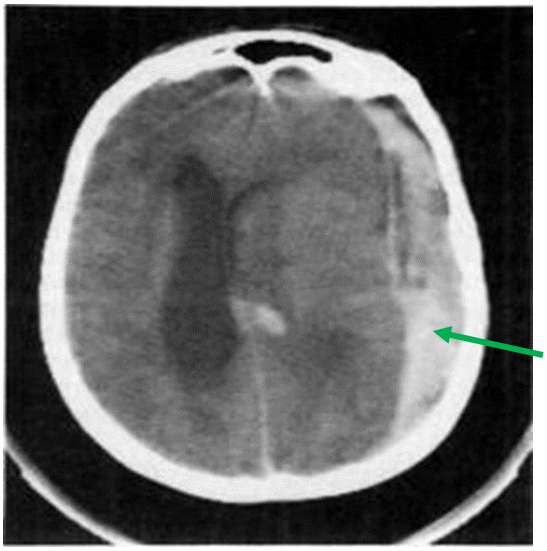

Typical acute SDH on CT scan:

Lunar shaped

Bleeding is Hyperdense: white like bone

Venous bleeding

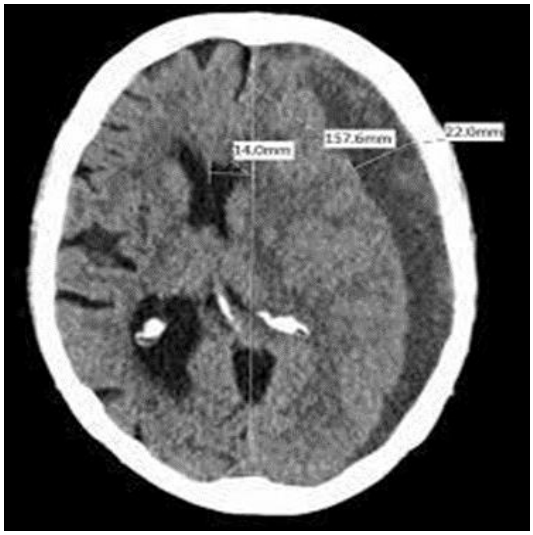

Typical chronic SDH on CT scan:

Lunar shaped

Bleeding is hypodense like CSF

Venous bleeding

	Epidural (acute)	Acute subdural	Chronic subdural
Location	Between the skull and dura matter	Between dura and arachnoid matter	Between dura and arachnoid matter
Cause	Arterial	Venous	Venous
Rupture	Middle meningeal artery	Bridging vein	Bridging vein
Shape	Biconvex lens	Lunar	Lunar
Color		Hyperdense	Hypodense
Treatment	Craniotomy	Craniotomy	Trepanation (Burr hole)

Lucid Interval

- ✓ Lucid interval is a temporary improvement in a patient's condition after a traumatic brain injury, after which the condition deteriorates.

- ✓ It occurs after the patient is knocked out (loses consciousness) by the initial concussive force of the trauma (car accident for example) , then the patient regains consciousness , then lapses into unconsciousness again after recovery when bleeding causes the hematoma to expand past the point at which the body can no longer compensate (due to increased intracranial pressure).

- ✓ A lucid interval is especially indicative of an epidural hematoma.

- ✓ It usually happens in children , and not every epidural hematoma causes lucid interval. An estimated 20 to 50% of patients with epidural hematoma experience such a lucid interval. (30% on average)

- ✓ It can last minutes or hours

- ✓ Now , even if nothing appears under a CT scan , we should be really careful , and the patient might need supervision inside the hospital , or we can tell the patient's parents that if the patient sleeps , they have to wake him up every (30-60 minutes) to make sure everything is fine.

- ✓ To stop the hemorrhage, the torn artery or vein must be ligated or plugged. The burr hole through the skull wall should be placed about 1 to 1.5 in. (2.5 to 4 cm) above the midpoint of the zygomatic arch.

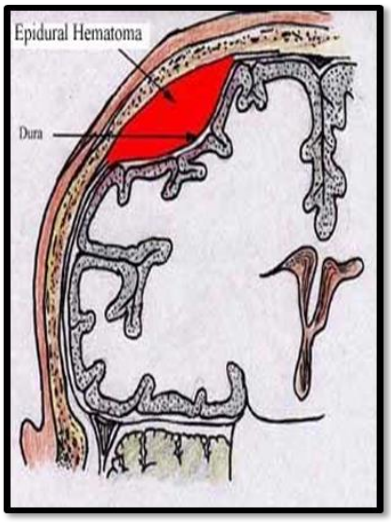

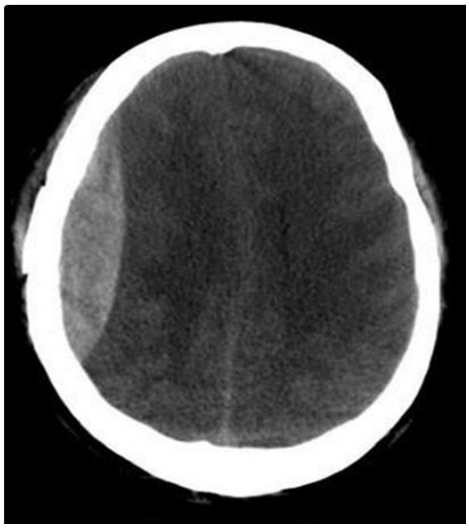

Subdural Hemorrhage

A subdural hemorrhage is caused by a violent shaking of the head (e.g., child (violent shaken baby syndrome) abuse or car accident) and commonly occurs in alcoholics and elderly.

The blood vessels involved are the **superior cerebral veins ("bridging veins").**

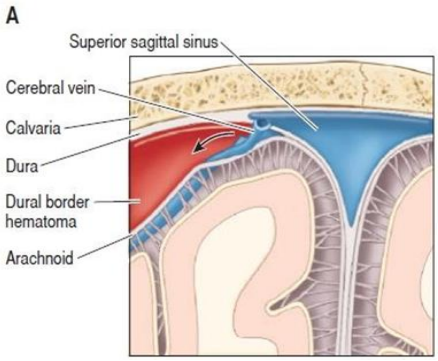

Clinical features include:

- **A CT** scan shows a **thin, crescent- shaped hyperdensity that hugs the contours of the brain; venous blood** is located between the dura and arachnoid; blood accumulates slowly (days to weeks after trauma);
- **No blood in the CSF after lumbar puncture.**

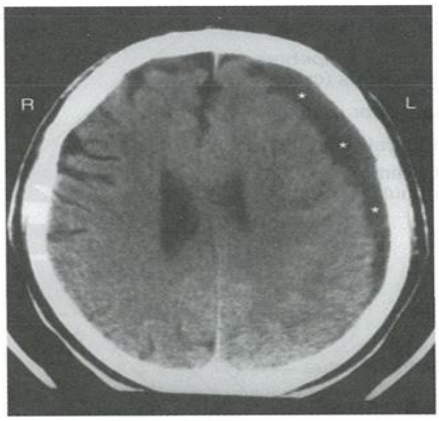

B. Subdural Hematoma*

Base of skull fractures

Base of skull fractures are really important because sometimes we miss it (we don't see it in CT scan) , and we won't notice it until symptoms start to appear.

Why it is important to identify base of skull fractures?

Because of possible serious complications like CSF rhinorrhea or otorrhea and then meningitis.

Explanation : base of skull fractures are dangerous because they might cause abrasions in the meninges and therefore leakage of the cerebrospinal fluid (CSF) through the nose or the ear , this means that there is communication between the brain , meninges , and the external environment which might cause meningitis.

What signs of base of skull fracture do we know?

- **Racoon eyes :** periorbital discoloration or hematoma that is symmetrical in shape, it indicates base of skull fracture even if we cannot see it on a CT scan
- **Battle sign:** hematoma behind the ear
- **Pneumocephalus :** subdural air in CT scan.



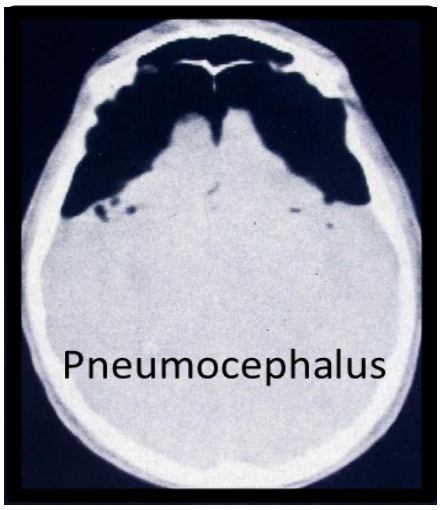

Note : a base of skull fracture can be indicated by :

- fluid (CSF) or blood leaking from the patient's ear (otorrhea)
- fluid (CSF) leaking from the patient's nose (rhinorrhea)
- **These two complications can stop on their own , but in case they don't, this requires a surgical intervention.**
- **Regarding rhinorrhea , in case we can't see fluid running from the nose , we ask the patient if he feels a salty taste in his throat.**

Brain Contusion

- ✓ Intra-parenchymal localized bleeding. (رضّة دماغية)

- ✓ It usually resolves with time , but in certain cases when we see it initially on the CT scan , we admit the patient to the hospital and we monitor it because it can expand in the first 48 hours to the level that we have to perform a surgery (craniectomy) to relieve the pressure on the brain , and even remove a part of the brain.

- ✓ If it exceeds 3 cm then it is an intracerebral hematoma.

Brain Herniations

All the previous injuries we discussed are dangerous because they could lead to brain herniation , which is protrusion of parts of the brain tissue through openings of the skull , which might lead to brainstem compression and eventually death.

Types of herniation:

1. **Subfalcine herniation** : the brain tissue moves underneath the falx cerebri in the middle of the brain. Brain tissue ends up being pushed across to the other side. (midline shift)

2. **Transtentorial herniation (uncal herniation)** : part of the brain herniates through the tentorium compressing on the brainstem which might lead to death . **It is also called uncal herniation due to the herniation of the uncus into the tentorial hiatus.**

3. **Caudal displacement of the brain stem** : high pressure in the brain pushes the brainstem inside the posterior fossa , this might also compress the brainstem stem and lead to death.

4. **Cerebellar tonsillar herniation** : herniation of the cerebellum (cerebellar tonsils) through foramen magnum.

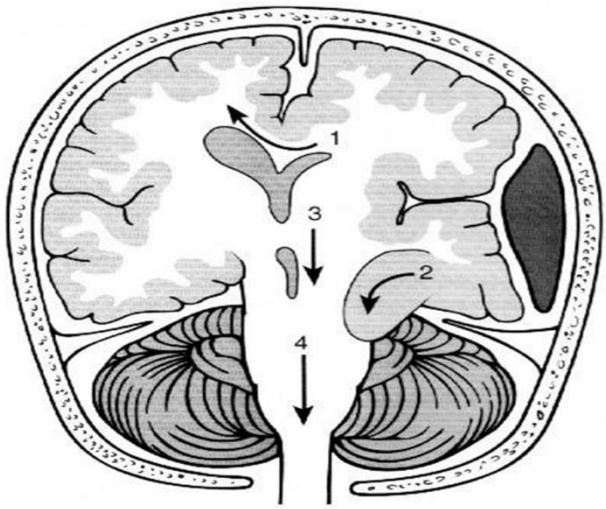

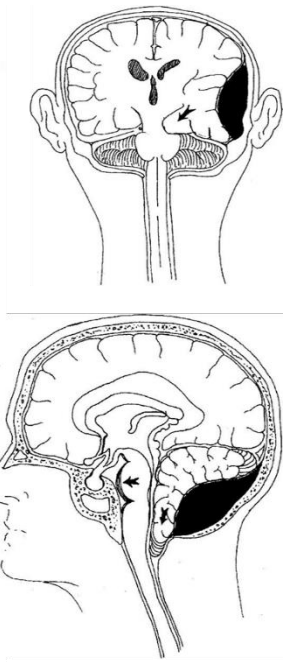

Fig. 3.3 Brain herniations. A lateral supratentorial mass will cause displacement of the lateral ventricles with (1) subfalcine herniation of the cingulate gyrus below the falx cerebri; (2) herniation of the uncus into the tentorial hiatus; (3) caudal displacement of the brain stem. Raised pressure within the posterior fossa may cause herniation of the cerebellar tonsils into the foramen magnum (4). (Adapted from Jennett and Teasdale 1981. Reproduced with permission.)