



Musculoskeletal System

Doctor 2019 | Medicine | JU

NO.

Pathology

Writer

Omar Rashdan

Scientific
correction

Grammatical
correction

Doctor

Fractures

‘ the most common pathology of the bone ‘

✚ *Fractures : loss of bone integrity from mechanical injury (trauma , car accident..) &/or diminished bone strength (due to abnormal bone from diseases such as osteoporosis , osteopetrosis , osteomalacia etc.)*

Classification of bone fractures:

▪ *Simple vs. Compound :*

Simple # → Closed , Skin is intact , Swelling.

*Compound # → Opened , Skin is ruptured ,
Fractured bone communicates with overlying skin.*

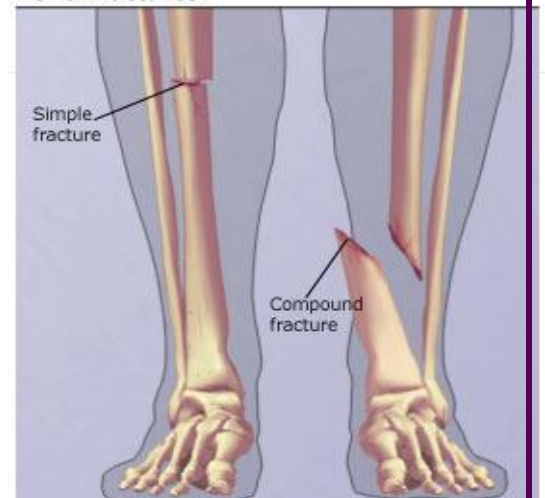
- *Simple fractures are easy to treat and heal quickly.*
- *Compound fractures are harder to treat and take longer time to heal.*

▪ *Displaced vs. Not displaced :*

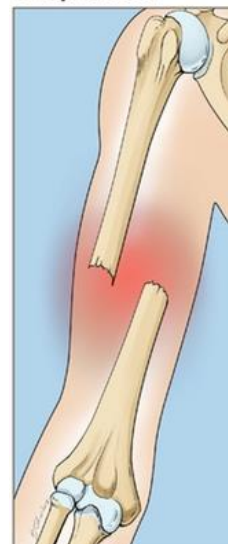
Displaced # → two ends of the fractured bone are not at the same axial line , ends are not aligned.

Non-displaced # → two ends are at the same axial line.

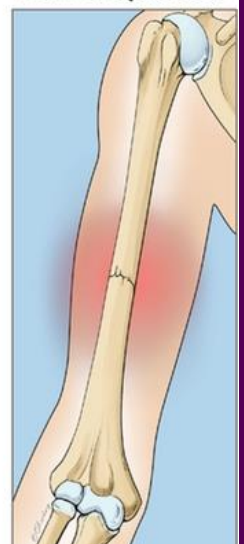
Bone Fractures



Displaced



Non-displaced



▪ **Stress fractures**

Stress # ➡ it is a repetitive slowly progressive bone fracture that happens in cases of osteoporosis, chronic abnormal bone and weak bone. *It usually happens in the axial skeleton, predominantly in the vertebral bodies leading to compression fractures.*

Book: *a slowly developing fracture that follows a period of increased physical activity in which the bone is subjected to repetitive loads*

▪ **Greenstick fractures**

Greenstick # ➡ soft bone fracture in children or young when the bone is not completely ossified (mineralized) - *in which the bone bends and breaks just like fresh wood-*

- As an orthopedic, when a child comes to your clinic due to sudden severe pain in his leg which he cannot stand on, you should be smart and able to diagnose greenstick fracture, as it doesn't appear under the X-ray scan, neither the hematoma has appeared yet.
-

▪ **Pathologic fractures**

Pathologic # ➡ any fracture that happens in an abnormal bone weakened by an underlying disease process, **or a tumor.**

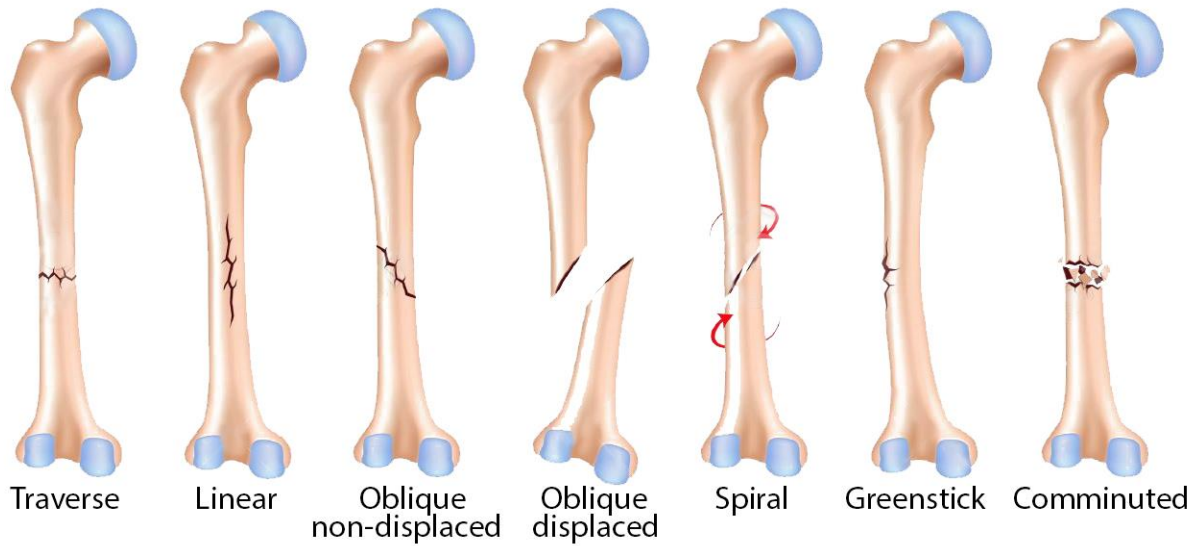
Hint: *A big fracture from a small trauma in an abnormal bone.*

Examples:

- *Compression fracture in the fifth lumbar vertebra in a woman suffering from severe osteoporosis.*
- *Fracture in the neck of femur in a man suffering from paget disease of bone after an accidental slip.*
- *Osteosarcoma of the proximal femur, chondrosarcoma of the neck of the femur might lead to fractures after minimal traumas.*

Important note: *in some cases, pathologic fractures might be the first presentation which leads to the discovery of a bone tumor*

Example: *A 55-year-old male presented with a fracture in the neck of femur, & after X-ray has been done, multiple osteolytic lesions have been found indicating multiple myeloma or metastatic carcinoma.*



Notes on the picture above:

✚ All the fractures above are in the femur bone which is a common bone to be fractured

✚ **Transverse #** (in the diaphysis) : Simple , Not compound , Non-displaced

✚ **Linear #** : Simple , Not compound , Non-displaced , Longitudinal , Happens due to a direct hit on the bone

✚ **Spiral #** : A certain type of Non-displaced , not compound , oblique fracture - especially in the humerus and the upper limb bones – that happens when torque (a rotating force) is applied along the axis of a long bone.

✚ **Comminuted #** : Break of the bone into more than two fragments. Usually , severe comminuted fractures are compound and displaced , indicating severe traumas such as road traffic accidents.

Bone Healing

Just like trauma, inflammation and wounds, bone fractures need healing so, mediators , growth factors, hematoma, granulation and scar formation are acquired .

Healing of the bone happens in stages :

- I. After 1-day , the reaction to a fracture begins with an organizing hematoma which fills the fracture gap and surrounds the area of bone injury.*
- II. Induction of multiple mediators of inflammation including Platelet Derived Growth Factor (PDGF) , TGF- β , Fibroblast Growth Factor (FGF) , Platelets , Inflammatory cells . Also , osteoclastic and osteoblastic activity are stimulated.*
- III. Chondrocytes will be stimulated for cartilage healing , initially.*

Important Note: During the healing process , woven bone appears.

- IV. In the late phases of the healing process , lamellar bone appears.*
- V. Complete repair of the bone after 3-4 weeks .*

FACTORS IMPACTING PROPER HEALING:

- *Displaced and comminuted fractures : hard to treat , require more time to heal*
- *Inadequate immobilization : leads to delayed union or nonunion.*
- *Pseudoarthrosis : happens in severe cases when nonunion persists , were the luminal surface may become lined by synovial-like cells, creating a false joint.*
- *Infection in open fractures : might lead to osteomyelitis post fracture*
Note: regarding infection , simple fractures are not to worry about.
- *Malnutrition : proper nutrition including protein, calcium and vitamin D is required to speed up the healing process.*
- *Steroids & anti-inflammatory drugs (AIDrugs).*

OSTEONECROSIS (AVASCULAR NECROSIS)

Osteonecrosis : Death of the bony tissue , mainly due to ischemia (loss of blood supply) that's why it is also called **Avascular necrosis**. It can be referred to as infarction (ischemic necrosis) of bone and marrow cells.

Osteonecrosis can occur in any bone. However, it occurs more commonly in certain bones and fracture sites ; like the **femoral head** which is the main classical example of a bone with Avascular necrosis.

Associated conditions

- **Vascular injury**

-Trauma: it is considered one of the major causes of osteonecrosis .It includes fractures ; for example : Fracture of the neck of femur → blood supply gets compromised → Avascular necrosis .

Note : one of the complications of pelvic fractures following a trauma is Avascular Necrosis of the head of the femur.

- Vasculitis : Is an inflammation of the blood vessels → risk factor for vascular thrombosis → ischemia .

- **Drugs** (more common than vasculitis)

Steroids : increases osteoclasts activity (as we learned before) → osteoporosis and bone loss → fractures → blood supply becomes compromised → ischemia

Example : A 65-year-old patient known to have rheumatoid arthritis for the last 15 years has been on steroids for the last 7 years , suddenly the patient wasn't able walk on his feet in addition to pelvic pain , the X-ray scan shows shadowing in the head of femur. → **Avascular Necrosis**

- **Systemic diseases**

Sickle cell disease : patients with this disease are at higher risk to develop vascular thrombosis due to sickle cell crisis

- **Radiation**

Repeated radiation therapy damages vascular components of the bone leading to ischemia.

Mechanism : *Avascular Necrosis due to vascular occlusion.*

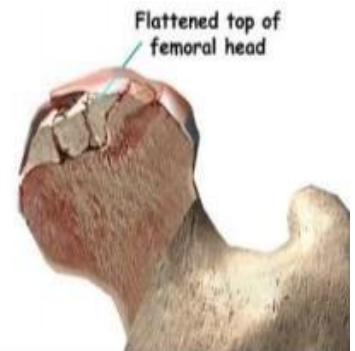
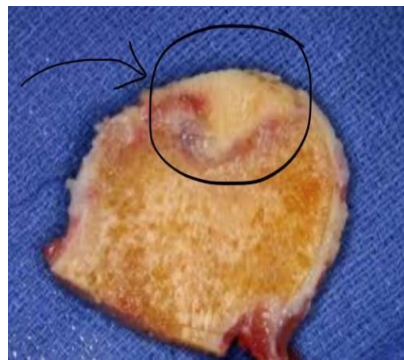
Example : *A patient diagnosed with sarcoma or malignancy in the pelvic bone with a previous history of radiation (radiotherapy) is at a higher risk of osteonecrosis*

Mechanisms

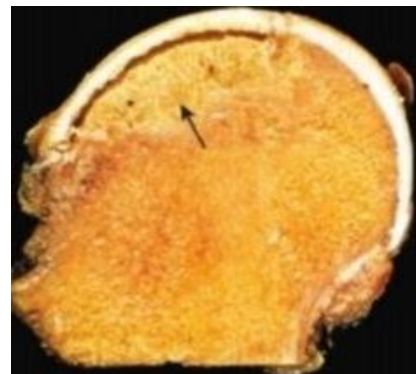
From the associated conditions mentioned above ,we can conclude that Osteonecrosis can happen in these suspected mechanisms :-

- 1) **Mechanical disruption** (Trauma leading to cut of blood supply by force)
- 2) **Thrombotic occlusion** (Sickle cell , Drugs-steroids-, Radiation)
- 3) **Extra vascular compression** (Trauma / Hematoma / Tumors / Fracture leading to compression on blood supply)

Necrotic bone is pyramidal in shape , the base of the pyramid is faced at the articular cartilage. (classic)



Note : wedge shaped necrosis in the head of the femur is classic to avascular necrosis



Osteomyelitis

Osteomyelitis : **Osteo** (relating to bones)-**myeloid** (relating to bone marrow)- **itis** (inflammation) .

Collectively : it is the inflammation of bone / marrow due to an infection

It's a Medical Emergency that is very serious and you have to pick it up diagnose it , and treat it properly .

Causes of Osteomyelitis

- Might be **part of a systemic infection**
Example : A patient with osteomyelitis of a vertebral body due to systemic septicemia such as gram-negative sepsis.
 - **Primary solitary focus** -which is much **more common and frequent**- in which only one bone is infected (ex :from surgical procedure at a certain site).
- ✚ Any organism can cause osteomyelitis , but bacterial osteomyelitis is the most common one.

Pyogenic Osteomyelitis: pus forming inflammation of the bone caused by an infecting organism , **mainly bacteria**.

Bacteria causing pyogenic osteomyelitis :

- **Staph. aureus** (gram +ve cocci) : **the most common cause of acute pyogenic osteomyelitis responsible for 80 to 90 % of the cases.**
- **Escherichia-coli** (gram –ve bacilli) , **Pseudomonas & Klebsiella** are more frequent in patients with history of recurrent urinary tract infections (UTI) or patients who are intravenous drug abusers (More virulent organisms) .

Mechanism of spread

1. **Hematogenous spread** : most common and occurs mainly in children
Example : Otitis media , Tonsillitis , Impetigo of the skin → bacteria in blood (bacteremia) → acute pyogenic osteomyelitis)

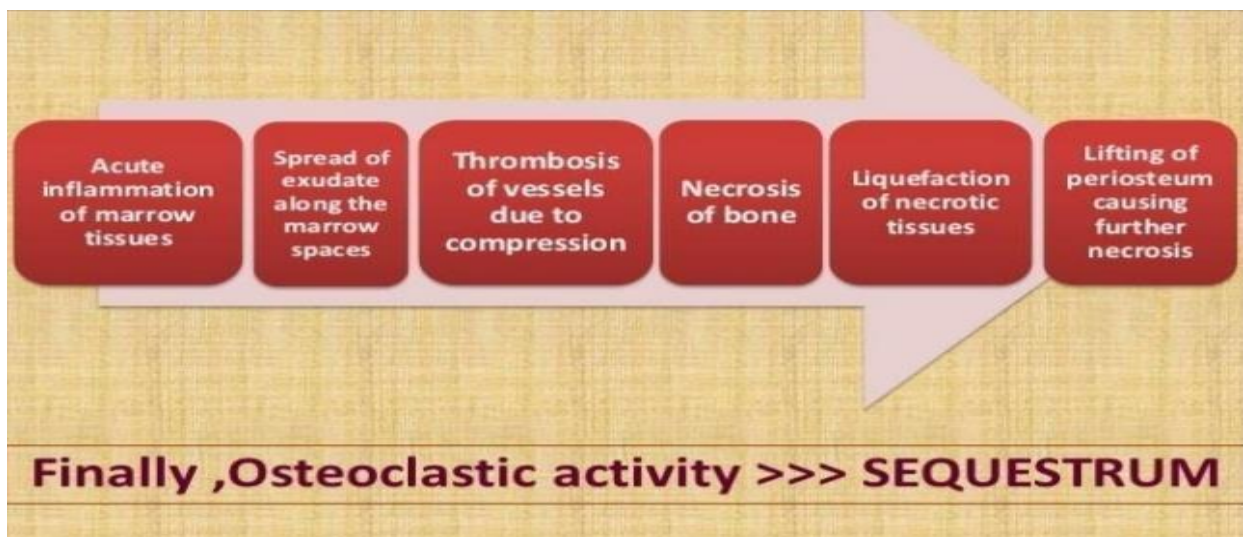
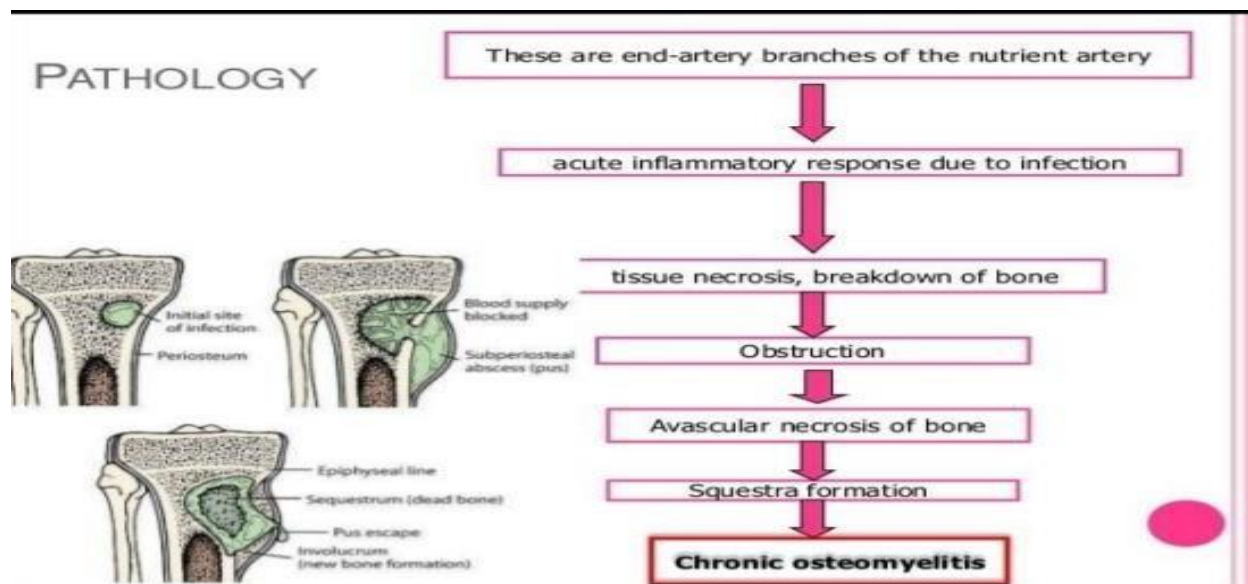
 2. **Extension from a contiguous site**: occurs mainly in adults .
Example : A patient with uncontrolled diabetes has a diabetic foot with severe ulcers , infections and gangrenes in the lower limb → bacteria goes to underlying bone.

 3. **Direct implantation after compound fractures and orthopedic surgeries**
Example :
 - I. A patient with a compound fracture in which the fractured bone is communicating with the overlying skin and becomes exposed to environmental bacteria that might enter and cause secondary osteomyelitis.
 - II. A patient with a closed fracture in which the skin was intact needed a surgery , and during the surgery the bone might have got infected.
- ✚ **Different age groups get infected with different type of organisms .**
- **Neonates** : Haemophilus influenzae & Group B strep.
 - **Sicklers** : Salmonella , patients with sickle cell disease are more likely to develop Salmonella pyogenic osteomyelitis for some reason .
- ✓ **Important Note** : The most common cause of pyogenic osteomyelitis for patients with sickle cell disease is (Staph. aureus) but we should think about Salmonella .

✚ In 50% of acute osteomyelitis cases , no organisms can be isolated (blood culture is negative) → but that doesn't mean that there is no bacteria **Why?** , mainly due to previous improper administration of antibiotic, so improper diagnosis and treatment interferes with your blood culture results (patient that was partially treated) → (False Negative result)

- ✚ Long bones get infected more often .
 - **in adults** : Metaphysis & epiphysis
 - **in children** : Metaphysis Or epiphysis (not both)

Stages of osteomyelitis



✚ **Stages :**

Acute inflammation → Spread of mediators & neutrophils and signaling molecules → Recruitment of WBC → Pus Formation (exudate) → Vascular thrombosis → Necrosis of the bone → Liquefactive necrosis → Lifting of periosteum (late sign of acute Pyogenic osteomyelitis)

✚ *One of the major causes of chronic osteomyelitis is undiagnosed or improperly treated acute osteomyelitis.*

ACUTE	PUS & NEUTROPHILS
CHRONIC	LYMPHOCYTES AND PLASMA CELLS And Macrophages

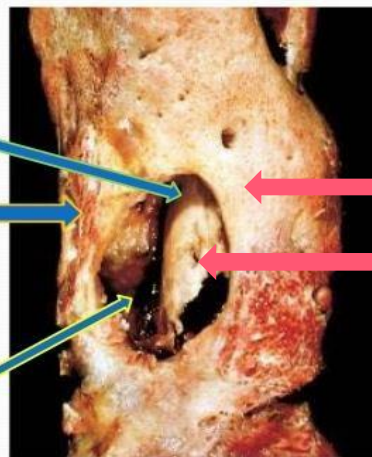
Important terms regarding to Osteomyelitis

1. **Sequestrum** : is the necrotic (dead) bone that is embedded in the pus / infected granulation tissue .
2. **Involucrum**: is the new bone laid down by the periosteum that surrounds the sequestra . (Involucrum: active bone forming region) / (the area of the active bone that surrounds the dead bone).
3. **Cloaca** : is the opening in the involucrum through which Pus & sequestra make their way out .

- **Sequestrum** is the necrotic bone that is embedded in the pus/infected granulation tissue.

- **Involucrum** is the new bone laid down by the periosteum that surrounds the sequestra.

- **Cloaca** is the opening in the involucrum through which pus & sequestra make their way out.



Reactive (viable) bone

Dead bone

Osteomyelitis clinically

- *Manifestations of Hematogenous Osteomyelitis :*

Fever , malaise (loss of appetite) , chills , leukocytosis (increased WBC count) , Throbbing pain locally (helpful for differential diagnosis) and it is a characteristic of presence of pus .

- *In infants the presentation is subtle , with only unexpected fever. In adults it appears as a local pain .*

- *Diagnosis :*

- I. *You should have a high index of suspicion*

- II. *X-ray is done , though , X-ray maybe normal in early phases → however we shouldn't wait till we see the X-ray lytic changes*

Important note : *normal X-ray does not rule out the presence of osteomyelitis , and actually , if we see changes in the X-ray scan due to pyogenic osteomyelitis , that means the patient is in a late phase of the disease.*

Biopsy and bone cultures are required to identify the pathogen in most instances.

- **Treatment :** *Admission , IV antibiotics and surgical drainage of pus.*

Note : *Proper IV antibiotics for Staph. aureus are given to patients in 80-90% of cases , unless the patient suffers from UTIs or is a drug abuser , then you should think of more broad spectrum antibiotics.*

Chronic osteomyelitis

- *Chronic Osteomyelitis is a very bad debilitating disease.*
- *5-25% of acute osteomyelitis persists as chronic osteomyelitis*
- *It is very rare to have patient with a chronic OM without them going first through the acute phase, however certain infections can start as chronic infections without the acute phase, for example: tb (insidious).*

Causes of Chronic Osteomyelitis

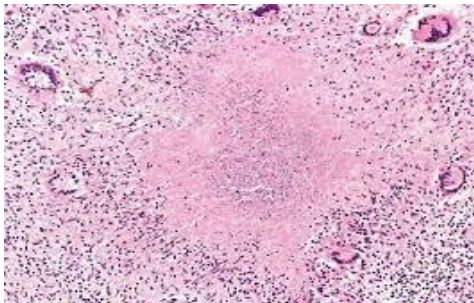
- *Delay in diagnosis*
- *Extensive necrosis (unlucky patients will have huge amount of necrotic bone in acute osteomyelitis which is very hard to clear with antibiotics due to the presence of an extremely virulent organism)*
- *Inadequate therapy: Inappropriate antibiotic or incomplete treatment with an antibiotic*
- *Weakened Host Immunity : the patient is taking immunosuppressive drugs or steroids*

COMPLICATIONS OF CHRONIC OSTEOMYELITIS:

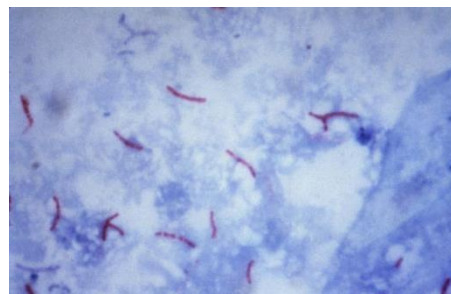
- *Pathologic fractures (abnormal bone)*
- *Secondary amyloidosis : deposition of a protein called amyloid ; amyloidosis is associated with chronic diseases including chronic osteomyelitis.*
- *Endocarditis : a rare condition that involves inflammation of the heart lining , it can be lethal*
- *Sepsis : the bacteria and bacterial toxins in the blood stream.*
- *Squamous cell carcinoma of draining sinus : the draining sinus around the skin can cause Squamous cell carcinoma and it is very rare.*
- *Sarcoma of the bone : similar to paget disease of bone.*

Mycobacterial Osteomyelitis

- *Caused by mycobacterium tuberculosis.*
- *It is a chronic type of inflammation*
- *Used to be a disease of developing countries.*
- *Now: there are more cases in developed countries like the USA due to immigration, but the main reason is immunocompromised patients.*
- *1-3% of patients with pulmonary or extrapulmonary TB can have bone involvement*
- *Hematogenous (spreads through the blood) or direct spread*
 - Examples :**
 - I. *TB in the lung can spread to the ribs or the humerus through the blood.*
 - II. *TB in the skin (diabetic foot) , the bacteria goes to the underlying bone.*
- *Clinically: it is very hard to diagnose maybe subtle and chronic course ,so you should have an index of suspicion.*
- *Pathology: necrotizing (caseating) granulomas*



H&E stain shows granuloma with central necrosis (caseating)



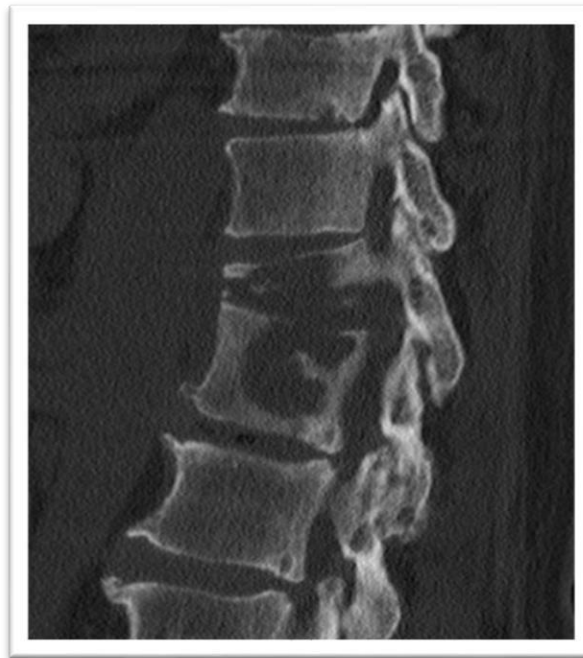Acid fast bacilli stain showing red snappers (Mycobacterium)

Ziehl-Neelsen stain

TB SPNDYLITIS (POTT DISEASE)

- *Pott disease: is a disease caused by TB infecting the vertebral body (destructive spine TB)*
- *Can be referred to as chronic osteomyelitis of the vertebral body*
- *After taking a biopsy and staining it with H&E , we can see necrotizing granuloma.*
- *Patients start to get better like magic after starting the regimen of anti TB drugs*
- *Difficult to treat*
- *May lead to pathologic fractures (compression fractures) that may compress the nerves leading to neurologic deficit, scoliosis, kyphosis*

*****Note : doctor mousa said he will bring a question 100% in the exam on POTT DISEASE.*****



Well done!