# Diseases of the esophagus 1

Manar Hajeer, MD, FRCPath

University of Jordan, School of medicine

- A hollow, highly distensible muscular tube
- Extends from the epiglottis to the GEJ, located just above the diaphragm

# Diseases that affect the esophagus

- 1. Obstruction: mechanical or functional.
- 2. vascular diseases: varices.
- 3. Inflammation: esophagitis.
- 4. Tumours.

# Mechanical Obstruction

- Congenital or acquired.

- Examples:
- Atresia
- Fistulas
- Duplications
- Agenesis (v rare)
- Stenosis.

# Atresia

- Thin, noncanalized cord replaces a segment of esophagus.
- Most common location: at or near the tracheal bifurcation
- +- fistula (upper or lower esophageal pouches to a bronchus or trachea).

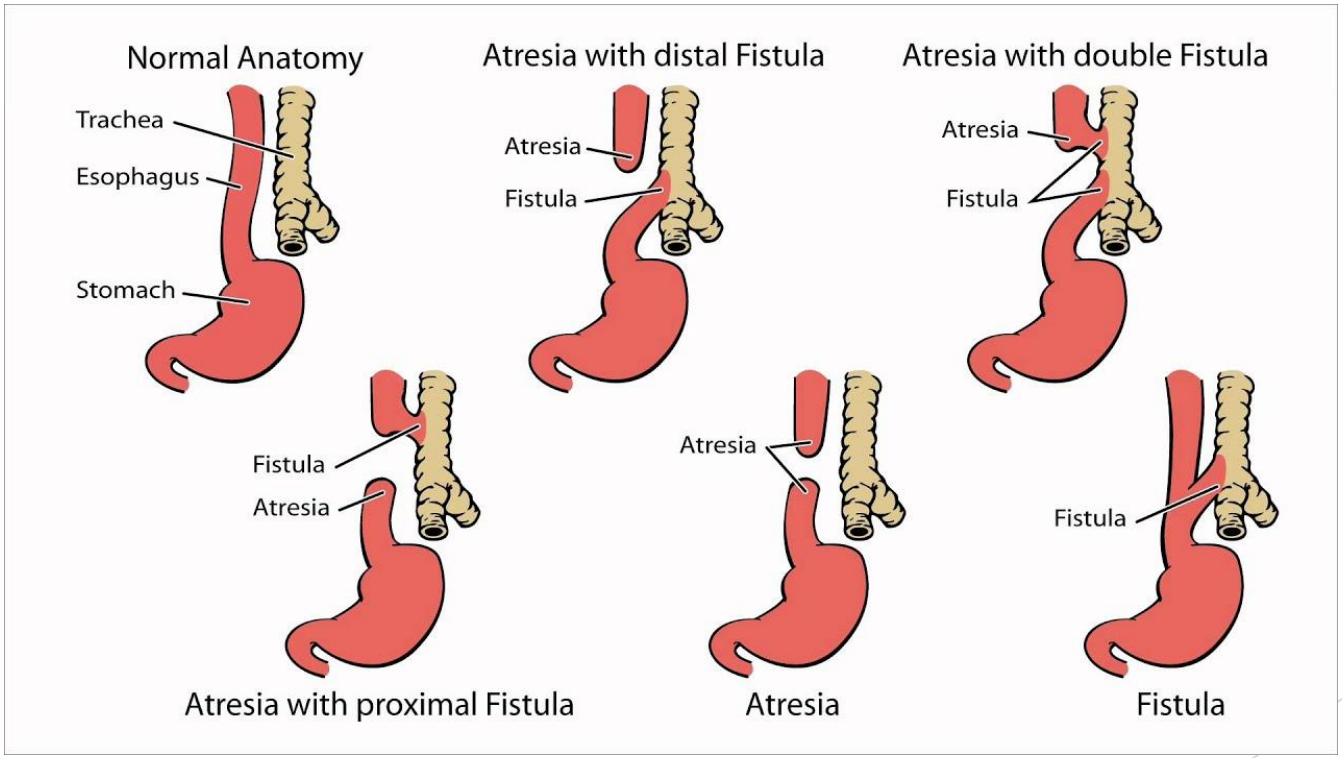
Normal Anatomy
Trachea
Esophagus
Stomach
Atresia with distal Fistula
Atresia
Fistula
Atresia with double Fistula
Atresia
Fistula
Fistula
Atresia
Atresia with proximal Fistula
Atresia
Atresia
Fistula
Fistula

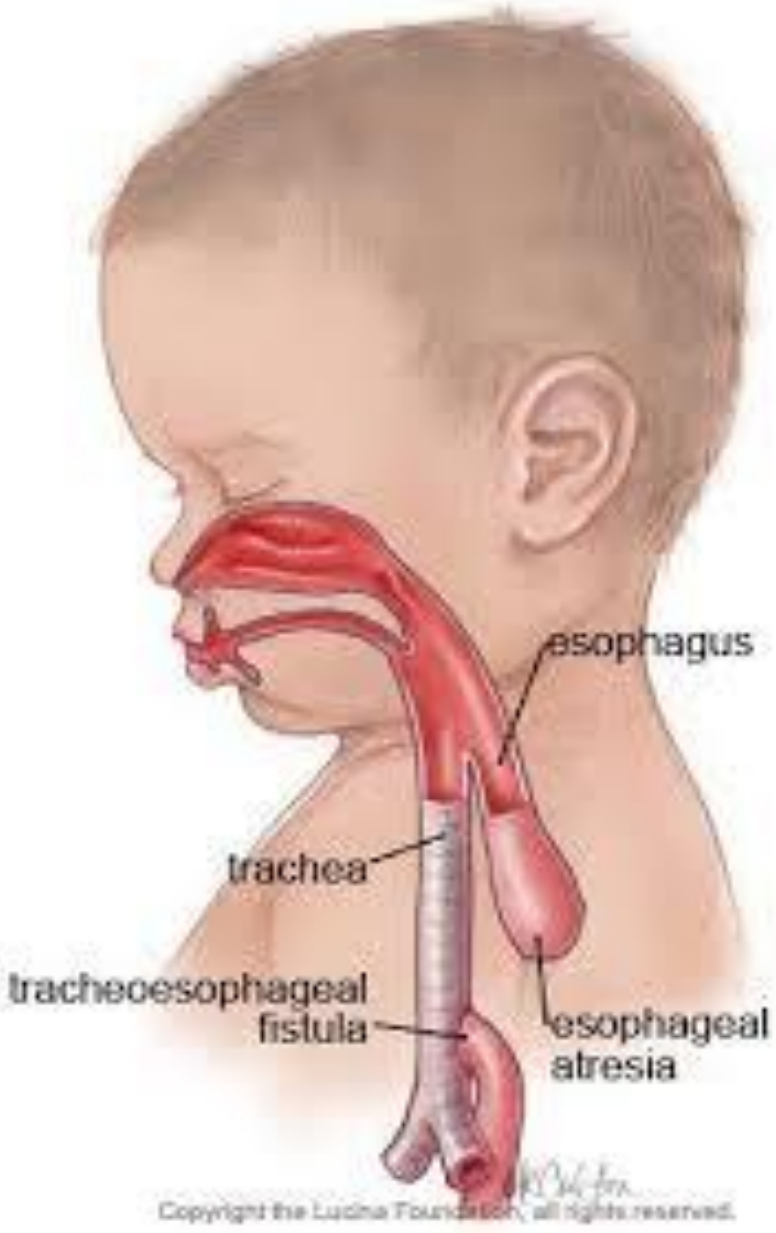
esophagus
trachea
tracheoesophageal
fistula
esophageal
atresia
Copyright the Lucina Foundation, all rights reserved.

# Clinical presentation:

- Shortly after birth: regurgitation during feeding
- Needs prompt surgical correction (rejoin).

- Complications if w/ fistula:
- Aspiration
- Suffocation
- Pneumonia
- Severe fluid and electrolyte imbalances.

# Esophageal stenosis

- Acquired>>>Congenital.
- Fibrous thickening of the submucosa & atrophy of the muscularis propria.
- Due to inflammation and scarring

- Causes:
- Chronic GERD.
- Irradiation
- Ingestion of caustic agents

# Clinical presentation

- Progressive dysphagia
- Difficulty eating solids that progresses to problems with liquids.

# Functional Obstruction

- Efficient delivery of food and fluids to the stomach requires coordinated waves of peristaltic contractions.
- Esophageal dysmotility: discoordinated peristalsis or spasm of the muscularis.
- Achalasia: the most important cause.

# Achalasia

- Triad:
- Incomplete LES relaxation
- Increased LES tone
- Esophageal  aperistalsis.

- Primary >>>secondary.

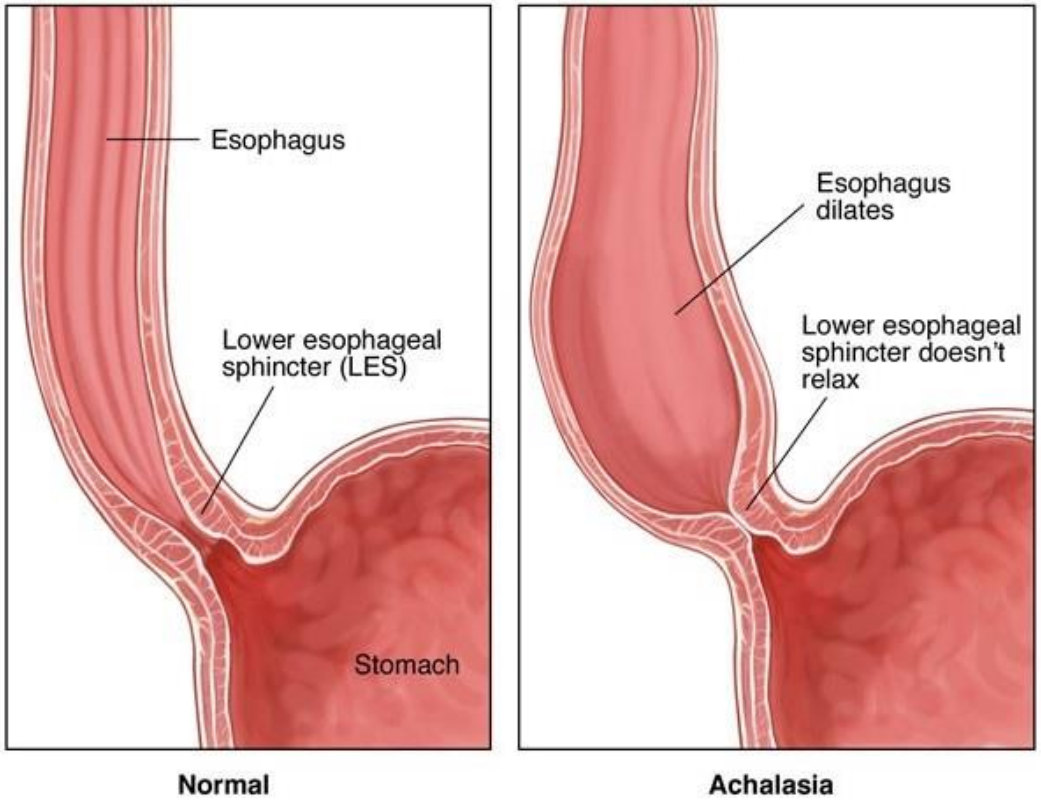


Normal

Achalasia

gastro.com.cy

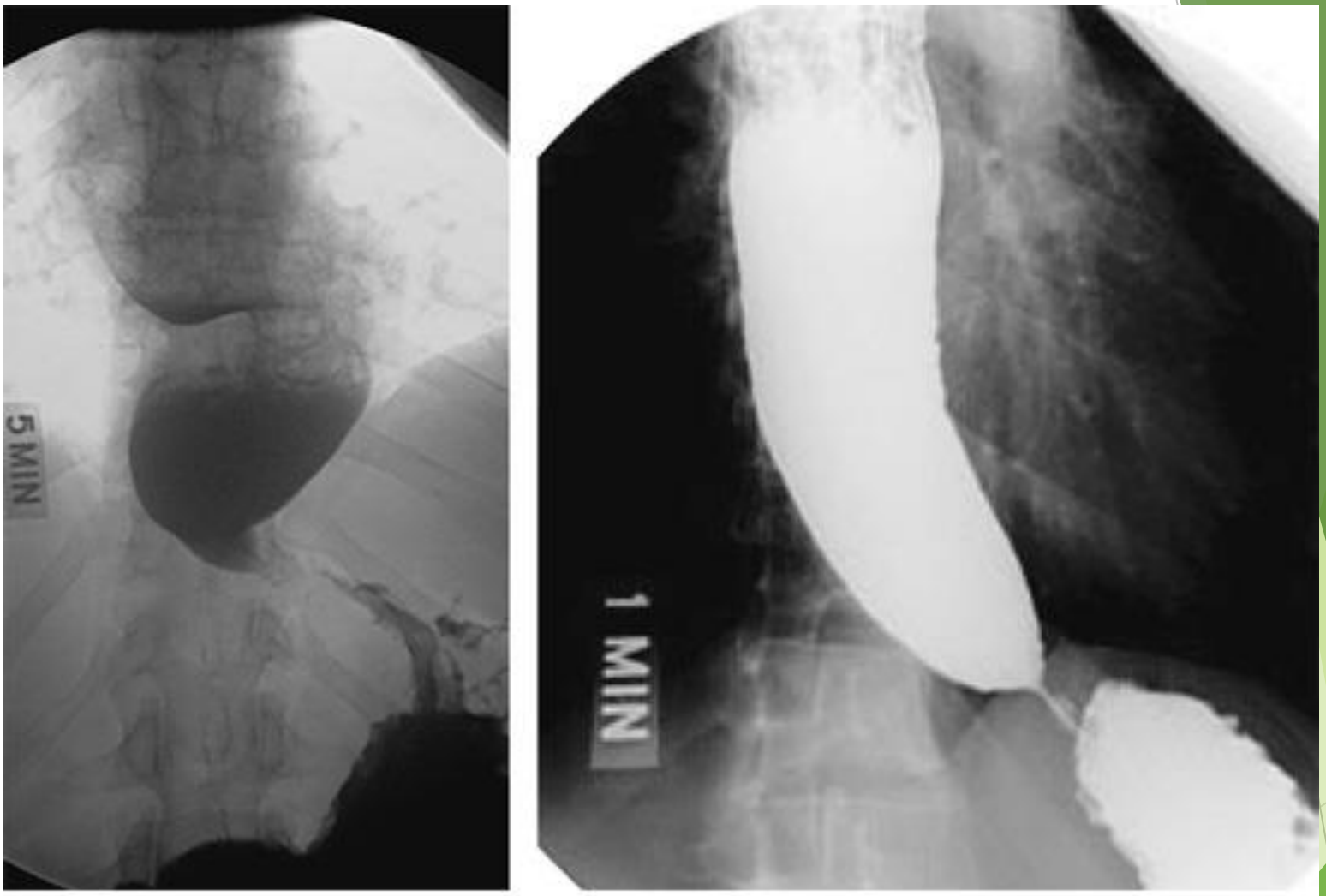


Source: Longo DL, Fauci AS, Kasper DL, Hauser SL, Jameson JL, Loscalzo J: *Harrison's Principles of Internal Medicine, 18th Edition*: www.accessmedicine.com

- Pneumatic balloon dilatation of the LES

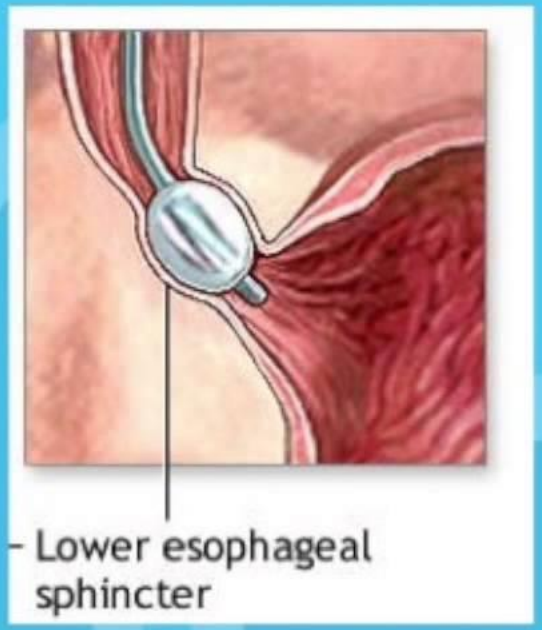


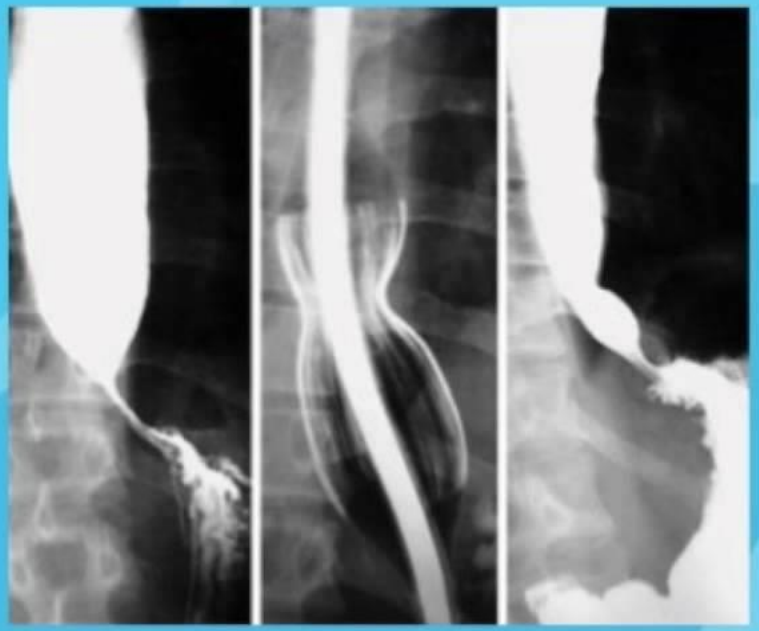

# Primary achalasia

- Failure of distal esophageal inhibitory neurons.
- Idiopathic
- Most common

# Secondary achalasia

- Degenerative changes in neural innervation

- Intrinsic
- Vagus nerve
- Dorsal motor nucleus of vagus

- **Chagas disease**, Trypanosoma cruzi infection>>destruction of the myenteric plexus>> failure of LES relaxation>> esophageal dilatation.

# Clinical presentation

- Difficulty in swallowing
- Regurgitation
- Sometimes chest pain.

# Vascular diseases: Esophageal Varices

- Tortuous dilated veins within the submucosa of the distal esophagus and proximal stomach.
- Diagnosis by: endoscopy or angiography.

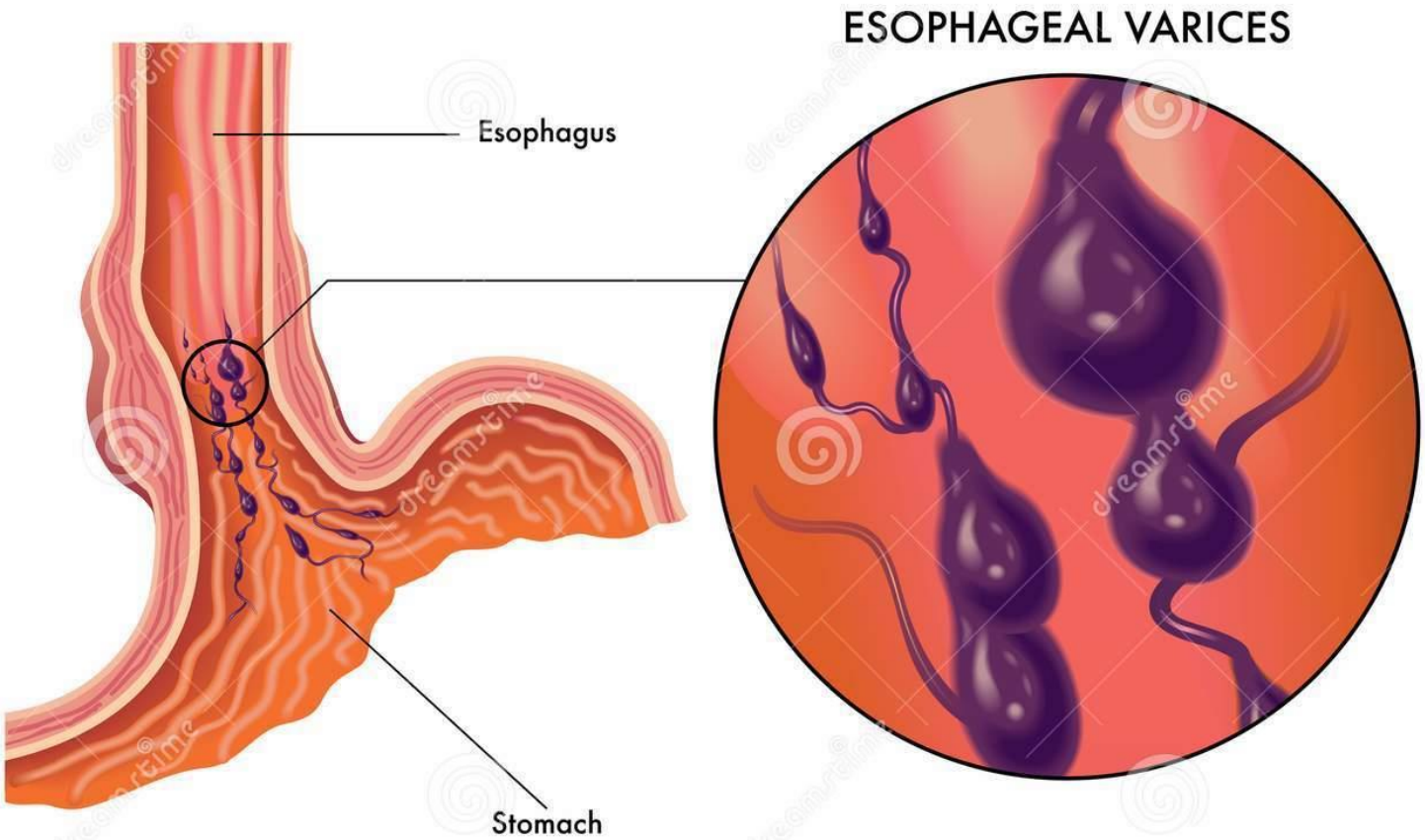

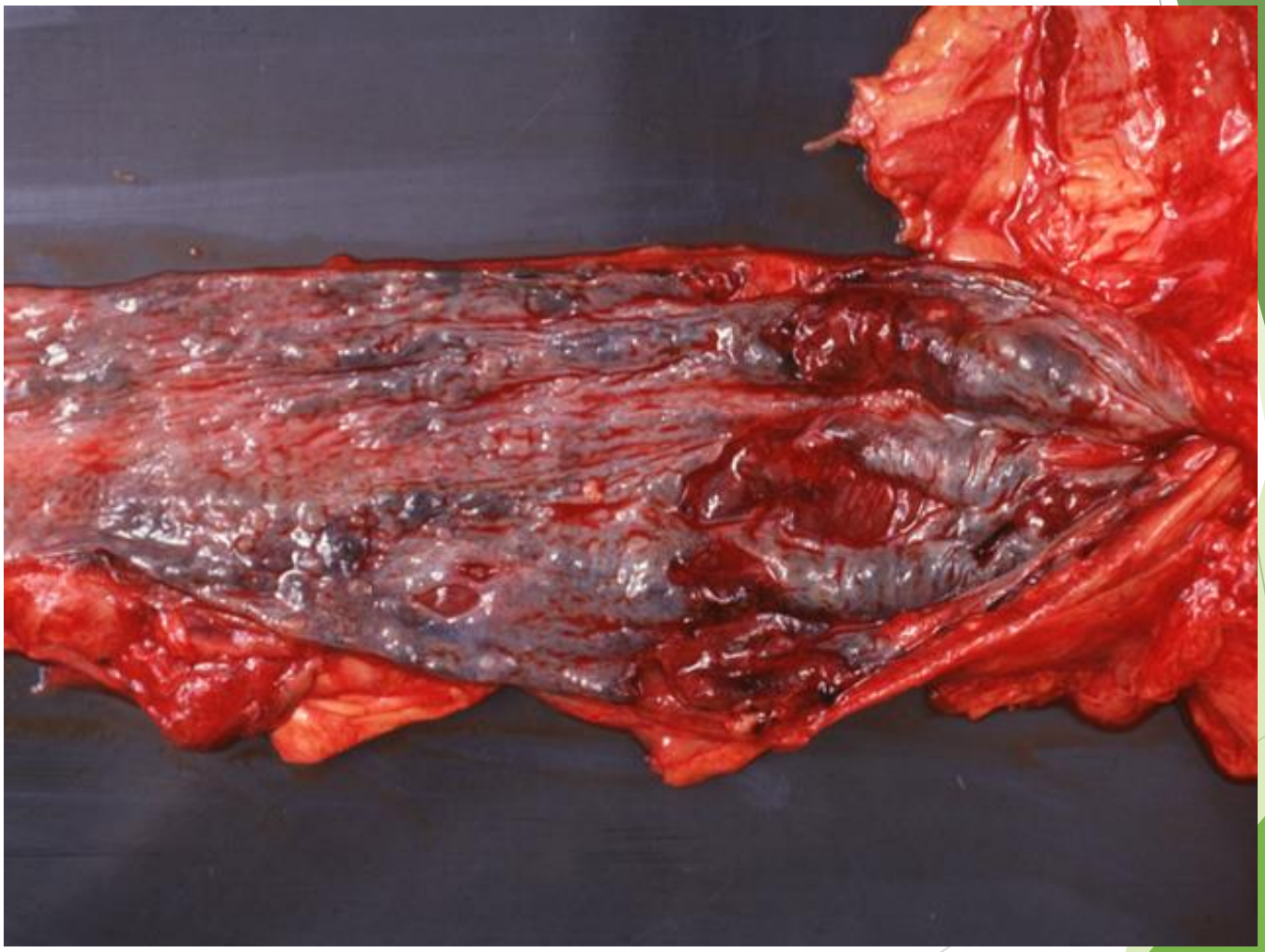

Medpics - UCSD School of Medicine

# Dilated varices beneath intact squamous mucosa

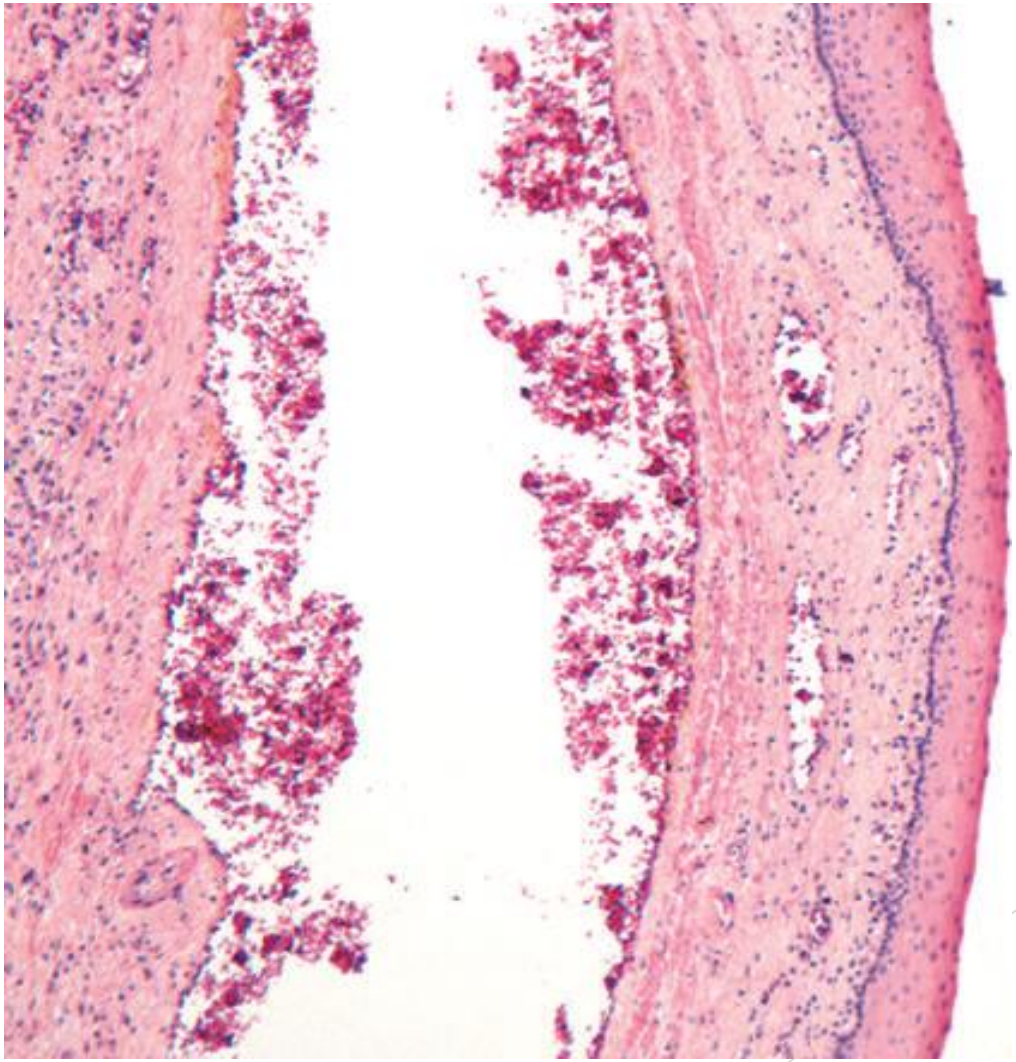

Robbins Basic Pathology 10th edition

# Pathogenesis:

- **Portal circulation**: blood from GIT>>portal vein>>liver (detoxification)>>inferior vena cava.
- Diseases that impede portal blood flow >> portal hypertension >>esophageal varices.
- Distal esophagus : site of Porto-systemic anastomosis.
- **Portal hypertension**>>collateral channels in distal esophagus>>shunt of blood from portal to systemic circulation>>dilated collaterals in distal esophagus>>varices

# Portal system

Usual circulation

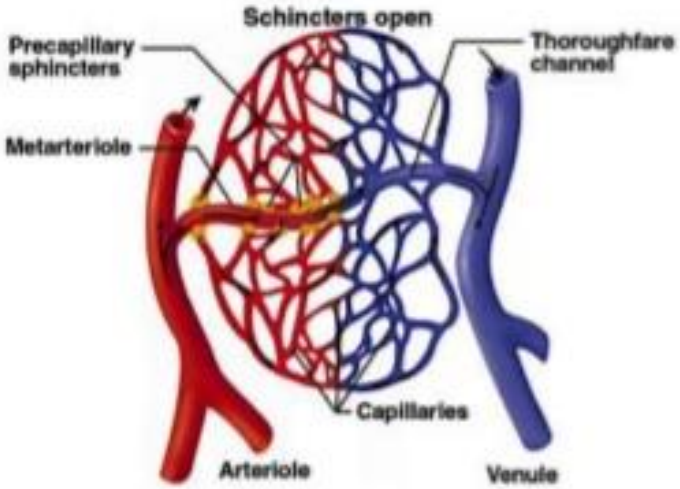


Portal circulation

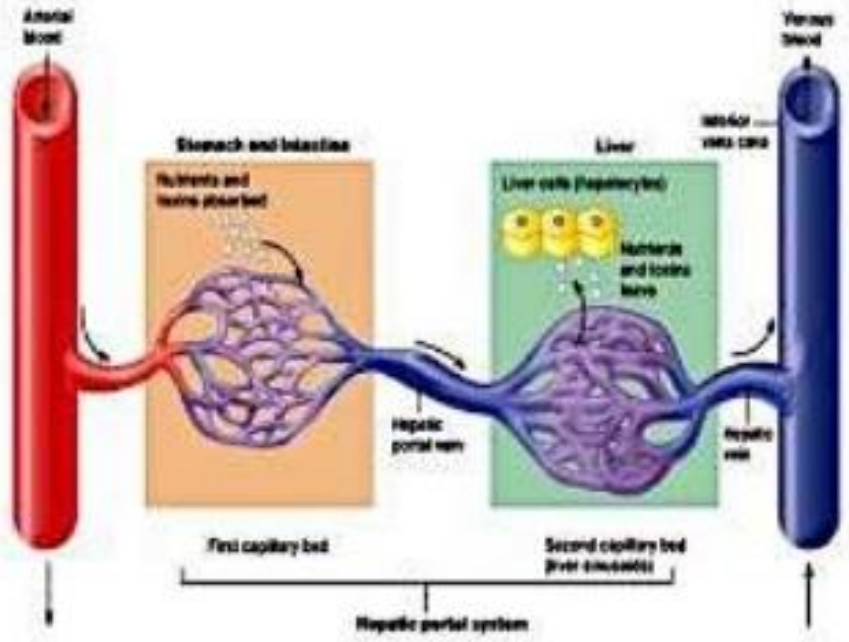


https://www.slideshare.net/rongon28us/hepatic-portal-vein-and-portocaval-anatomosis

# SITES OF PORTACAVAL ANASTOMOSIS

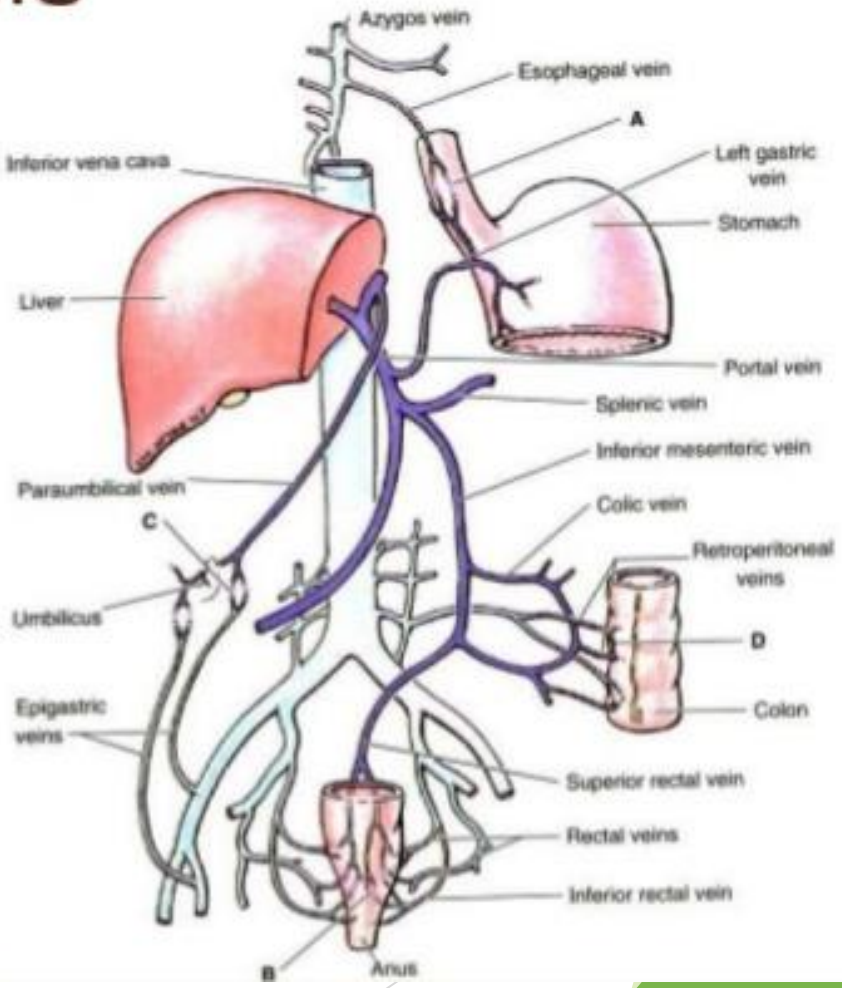


**Five sites of portal/systemic circulation** :

1. Lower third of the Esophagu
2. Paraumbilical Area
3. Upper end of Anal canal
4. Retroperitonial
5. Bare area of liver

https://www.slideshare.net/charslan626/hepatic-anastomosis

# Causes of portal hypertension

- Cirrhosis is most common

  Alcoholic liver disease.
- Hepatic schistosomiasis 2nd most common worldwide.

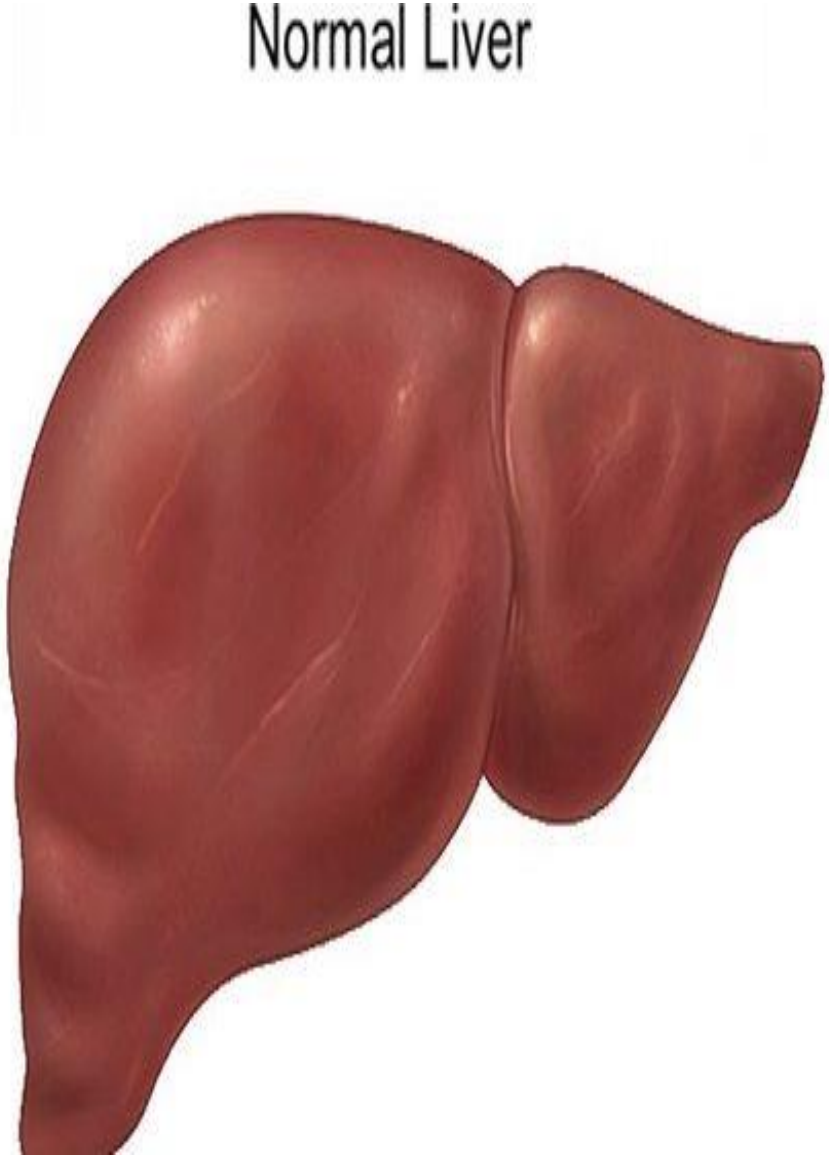



http://www.researchintoasthma.com/7-random-facts-about-liver-cirrhosis.html

# Clinical Features

- Often asymptomatic.
- Rupture leads to massive hematemesis and death.
- 50% of patients die from the first bleed despite interventions.
- Death due to: hemorrhage, hepatic come, and hypovolemic shock
- Rebleeding in 20%.

# ESOPHAGITIS

- Esophageal Lacerations.
- Mucosal Injury
- Infections
- Reflux Esophagitis
- Eosinophilic Esophagitis

# Esophageal Lacerations

- Mallory weiss tears are most common
- Due to : severe retching or prolonged vomiting
- Present with hematemesis.
- Failure of gastroesophageal musculature to relax prior to antiperistaltic contraction associated w/ vomiting>>stretching>>>tear.

- Linear lacerations
- longitudinally oriented
- Cross the GEJ.
- Superficial
- Heal quickly , no surgical intervention

# Chemical Esophagitis

- Damage to esophageal mucosa by irritants
- Alcohol,
- Corrosive acids or alkalis
- Excessively hot fluids
- Heavy smoking
- Medicinal pills (doxycycline and bisphosphonates)
- Iatragenic (chemotx, radiotx , GVHD)

# Clinical symptoms & morphology

- Ulceration  and acute inflammation.
- Only self-limited pain, odynophagia (pain with swallowing).
- Hemorrhage, stricture, or perforation in severe cases

# Infectious esophagitis

- Mostly in debilitated or immunosuppressed.

- Viral (HSV, CMV)
- Fungal (candida >>> mucormycosis & aspergillosis)
- Bacterial: 10%.

- Candidiasis :

- Adherent.
- Gray-white pseudomembranes
- Composed of matted fungal hyphae and inflammatory cells

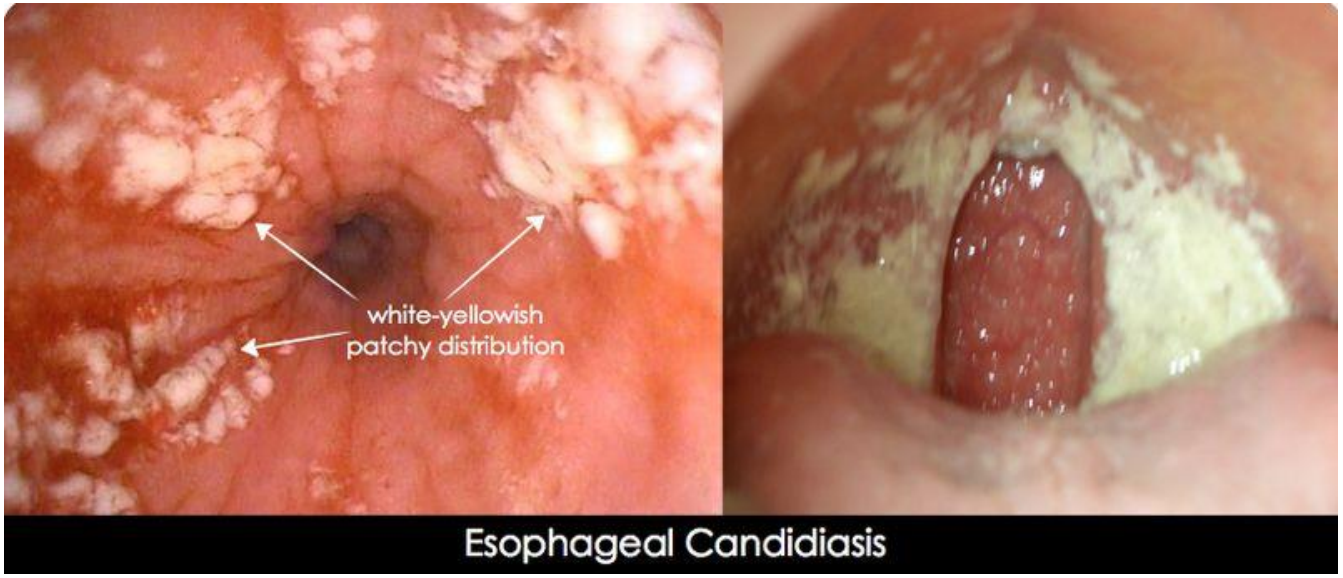


https://www.pinterest.com/pin/374291419013418659/

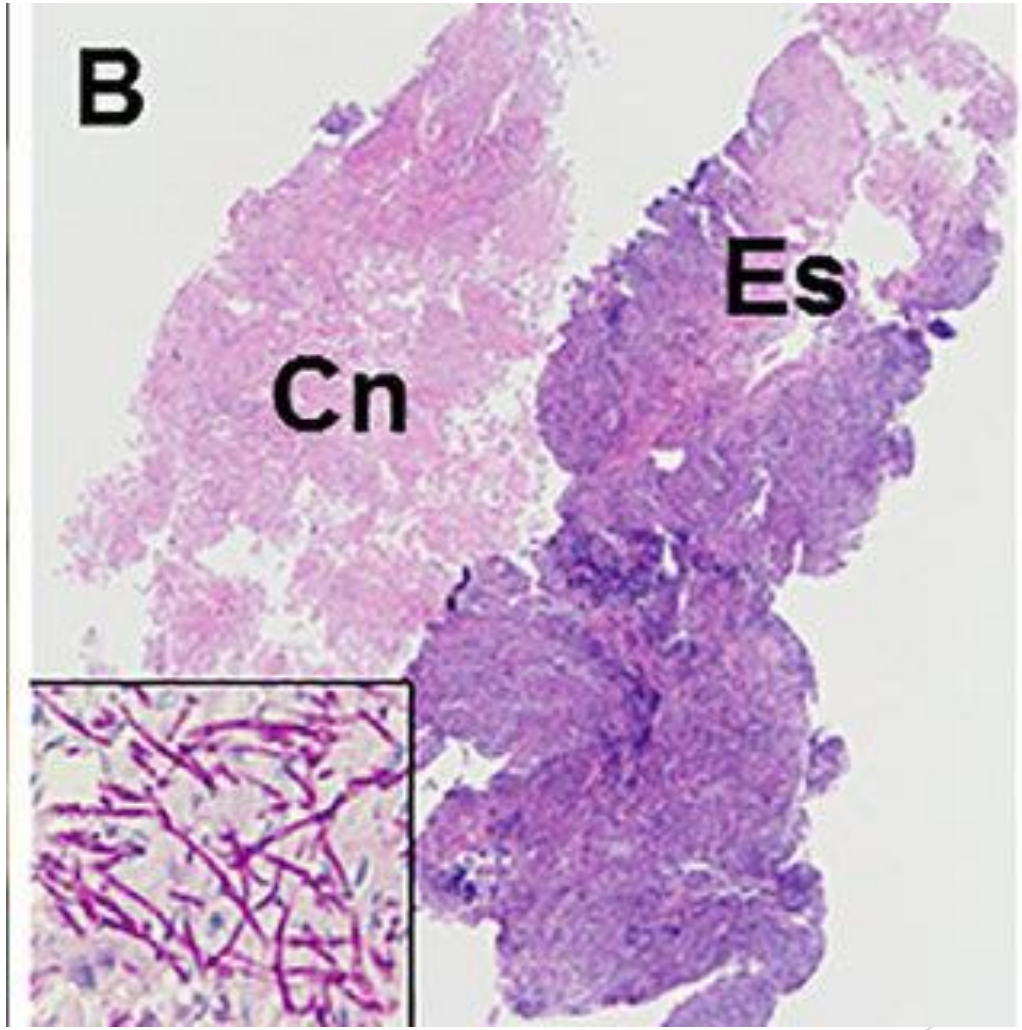


www.researchgate.net/publication/285369734_Esophageal_Candidiasis_as_the_Initial_Manifestation_of_Acute_Myeloid_Leukemia

- Herpes viruses
- Punched-out ulcers
- Histopathologic:
- Nuclear viral inclusions
- Degenerating epithelial cells ulcer edge
- Multinucleated epithelial cells.

Semantic Scholar

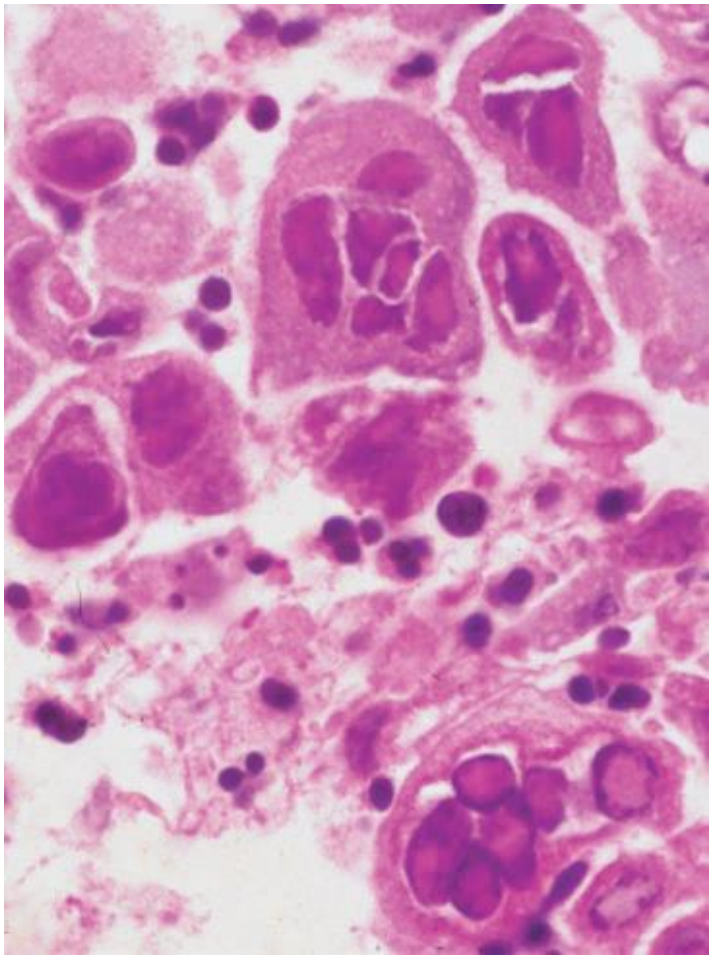

Robbins Basic Pathology 10th edition

- CMV :
- Shallower ulcerations.
- Biopsy: nuclear and cytoplasmic inclusions in capillary endothelium and stromal cells. Megalo. cells

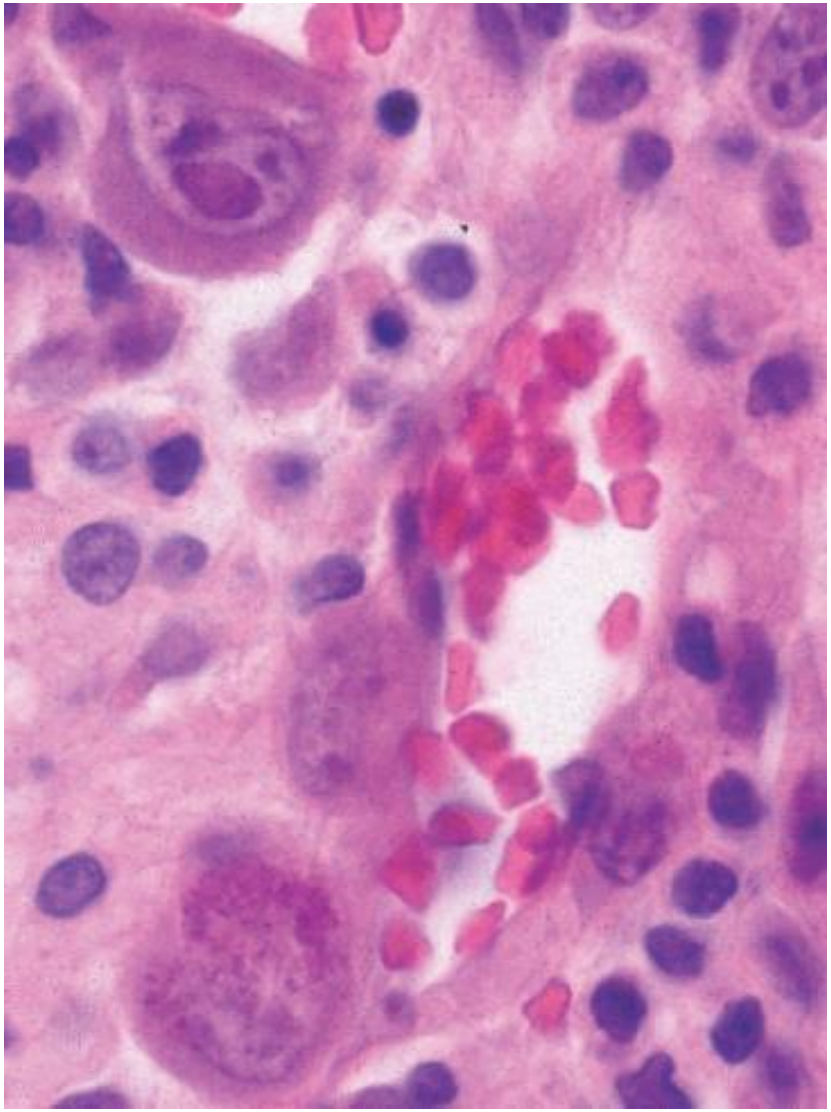

Robbins Basic Pathology 10th edition