

Problem Based Learning 1

Feras Fararjeh MD

13.10.2021

Case 1

- A 19 year old male college student. Presents with history of yellowish discoloration of sclera, exertional fatigue and shortness of breath. Additionally, there is left sided abdominal pain. He has family members with similar symptoms.

Case 1

- Findings:

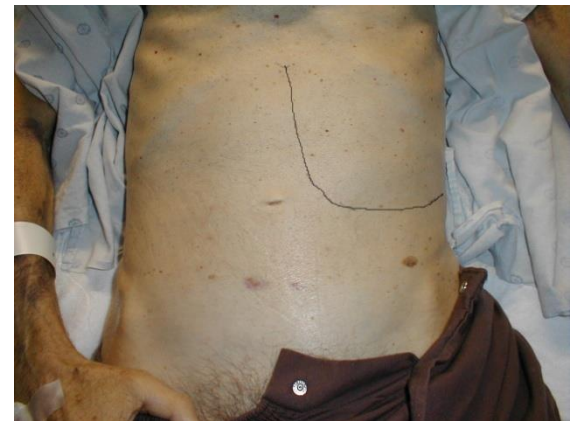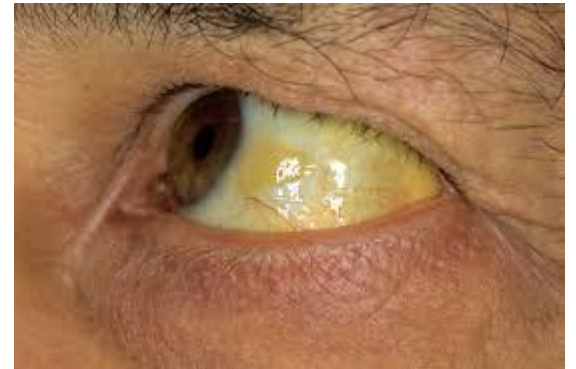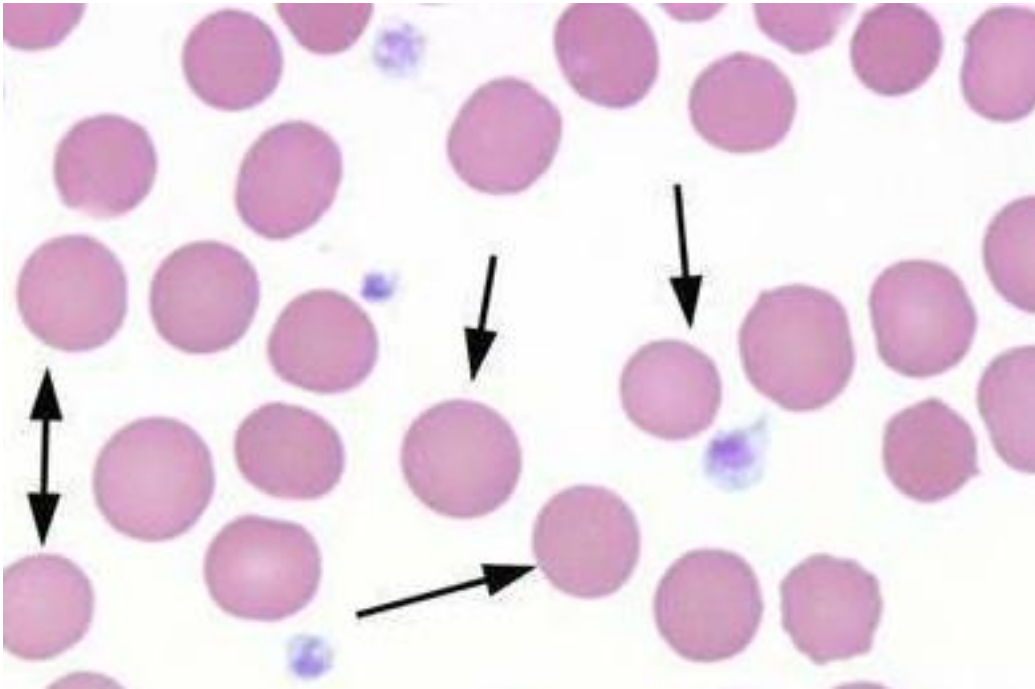
Pallor

Jaundice (yellowish discoloration)

Splenomegaly (enlarge spleen)

Abnormal red cells on blood film

Case 1



Case 2

- A 24 year old male. Presents with new onset yellowish discoloration of sclera with exertional fatigue and shortness of breath. Urine is very dark. Patient was normal before attack. He had fava bean 1 day before onset of symptoms.

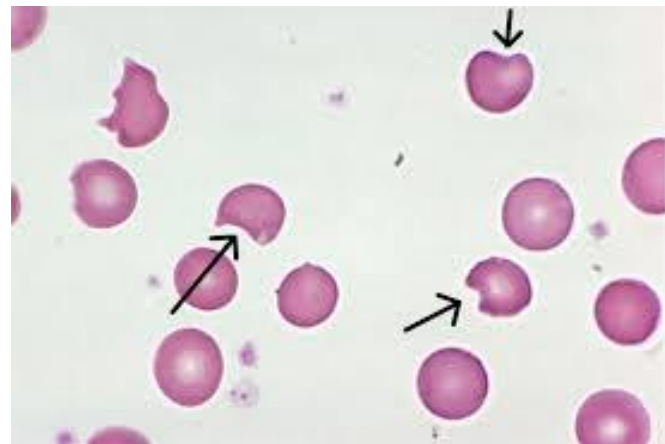Case 2

- Findings:

Pallor

Jaundice (yellowish discoloration)

Abnormal red cells on blood film



Case 3

- A 20 year old female college student presents with acute pain in the back, shoulder and extremities. She reports this is not the first time; attacks are more frequent in cold and stressful conditions.
- On a previous occasion, she was admitted with respiratory symptoms and had her blood exchanged.

Case 3

- Findings:

Pallor

Jaundice

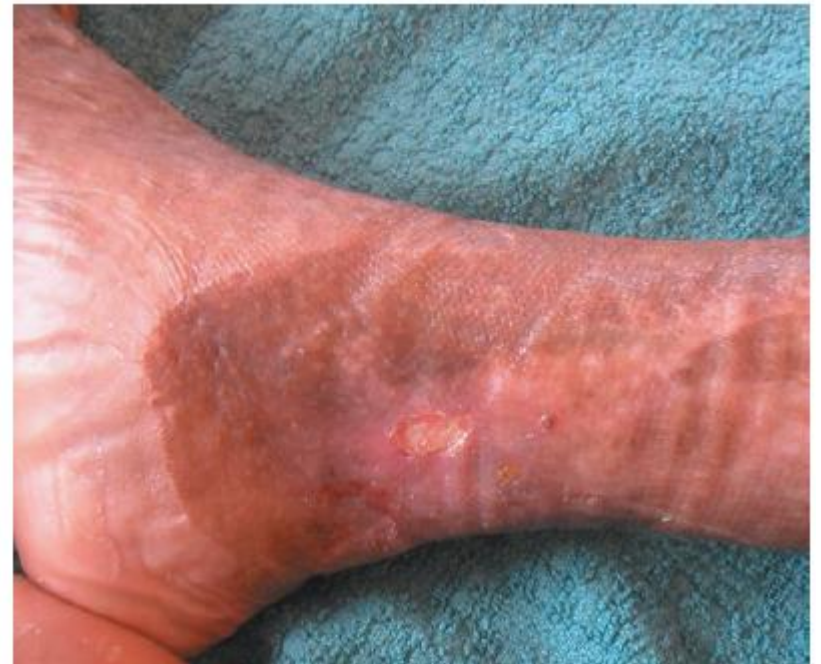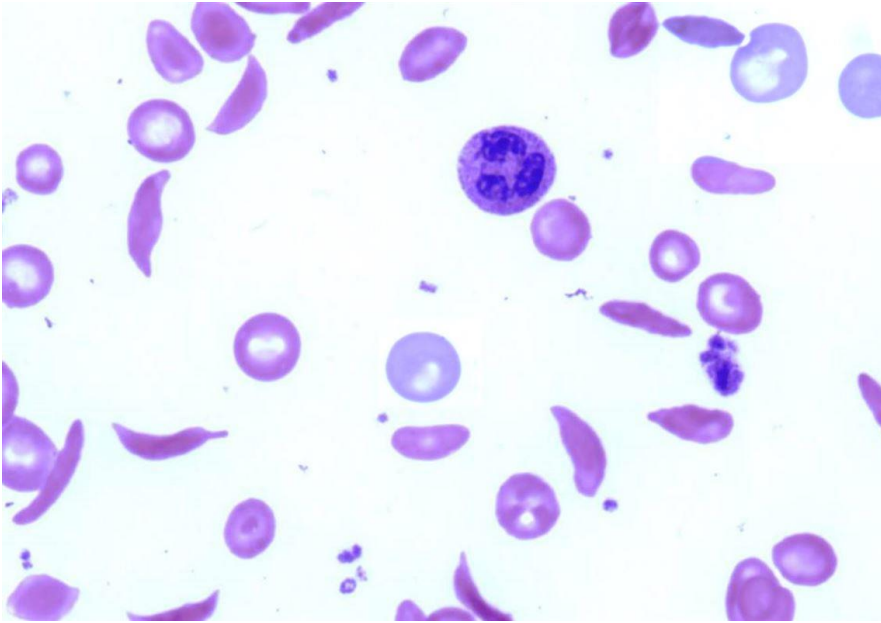
Underweight

Skeletal abnormalities (medullary and epiphyseal infarction, dactylitis, marrow hyperplasia)

Leg ulcers

Abnormal red cells on blood film

Case 3



Case 4

- A 29 year old housewife presents with exertional fatigue, shortness of breath and palpitations. This started few months ago but is progressive. She had 3 complete pregnancies in the last 5 years. Her menstrual blood loss is heavy. She has no bleeding or infective symptoms. Her diet sounds balanced and she has no nausea, vomiting or altered bowel habits.

Case 4

- Findings:

Pallor

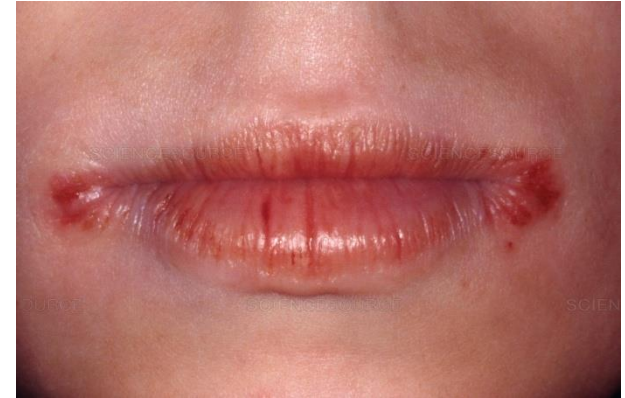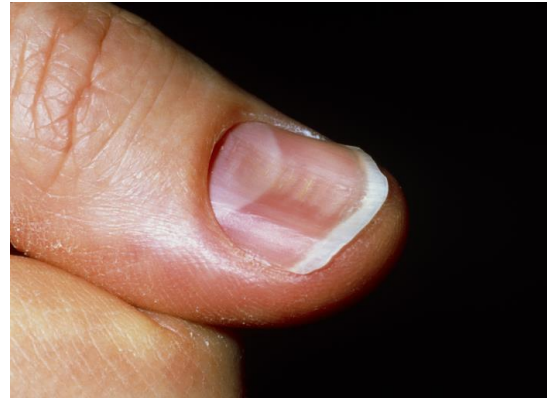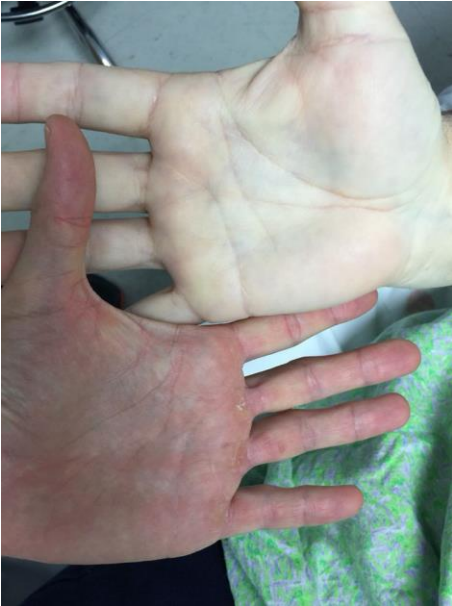Hair loss

Koilonychia

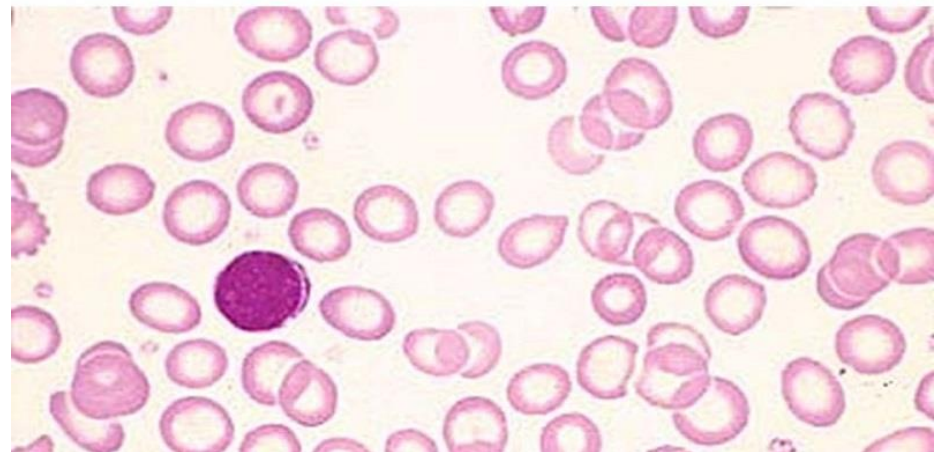
Angular stomatitis

Abnormal red cells on blood film

Case 4



Hypochromic Microcytic Anemia (iron deficiency)

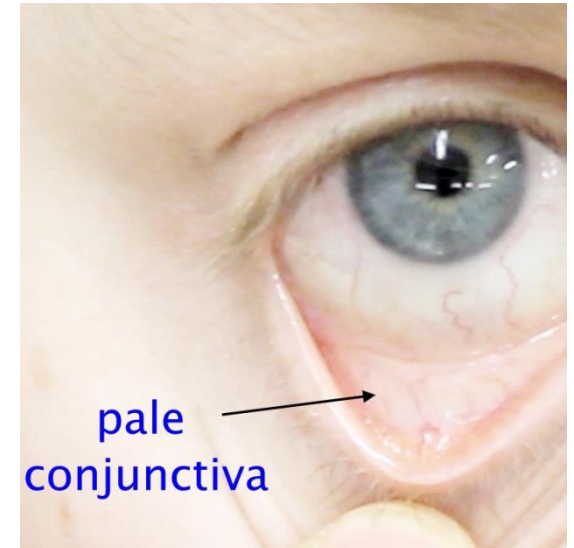
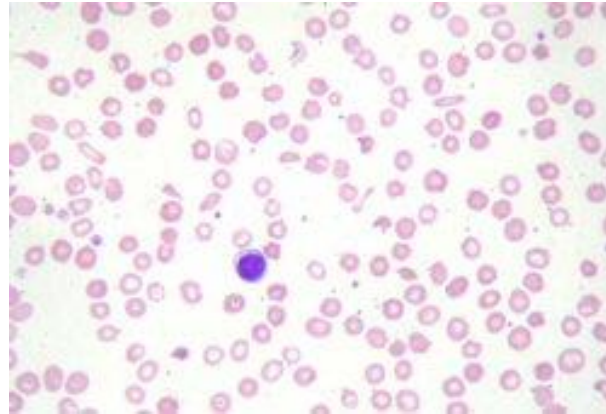


Case 5

- A 62 year old retired engineer. He has new symptoms of exertional fatigue and shortness of breath. This started around 2 months ago. He also noticed a change in his bowel habits recently and thinks he is losing weight.
- He is not vegetarian and his diet sounds balanced.

Case 5

- Findings:
Pallor



What is the next thing to do?

Case 6

- A 42 year old female with history of surgery done 10 years ago for morbid obesity (gastric by pass) presents with exertional fatigue and shortness of breath. She reports some mental sluggishness and inability to walk normally. Her family think she is becoming depressed and more forgetful. She is not attending her scheduled clinic visits and not taking her prescribed medications.

Case 6

- Findings:

Pallor

Mild jaundice

Symmetric paresthesias/numbness

Shuffling gait

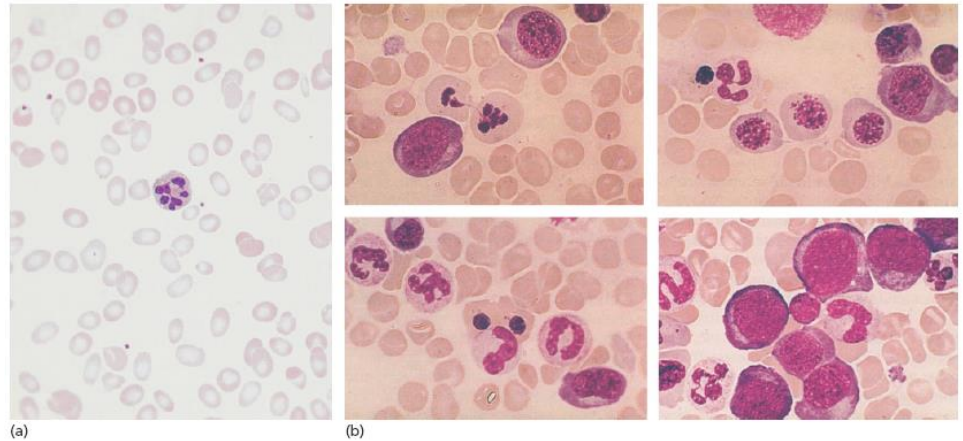


Figure 5.4 Severe megaloblastic anaemia: (a) peripheral blood; (b) bone marrow.

What is the next thing to do?

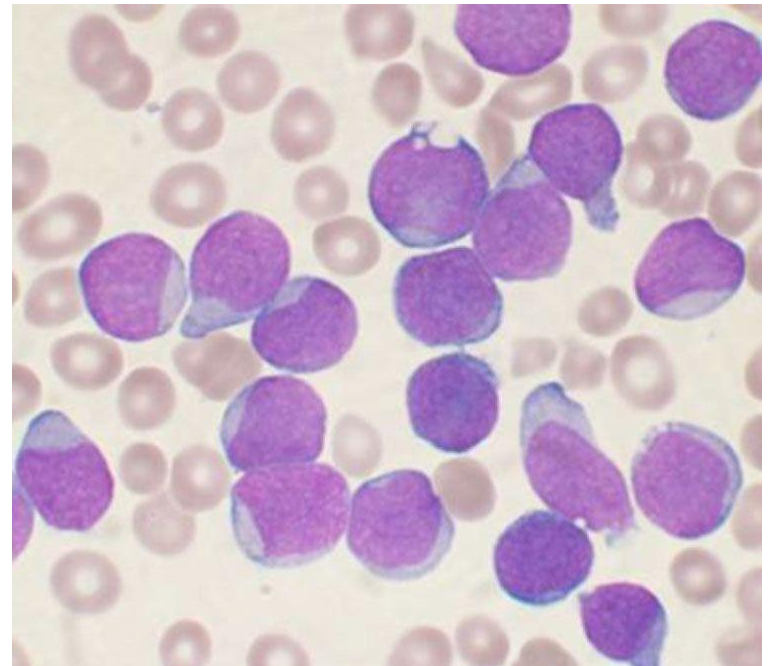
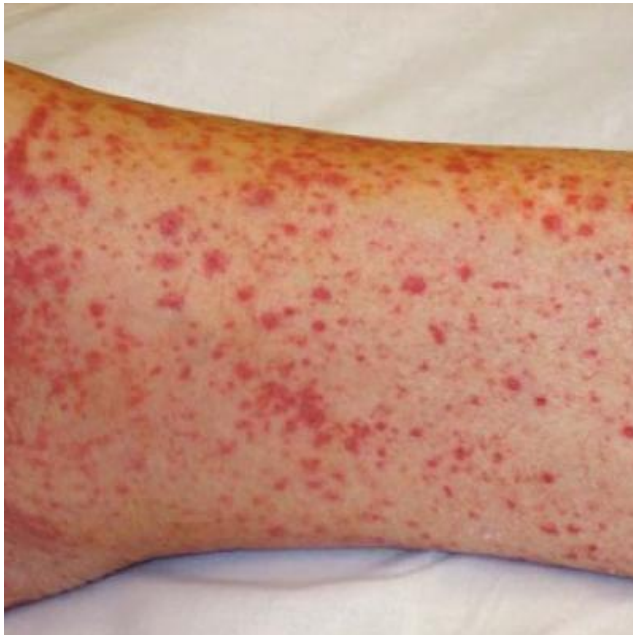Case 7

- A 64 year old lady presents with acute onset of symptoms that started one week ago:
 - Fatigue
 - Palpitations
 - Shortness of breath
 - Fever
 - Cough with sputum
 - Gum bleeding
 - Skin bruising
- No previous episodes and no family history of similar conditions

Case 7

- Findings:
 - Pale
 - Documented fever
 - Skin bleeding (Ecchymosis, petechial rash)
 - Abnormal blood film and bone marrow
 - Bone marrow is hypercellular and replaced by abnormal cells

Case 7



Case 8

A 40 year old gentleman presents with acute onset of symptoms that started one week ago:

- Fatigue
- Palpitations
- Shortness of breath
- Fever
- Gum bleeding
- Skin bruising

No previous episodes and no family history of similar conditions

Case 8

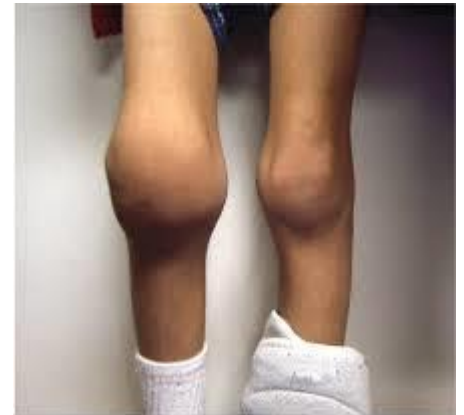- Findings:
 - Pale
 - Documented fever
 - Skin bleeding (Ecchymosis, petechial rash)
 - Blood film showing reduced cell numbers but no abnormal cells.
 - Bone marrow is markedly hypocellular

Case 9

- A 7 year old boy presents with swollen knee of few days duration. This is not the first time it happens. Both knees and ankles are affected but his right knee is affected most. Symptoms start by feeling of hotness in the joint followed by swelling, pain, reduced ability to move and hot skin.
- His mother reports he bled abnormally after circumcision. He has not had any surgical procedures done. His mother thinks that some of her family members had similar symptoms.

Case 9

- Findings:
 - Swollen knee (with effusion) with hotness and reduced movement.



Source: Lichtenan NA, Kopp TI, Salgishin U, Kaushansky K, Prchal JT.
Williams Hematology, 8th Edition | <https://www.accessmedicine.com>
Copyright © The McGraw-Hill Companies, Inc. All rights reserved.

Thank you