ANATOMY OF THE HEART

The Heart

- **The heart, slightly larger than one's loosely clenched fist**

- **It is a double, self-adjusting suction and pressure pump (Moore, clinically oriented Anatomy)**

The heart is a pair of valved muscular pumps combined in a single organ (Gray's Anatomy)

- The general shape of the heart is that ***of a pyramid*** that has ***fallen over*** and ***is resting on one of its sides.***

It has:
AN APEX
A BASE
4 SURFACES & BORDERS

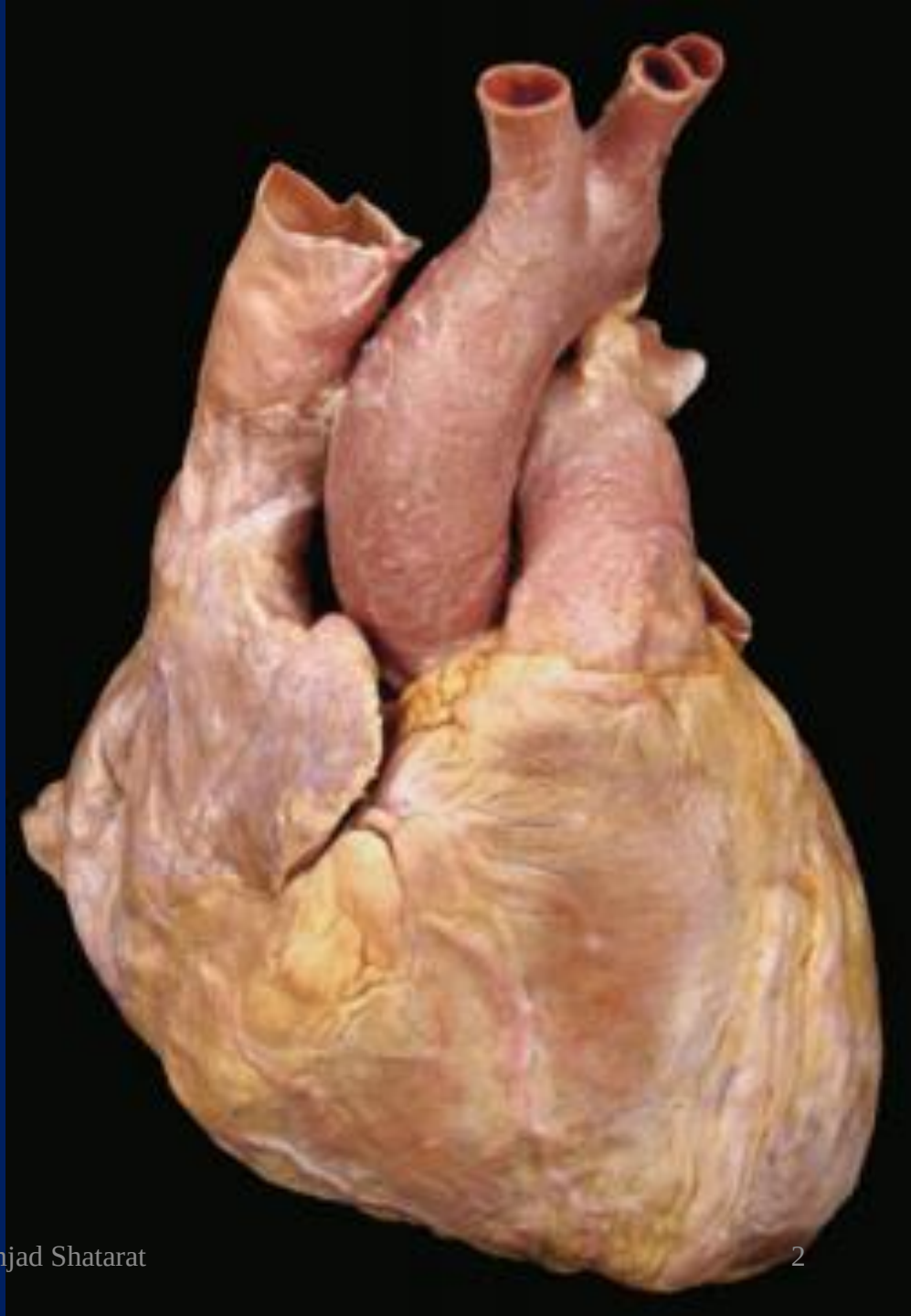

The surfaces of the pyramid consist of:

1-a diaphragmatic (inferior)

2-anterior (sternocostal) surface

3-right pulmonary surface

4-left pulmonary surface

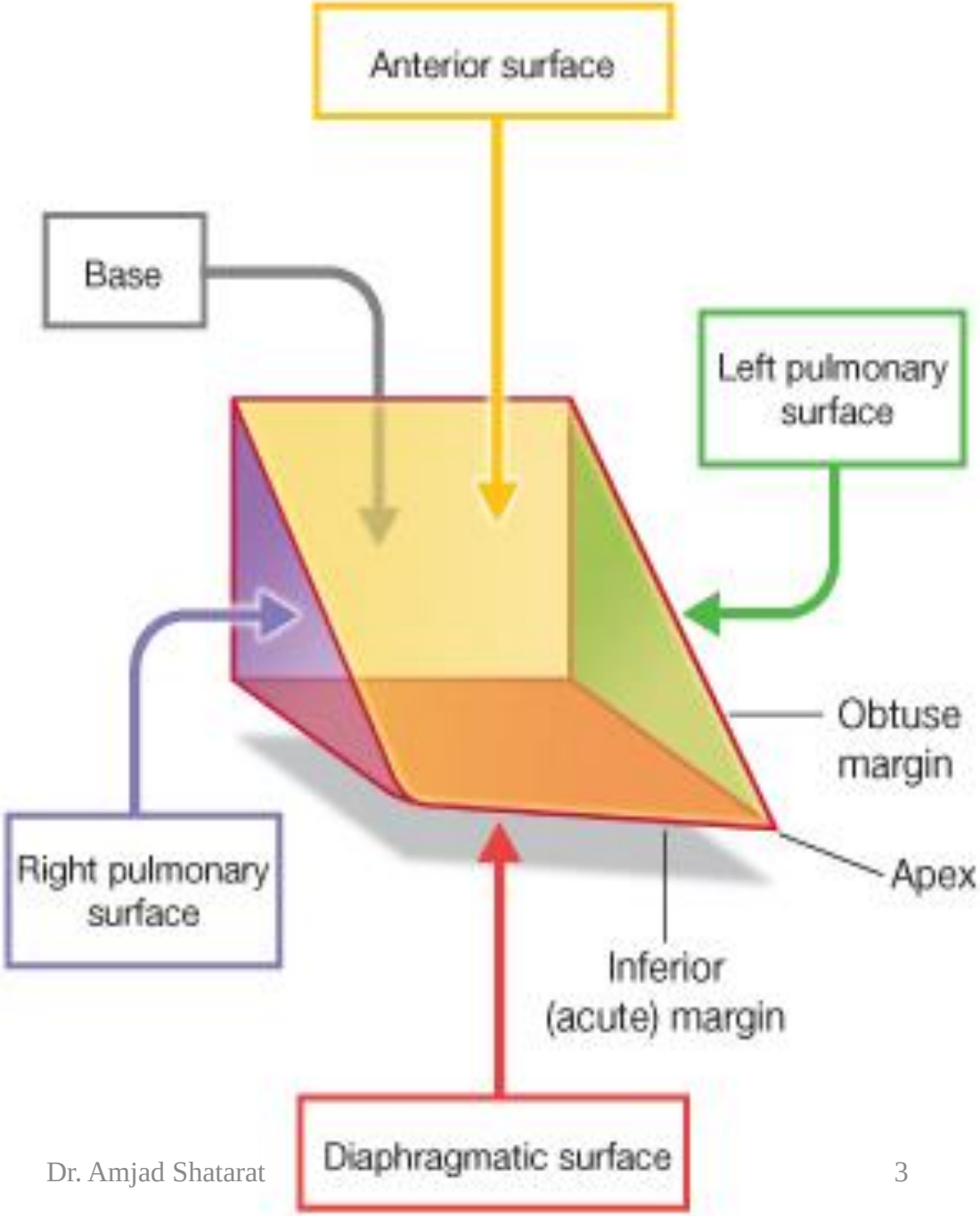

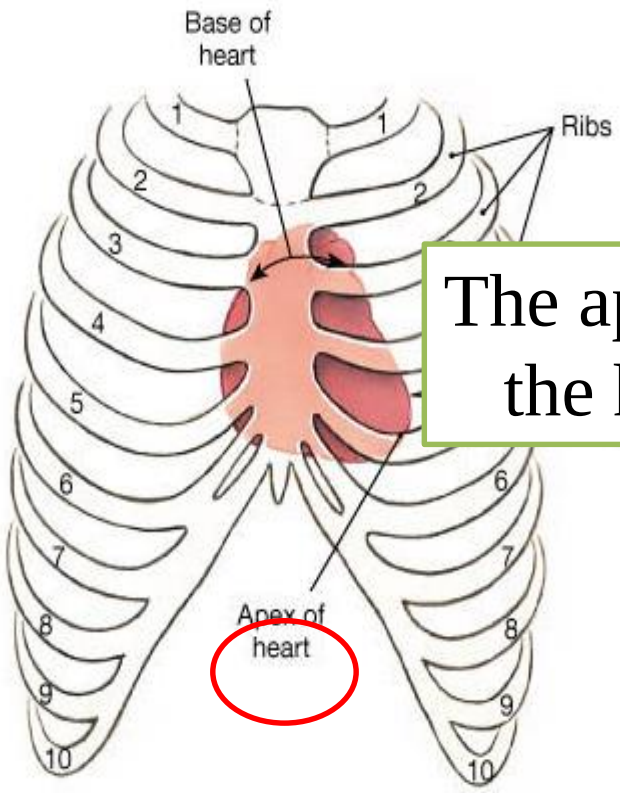

The apex of the heart

- Is formed by the ***inferolateral*** part of ***the left ventricle***

- It is directed downward forward, and to the left
- Lies posterior to **the left 5th intercostal space** usually approximately **9 cm** **(a hand's breadth)** from the median plane

- It is where the sounds of **mitral valve closure** are maximal (apex beat); the apex underlies the site where the heartbeat may be **auscultated** on the thoracic wall

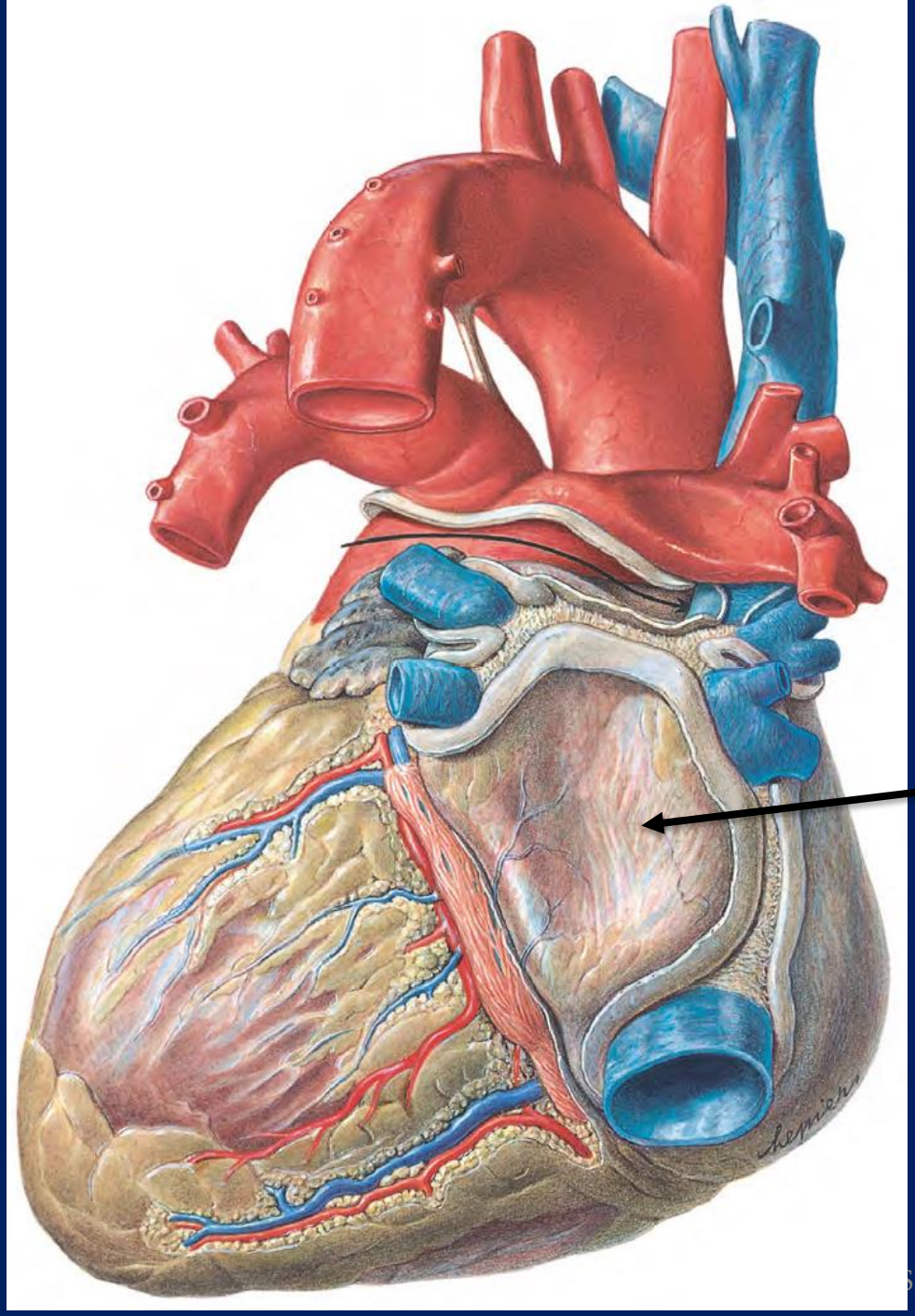

The base of the heart

- Is the heart's posterior aspect
- Is formed mainly by ***the left atrium,*** with a lesser contribution by the right atrium.

The base of the heart

Faces posteriorly toward the bodies of
vertebrae T6–T9
and
is separated from them by
<u>the pericardium</u>
<u>oblique pericardial sinus</u>
<u>Esophagus</u>
<u>aorta</u>

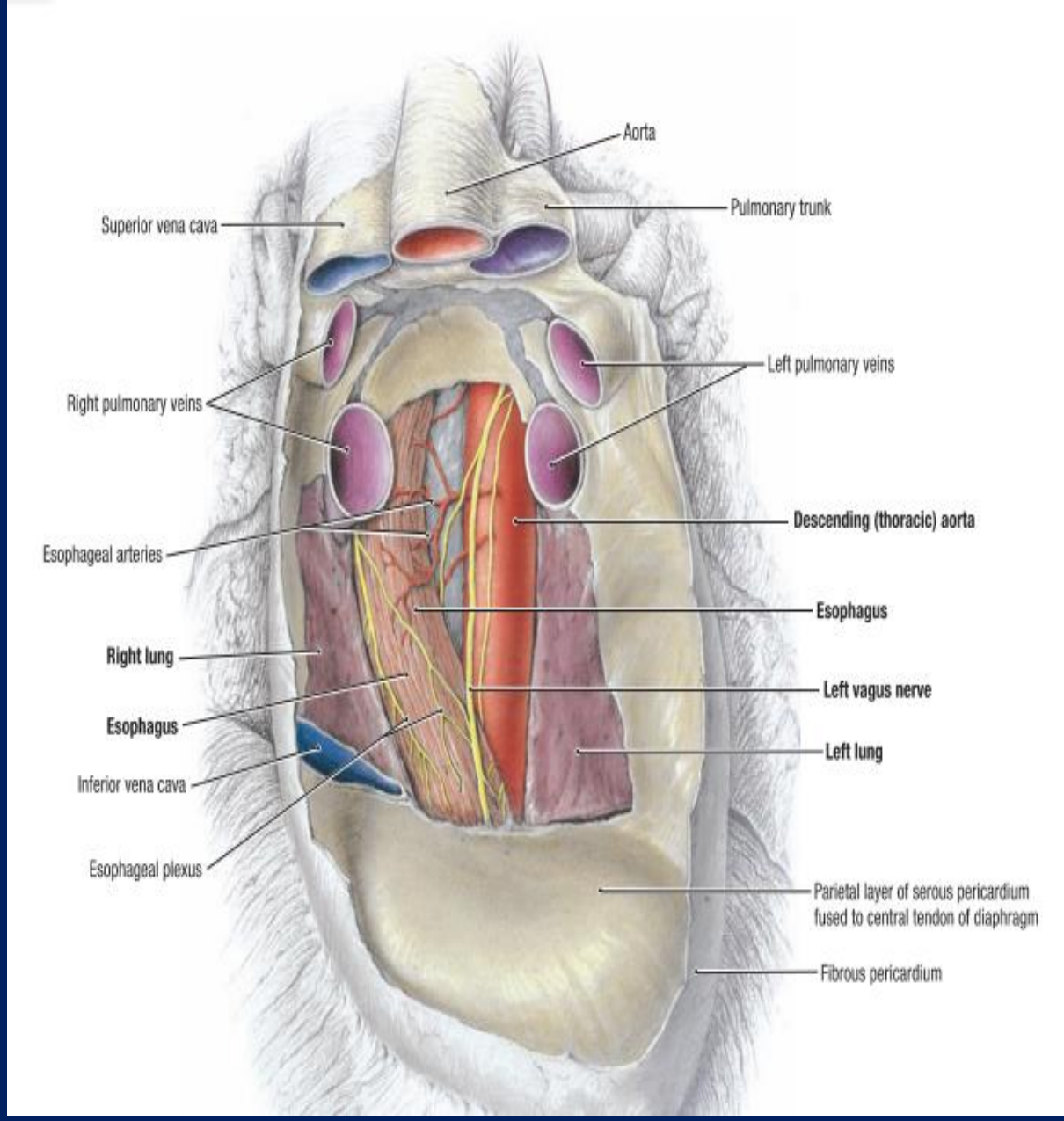

The sternocostal surface

is formed mainly by the right atrium and the right ventricle

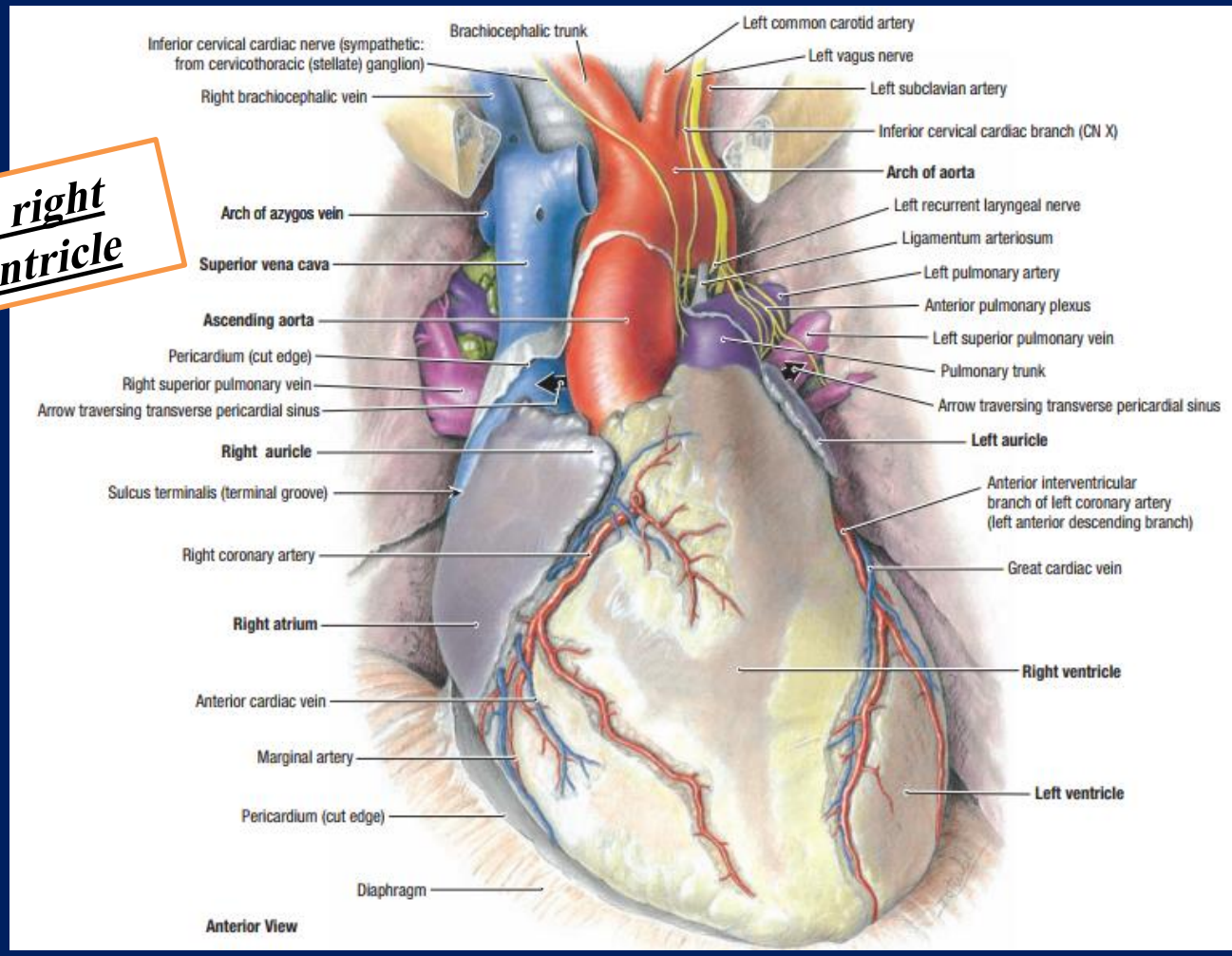

The diaphragmatic surface

It is formed mainly by **the right and left ventricles** separated by the ***posterior interventricular groove***

The ***inferior surface of the right atrium***, into which the inferior vena cava opens, ***also forms part of this surface***

it is related mainly to the central tendon of the diaphragm

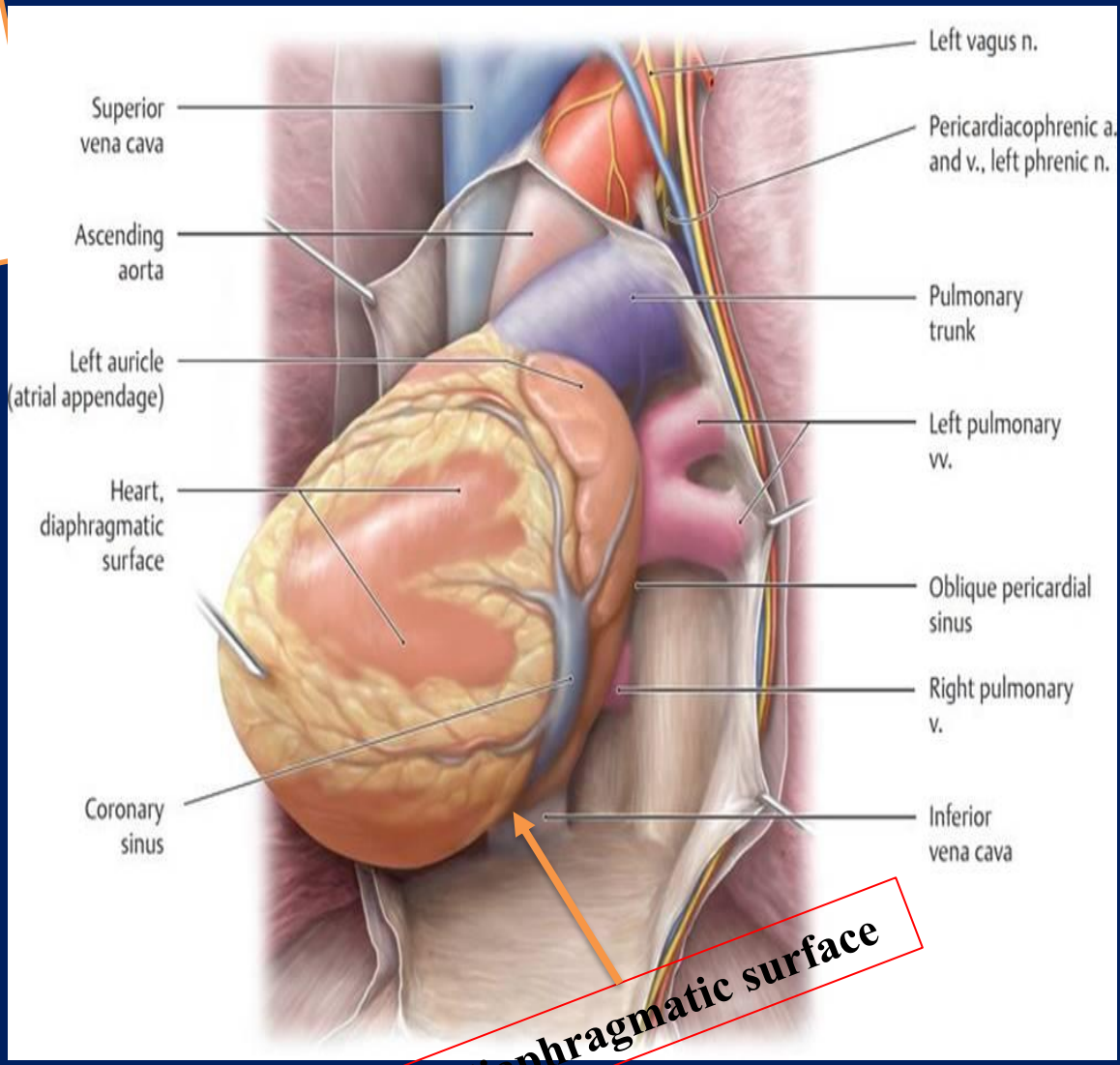

The diaphragmatic surface

The **left pulmonary surface**

faces the left lung, is broad and convex, and consists of ***the left ventricle and a portion of the left atrium***

it forms the cardiac impression in the left lung

The **right pulmonary surface**

faces the right lung, is broad and convex, and consists of **the right atrium**

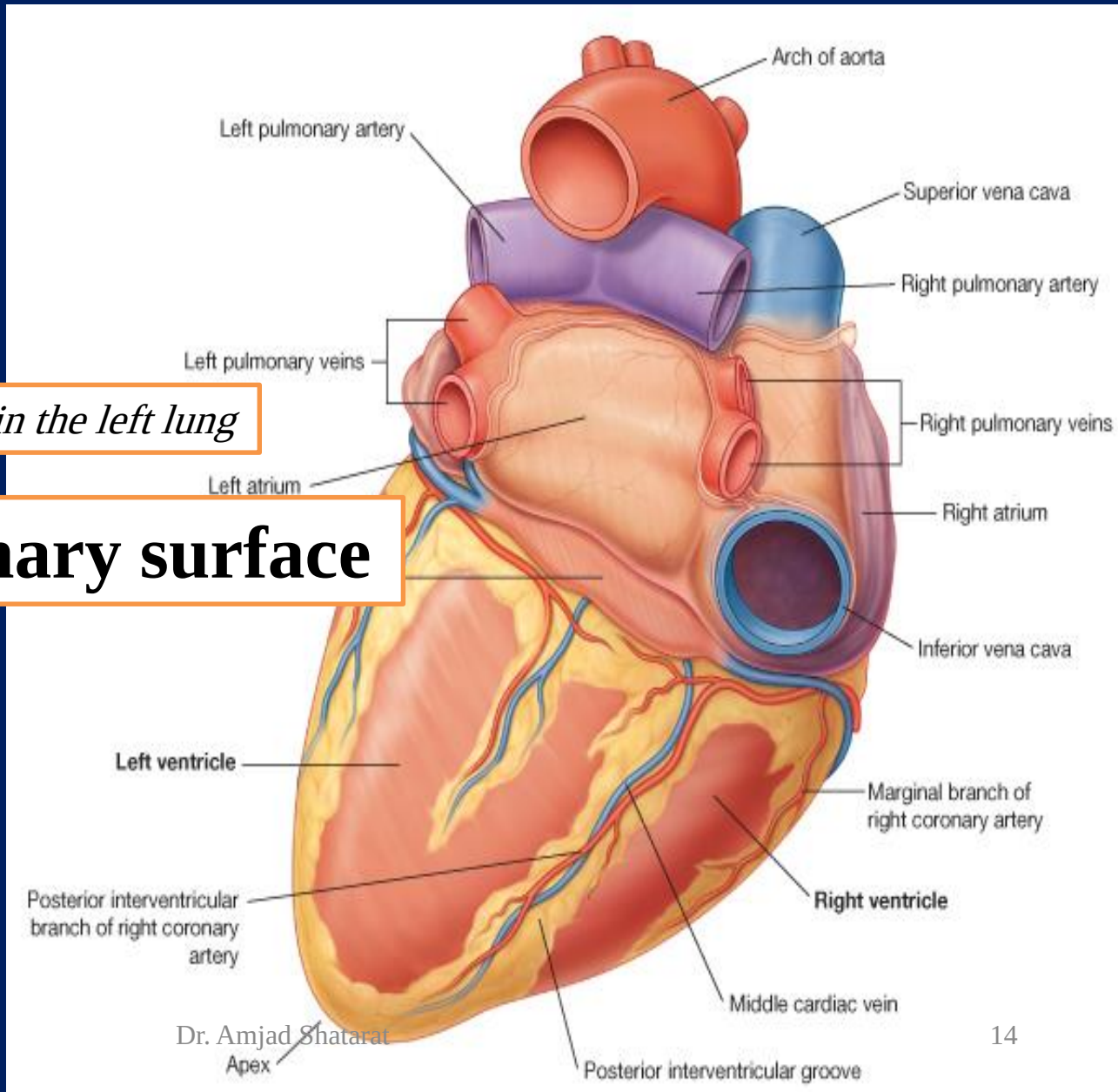

Borders of the Heart on an X-ray

The right border in a standard posterior-anterior view consists of :
The superior vena cava
The right atrium
The inferior vena cava

The inferior border consists of
The right ventricle
The left ventricle at the apex

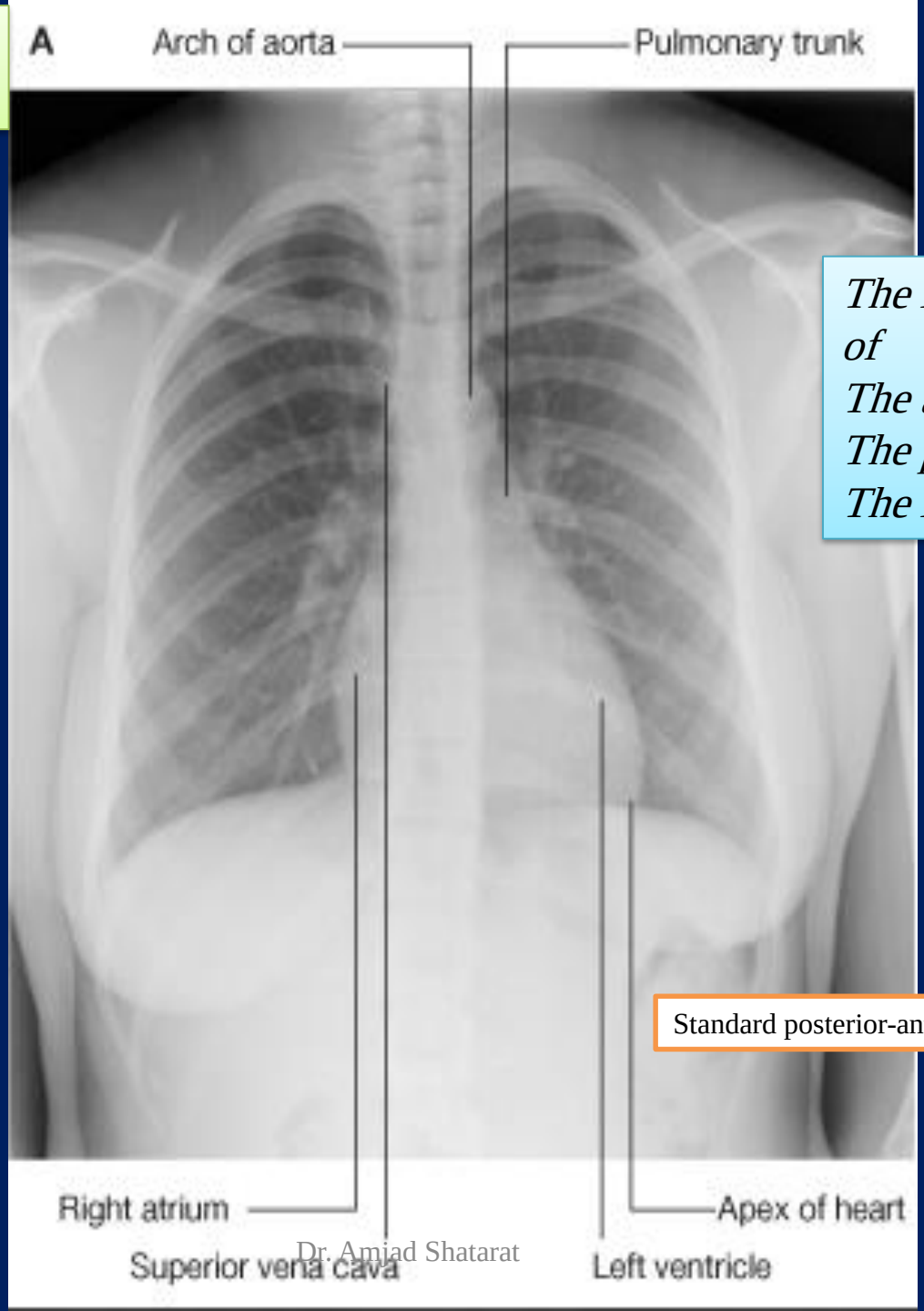

The left border consists of
The arch of the aorta,
The pulmonary artery
The left ventricle

Standard posterior-anterior view of the chest

The coronary sulcus

circles the heart, separating the atria from the ventricles

It contains

The right coronary artery
The small cardiac vein
The coronary sinus
The circumflex branch of the left coronary artery

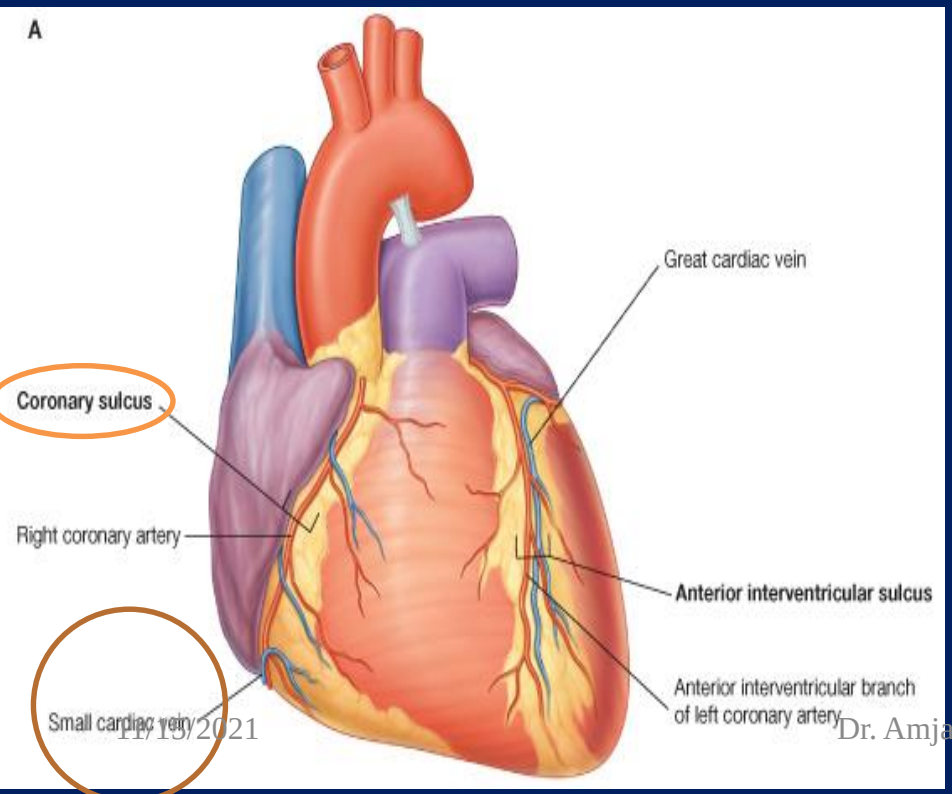

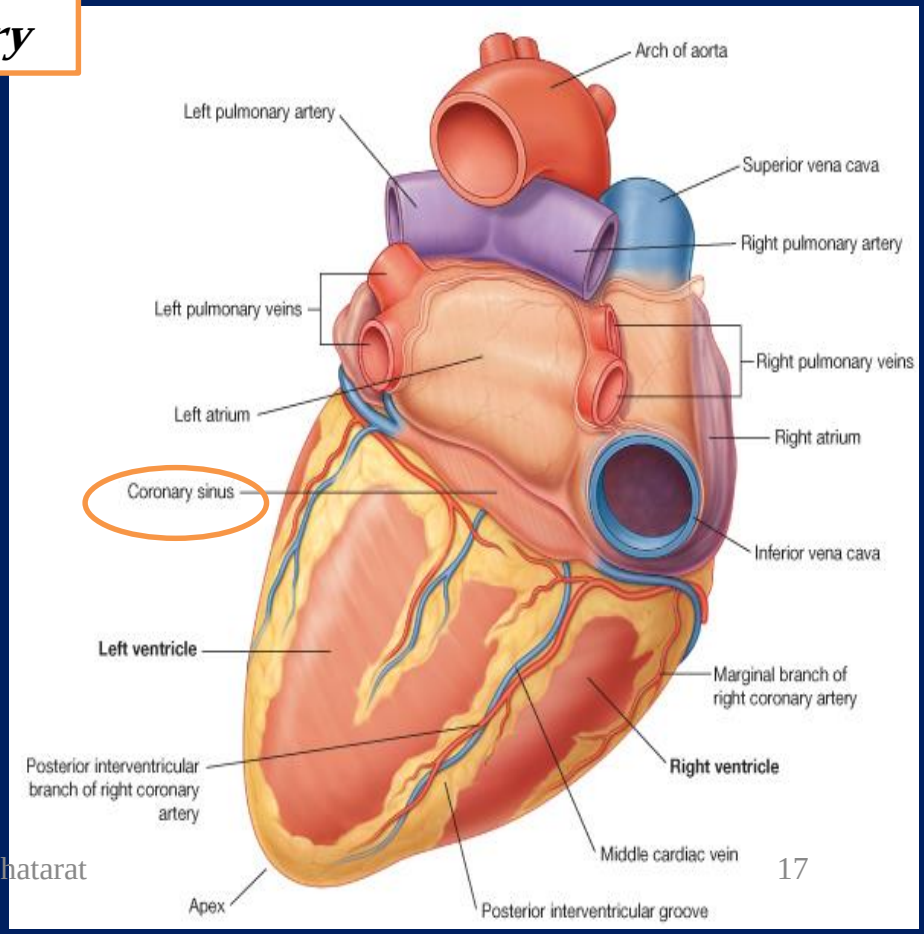

The anterior interventricular sulcus

- Is on the anterior surface of the heart
  - contains;
    - ***the anterior interventricular artery***
    - ***<u>The great cardiac vein</u>***

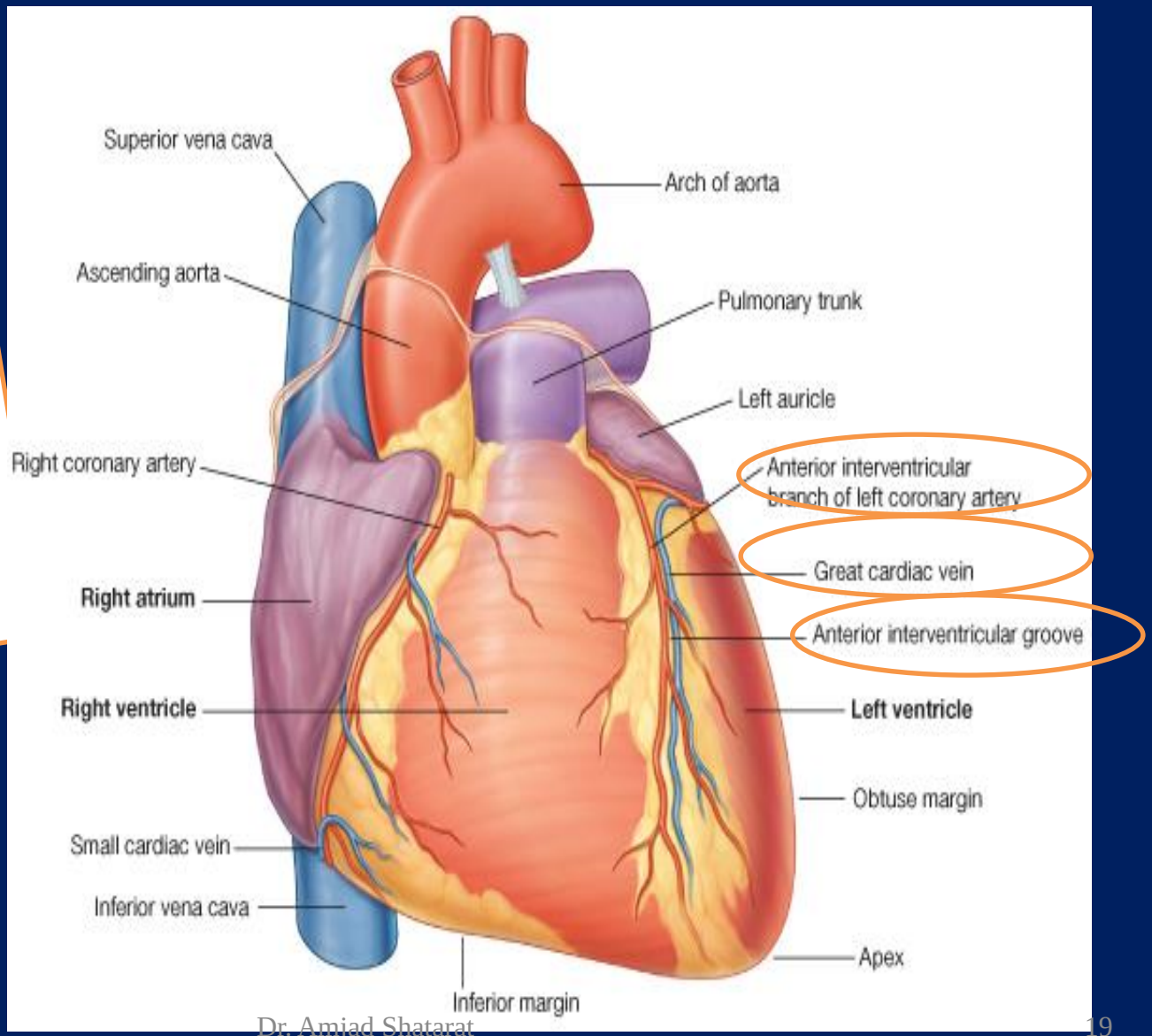

The posterior interventricular sulcus

- Is on the diaphragmatic surface of the heart and contains:
  - ***The posterior interventricular artery***

    and
- ***The middle cardiac vein.***

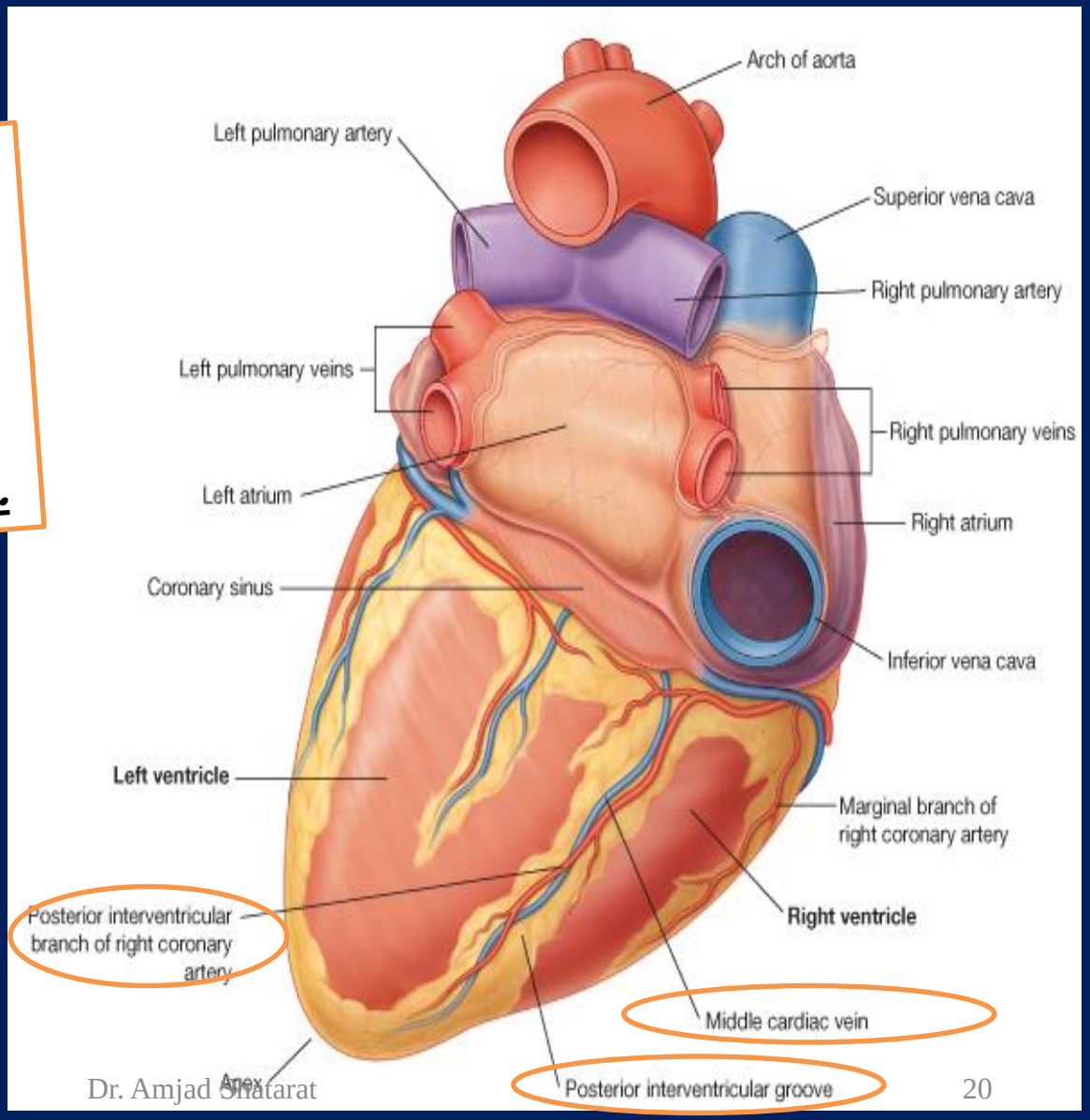

The walls of the heart are composed of cardiac muscle,

1- The myocardium; covered externally with serous pericardium

2-The epicardium; and lined internally with a layer of endothelium

3-The endocardium.

Fibrous skeleton of the heart

- This is a complex framework of dense collagen forming four fibrous rings (L. anuli fibrosi)

1-That surround the orifices of the valves

And

2- Right and left ***fibrous trigone*** (formed by connections between rings)

and

3-The membranous parts of the **interatrial and interventricular septa**

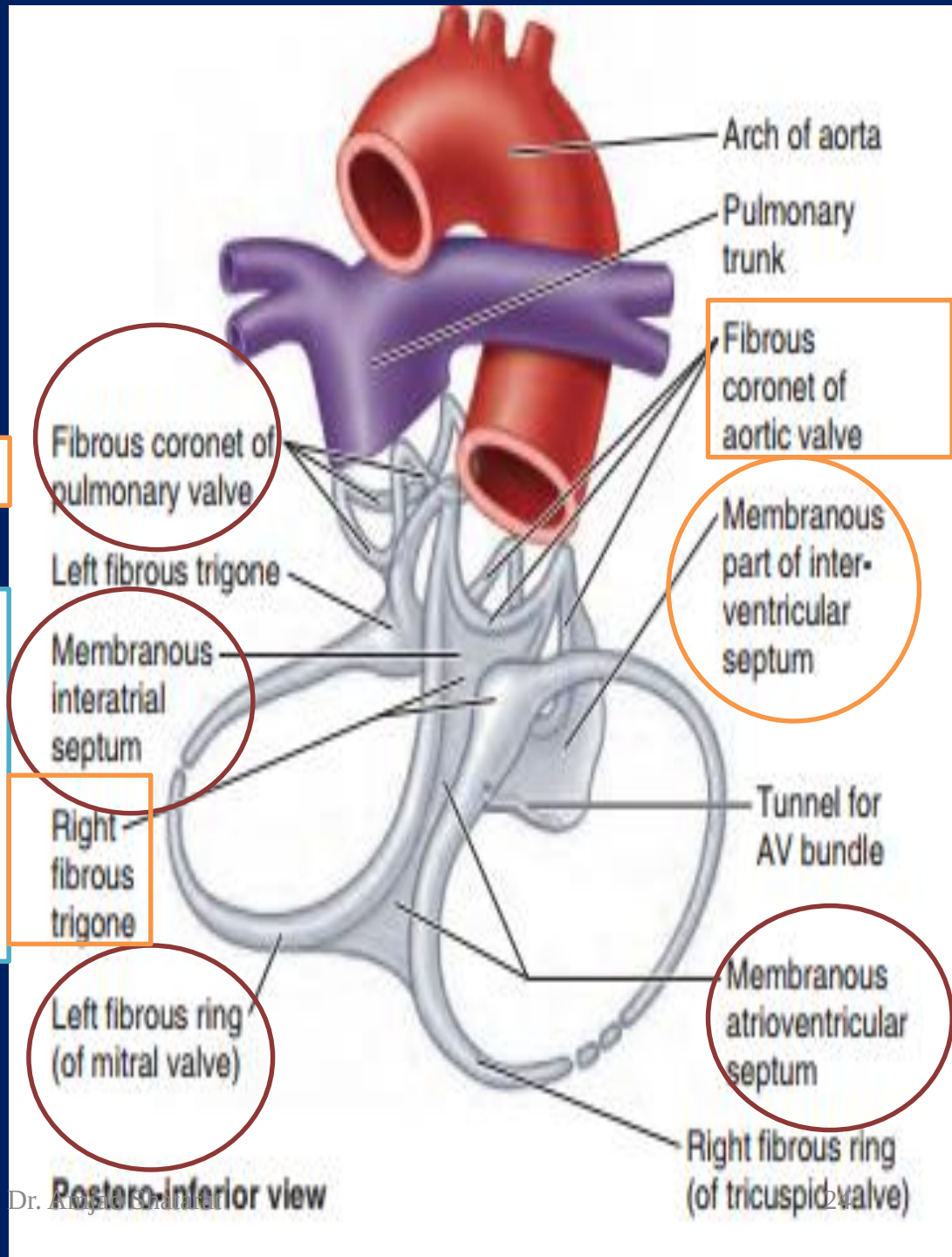

- The fibrous skeleton of the heart:
- Keeps the orifices of the AV and semilunar valves patent and prevents them from being overly distended by an increased volume of blood pumping through them.
- Provides attachments for the leaflets and cusps of the valves.
- Provides attachment for the myocardium
- Forms an electrical “insulator,” by separating the myenterically conducted impulses of the atria and ventricles so that they contract independently and by surrounding and providing passage for the initial part of the **AV bundle of the conducting** system of the heart

Chambers of the Heart

The heart is divided by septa into ***four chambers:***

1-THE RIGHT ATRIUM
2-LEFT ATRIUM
3- THE RIGHT VENTRICLE
4-LEFT VENTRICLE

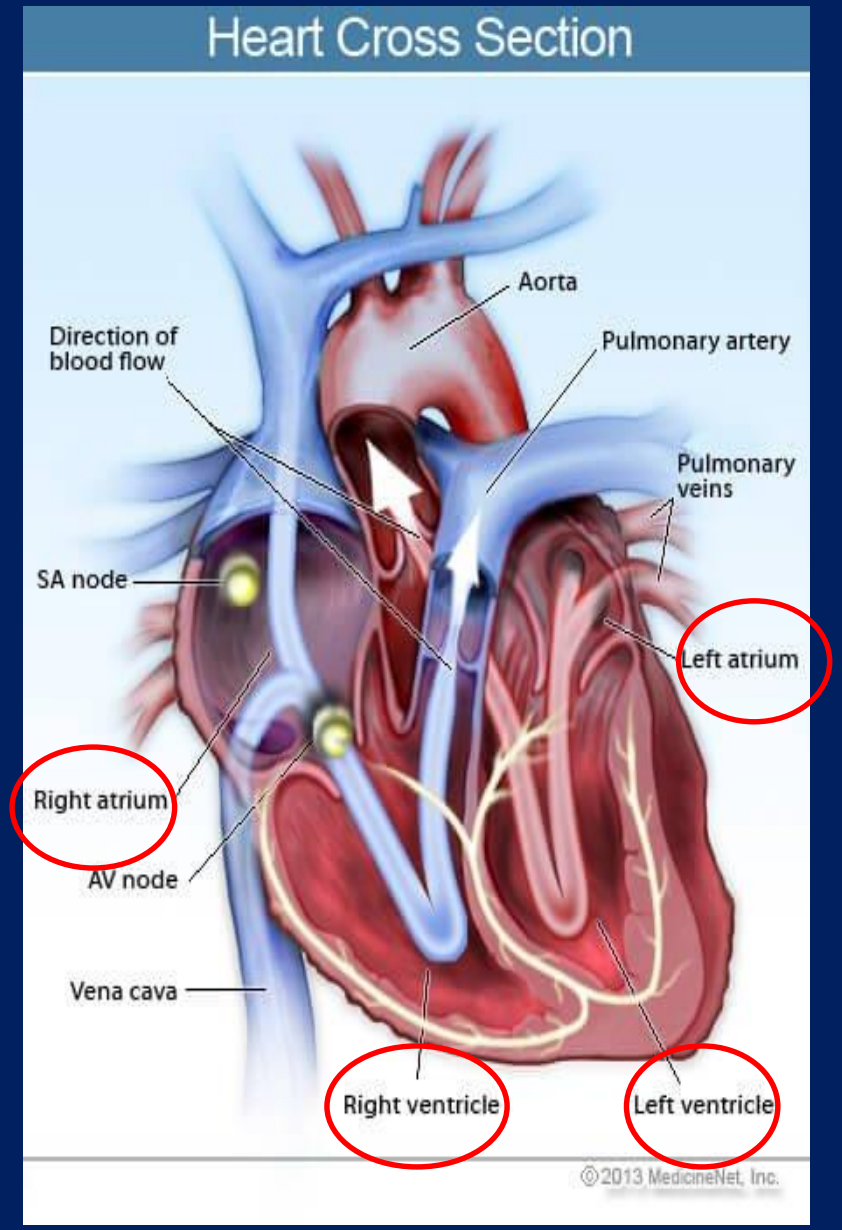

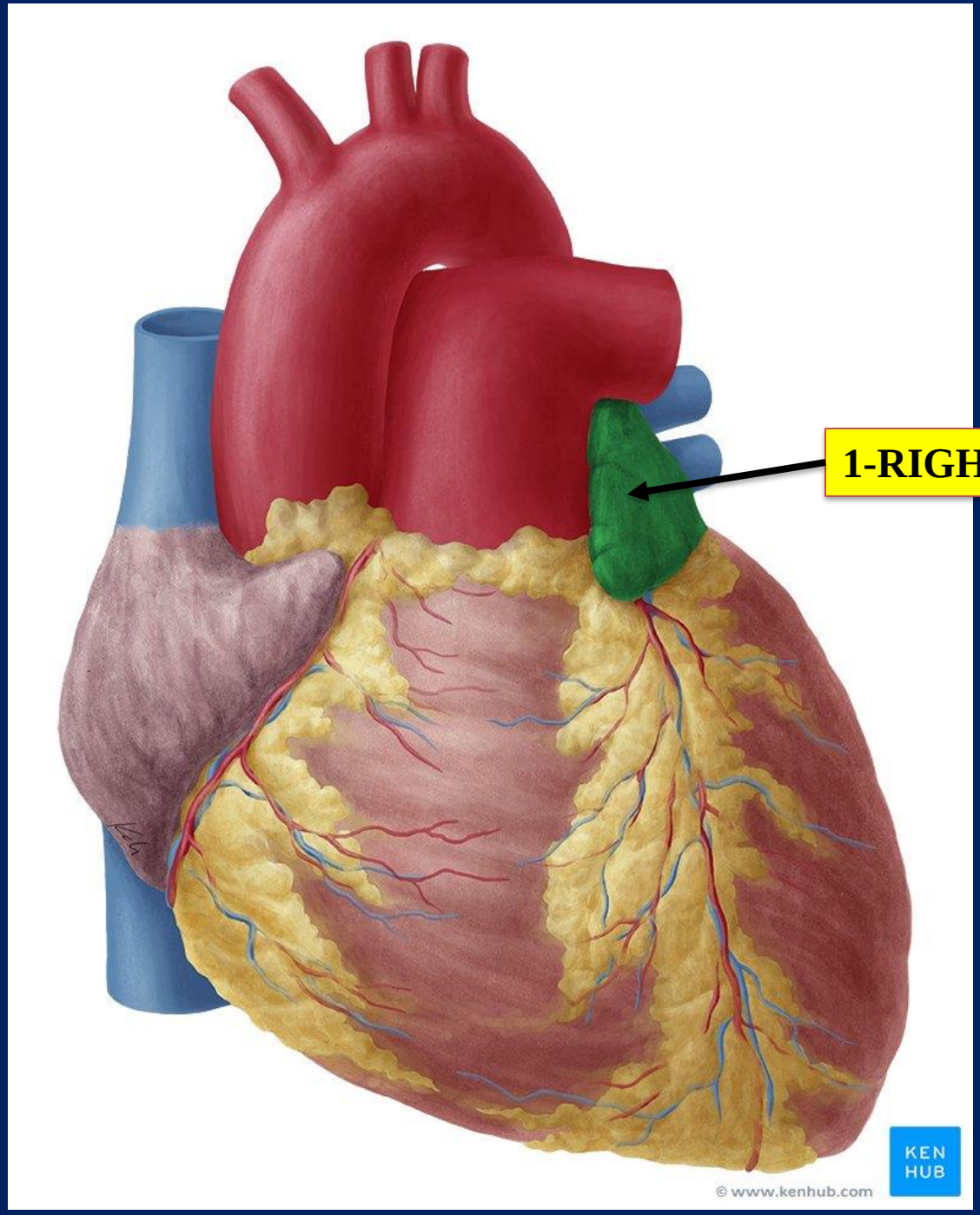
1-RIGHT ATRIUM
KEN HUB
© www.kenhub.com

The right atrium consists of ***a main cavity*** and a small ***outpouching, the auricle.***

Note

The term "auricle" is often improperly used instead of atrium. The true auricle is then regrettably called "auricular appendage" instead of atrial appendage, which is morphologically correct. The term "auricular fibrillation" is clinically incorrect and should be atrial fibrillation

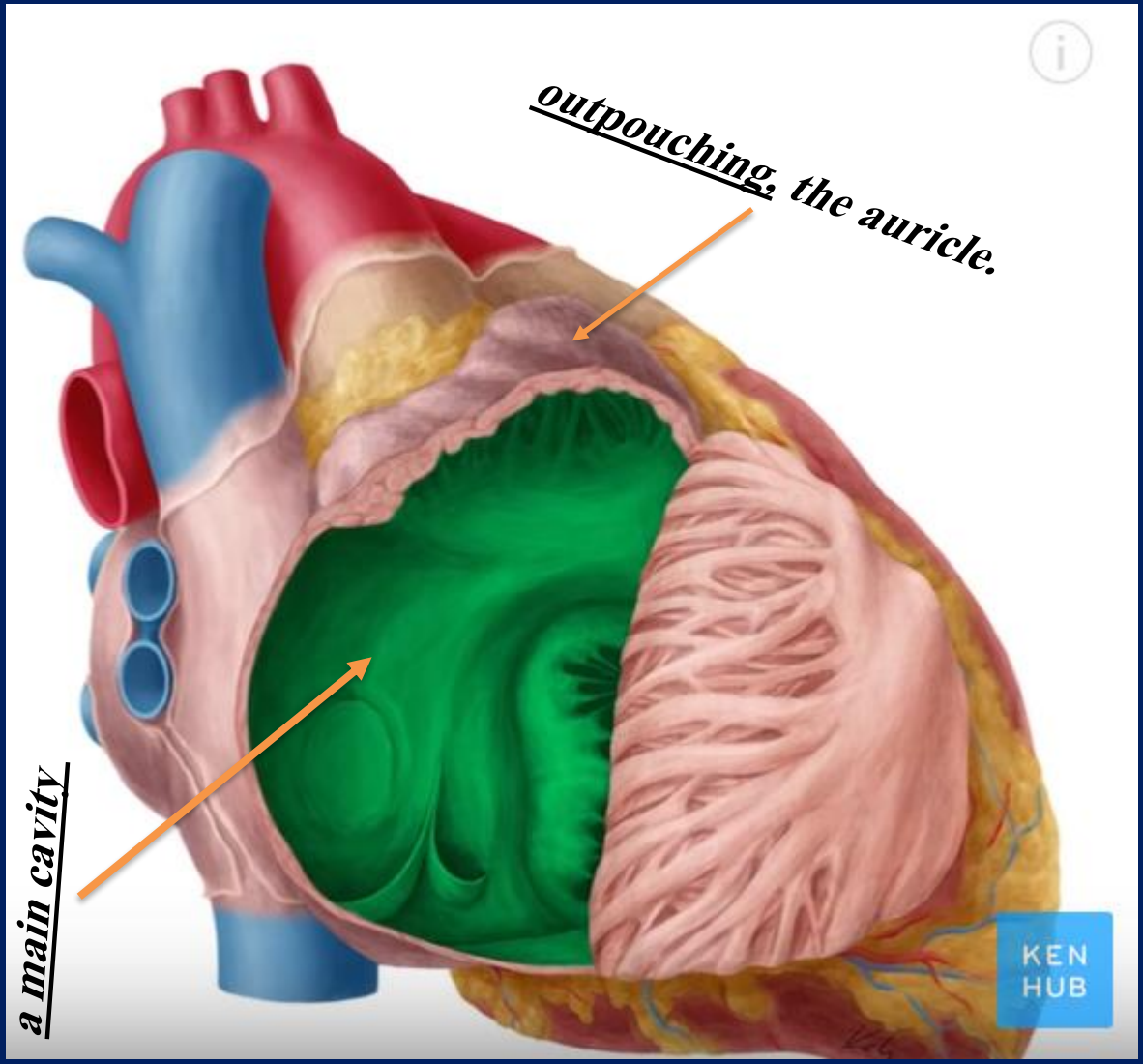

The right atrium consists of two parts:

2-a thin-walled anterior **trabeculated** part that constitutes the original embryonic right atrium

(1) a posterior smooth-walled part derived from the **embryonic sinus venosus** **(the sinus venarum)** into which enter the superior and inferior venae cavae

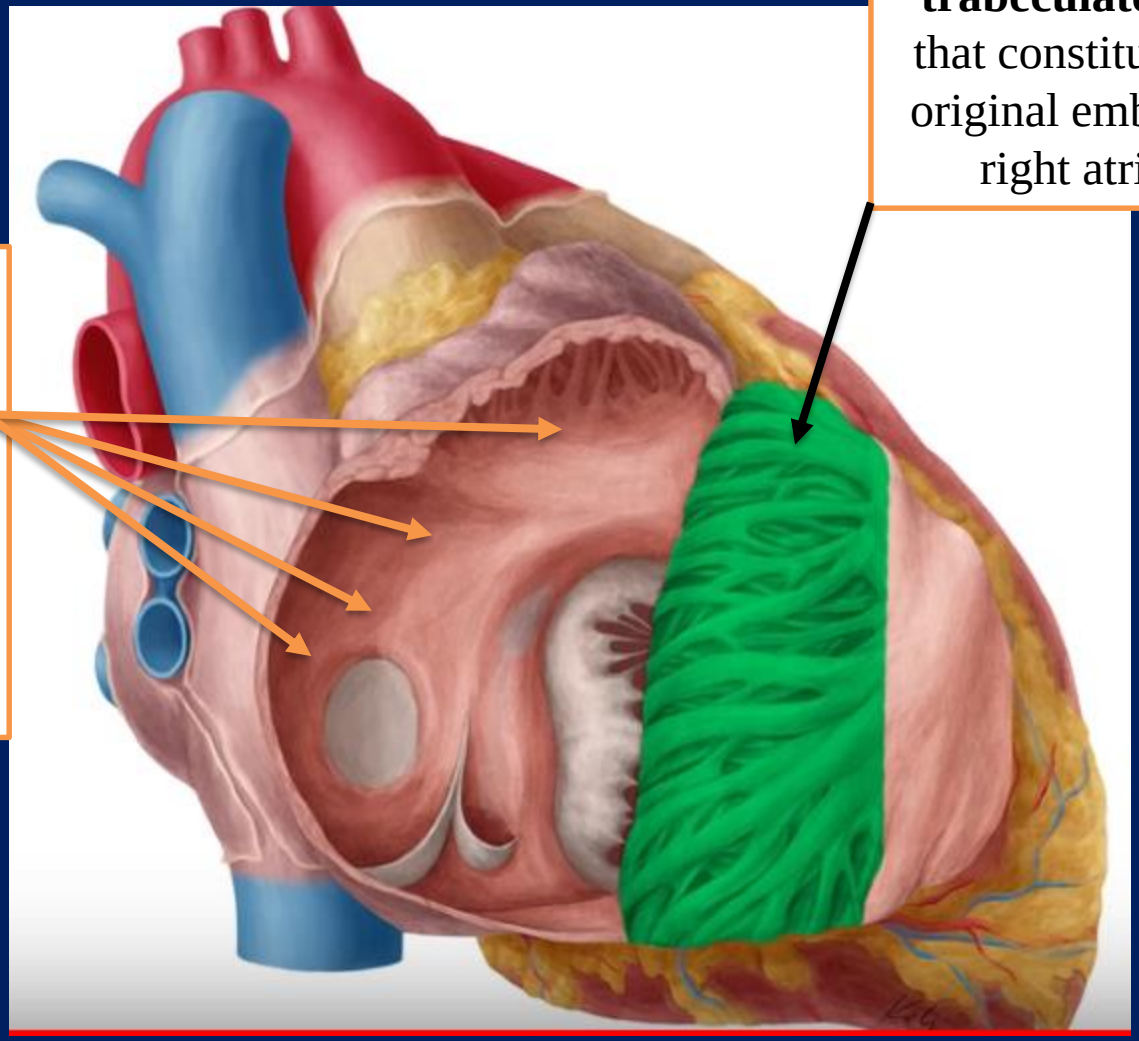

Internally, the two parts of the atrium are separated by a ridge of muscle

The crista terminalis

The crista terminalis

is most prominent superiorly, next to the SVC orifice, then fades out to the right of the IVC ostium.
Its position corresponds to that of the
sulcus terminalis externally

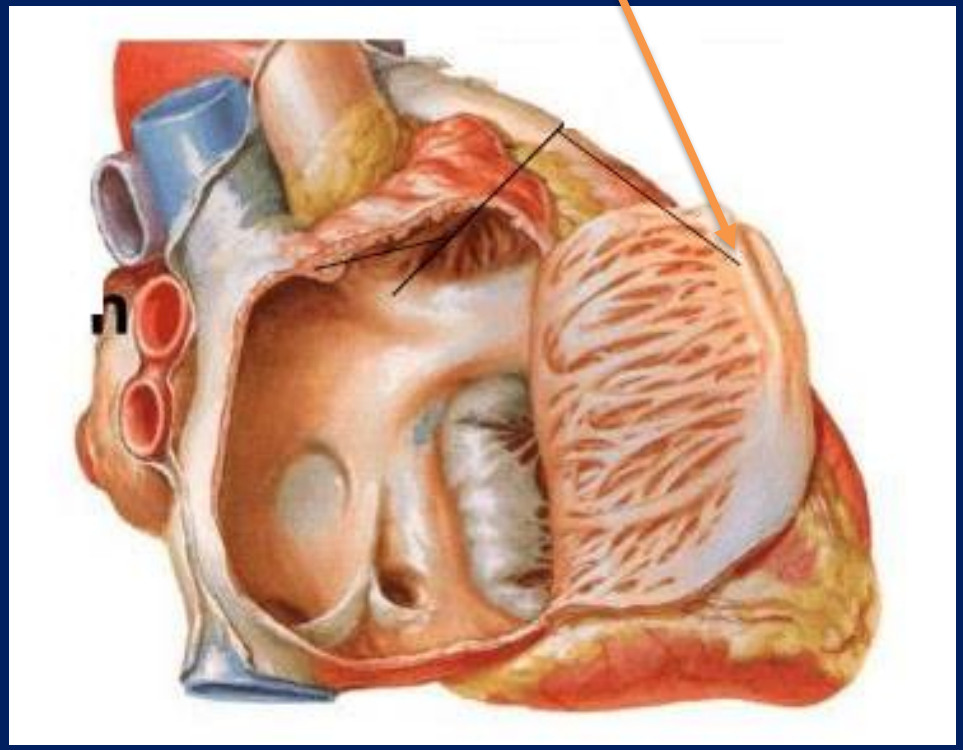

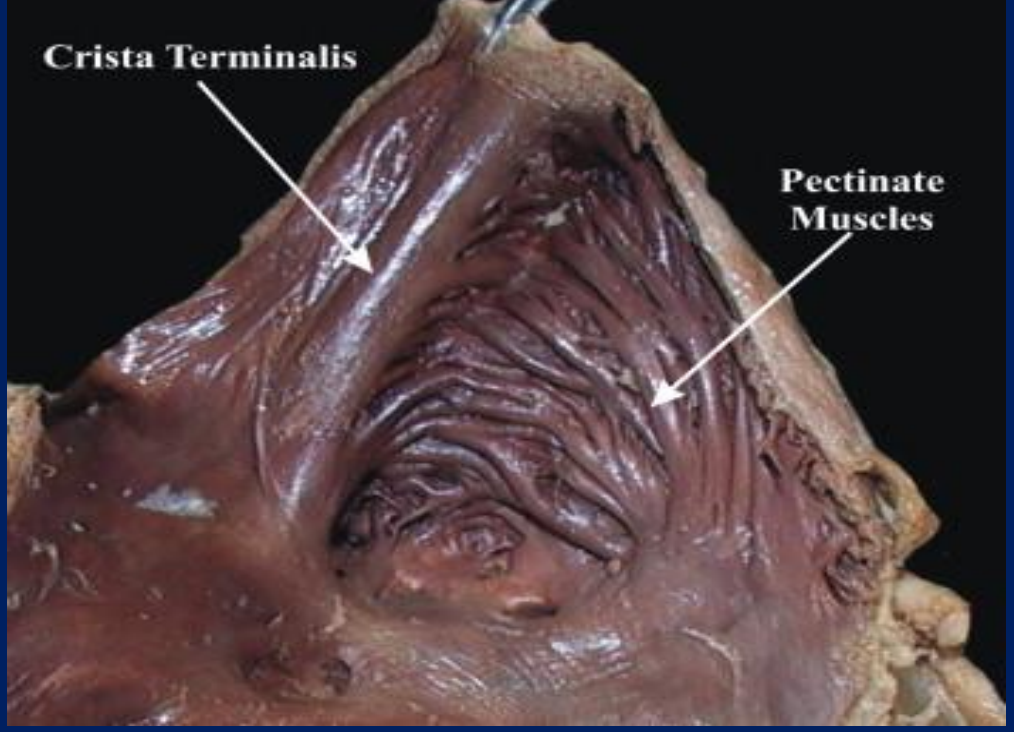

❖ From the lateral aspect of the crista terminalis, a large number of ***pectinate muscles*** run laterally and generally parallel to each other along the free wall of the atrium.

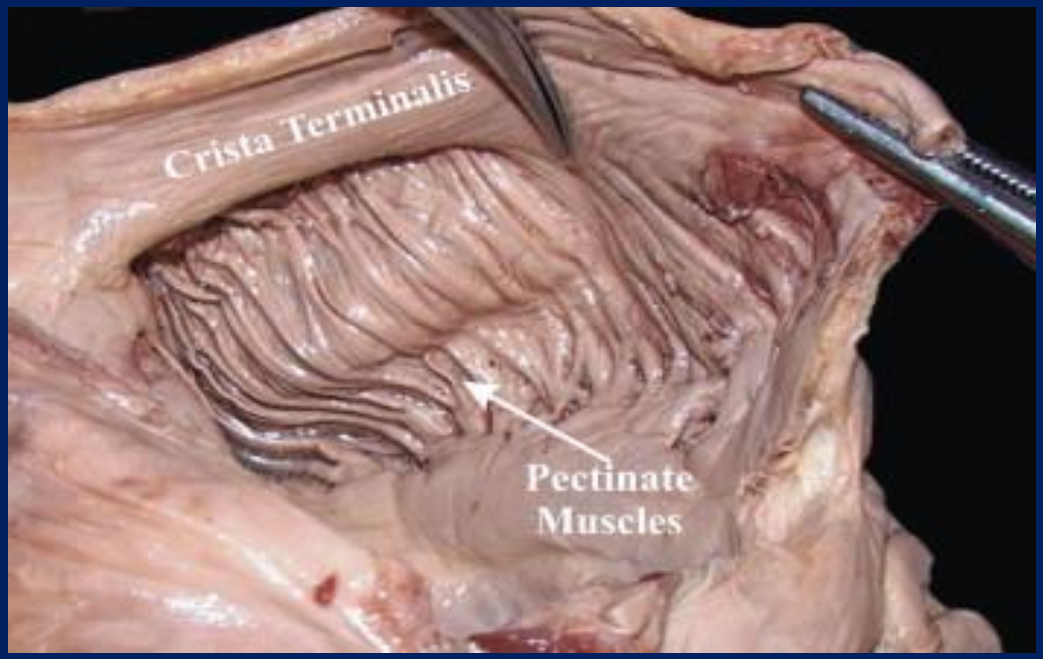

The ear-like right auricle is a conical muscular pouch that projects from Rt. atrium like an add-on room, increasing the capacity of the atrium as it **overlaps the ascending aorta.**

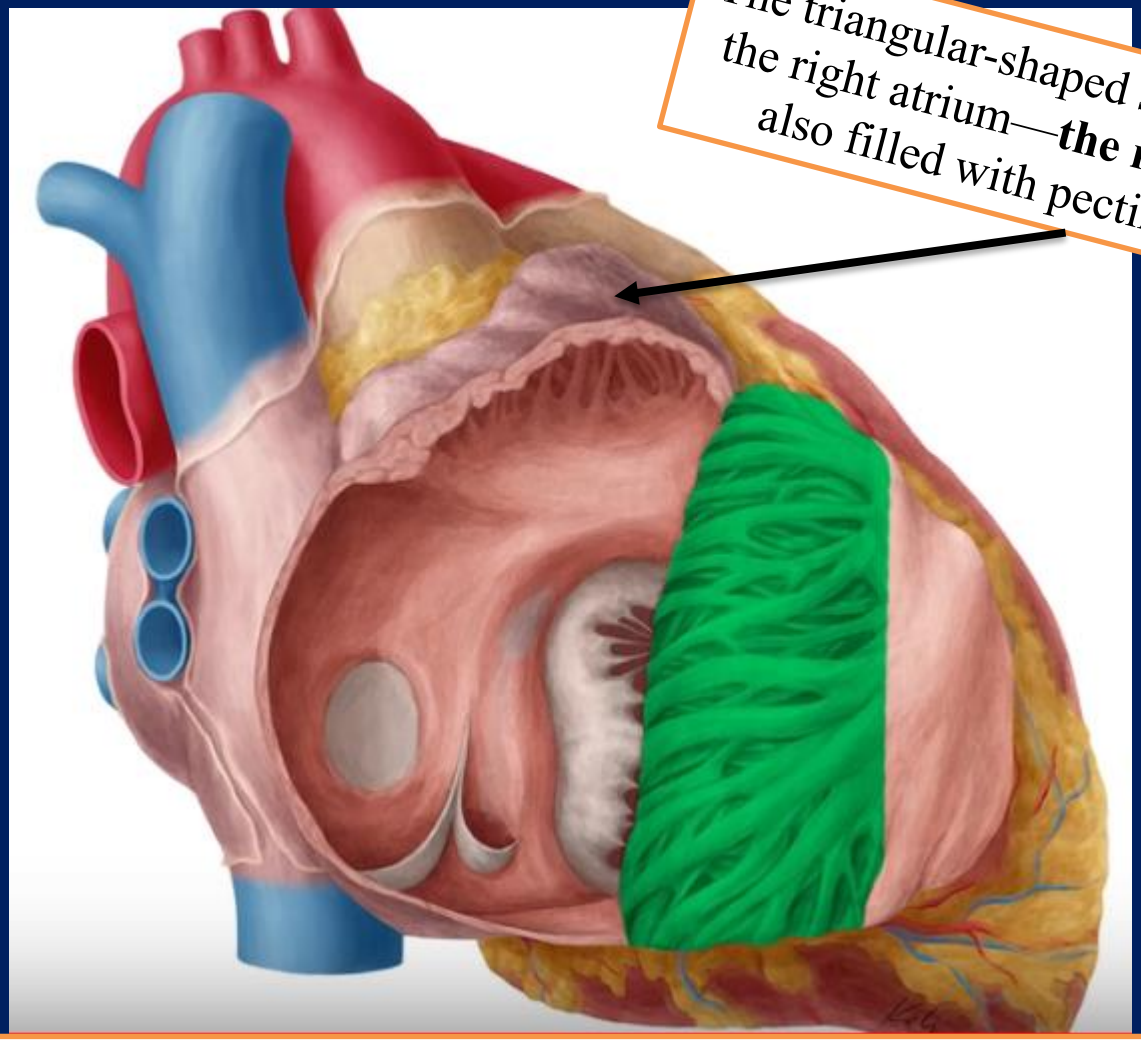

The triangular-shaped superior portion of the right atrium—**the right auricle—is** also filled with pectinate muscles.

The right auricle usually is not well demarcated externally from the rest of the atrium. The right auricle is a convenient, ready-made ***point of entry for the cardiac surgeon and is used extensively.***

Openings into THE RIGHT ATRIUM

1-The superior vena cava opens into the upper part of the right atrium

2-The inferior vena cava opens into the lower part of the right atrium

3-The coronary sinus, which drains most of the blood from the heart wall

4-The right atrioventricular orifice is guarded by **THE TRICUSPID VALVE**

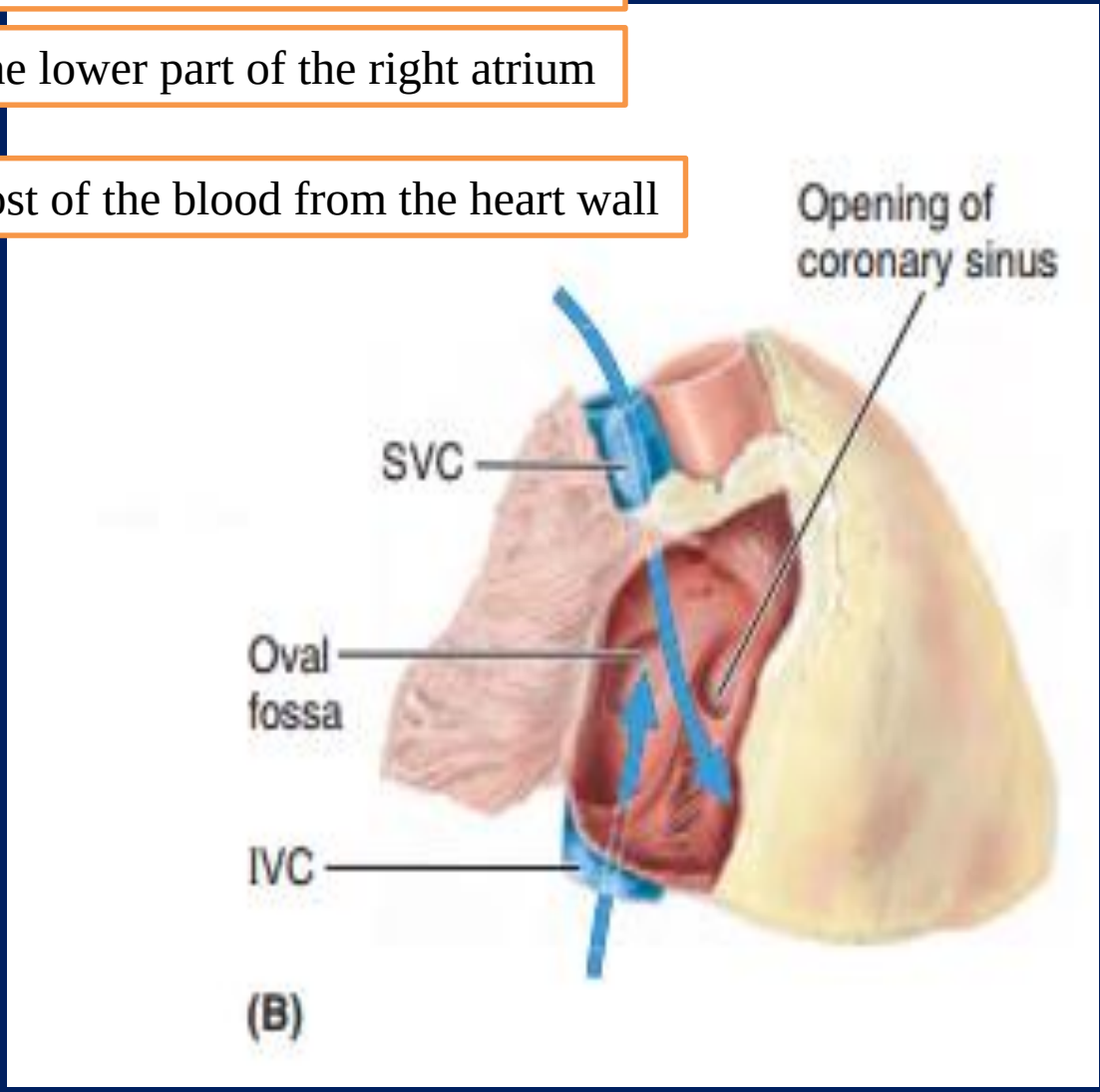

1-The superior vena cava

❖ returns blood from head, neck and upper limb and also receives blood from the chest wall and the esophagus via the azygos system

2-The inferior vena cava

- is larger than its superior counterpart:
- it drains blood from all structures below and **including the diaphragm** into the lowest part of the atrium near the septum.
- Anterior to its orifice is a flap-like valve

the Eustachian valve or valve of the inferior vena cava

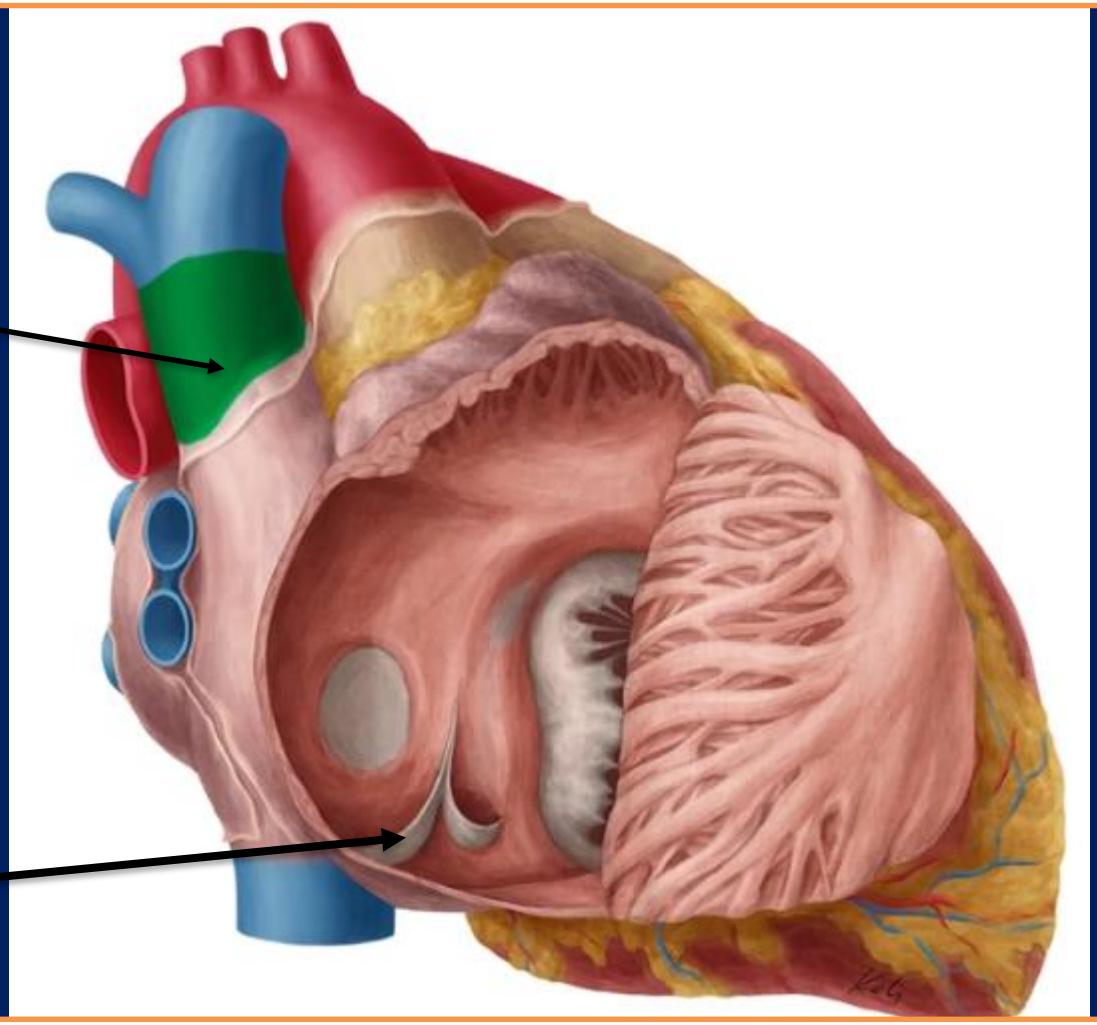

It is large during fetal life, when it serves to direct richly oxygenated blood from the placenta through the foramen ovale of the atrial septum into the left atrium

3-The coronary sinus opens into the venous atrial component between the orifice of the inferior vena cava, the fossa ovale and the vestibule of the atrioventricular opening

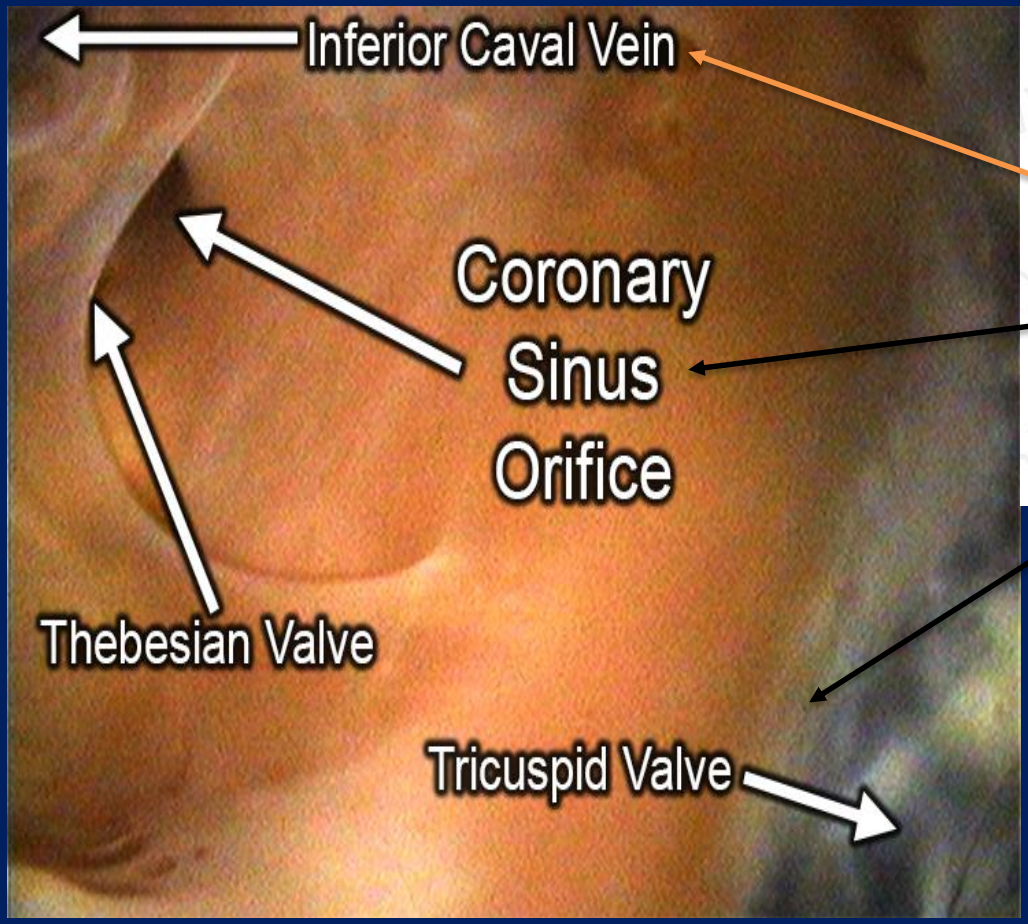

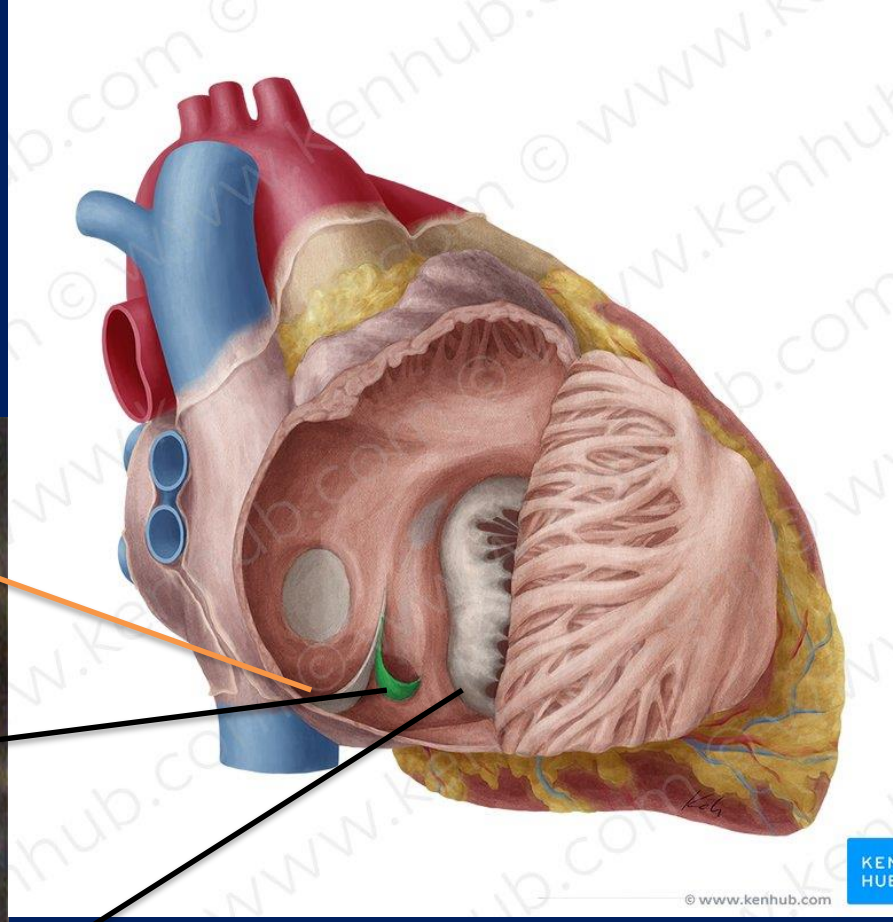

The coronary sinus is often guarded by a thin, semicircular valve that covers the lower part of the orifi ce

Thebesius' valve

also known as the

Thebesian valve

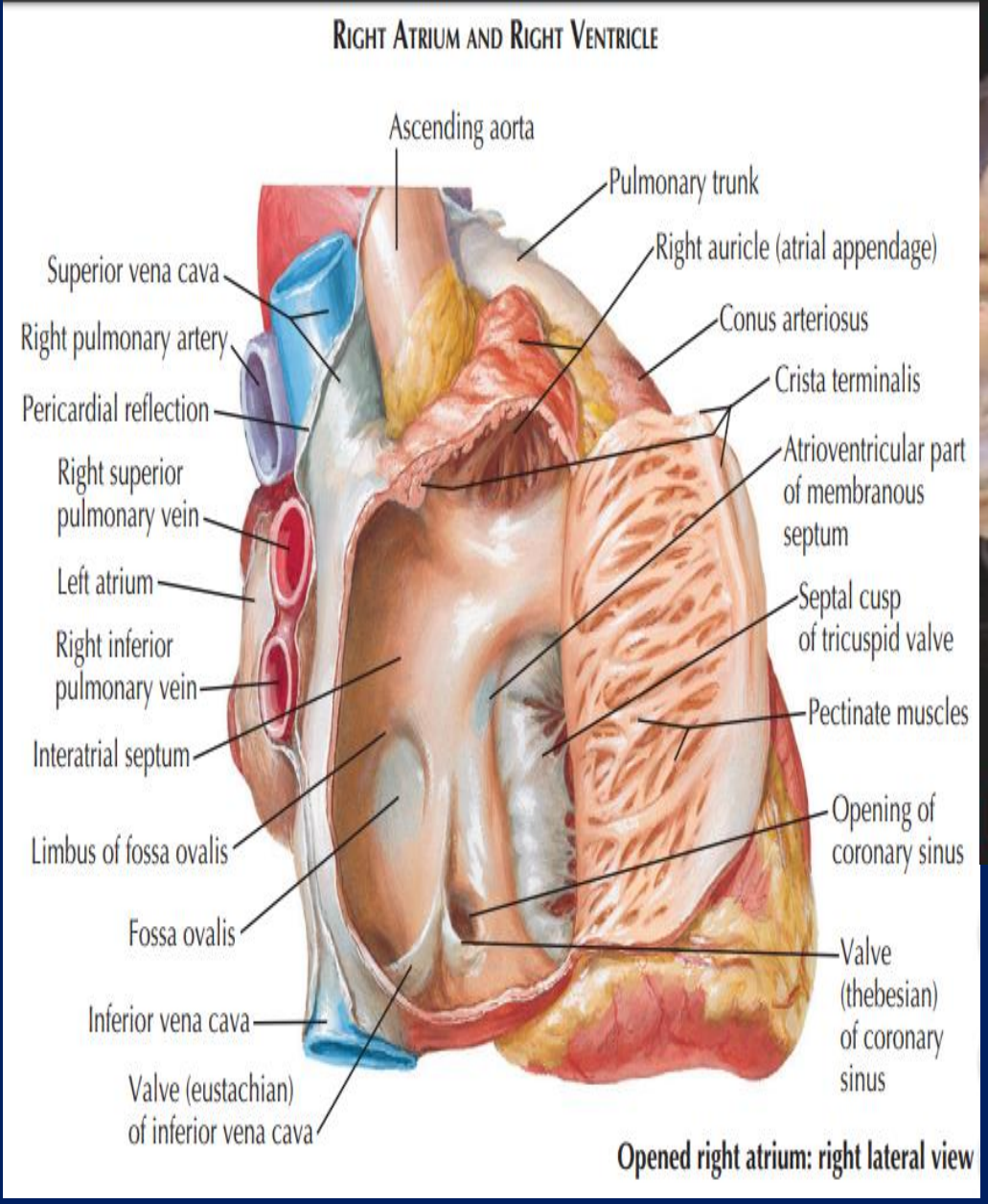
Right Atrium and Right Ventricle
Ascending aorta
Pulmonary trunk
Right auricle (atrial appendage)
Superior vena cava
Right pulmonary artery
Conus arteriosus
Pericardial reflection
Crista terminalis
Right superior pulmonary vein
Atrioventricular part of membranous septum
Left atrium
Septal cusp of tricuspid valve
Right inferior pulmonary vein
Pectinate muscles
Interatrial septum
Opening of coronary sinus
Limbus of fossa ovalis
Fossa ovalis
Valve (thebesian) of coronary sinus
Inferior vena cava
Valve (eustachian) of inferior vena cava
Opened right atrium: right lateral view

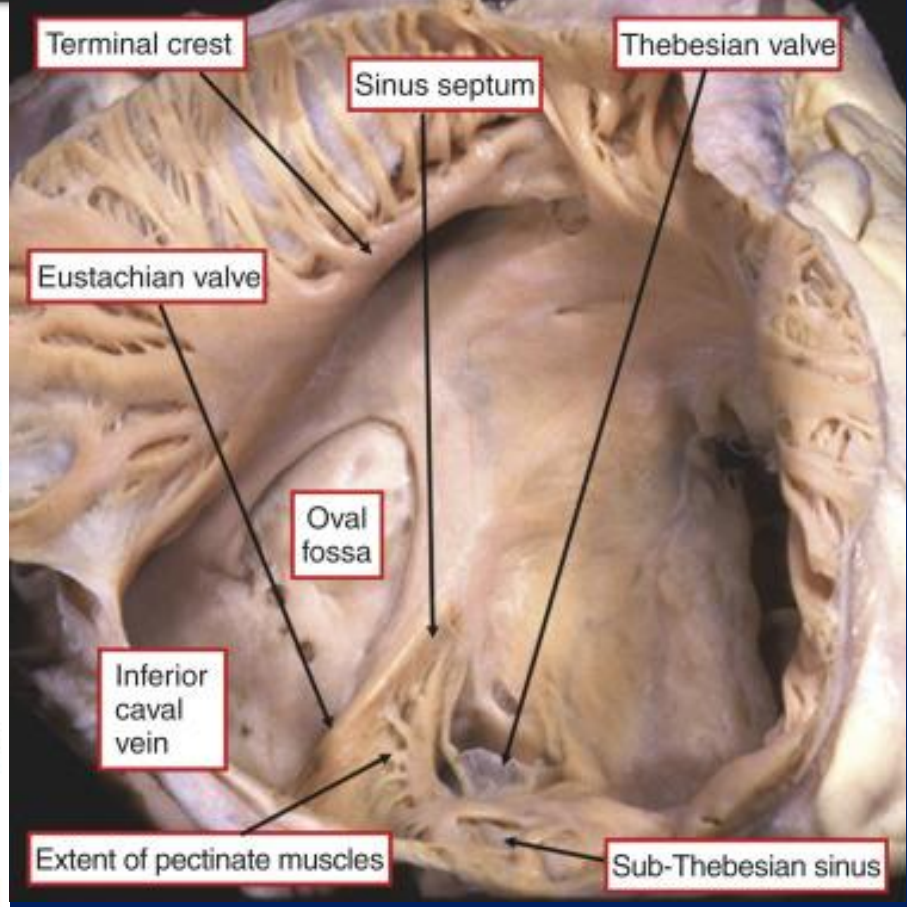
Terminal crest
Thebesian valve
Sinus septum
Eustachian valve
Oval fossa
Inferior caval vein
Extent of pectinate muscles
Sub-Thebesian sinus

4-Several small venous ostia, draining the minimal atrial veins, are found scattered around the atrial walls. They return a small fraction of blood from the heart, and are most numerous on the septal aspect.

The anterior cardiac veins

and, sometimes, **the right marginal vein** may enter the atrium through larger ostia

Fetal Remnants in the right Atrium

The fossa ovalis and **anulus ovalis.**
These latter structures lie ***on the atrial septum, which separates the right atrium from the left atrium***

The fossa ovalis is a shallow depression, which is the site of the foramen ovale in the fetus

The anulus ovalis forms the upper margin of the fossa.

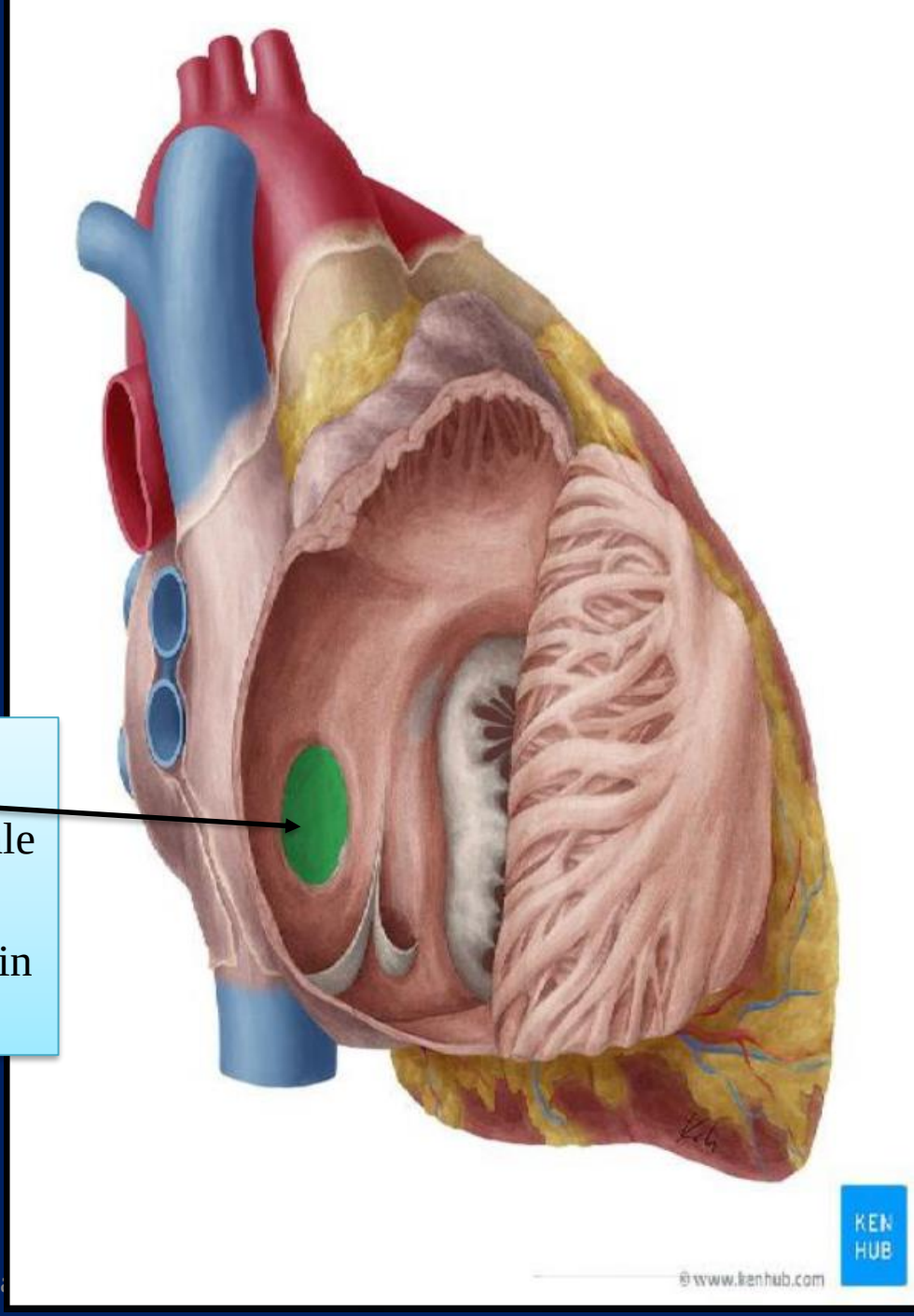

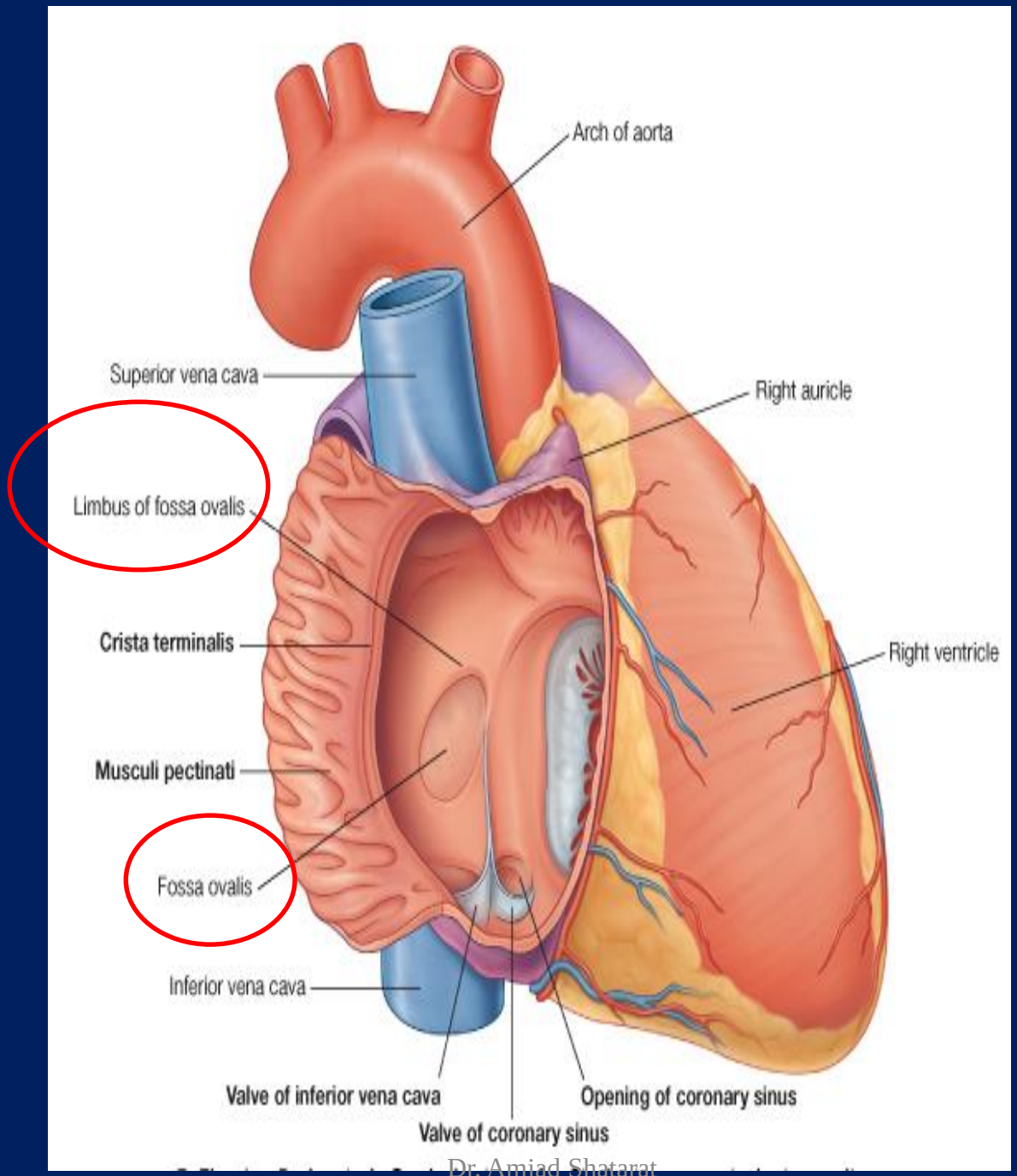
Arch of aorta
Superior vena cava
Right auricle
Limbus of fossa ovalis
Crista terminalis
Right ventricle
Musculi pectinati
Fossa ovalis
Inferior vena cava
Valve of inferior vena cava
Opening of coronary sinus
Valve of coronary sinus