Nose

- External nose
  - Bony framework
    - Nasal part of frontal bone
    - Frontal process of maxilla
    - nasal bone.
  - Cartilaginous framework
    - Alar cartilage
    - Lateral nasal cartilage
    - Septal cartilage
- Nasal Cavity
  - Nostril
    - anterior nares of the nasal cavity from which air comes in
  - Vestibule
    - area of the nasal cavity lying above the nostril in the ala of the nose
  - Choana
    - posterior nares of the nasal cavity

xMind Evaluation Mode

Nasal Cavity Relations

- lateral wall
  - Vestibule
  - Antrum
  - 3 Conchaes
    - Superior conchae
      - originates from ethmoidal bone
    - Middle conchae
      - originates from ethmoidal bone
    - Inferior conchae
      - originates from is the maxilla
  - 3 meatuses
  - 1 recess
- medial wall
  - the septum
    - cartilage (anteriorly)
    - perpendicular plate of ethmoid bone (posteriorly & superiorly)
    - vomer (posteriorly & downward)
- Roof
  - Anterior part
    - Nasal spine of the frontal bone
    - nasal bones
  - Middle part
    - horizontal cribriform plate of ethmoid
  - Posterior part
    - Anterior surface of the sphenoid bone & sphenoidal sinus.
    - Ala of the vomer
    - Vaginal process of the palatine bone
- Floor
  - upper surface of the hard palate
    - Horizontal plate of palatine bone
    - Palatine process of maxilla

xMind Evaluation Mode

Nasal Cavity

- Blood Supply
  - Maxiilary Artery
    - Sphenopalatine artery
      - Short sphenopalatine artery — Posterior Superior quadrant
      - Long sphenopalatine artery
        - medial wall septum (mainly)
        - supply part of the lateral wall
    - Palatine artery
      - Greater palatine artery — postero and antero-inferior quadrant of lateral wall
      - Lesser palatine artery — supplies the soft palate
    - infraorbital Artery — Alveolar arteries — Superior Alveolar artery — lateral wall
  - ophthalmic artery — ethmoidal arteries
    - Anterior ethmoidal artery — anterior- superior quadrant
    - Posterior ethmoidal artery — upper parts of the medial and lateral walls
  - Facial Artery
    - Superior labial artery
      - Alar branch — supplies the region around the naris
      - Septal branch — supplies anterior regions of the nasal septum
      - supplies the lateral wall
    - Lateral nasal arteries
      - supply blood of the external nose
      - give alar branches — supply the nasal vestibule
- Venous Drainage
  - facial vein — anterior 1/3
  - lateral pterygoid plexus — posterior 2/3
- Lymphatics
  - submandibular lymph nodes — Anterior part
  - retropharyngeal lymph nodes THEN deep cervical lymph nodes — Upper & posterior parts
- Nerve Supply
  - olfactory nerve — sensation/olfaction
  - ophthalmic nerve
    - Anterior ethmoidal nerve — sensory to lateral & medial walls
    - Posterior ethmoidal nerve — Supply mucosa of the ethmoidal & sphenoid air sinuses — does not extend into the nasal cavity itself
  - Maxillary nerve
    - Posterior superior lateral nasal nerves — lateral wall of the nasal cavity
    - Posterior inferior nasal nerves — lateral wall of the nasal cavity
    - infra-orbital nerve — Anterior superior alveolar nerve — supplies the lateral wall near the anterior end of the inferior concha
    - nasopalatine nerve — supplies the oral mucosa posterior to the incisor teeth
    - Posterior superior medial nasal nerves — cross the roof to the nasal septum and supply both these regions
  - facial nerve — secretomotor innervation for the mucous glands of the nose

XMind Evaluation Mode

Nasal Cavity

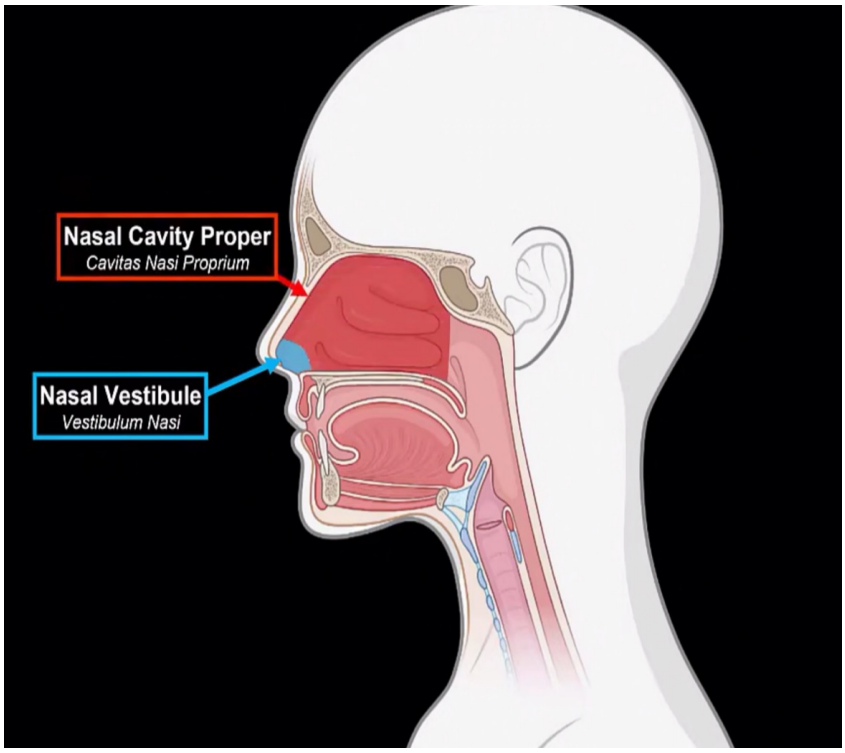

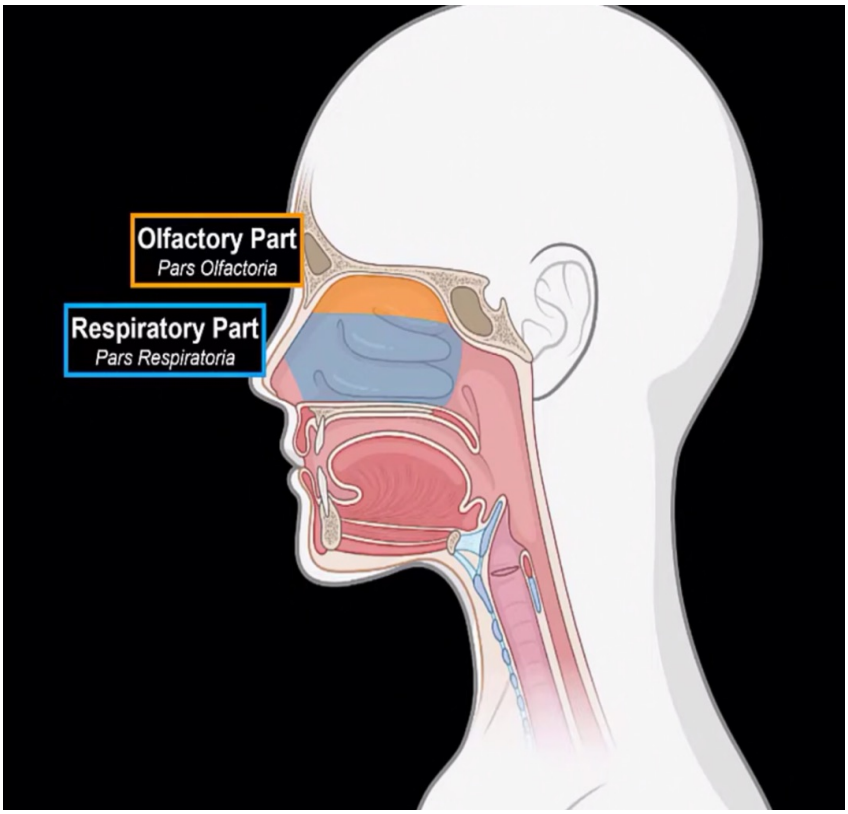

Lacrimal bone

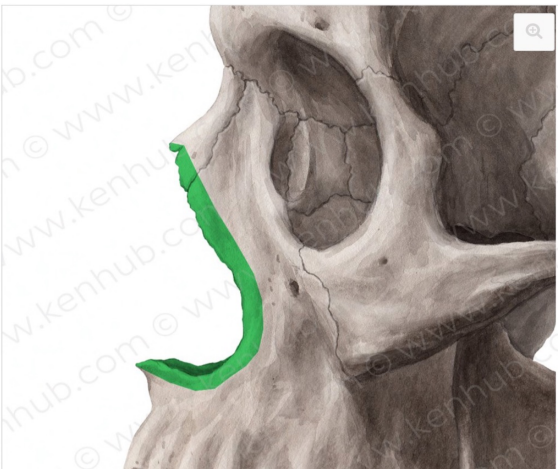

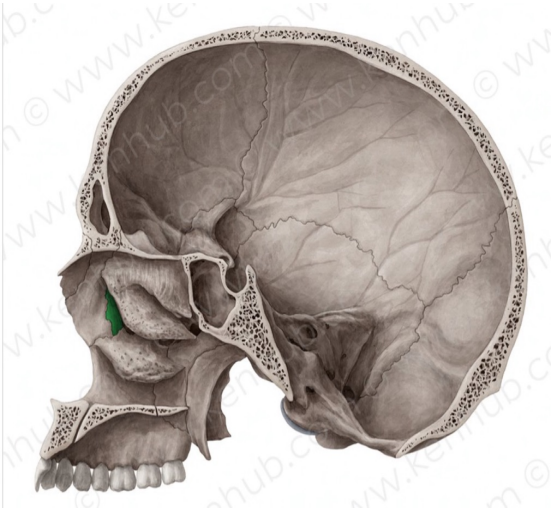

Nasal bone

Nasal surface of Maxilla

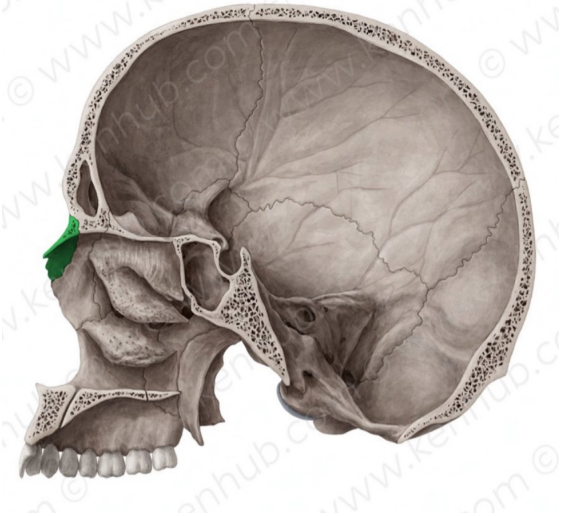

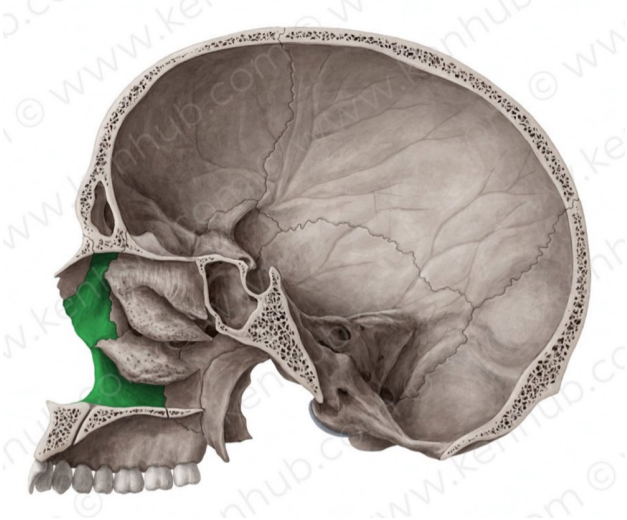

Sphenoid Bone

Medial plate of ptergoid process of Sphenoid

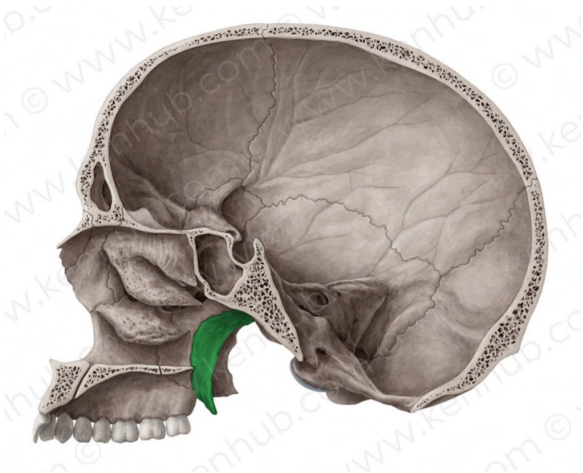

Ethmoid bone

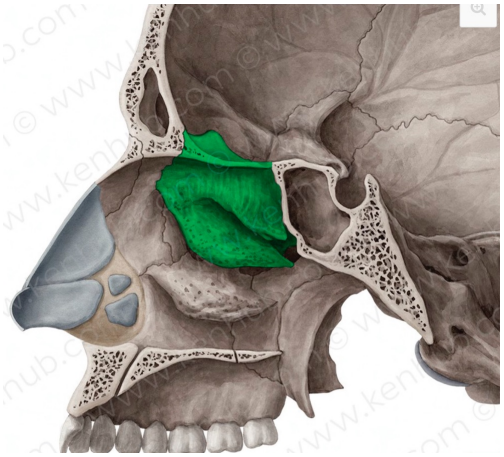

Vomer

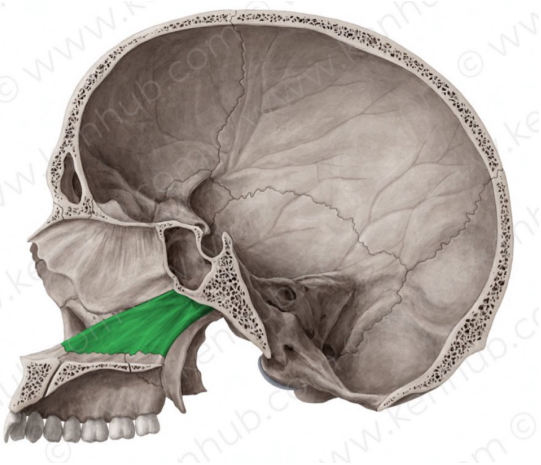

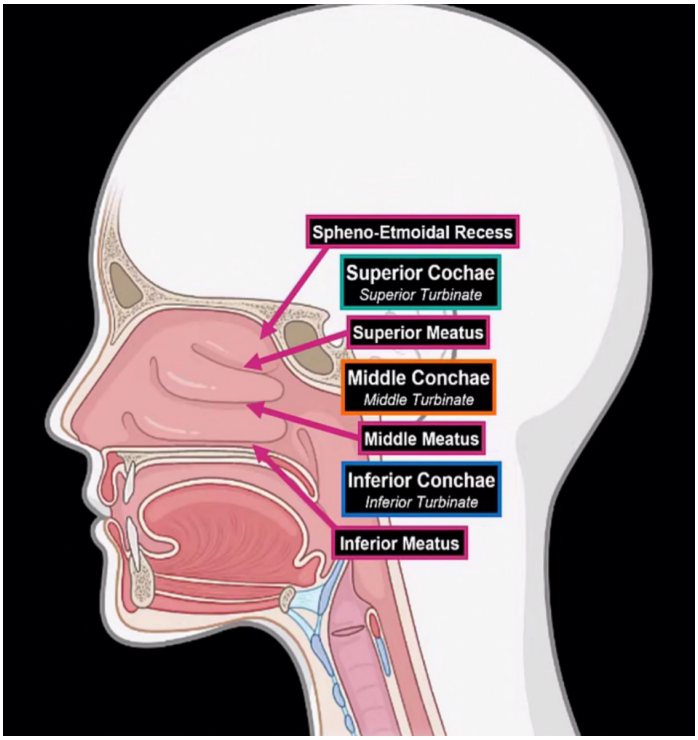

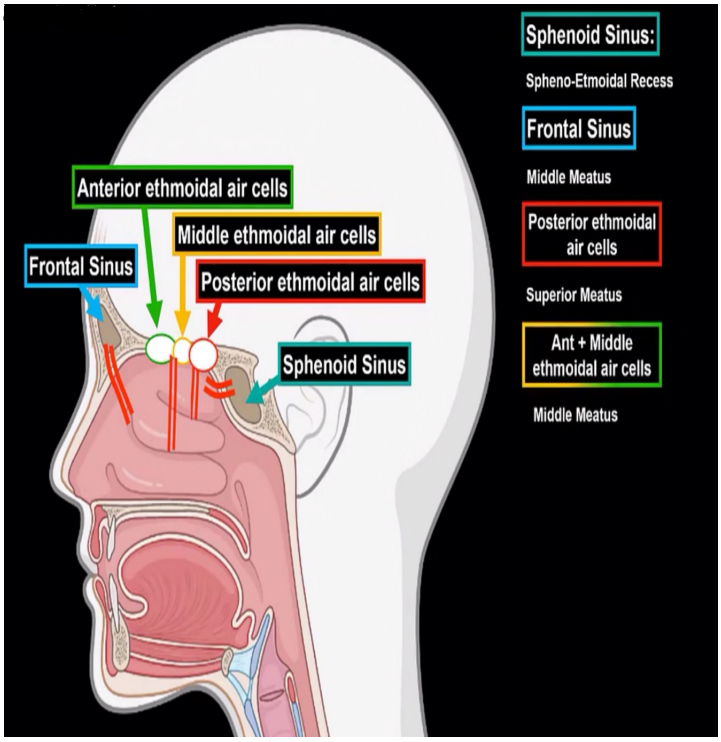

Frontal Sinus

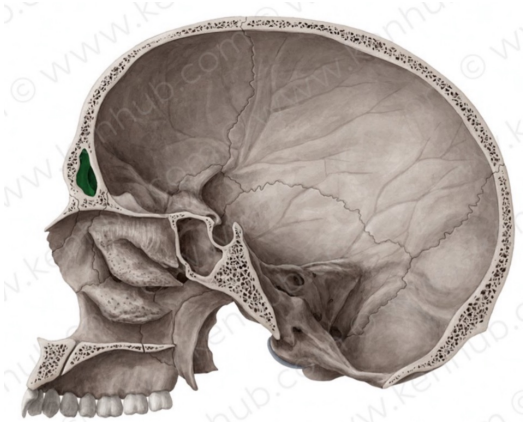

Sphenoidal sinus

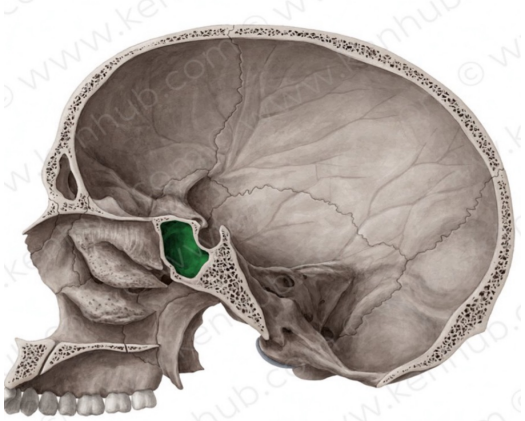

Superior Conchae

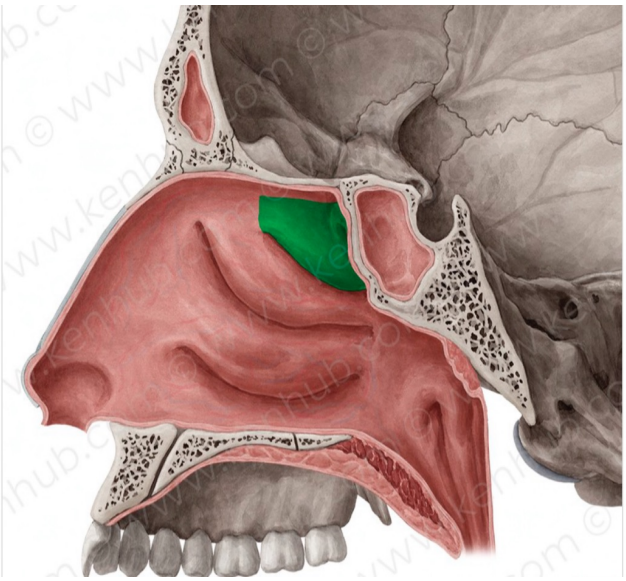

Middle Conchae

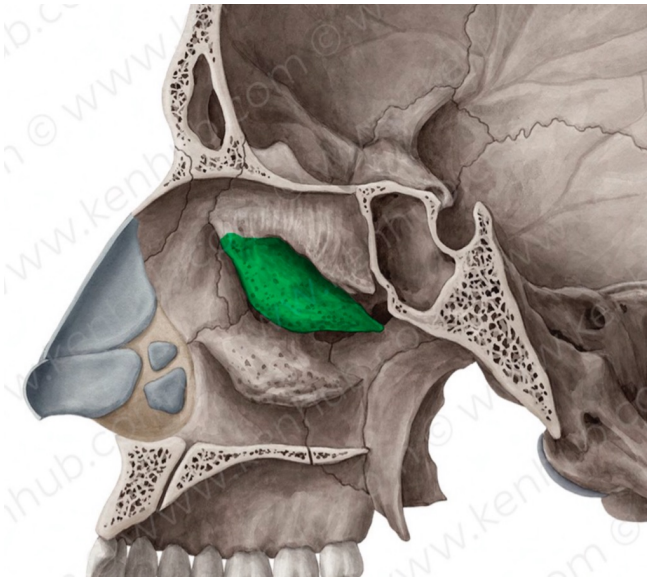

Inferior Choncae

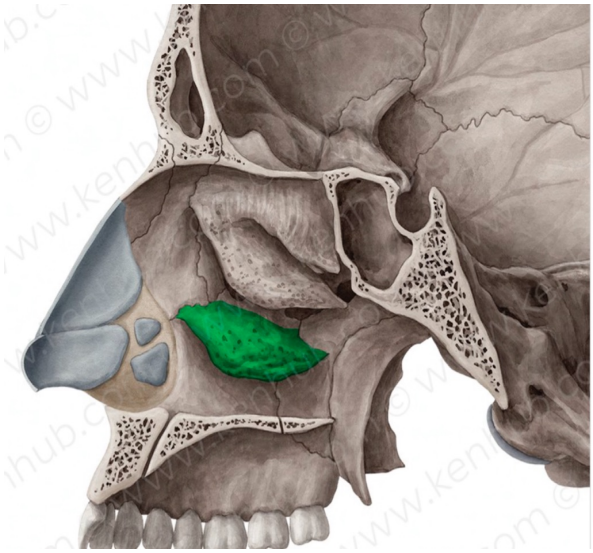

Sphenoethmoidal recess

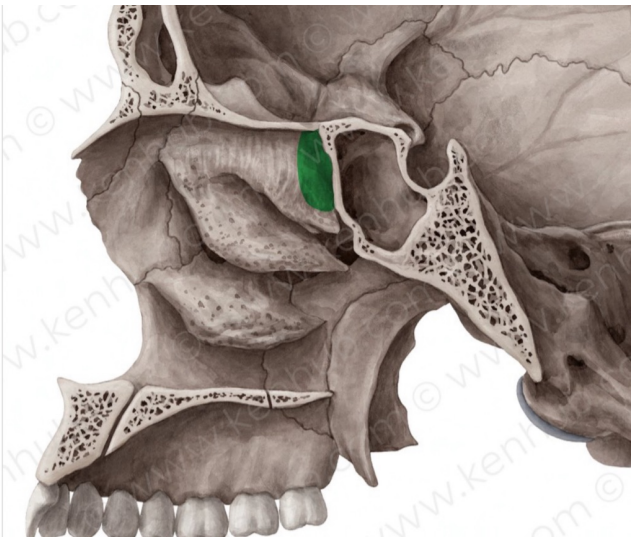

Superior Meatus

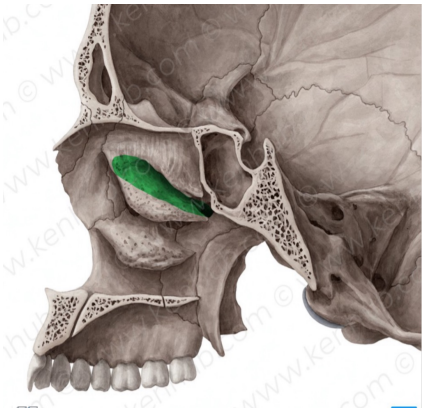

Middle Meatus

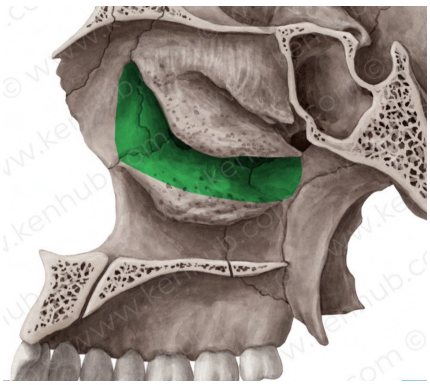

Inferior Meatus

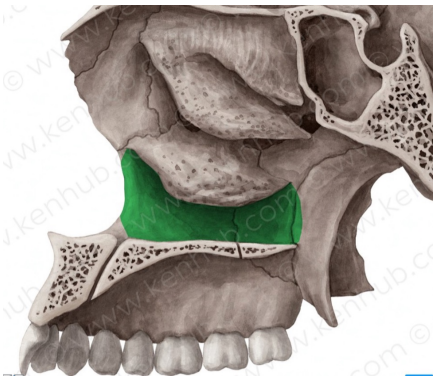

Nasal Vestibule

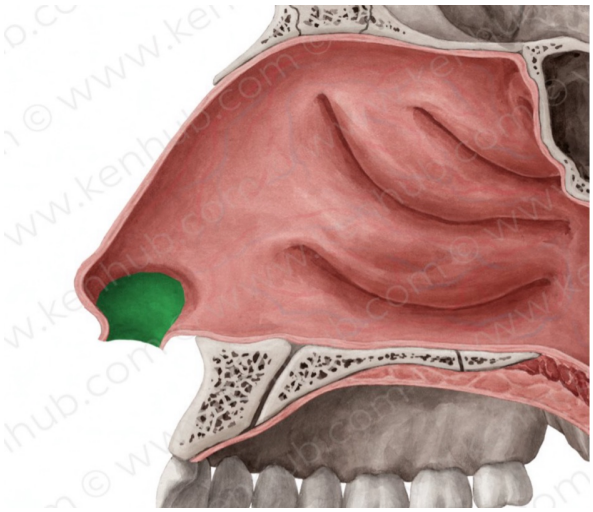

Nasal septum

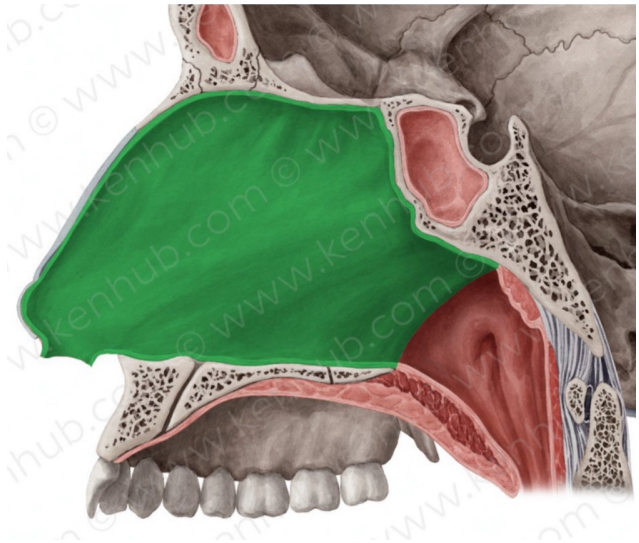

Cartilage of the septum

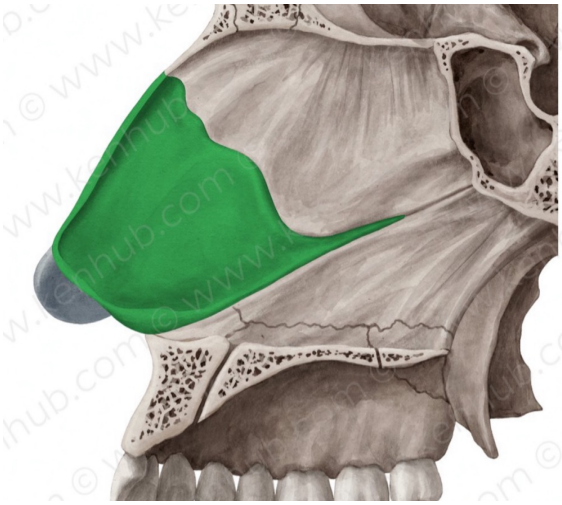

Perpendicular plate of ethmoid bone

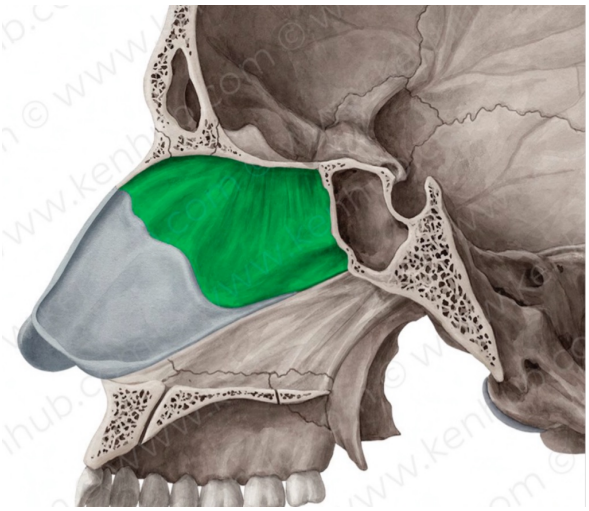

Hard palate

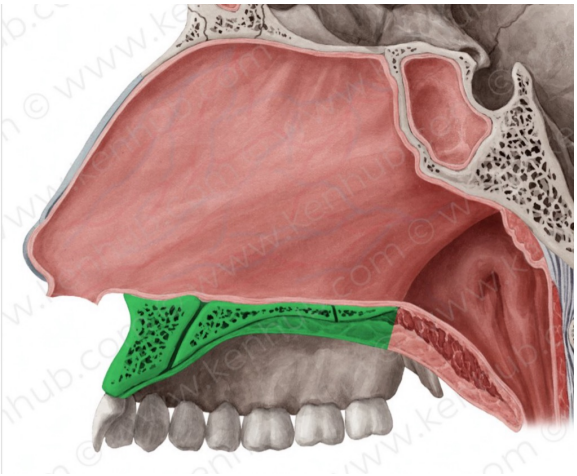

Soft palate

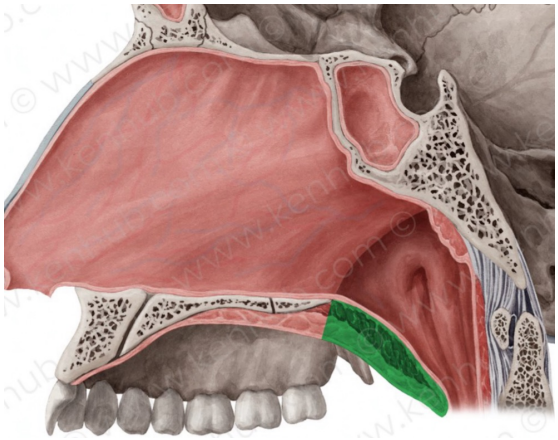

Palatine process of Maxilla

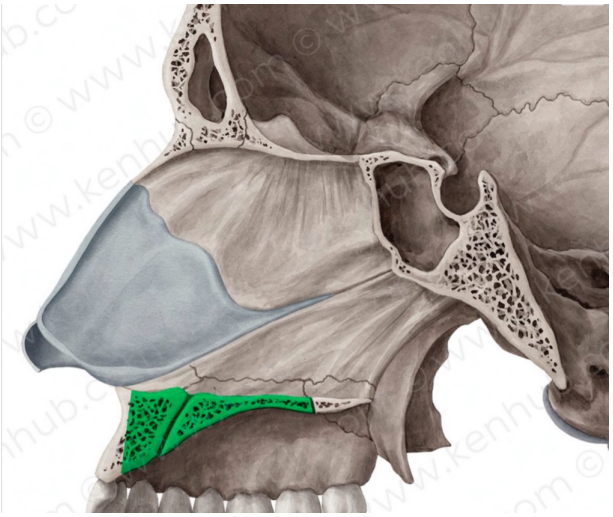

Cribriform plate of ethmoid

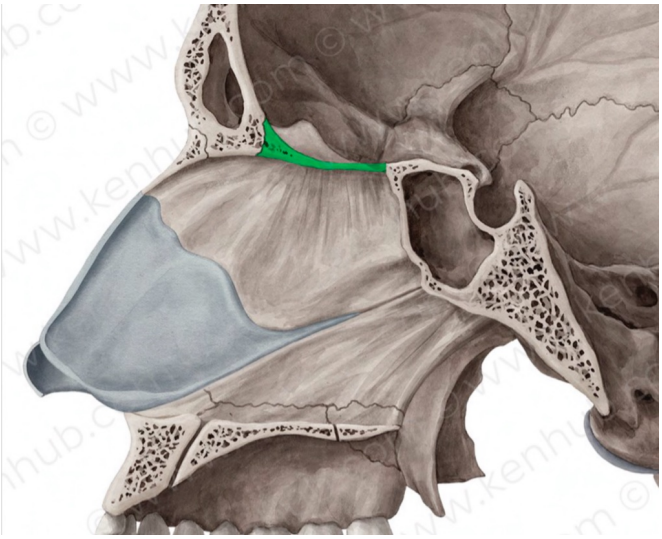

Coana

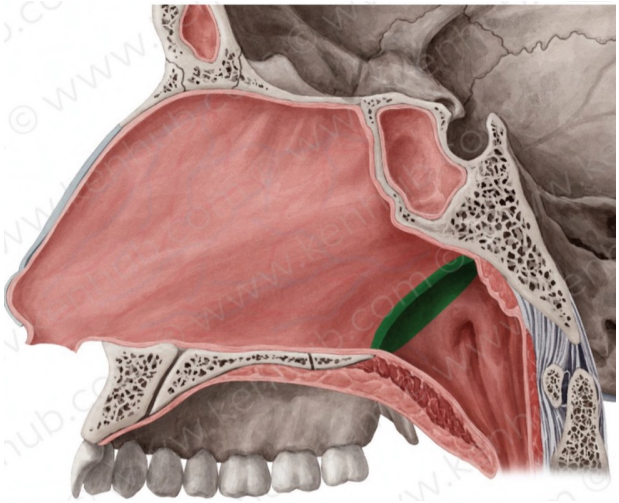

Palatine bone

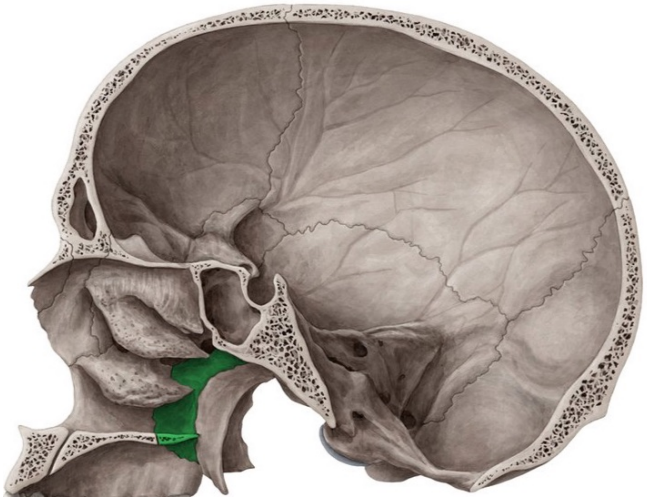

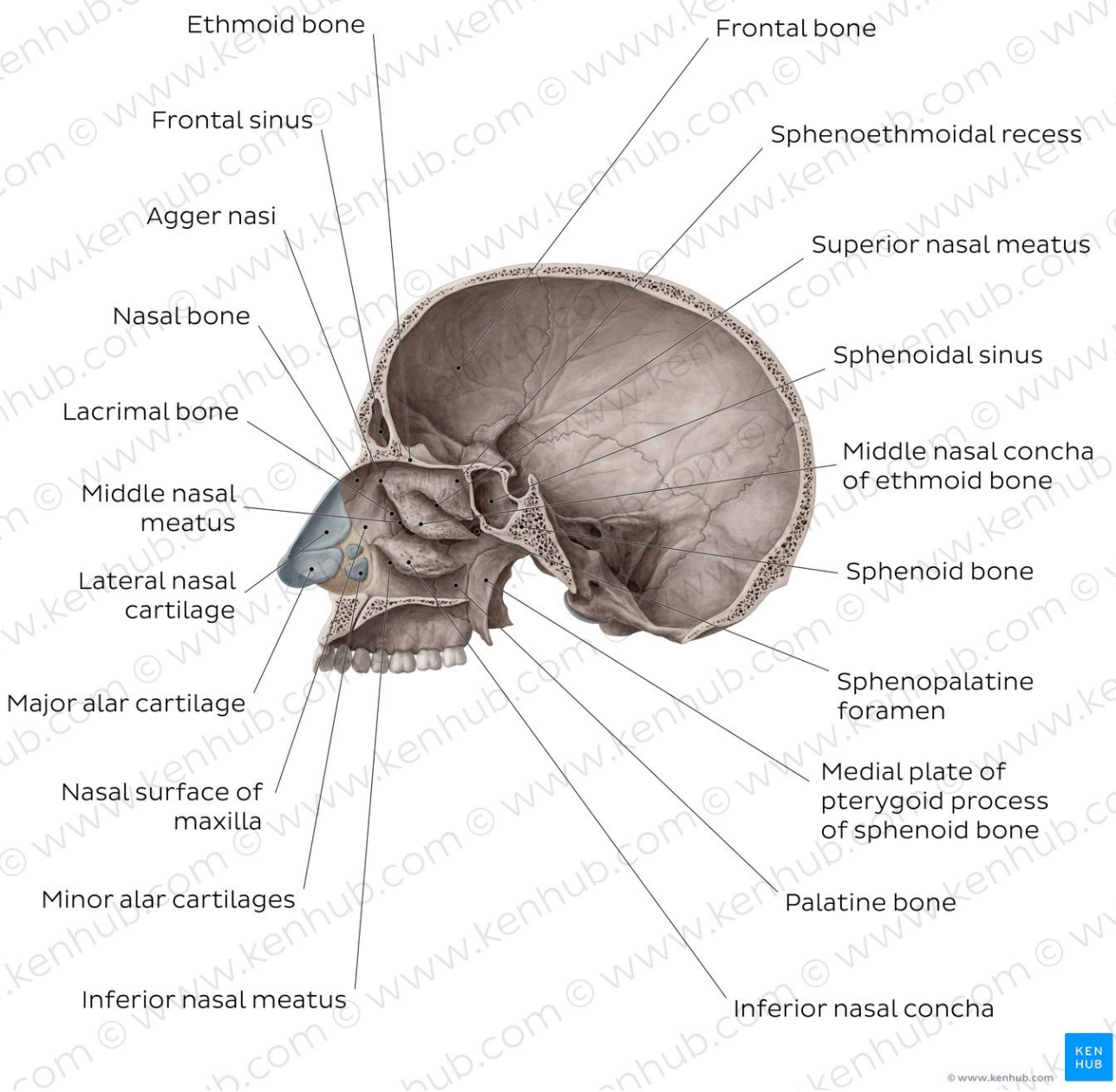

Done by : leen Farouq