

Somatic Sensations: General Organization; The Tactile and Position Senses- L2-3

Faisal I. Mohammed, MD, PhD

Objectives

- List the type of mechanoreceptive sensations and its receptors
- Describe the two pathways for its transmission (dorsal column and anterolateral spinothalamic tracts)
- Follow these pathway to the cortex
- Differentiate the two pathways

Classification of Somatic Sensations

⊕ Mechanoreceptive - stimulated by mechanical displacement

⊕ **tactile**

⊕ touch

⊕ pressure

⊕ vibration

⊕ tickle and itch

⊕ **position or proprioceptive**

⊕ static position

⊕ rate of change

Classification of Somatic Sensations

- ⊕ Thermoreceptive

 - ⊕ detect heat and cold

- ⊕ Nociceptive

 - ⊕ detect pain and are activated by any factor that damages tissue

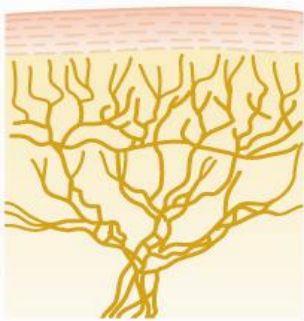Tactile Receptors

- ⊕ Free nerve endings ($A\delta$ and C fibers)
 - ⊕ detect touch and pressure
 - ⊕ found everywhere in the skin and other tissues
- ⊕ Meissner's corpuscles ($A\beta$)
 - ⊕ rapidly adapting (within a fraction of a second) and detect movement of light objects over skin
 - ⊕ found on nonhairy skin (glabrous skin), fingertips and lips
- ⊕ Merkel's discs ($A\beta$)
 - ⊕ respond rapidly at first and then slowly adapt, detect the "steady state"
 - ⊕ found on hairy as well a glabrous (non hairy) skin

Tactile Receptors

- ⊕ Hair end organ
 - ⊕ adapts rapidly and detects movement over the body
- ⊕ Ruffini's end organ
 - ⊕ slowly adapting and respond to continual deformation of the skin and joint rotation
- ⊕ Pacinian corpuscle
 - ⊕ very rapidly adapting and is stimulated only by rapid movement
 - ⊕ detects vibration and other rapid changes in the skin

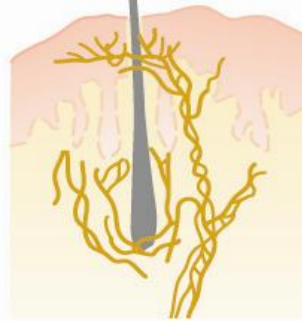
Types of Sensory Receptors



Free nerve endings



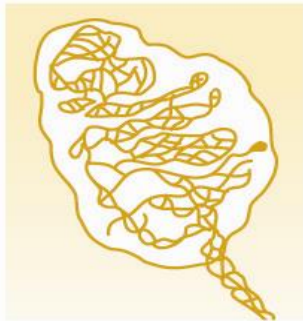Expanded tip receptor




Tactile hair



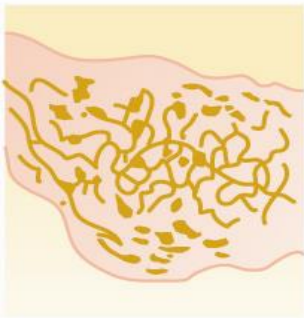
Pacinian corpuscle



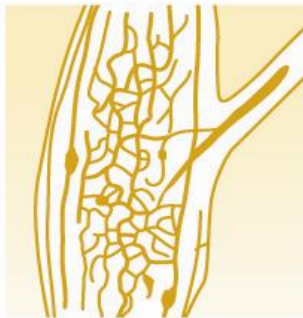Meissner's corpuscle



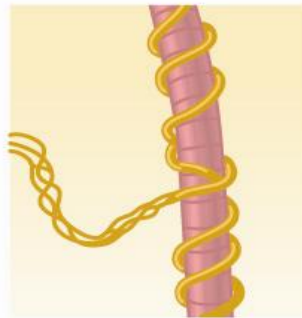
Krause's corpuscle



Ruffini's end-organ

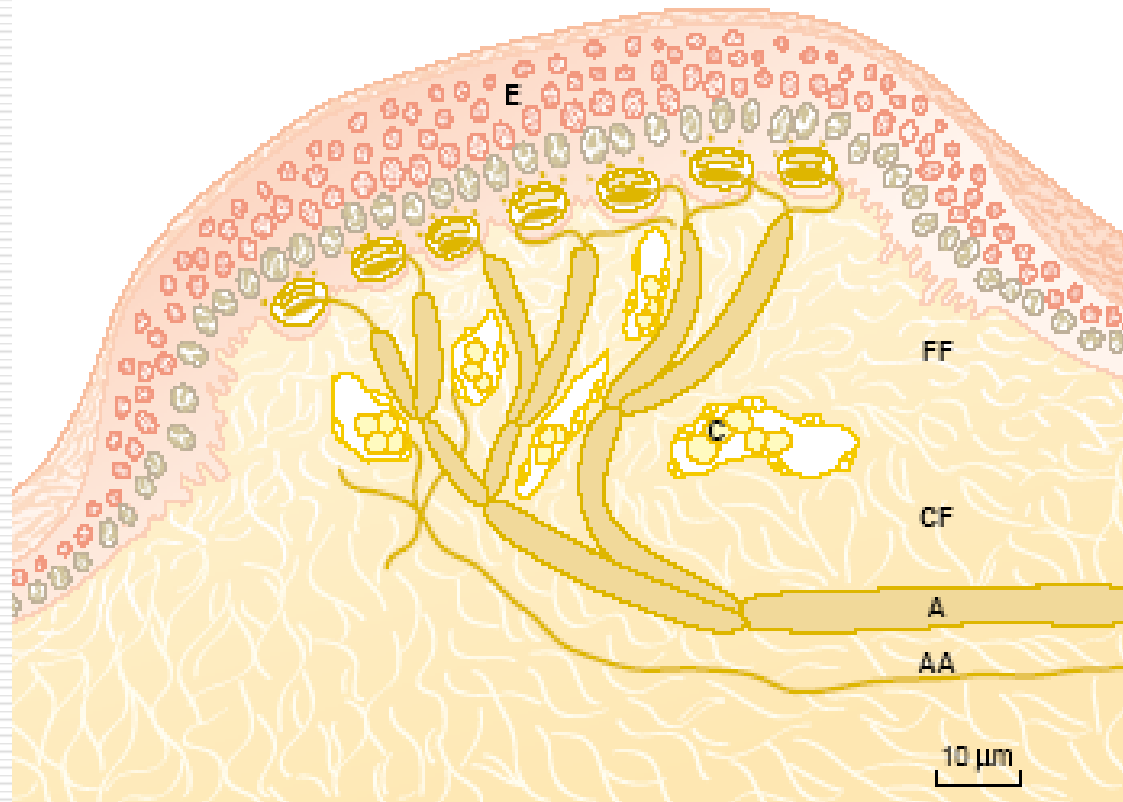


Golgi tendon apparatus



Muscle spindle

Merckel's disc for mechanical sensation (Touch in hairy skin)



Iggo dome receptors

Figure 47-1

Iggo dome receptor. Note the multiple numbers of Merkel's discs connecting to a single large myelinated fiber and abutting tightly the undersurface of the epithelium. (From Iggo A, Muir AR: The structure and function of a slowly adapting touch corpuscle in hairy skin. *J Physiol* 200: 763, 1969.)

Tactile Sense Transmission

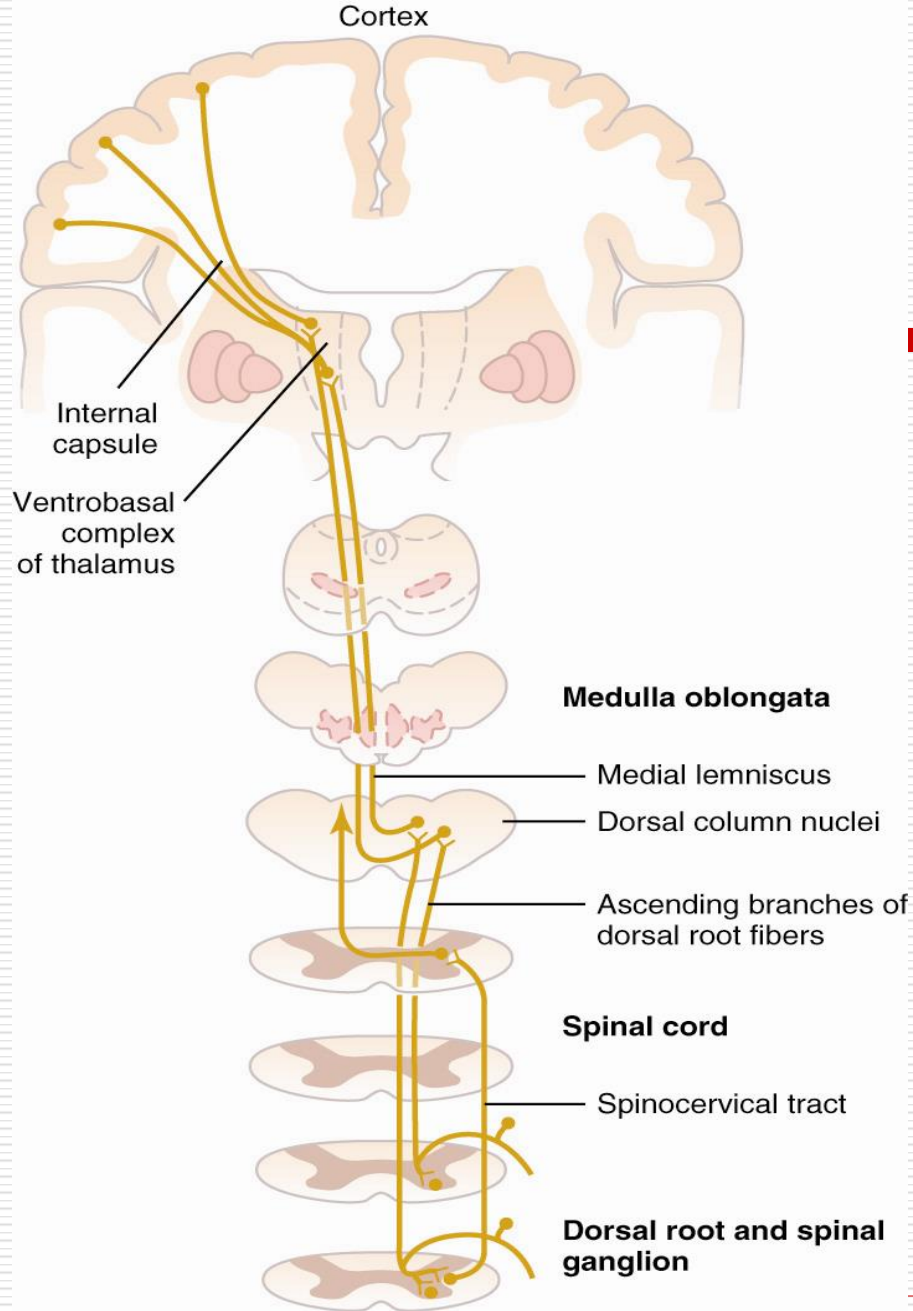
- ⊕ Meissner's corpuscles, hair receptors, Pacinian corpuscles and Ruffini's end organs transmit signals in type $A\beta$ nerve fibers at 30-70 m/sec.
- ⊕ Free nerve endings transmit signals in type $A\delta$ nerve fibers at 5-30 m/sec, some by type C unmyelinated fibers at 0.5-2 m/sec.
- ⊕ The more critical the information the faster the rate of transmission.

Pathways for the Transmission of Sensory Information

- ⊕ Almost all sensory information enters the spinal cord through the dorsal roots of the spinal nerves.
- ⊕ Two pathways for sensory information
 - ⊕ dorsal column-medial lemniscal system
 - ⊕ anterolateral system

Dorsal Column System

- ⊕ Contains large myelinated nerve fibers for fast transmission (30-110 m/sec).
- ⊕ High degree of spatial orientation maintained throughout the tract
- ⊕ Transmits information rapidly and with a high degree of spatial and temporal fidelity (faithfulness) (i.e., discrete types of mechanoreceptor information).
- ⊕ *Fine touch, vibration, position, fine pressure*



The Dorsal Column-Medial Lemniscal Pathway System

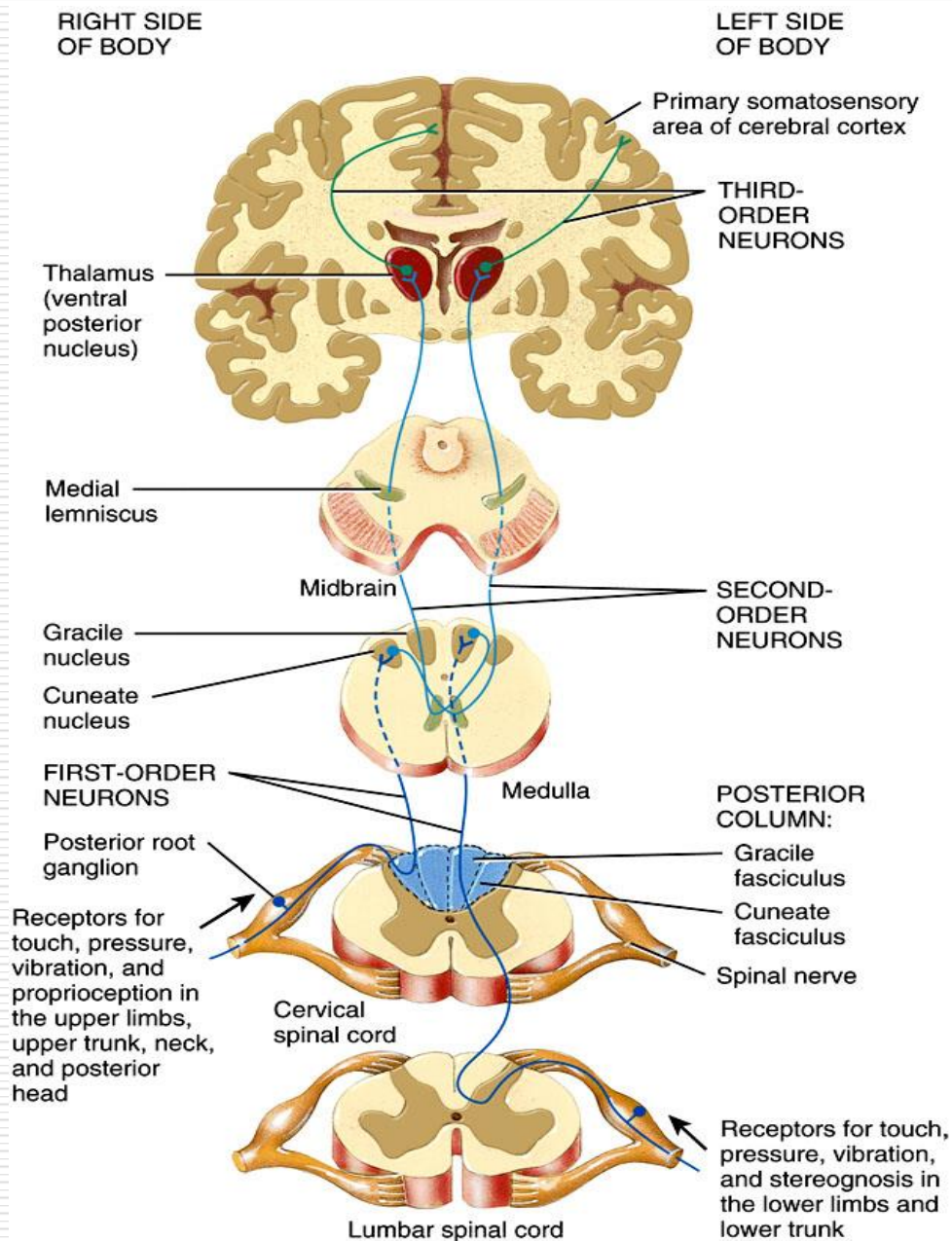
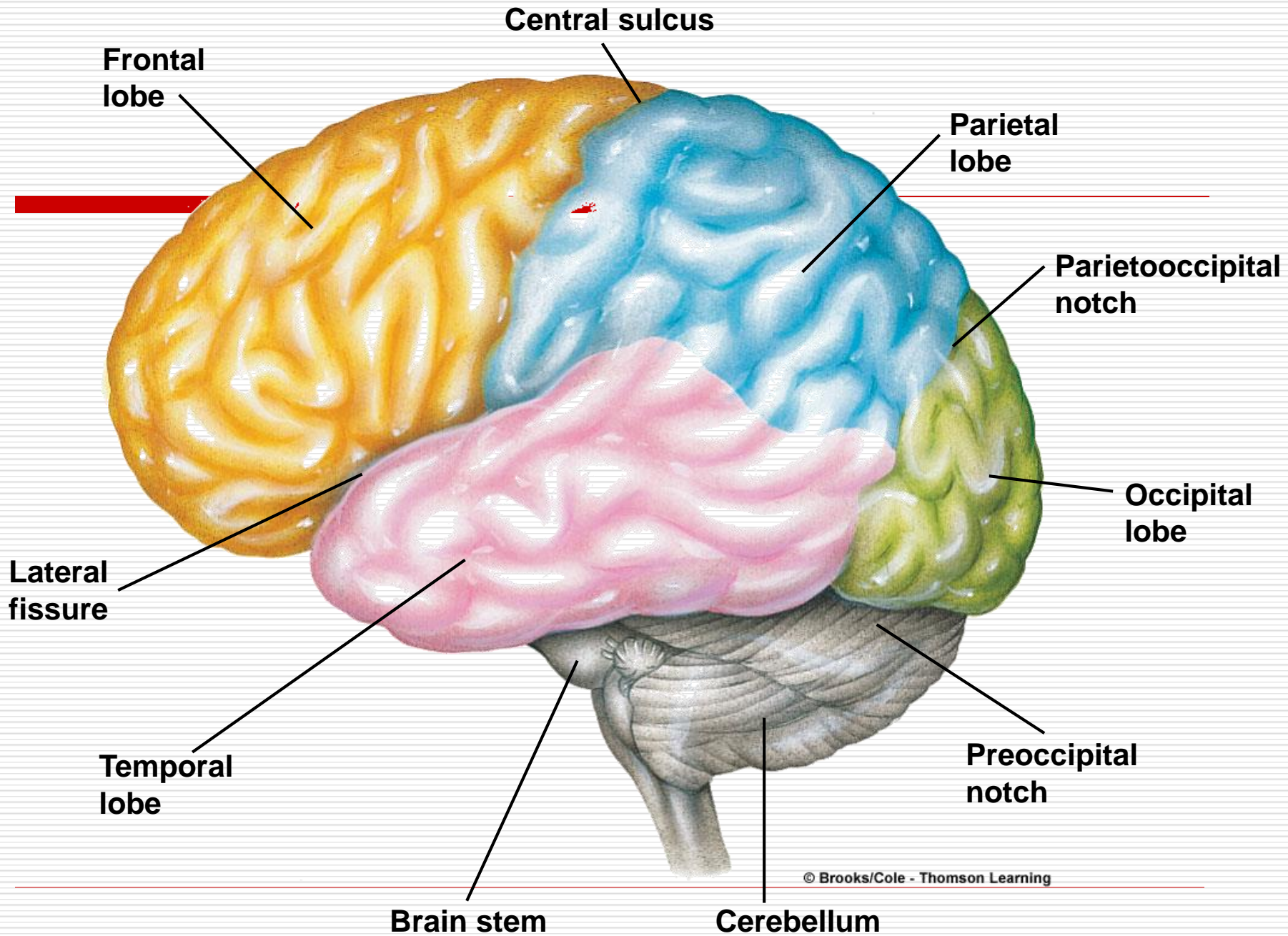


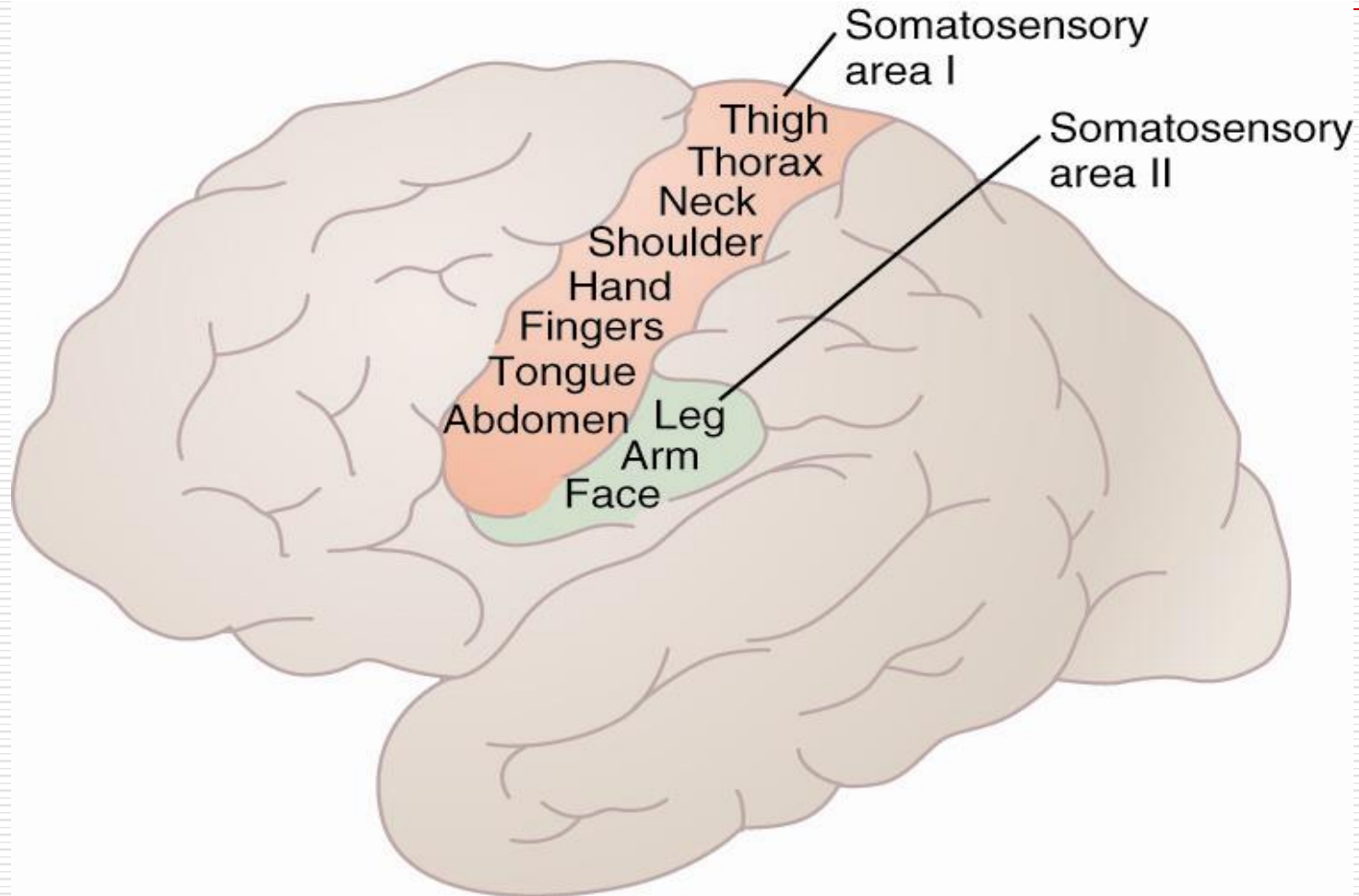
Figure 16.05 Tortora - PAP 12/e
 Copyright © John Wiley and Sons, Inc. All rights reserved.

The posterior column-medial lemniscus pathway

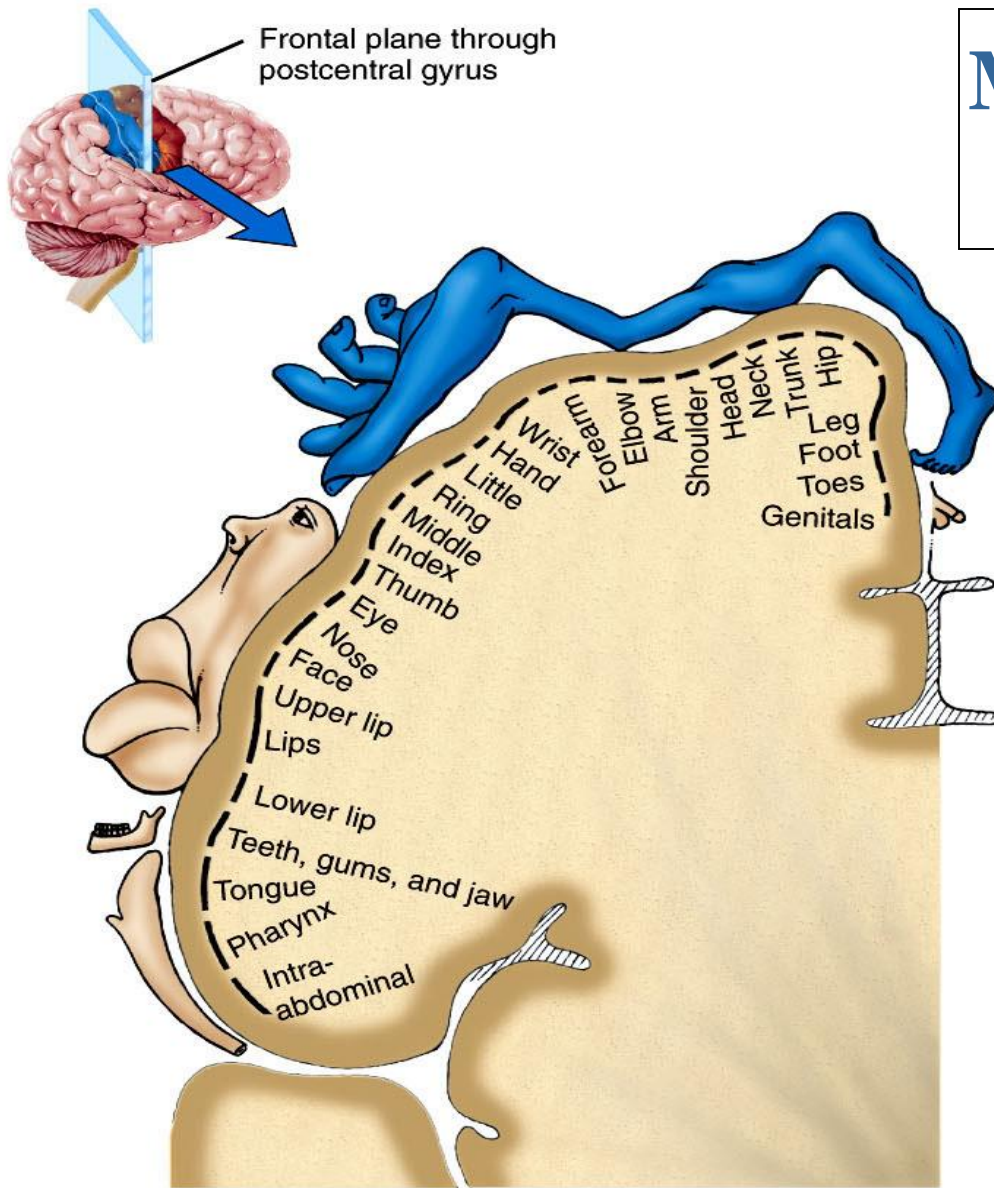
- ❖ Conveys nerve impulses for fine touch (well localized), fine pressure, vibration, weight discrimination, two-points discrimination, stereognosis, conscious proprioception from the limbs, trunk, neck, and posterior head to the postcentral gyrus of the cerebral cortex.



The Somatosensory Cortex

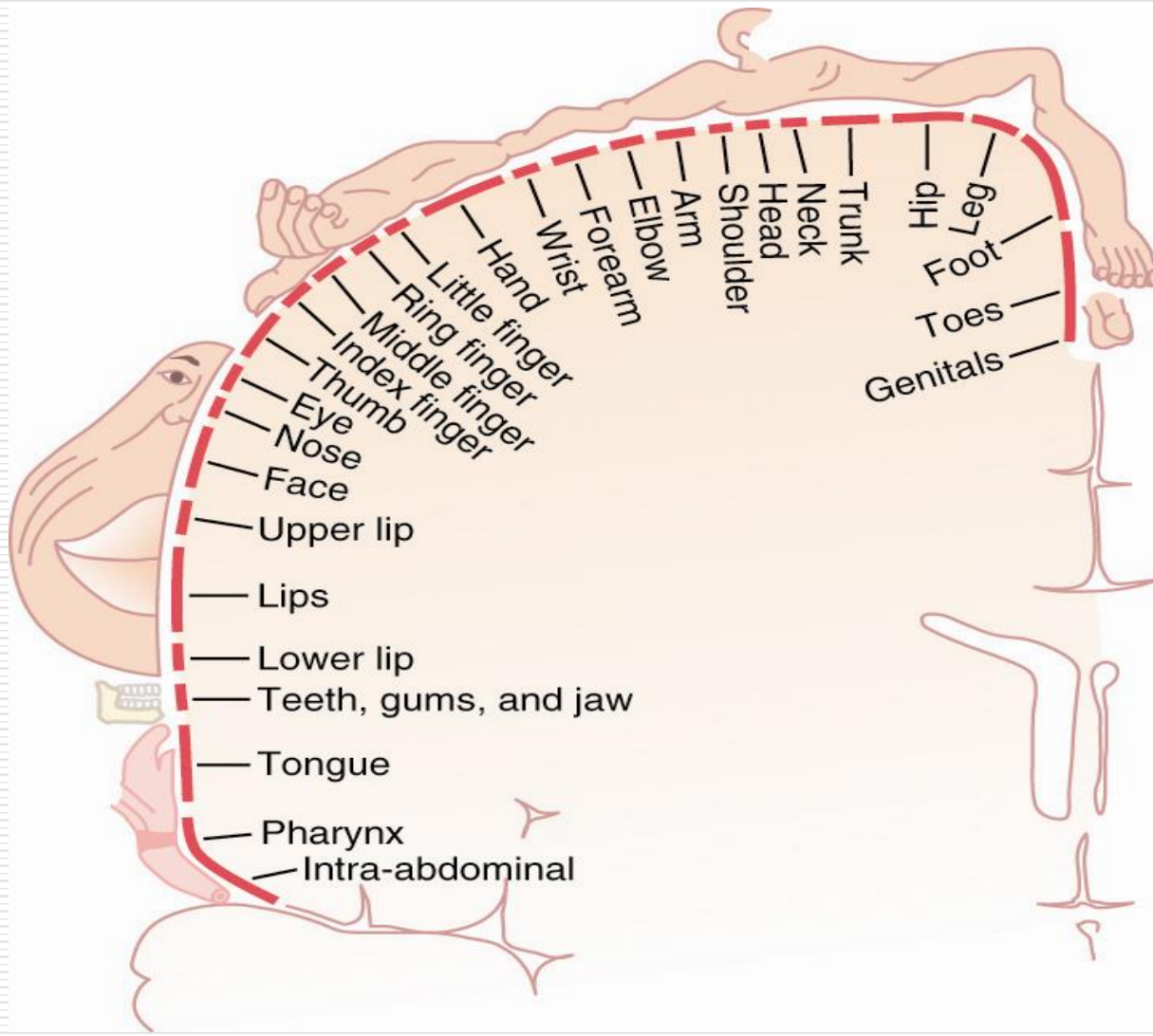


Mapping of the Primary Somatosensory Area

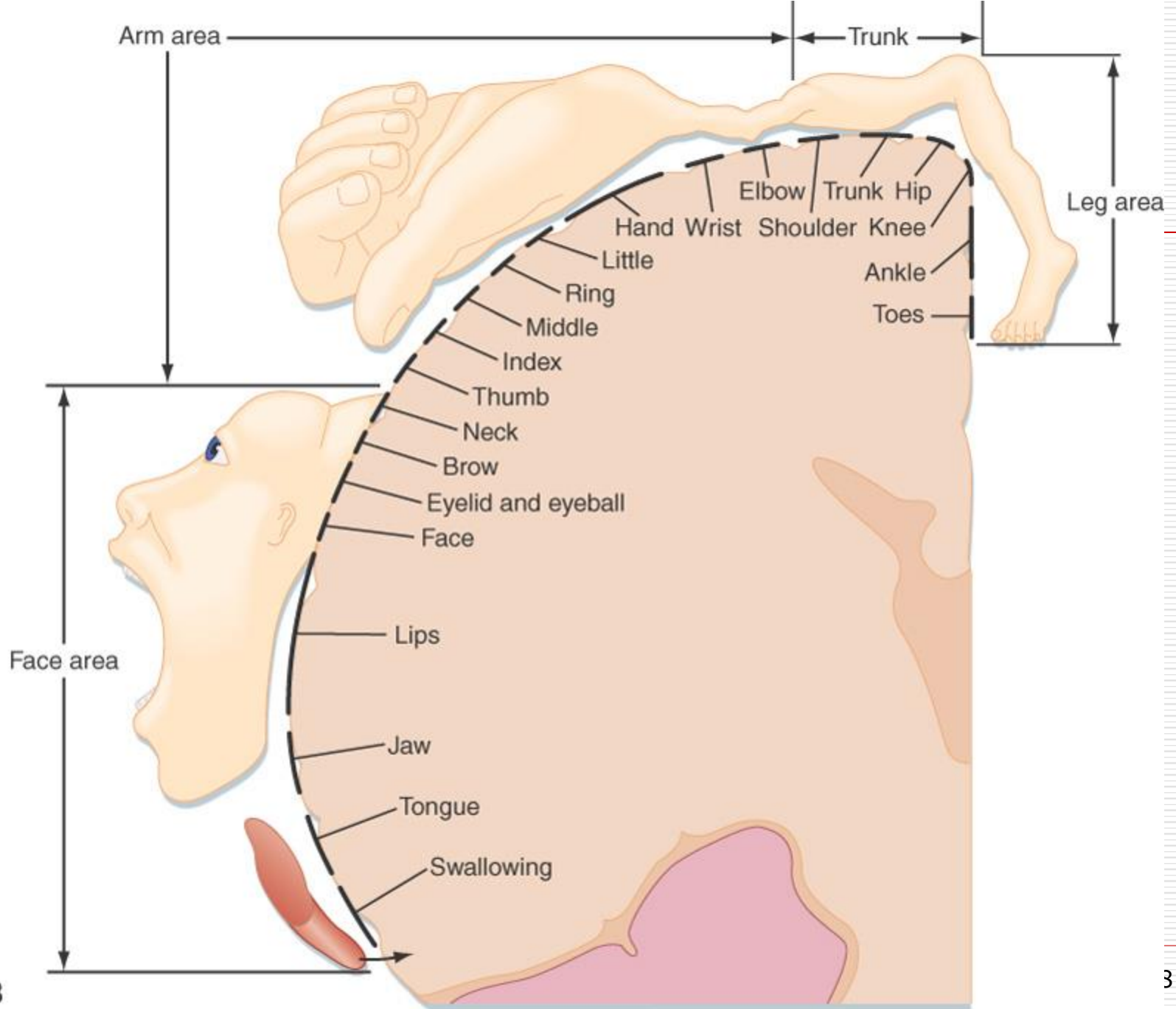


(a) Frontal section of primary somatosensory area in right cerebral hemisphere

- Mapping of the postcentral gyrus.
- Size of the cortical region representing a body part depends on the density of the receptors on that part and sensory impulses received from that part.

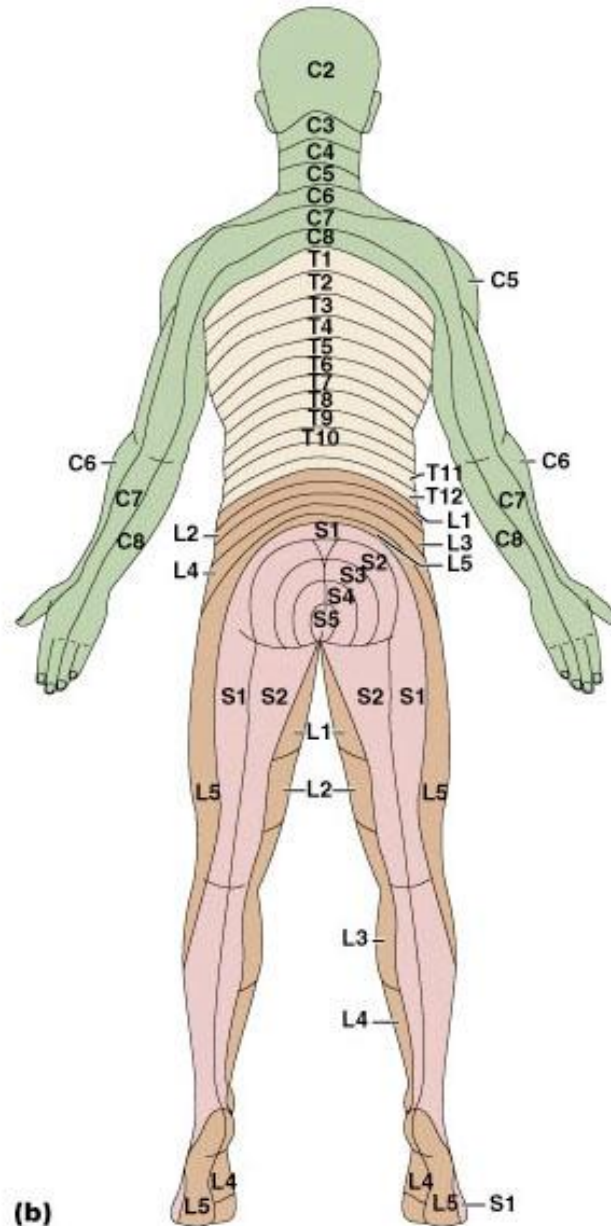
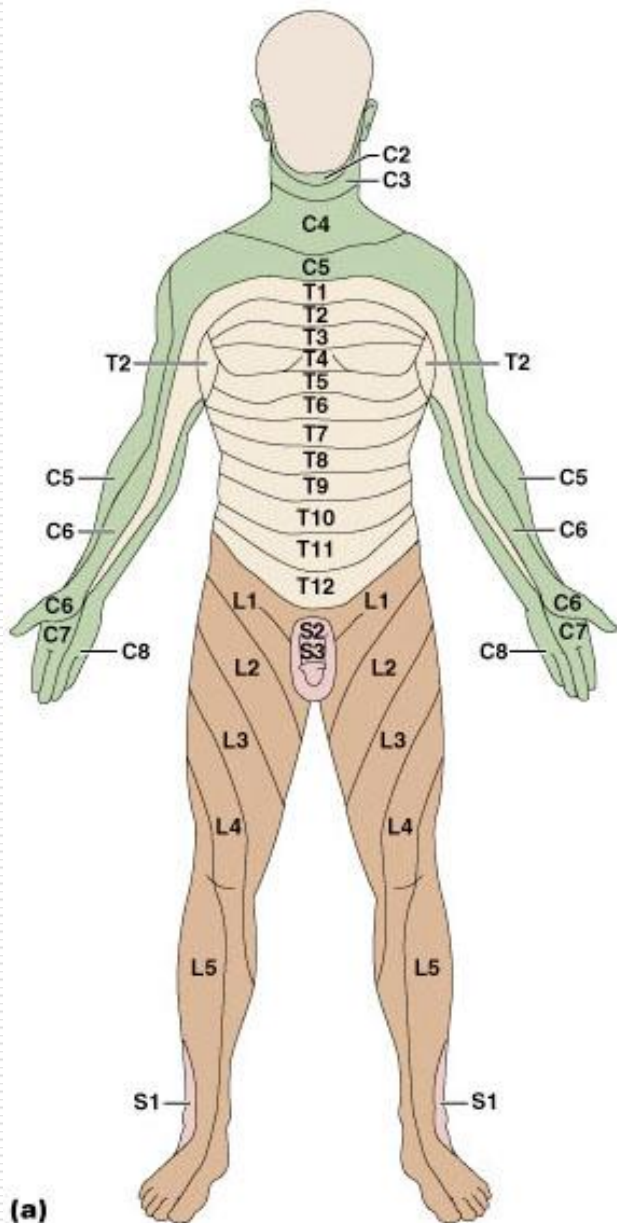


Somatic Sensory Cortex



B

Dermatomes

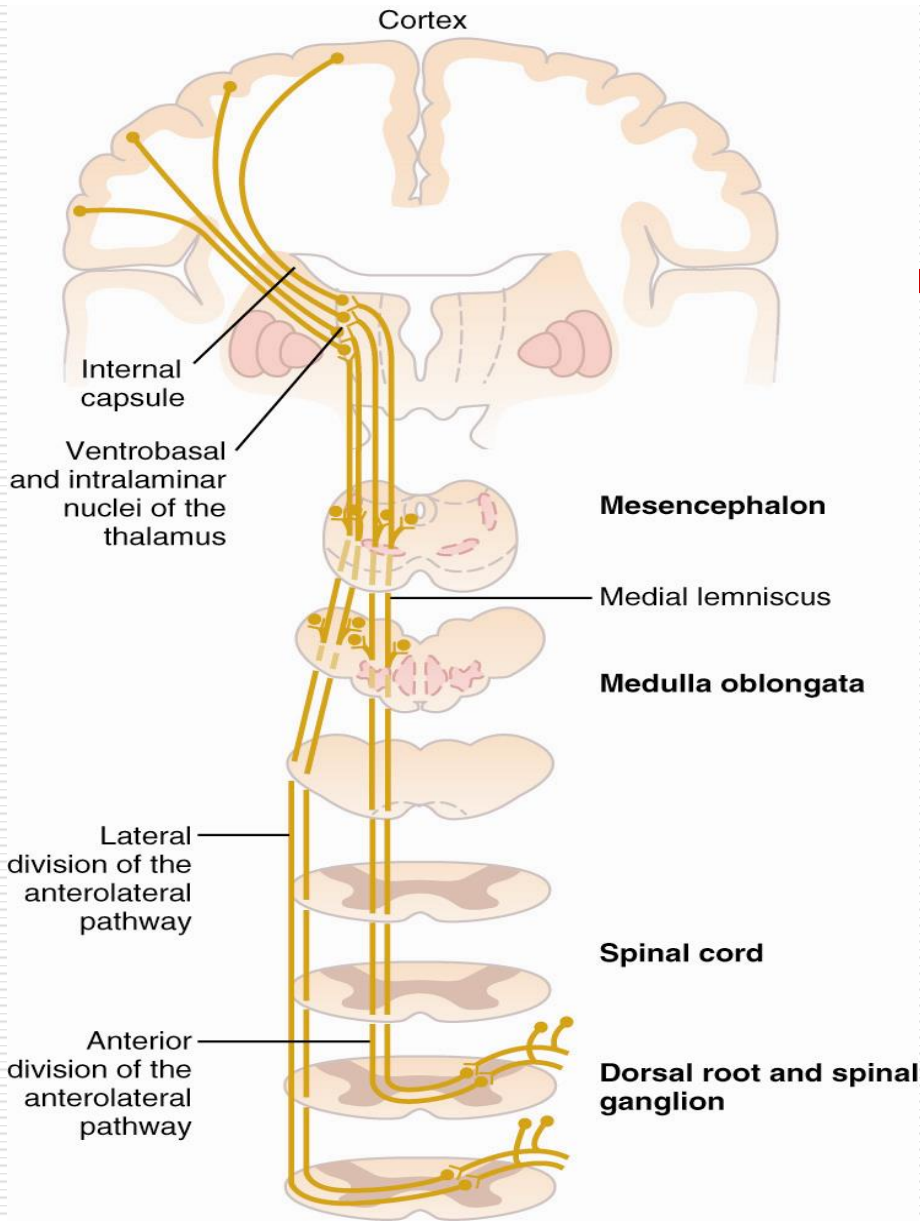


Somatic Sensations: General Organization; The Tactile and Position Senses- L8-

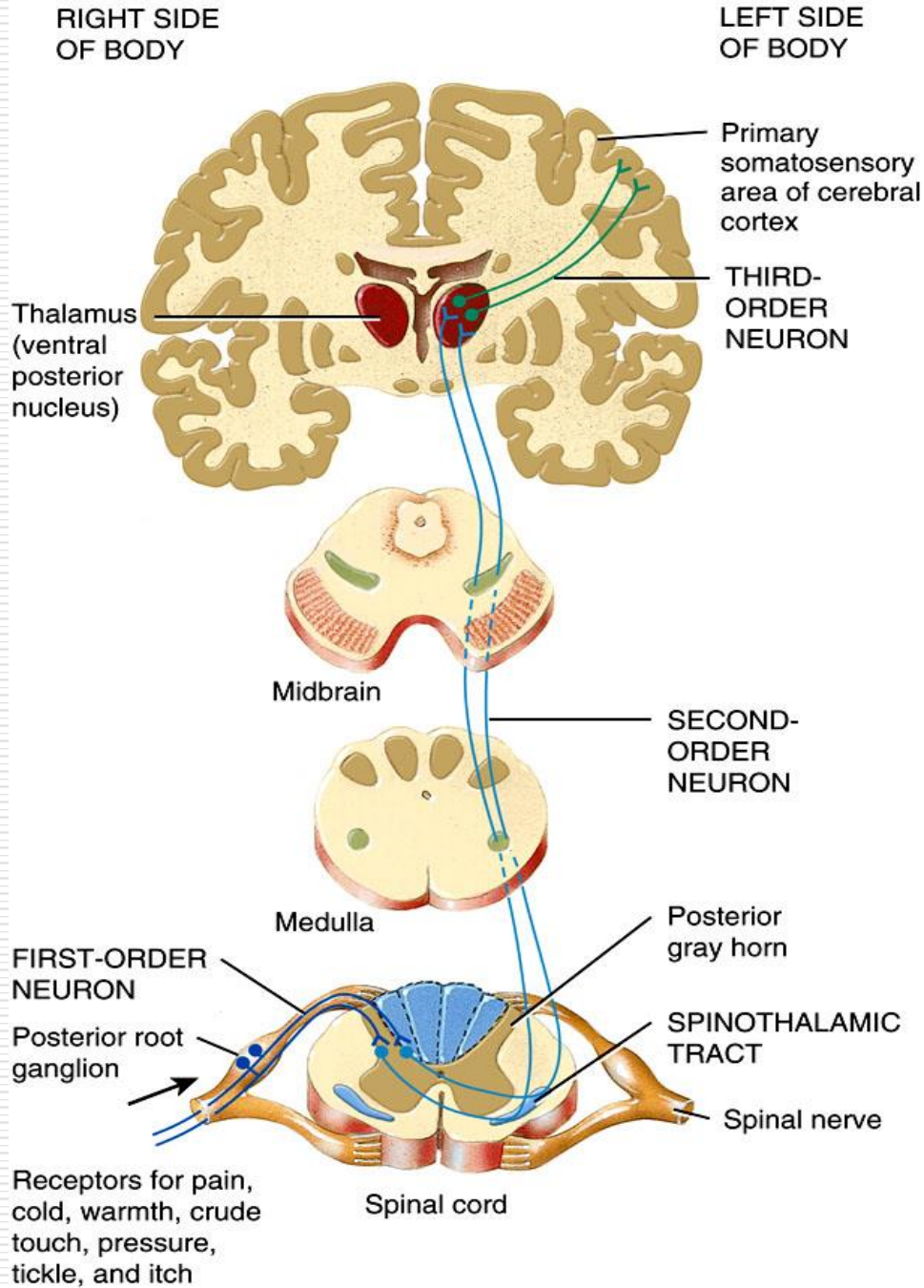
Faisal I. Mohammed, MD, PhD

Anterolateral System (Spinothalamic pathway system)

- ⊕ Smaller myelinated and unmyelinated fibers for slow transmission (0.5-40 m/sec)
- ⊕ Low degree of spatial and temporal orientation
- ⊕ Transmits a broad spectrum of modalities
- ⊕ *Pain, thermal sensations, crude touch and pressure, tickle and itch, sexual sensations.*



Anterolateral System (Spinothalamic pathway)



The Anterolateral (spinothalamic) pathway

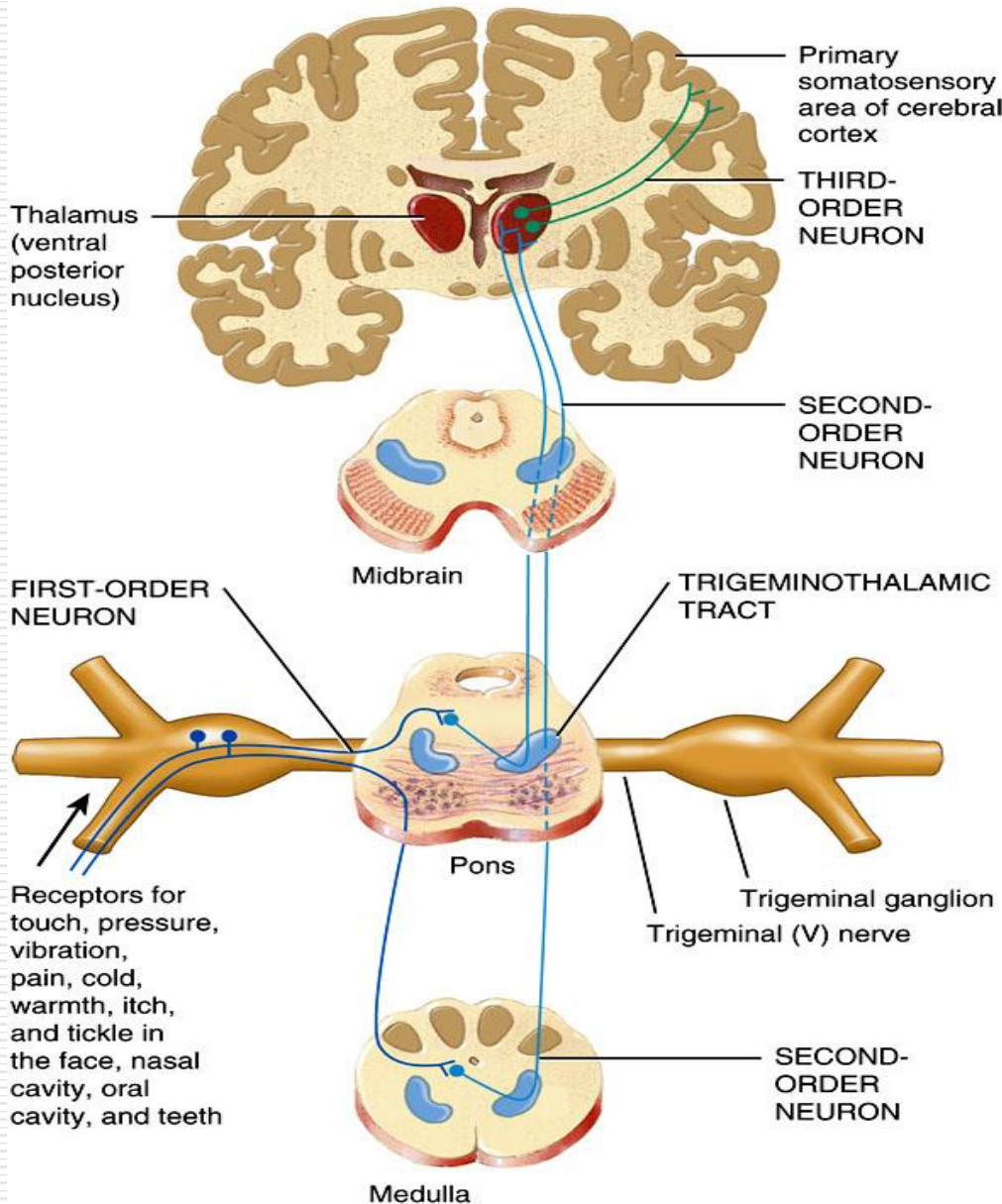
- Conveys nerve impulses for crude touch (poorly localized), crude pressure, pain, cold, warmth, itch, and tickle from the limbs, trunk, neck, and posterior head to the postcentral gyrus of the cerebral cortex.

Comparison between the two systems

- ⊕ Dorsal column is well localized, compared to anterolateral
- ⊕ Dorsal column has better temporal and spatial faithfulness (i.e speed of transmission 30-120 m/sec compared to 8-40 m/sec for the anterolateral)
- ⊕ Dorsal column has better intensity gradation (more than 100 compared to less than 20 for anterolateral)
- ⊕ Repetitive stimuli are only confine to dorsal column tracts.
- ⊕ Anterolateral tracts transmit broad spectrum modalities of sensation

RIGHT SIDE
OF BODY

LEFT SIDE
OF BODY



Trigeminothalamic Pathway

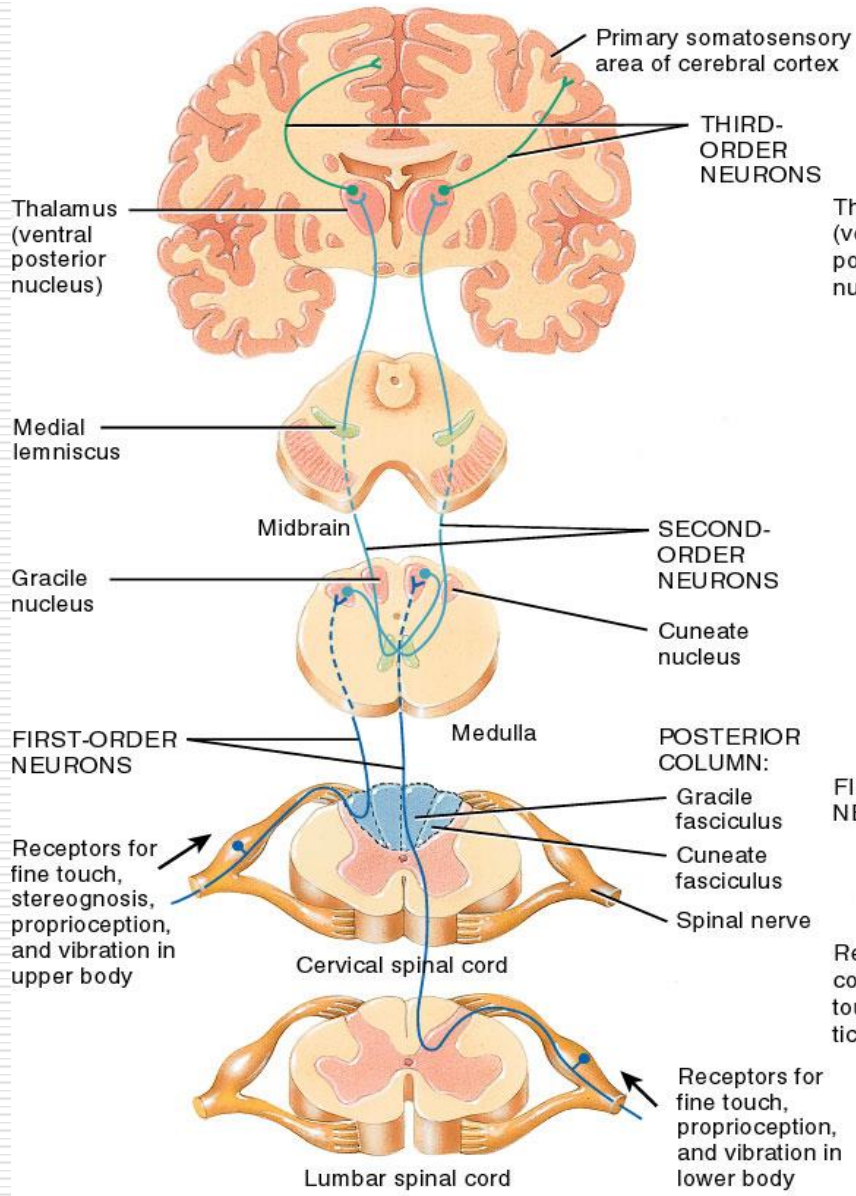
Conveys nerve impulses for most somatic sensations from the face, nasal cavity, oral cavity and teeth to the cerebral cortex. It is synonymous to both sensory systems

RIGHT SIDE OF BODY

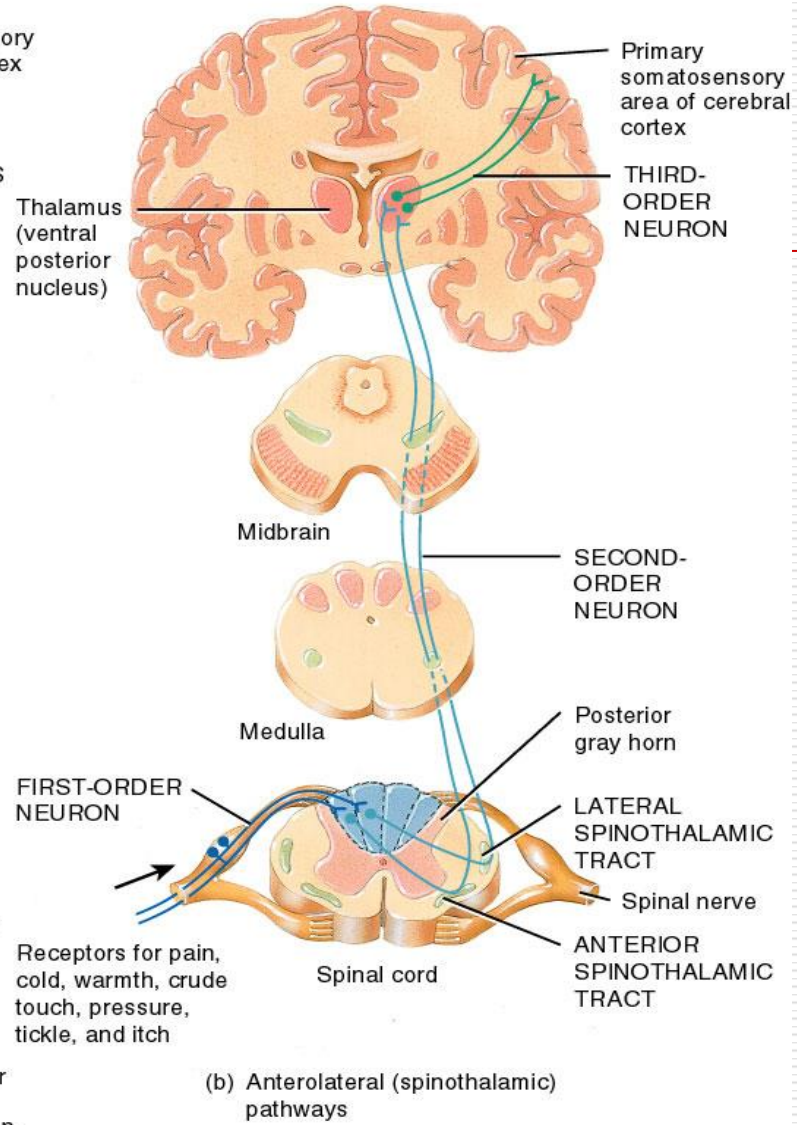
LEFT SIDE OF BODY

RIGHT SIDE OF BODY

LEFT SIDE OF BODY



(a) Posterior column-medial lemniscus pathway



(b) Anterolateral (spinothalamic) pathways

Somatic Sensory Cortex

- ⊕ Located in the *postcentral gyrus*
- ⊕ Highly organized distinct spatial orientation
- ⊕ Each side of the cortex receives information from the opposite side of the body
- ⊕ Unequal representation of the body
 - ⊕ lips have greatest area of representation followed by the face and the thumb
 - ⊕ trunk and lower body have the least area

Cellular Organization of the Cortex

- ⊕ Six separate layers of neurons with layer I near the surface of the cortex and layer VI deep within the cortex.
- ⊕ *Incoming signals* enter *layer IV* and spread both up and down.
- ⊕ *Layers I and II* receive *diffuse input* from lower brain centers.

Cellular Organization of the Cortex...cont

- ⊕ *Layer II and III neurons send axons to closely related portion of the cortex presumably for communicating between similar areas.*
- ⊕ *Layer V and VI send axons to more distant parts of the nervous system, layer V to the brainstem and spinal cord, layer VI to the thalamus.*

Diffuse lower input



Related brain areas



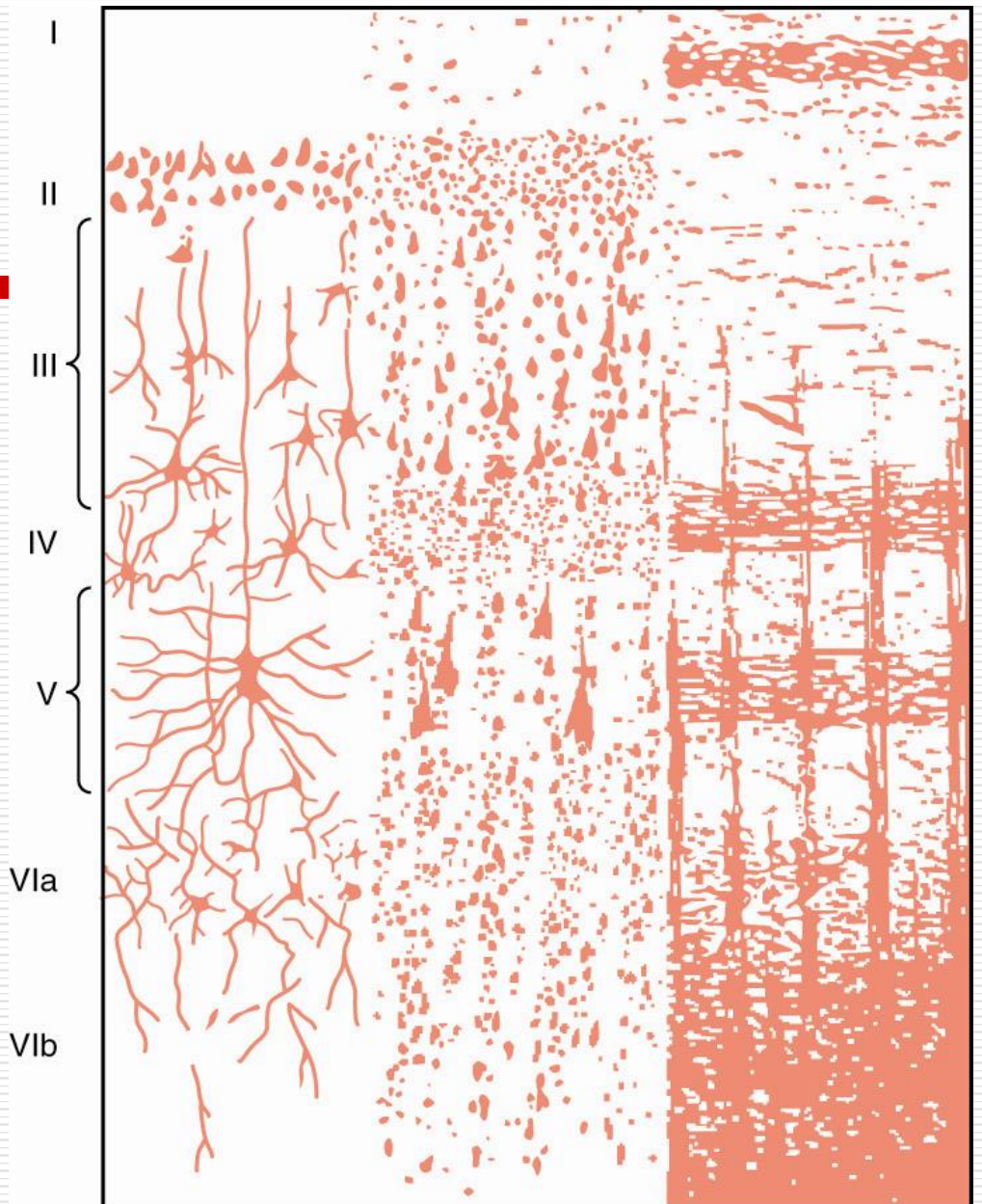

Incoming signals



To brainstem and cord



To thalamus



Cellular Organization of the Cortex...cont

- ⊕ Within the layers the neurons are also arranged in columns.
- ⊕ Each column serves a specific sensory modality (i.e., stretch, pressure, touch).
- ⊕ Different columns interspersed among each other.
 - ⊕ interaction of the columns occurs at different cortical levels which allows the beginning of the analysis of the meaning of the sensory signals

Function of the Somatic Sensory Cortex

- ⊕ Destruction of *somatic area I* results in:
 - ⊕ loss of discrete localization ability
 - ⊕ inability to judge the degree of pressure
 - ⊕ inability to determine the weight of an object
 - ⊕ inability to determine the shape or form of objects, called *astereognosis*
 - ⊕ inability to judge texture

Somatic Association Areas

- ⊕ Located behind the somatic sensory cortex in the parietal area of the cortex.
- ⊕ Association areas receive input from somatic sensory cortex, ventrobasal nuclei of the thalamus, visual and auditory cortex.
- ⊕ Function is to decipher sensory meaning.
- ⊕ Loss of these areas results in the inability to recognize complex objects and loss of self (Amorphosynthesis)

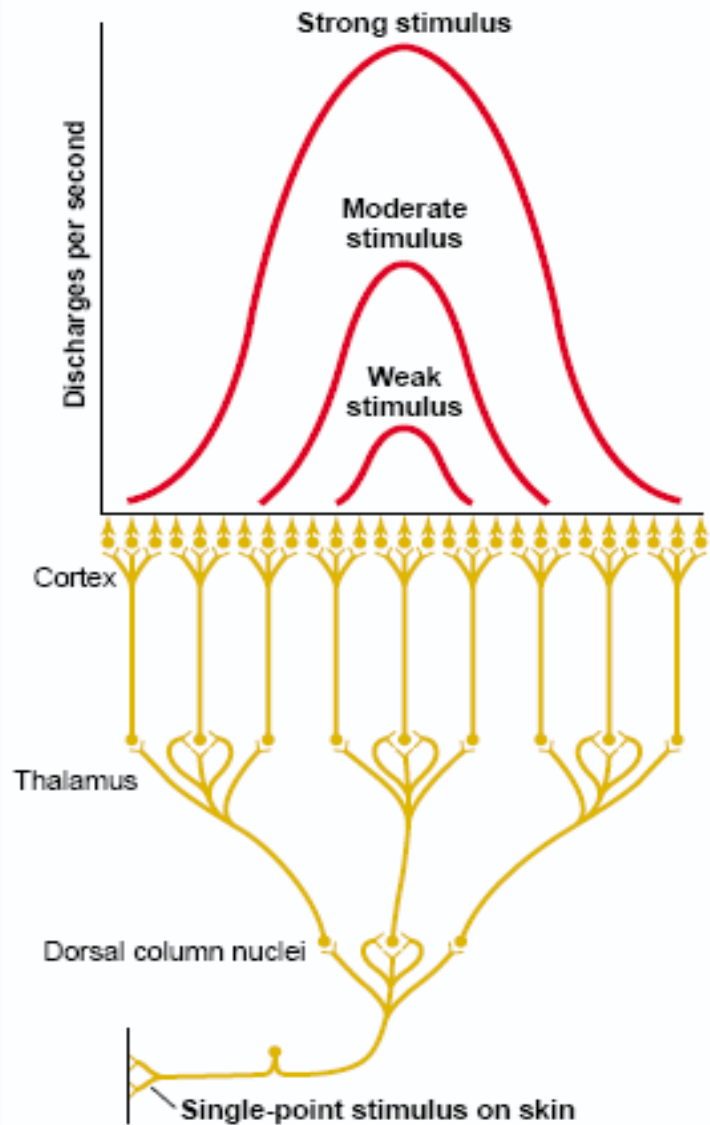
Special Aspects of Sensory Function

- ⊕ Thalamus has some ability to discriminate tactile sensation.
- ⊕ Thalamus has an important role in the perception of pain and temperature.

Special Aspects of Sensory Function...cont

- ⊕ Corticofugal fibers
 - ⊕ fibers from the cortex to the sensory relay areas of thalamus, medulla and spinal cord
 - ⊕ these fibers are inhibitory, they can suppress the sensory input
 - ⊕ function to decrease the spread of a signal and sharpen the degree of contrast and adjust the sensitivity of the system

Coding for the intensity of the stimulus as perceived at the cerebra cortex



Processing of two-
points discrimination
at the cerebral
cortex: the use of
lateral inhibition.

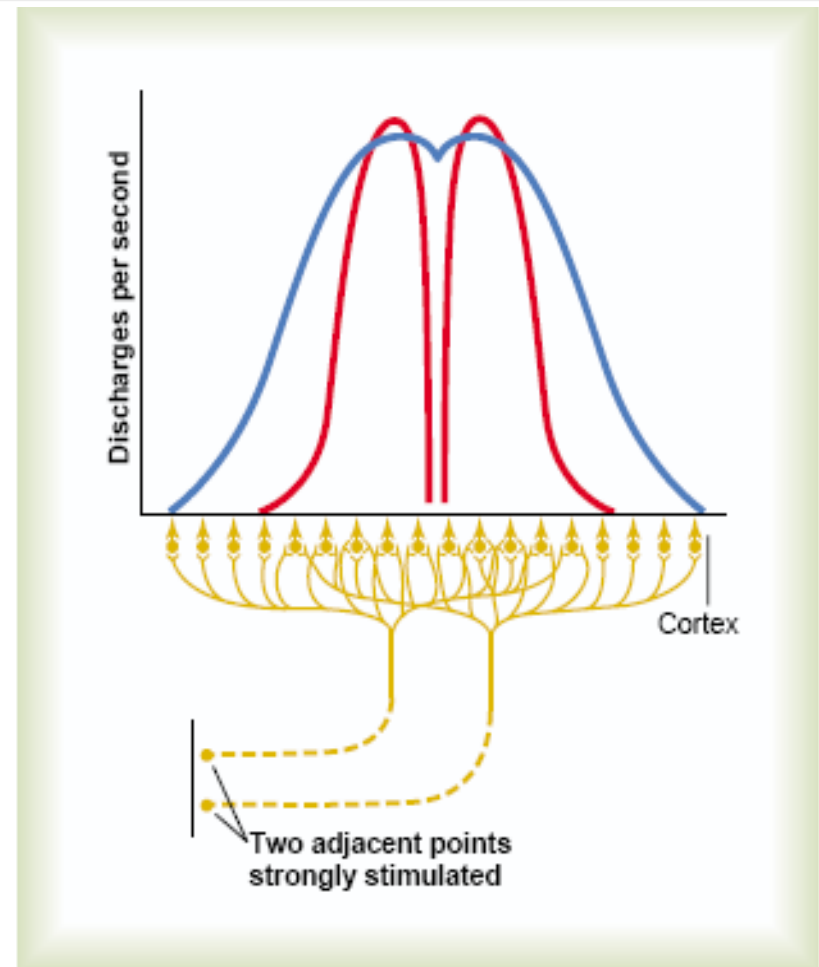


Figure 47-10

Transmission of signals to the cortex from two adjacent pinpoint stimuli. The blue curve represents the pattern of cortical stimulation without "surround" inhibition, and the two red curves represent the pattern when "surround" inhibition does occur.

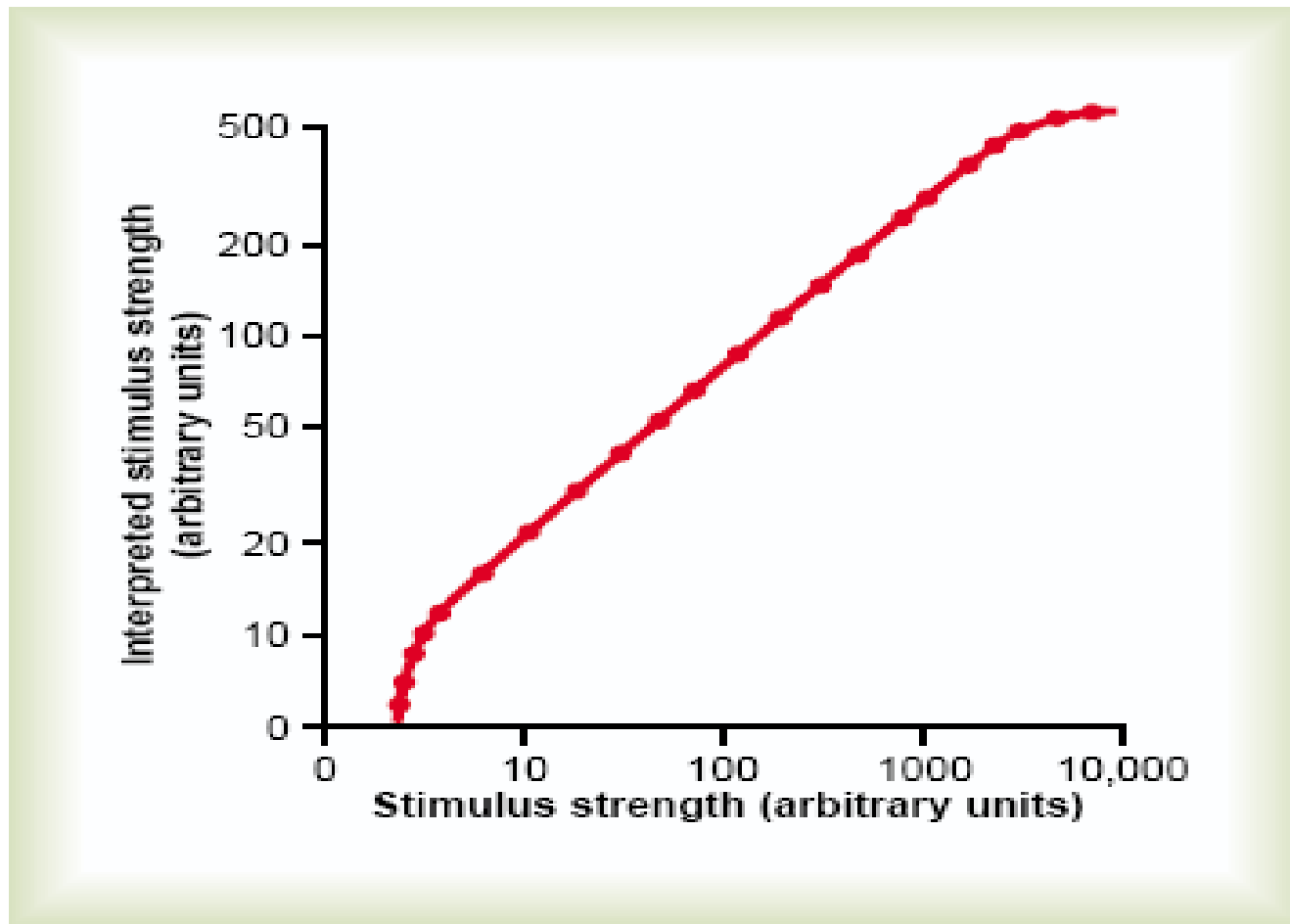


Figure 47-11

Graphical demonstration of the “power law” relation between actual stimulus strength and strength that the psyche interprets it to be. Note that the power law does not hold at either very weak or very strong stimulus strengths.

Processing of position sense

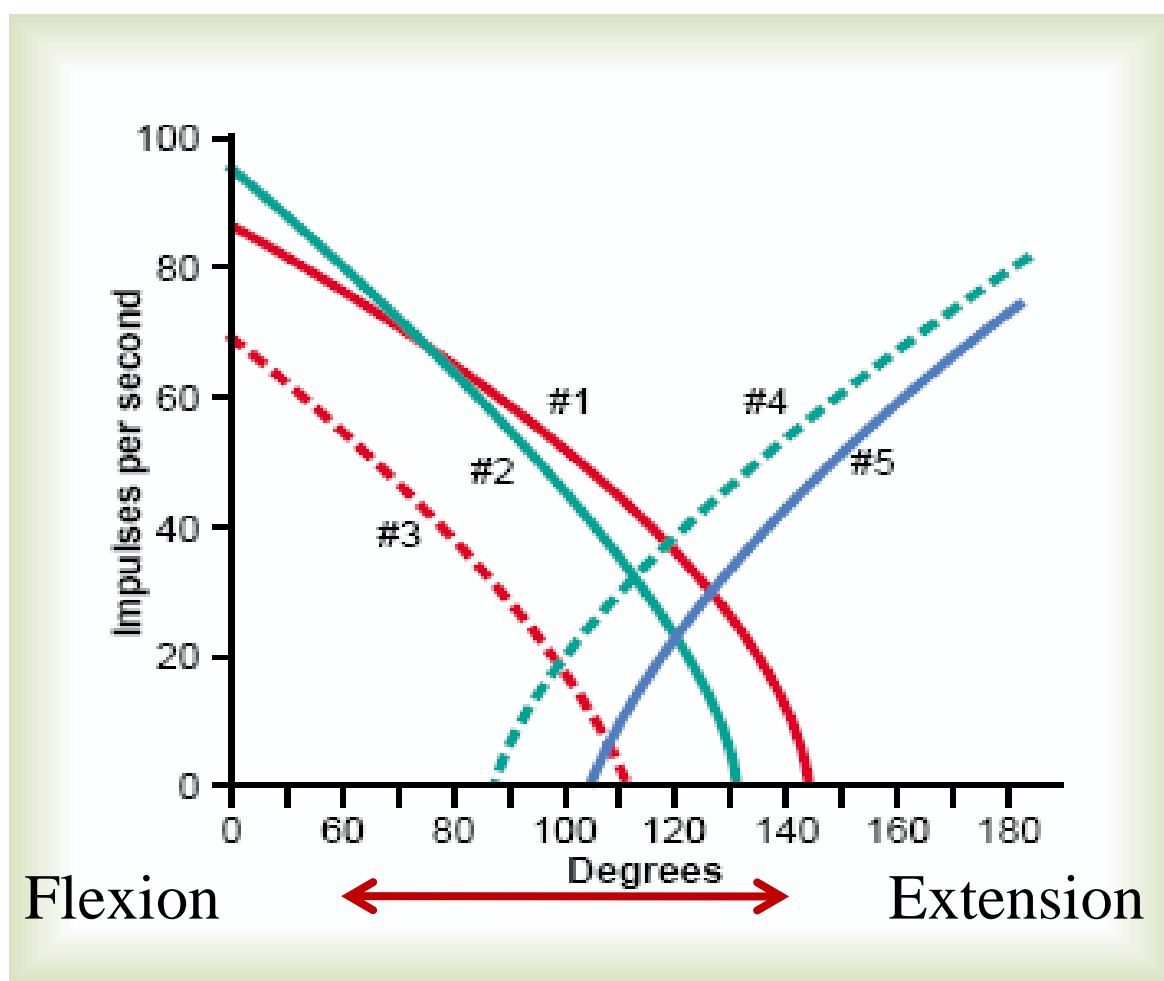


Figure 47-12

Typical responses of five different thalamic neurons in the thalamic ventrobasal complex when the knee joint is moved through its range of motion. (Data from Mountcastle VB, Poggio GF, Werner G: The relation of thalamic cell response to peripheral stimuli varied over an intensive continuum. *J Neurophysiol* 26:807, 1963.)

Thank You

