ANATOMY

SHEET NO. 12- lec 2 online

WRITER : 018 sheets

CORRECTOR : Jawad Alrawabdeh ,Ghada Alzoubi

DOCTOR : Dr. Mohammad alsalem

Vagus nerve (cranial nerve X):

1. **Motor nucleus** (lower part of nucleus ambiguous).
   Supplies the constrictor muscles of the pharynx and the muscles of the larynx.
2. **Dorsal nucleus of Vagus** *(parasympathetic),* anterior to the floor of the lower part of the fourth ventricle, it receives afferents from the hypothalamus and glossopharyngeal nerve *(carotid sinus reflex).*
   Efferent to involuntary muscles of the bronchi, heart, esophagus, stomach, small intestines, and large intestines as far as the distal one-third of the transverse colon.

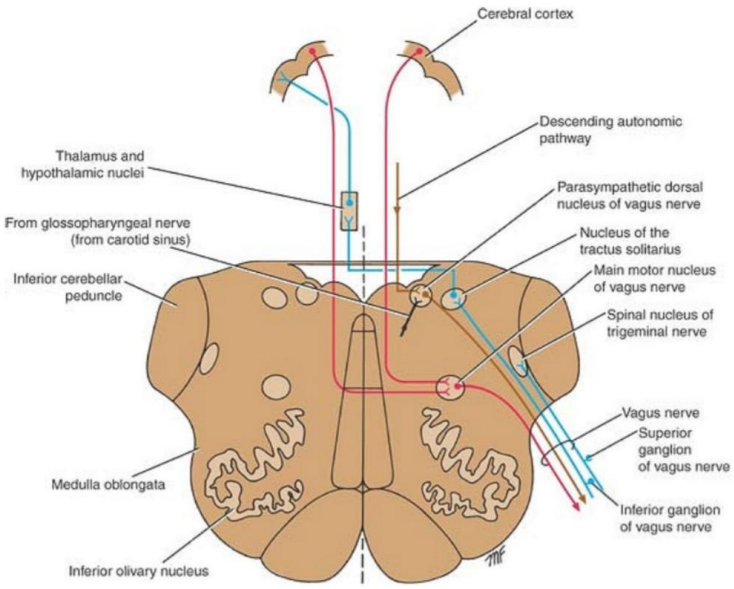

3. **Sensory nucleus:**
   - Taste from the epiglottis: carried to the lower part of **nucleus tractus solitarius**, cell bodies of the first order neurons in the **inferior ganglia** *(don't confuse it with the inferior ganglion of the glossopharyngeal, both have superior and inferior ganglia)*.
   - General sensation: cell bodies of the first order neurons in the **superior ganglia**, then to the **spinal nucleus of trigeminal**.
     carries sensation from the outer ear, mucosa of the larynx, and the dura of posterior cranial fossa.

Course ~~not required; just remember that it can reach the abdomen.~~

Injury:

- Uvula deviates to the healthy side.
- Hoarseness of voice *(paralysis in the muscles of the larynx)*
- Dysphagia and nasal regurgitation *(paralysis in the muscles of the pharynx)*
- Arrhythmia in heart and irregularity in GI tract because *(parasympathetic dysfunction)*

course: jugular foramen to carotid sheath (with internal jugular vein and carotid artery) then goes through neck and goes posterior to the hilum of the lung.
Then descends to abdomen through esophageal hiatus and here it divides into right (posterior) and left(anterior)
posterior vagal trunk = right vagal branch
anterior vagal trunk = left vagal branch

Accessory nerve (cranial nerve XI):

Motor and has two roots: cranial and spinal.

1. Cranial root from nucleus ambiguous.
2. Spinal root originates from the spinal cord (lamina IX from the upper 5 cervical segments).

Accessory nucleus has the cell bodies

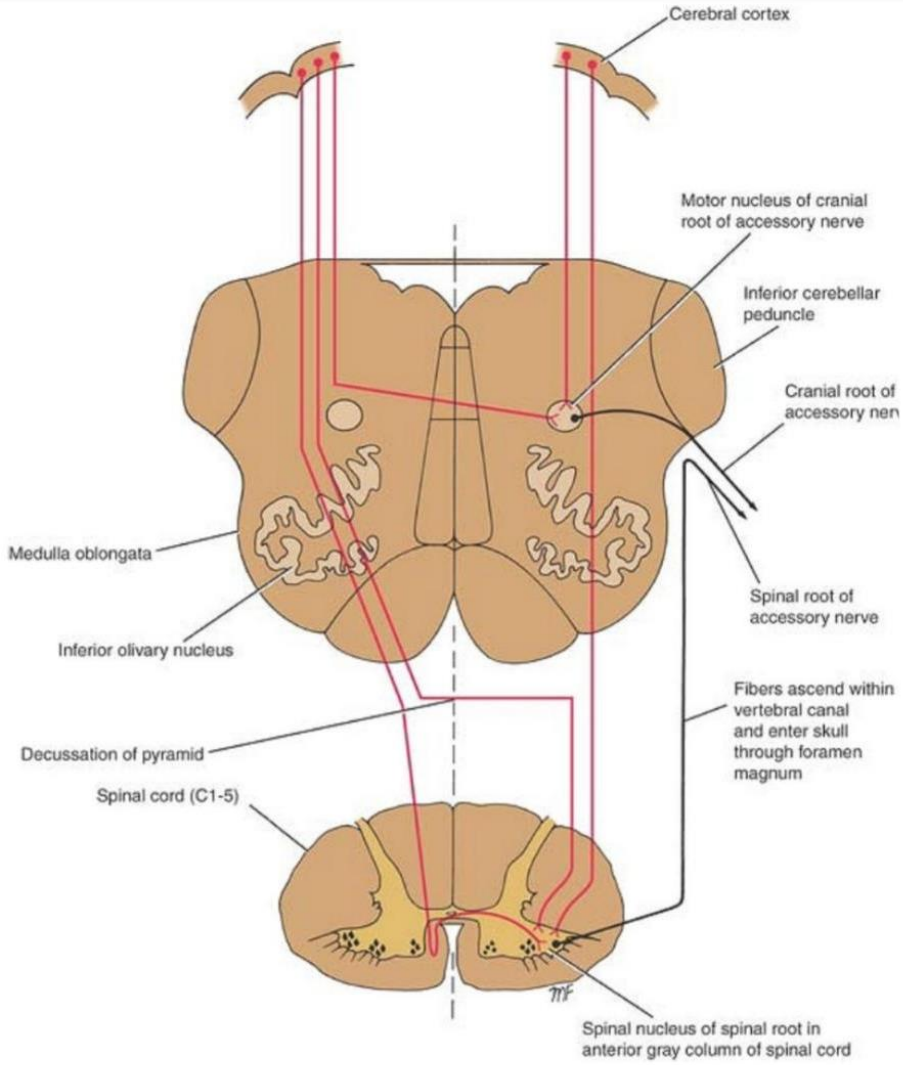

The spinal root ascends to the cranial cavity though foramen magnum to join the cranial root, they then move together *(fibers of the two roots don't mix)* and leave through the jugular foramen.

They separate once more and the cranial root joins the vagus nerve and courses along with it, while the spinal descends by itself and supplies the trapezius and sternocleidomastoid.

*The soft palate is thought to be supplied by the cranial root.

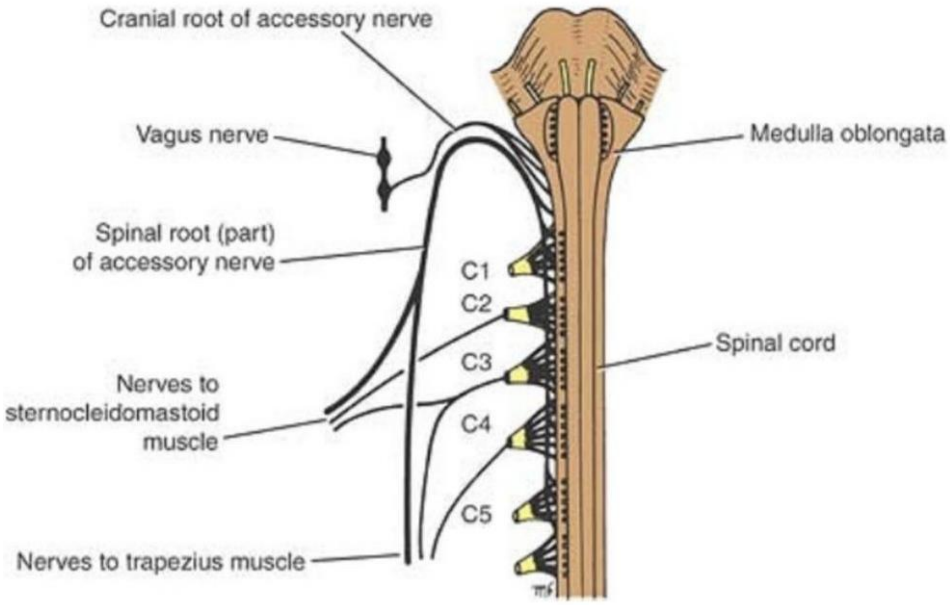

Hypoglossal nerve (cranial nerve XII):

Has one motor nucleus, Beneath the floor of the lower part of the fourth ventricle.

Supplies all the muscles of the tongue except palatoglossus *(from the vagus).*

Cells responsible for supplying the genioglossus muscle receive from the opposite cerebral hemisphere (not bilateral).

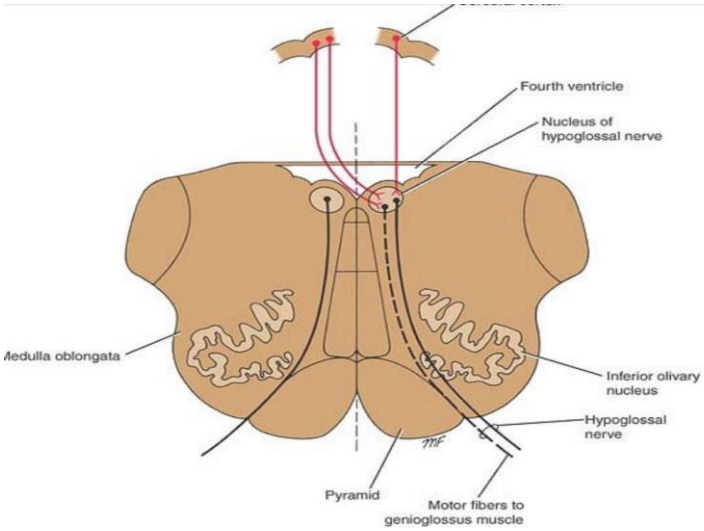

There are two fibers in this nucleus because one fiber is specialized for the genioglossus muscle (only receives contralateral innervation)

Course:

- Emerges between the olive and the pyramid *(the other medullary cranial nerves emerge between the inferior cerebellar peduncle and the olive).*
- Leaves the skull through the hypoglossal canal.
- Courses between the internal carotid artery and the internal jugular vein to eventually reach the tongue, during its course it attaches to the C1 spinal nerve but doesn't mix with it.

(c1 from ansa cervicalis innervates geniohyoid and thyrohyoid)

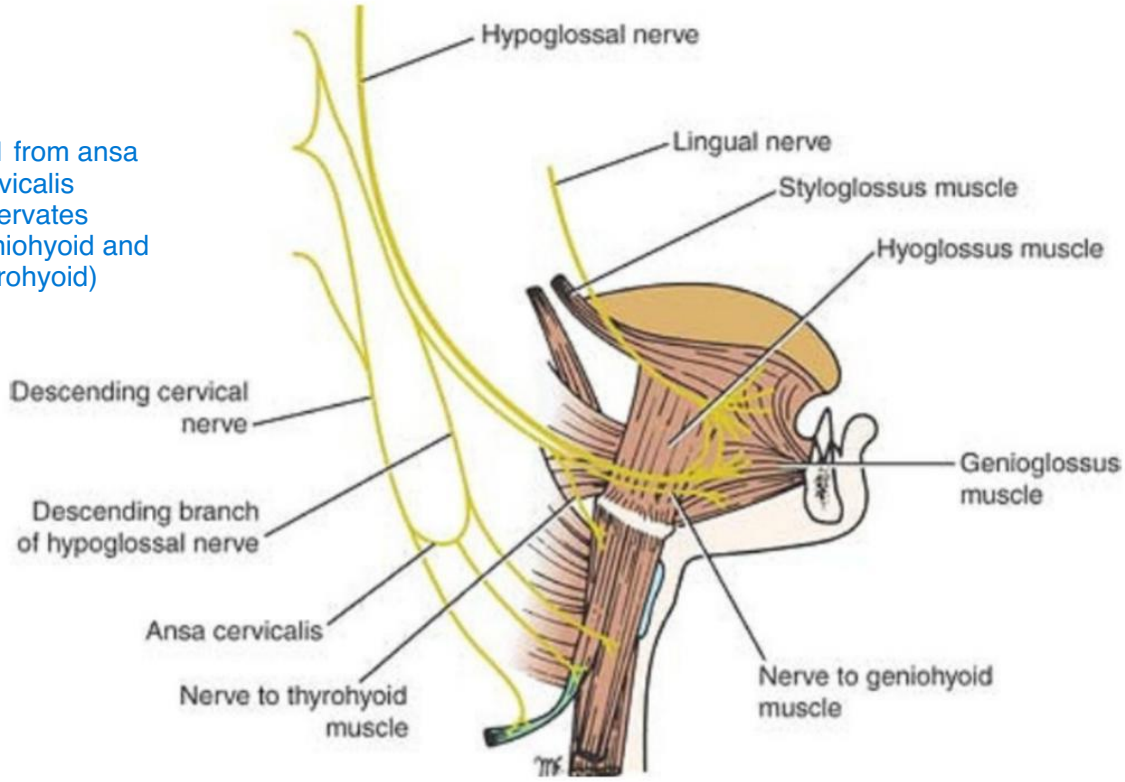

Injury:

Lower motor neuron lesion: Tongue deviates toward the paralyzed side during protrusion with muscle atrophy (ipsilateral)

Upper motor neuron lesion: On protrusion, tongue will deviate to the side opposite the lesion *(genioglossus paralysis)* with no atrophy.

Reticular formation:

Deeply placed continuous network of nerve cells and fibers that extend from the spinal cord through the medulla, the pons, and the midbrain, it might reach some superior structures like the thalamus and subthalamus but it's mainly in the brainstem.

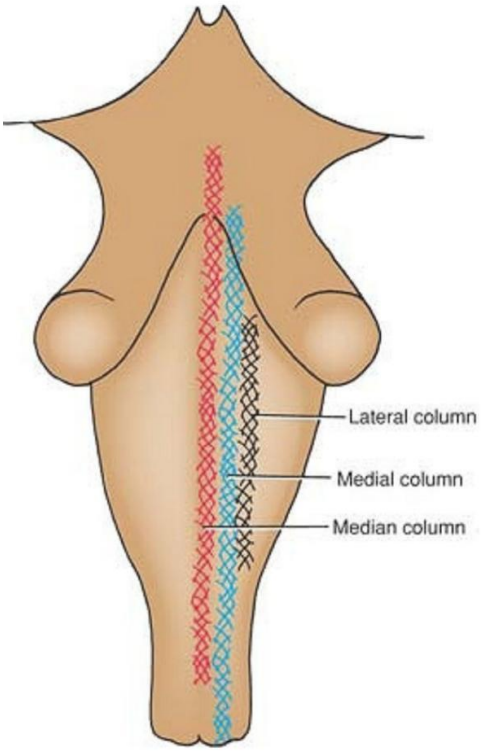

Divided into three longitudinal columns:

- Median column: intermediate-size neurons
- Medial column: large neurons
- Lateral column: small neurons

General function:

1. Control of skeletal muscle
2. Control of somatic and visceral sensations
3. Control of the autonomic nervous system *(vital centers)*
4. The reticular activating system *(it switches the cortex on and off)*

This lecture will discuss the blood supply of the brain stem and the lesions related to the blood supply.

We'll begin by briefly discussing *The circle of Willis*

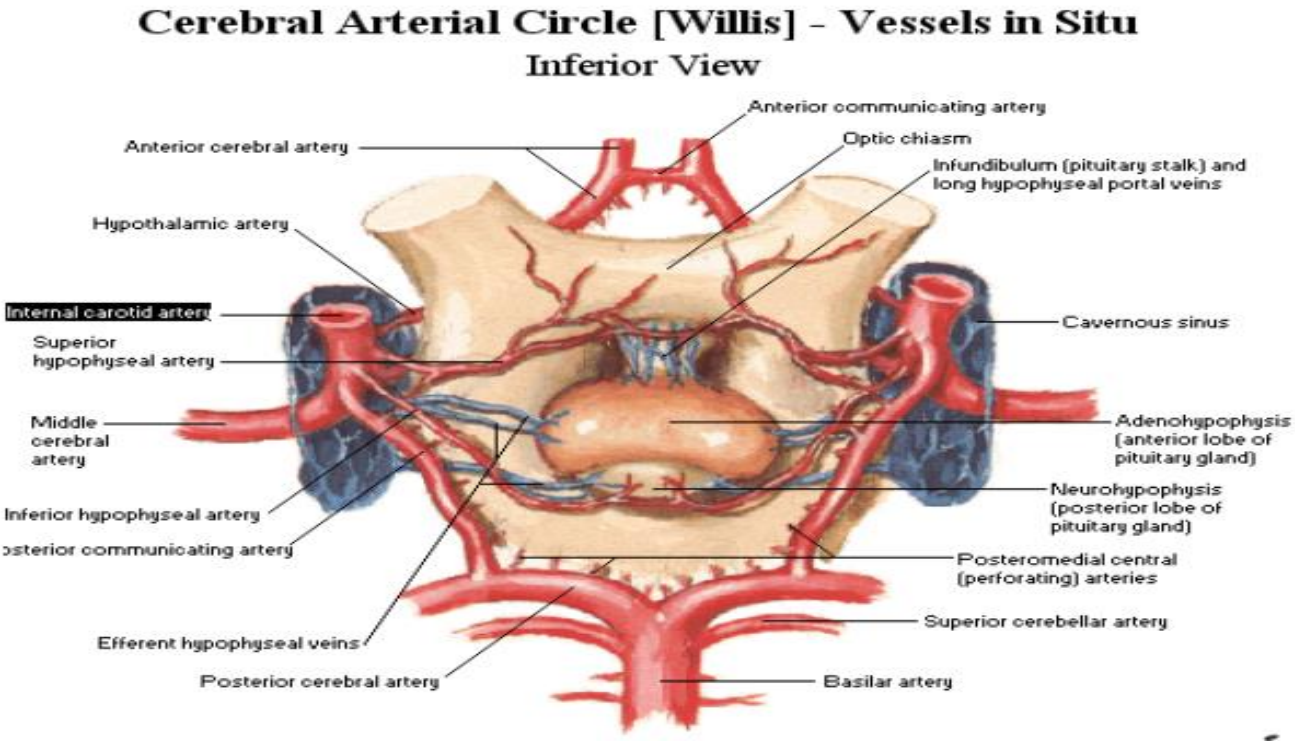

Formed by 2 arteries in the cranial cavity which are *the internal carotid artery* and *the basilar artery* formed by the two vertebral arteries after entering through the foramen magnum.

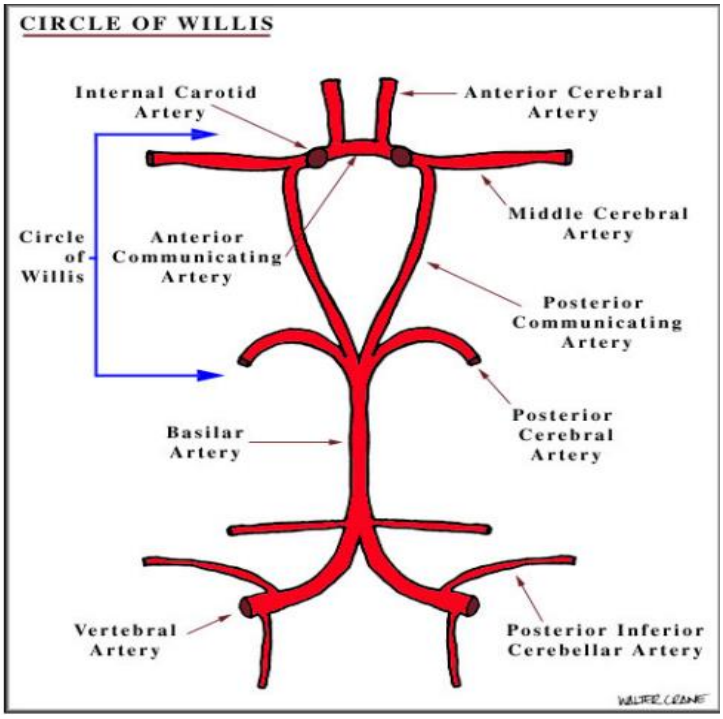

In this picture to the right you can see the major branches from the circle of Willis.

The part which is of interest to us for the supply of the brain stem is lower part (the two vertebral arteries forming the basilar)

The internal carotid artery is curved in a special way to prevent blood from falling down due to gravity

Branches from the vertebral (like the anterior spinal and posterior inferior cerebellar artery) and branches from the basilar will be the main blood supply of the medulla oblongata and the pons, while the midbrain will be supplied by the posterior cerebral artery and superior cerebellar artery and the basilar.

In this picture on the right you can see the course of the vertebral artery, which originates from the subclavian artery and moves through the transverse foramina of cervical vertebra and eventually (at c1 vertebra) it curves upward forward and medially and then enters the foramen magnum and forms the basilar artery when the 2 sides unite.

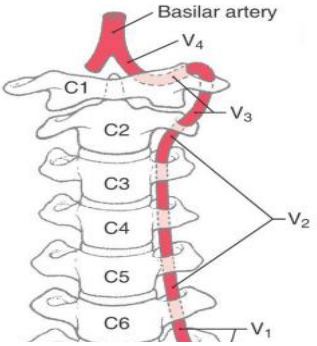

The second picture below is a posterior view of the arteries and shows the 2 vertebral arteries and these arteries give *the anterior spinal artery,* a single artery which moves along the anterior median fissure of the spinal cord and medulla, it has two roots each one from the vertebral artery on each side.

The vertebral artery also gives a branch called *the posterior inferior cerebellar artery* (PICA) and this gives a branch called the posterior spinal artery.

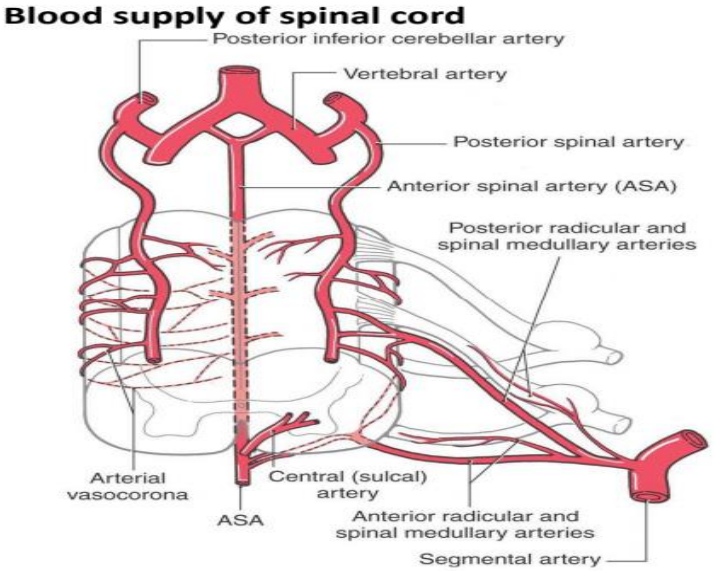

internal carotid artery gives off middle and posterior cerebral artery

This is a picture of the brainstem and the arteries, you can see the two vertebral arteries, the vertebral gives the anterior spinal as well as *PICA* -posterior inferior cerebellar artery and (PICA gives the posterior spinal), these arteries will supply the medulla oblongata (vertebral, ASA,PICA,PSA).

circle of willis includes posterior and and anterior communicating arteries

Label the blood supply to the brainstem.

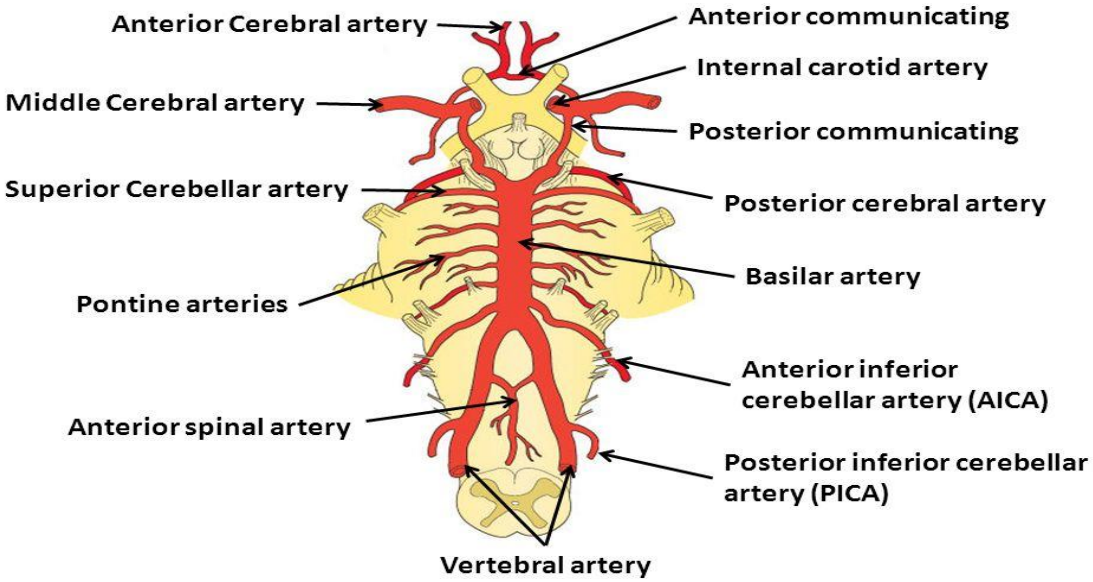

You can the basilar artery which moves along the basilar groove on the pons and gives pontine arteries which supply the pons. The basilar artery then divides into two posterior cerebral arteries which receive the posterior communicating artery to complete the circle of Willis.

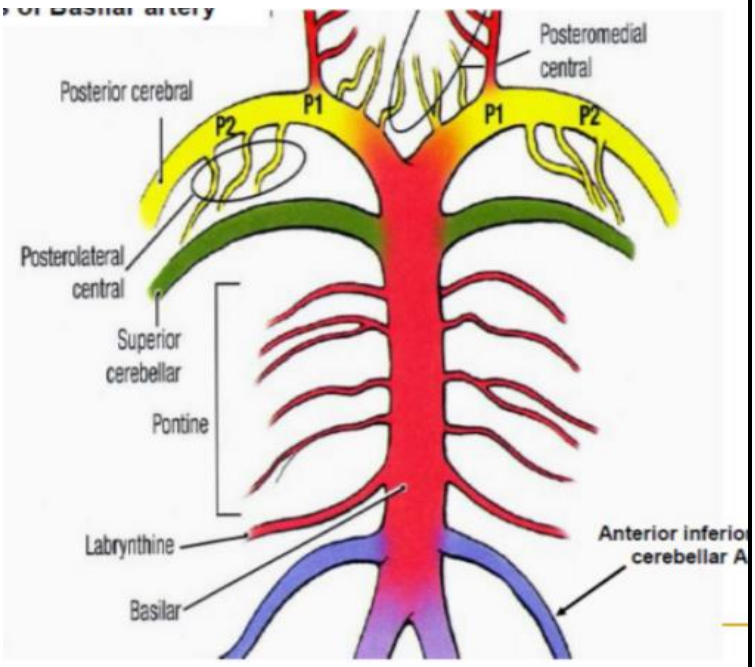

The main branches of the basilar artery are:

1- anterior inferior cerebellar artery (AICA) supplies inferior surface of the cerebellum.

2- Pontine arteries.

3- Superior cerebellar arteries that branch off the basilar before its bifurcation into the posterior cerebral arteries (supplies superior surface of cerebellum and pons).

Blood supply of the medulla oblongata

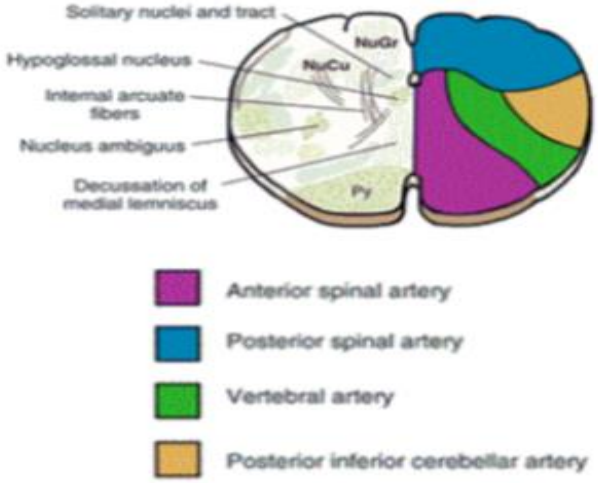

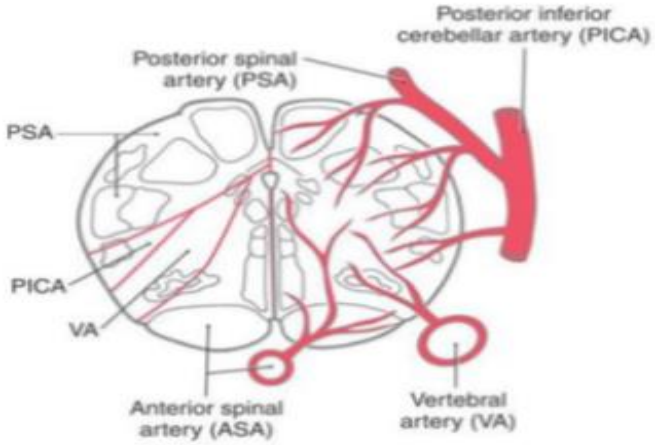

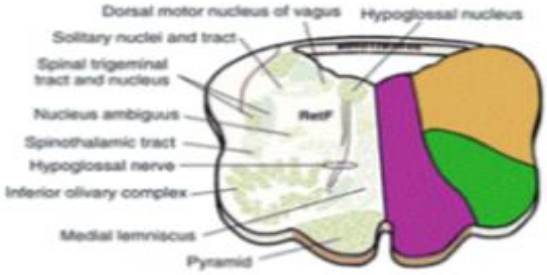

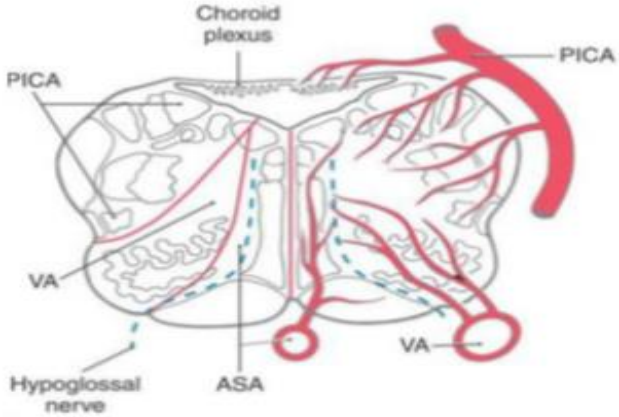

The above cross section is at the level of closed medulla (the cavity is the central canal) and the other is at the level of open medulla (the cavity is the 4th ventricle), and you can see the arteries that supply the medulla oblongata.

Starting anteriorly above, you can see the anterior median fissure and a cross section of the anterior spinal artery which supplies the midline structures (notice the sections on the left, the ASA supplies the purple), the area slightly lateral to it (green) is supplied by the vertebral artery. The most lateral and posterior parts are supplied by PICA (a branch of vertebral) and posterior spinal artery (a branch of PICA).

Notice that the PSA supplies the posterior aspect on the lower level or closed medulla but when you ascend to open medulla the PSA doesn't contribute to supply.

To sum up, midline structures are supplied by the ASA, more lateral to it the vertebral artery and most lateral and posterior structures by PICA (open medulla), and PSA contributes to posterior structures in closed medulla.

Medial medullary syndrome (Dejerine syndrome)

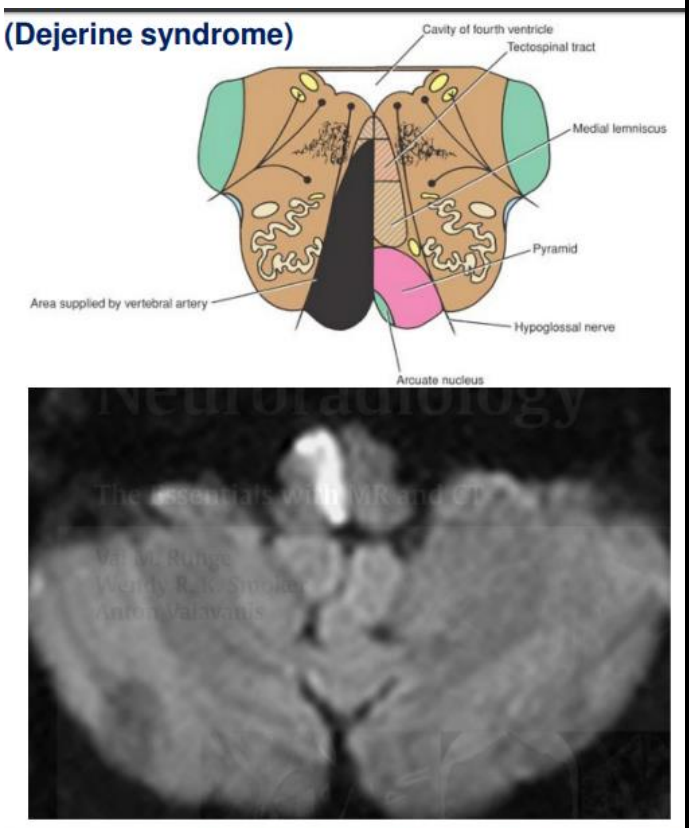

It is caused by a lesion in anterior spinal artery which supplies the area close to the midline at.

Notice in the picture the dark area is the location where there is loss of blood supply.

Symptoms (related to the structures on the midline):

• Contralateral hemiparesis (weakness in muscles, paralysis may happen based on severity)

Notice that the anterior aspect of the midline is occupied by the pyramids (corticospinal tracts), it is contralateral because at this level decussation hasn't happened yet.

• Contralateral loss of proprioception, fine touch and vibratory sense due to damage to the medial lemniscus (remember that decussation happened so the medial lemniscus on the left carries information about the right side of the body).

• Deviation of the tongue to the ipsilateral side when it is protruded (hypoglossal root or nucleus injury).

This syndrome is characterized by Alternating hemiplegia

Note: Alternating hemiplegia means;

1- The upper and lower limbs are paralyzed in the contralateral side of lesion = upper motor neuron lesion (decussation).

2- while the face is paralyzed in the ipsilateral side of lesion = lower motor neuron lesion (no decussation).

Symptoms related to cranial nerve <u>(ipsilaterally)</u>

The white area in the second picture represents the lesion which is at the midline.

Lateral medullary syndrome (Wallenberg syndrome) or PICA syndrome

It is caused by a lesion in PICA which supplies the area close to lateral areas.

The dark area is affected (supplied by PICA), in the radiograph it is the are with a red arrow on it.

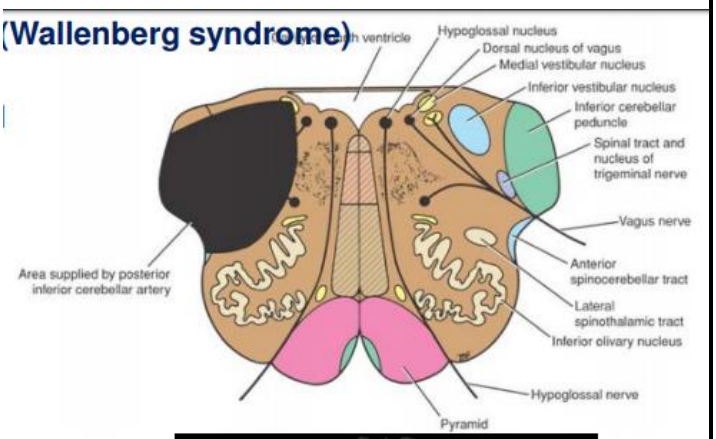

Symptoms

contralateral loss of pain and temperature sensation from the body (anterolateral system, decussation already happened at this level so the ALS on the left carries information about the right side of the body).

ipsilateral loss of pain and temperature sensation from the face (involvement of spinal trigeminal tract and nucleus).

Loss of balance

vertigo and nystagmus (vestibular nuclei).

Nystagmus is irregular movements of the eyeballs (the vestibular nucleus connected to the cranial nerves supplying the eye muscles).

loss of taste from the ipsilateral half of the tongue (solitary tract and nucleus).

Nucleus tractus solitarius is a sensory nucleus for 2 types of sensations, visceral sensory and taste. This nucleus receives taste sensations from the same side through 3 cranial nerves (7th and 9th and 10th

hoarseness and dysphagia (nucleus ambiguus or roots of cranial nerves IX and X)

Nucleus ambiguus is a motor nucleus for 3 cranial nerves (9th, 10th and 11th) and has the lower motor neurons supplying the muscles of the larynx and pharynx. (muscles are affected ipsilaterally)

Loss of sympathetic because of hypothalamospinal fibers

Ipsilateral Horner syndrome (hypothalamospinal fibers)

Rem: lateral (medullary) reticulospinal tract has descending autonomic regulating fibers provide a pathway by which the hypothalamus can control the sympathetic and sacral parasympathetic outflow. If these fibers are cut then symptoms similar to Horner syndrome will develop like ptosis, miosis (constriction of pupil) and anhidrosis, all related to sympathetic injury.

Vascular lesions of the posterior spinal artery

Symptoms

Decussation occur at the level of lower part of medulla oblongata

ipsilateral loss of proprioception and vibratory sense (related to PCML system specifically nucleus gracilis and cuneatus).

ipsilateral loss of pain and temperature sensation from the face (lateral to the nucleus cuneatus is the trigeminal nucleus and is affected).

Spinal nucleus of trigeminal

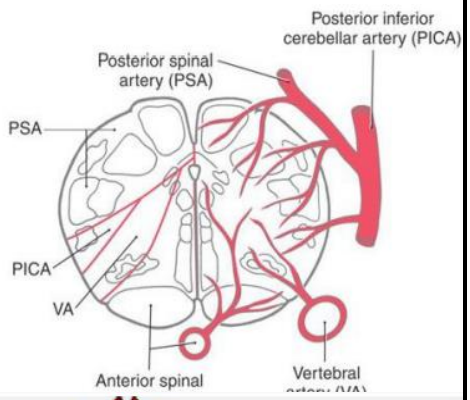

Blood supply of pons

Remember that the basilar artery moves through the basilar groove on the pons and gives the anterior inferior cerebellar artery and superior cerebellar and pontine arteries and ends by dividing into two posterior cerebral arteries.

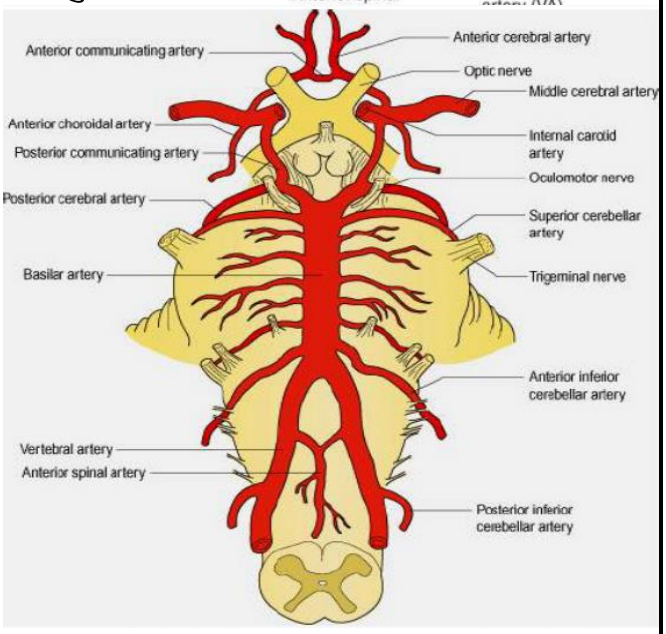

The following is a cross section of the pons:

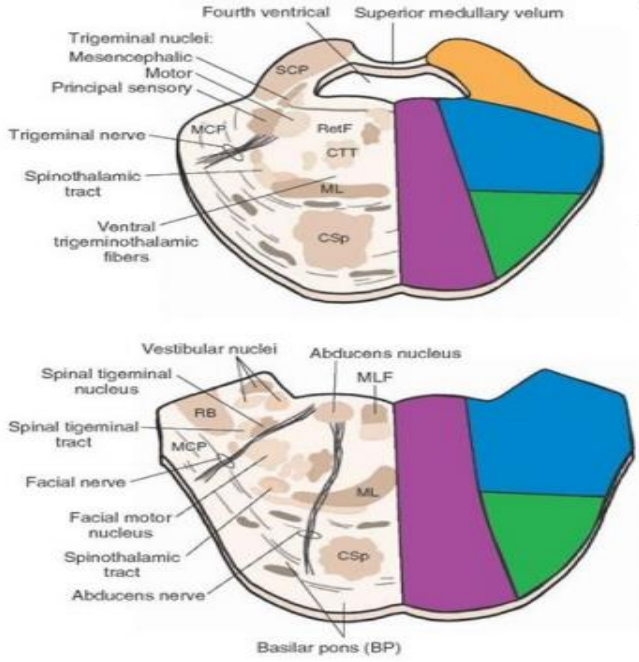

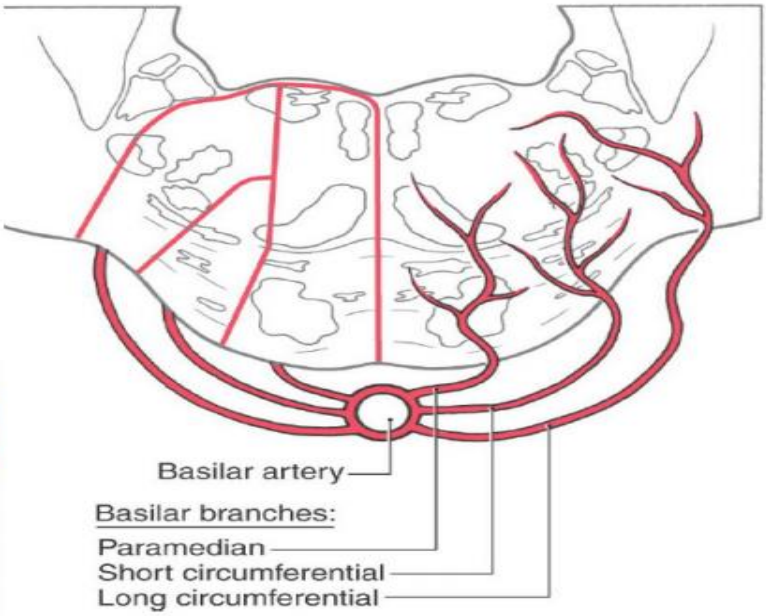

The blood supply of pons will be discussed at 2 levels, the inferior level (caudal part) closer to the pontomedullary junction and the superior level (midpontine) where we can see the trigeminal nuclei.

Generally, the pons will be supplied by paramedian branches (from basilar), from there name they're close to the midline so the structures at the midline will be supplied by these branches (purple structures in the figure), the lateral structures (green and blue) are supplied by the circumferential branches (some sources divide them into short and long circumferential branches). AICA also contributes to supply of lateral part (blue) with the circumferential arteries.

At the upper level (midpontine, level of trigeminal nucleus) branches from the superior cerebellar arteries aid in supply of the posterior part with the circumferential branches.

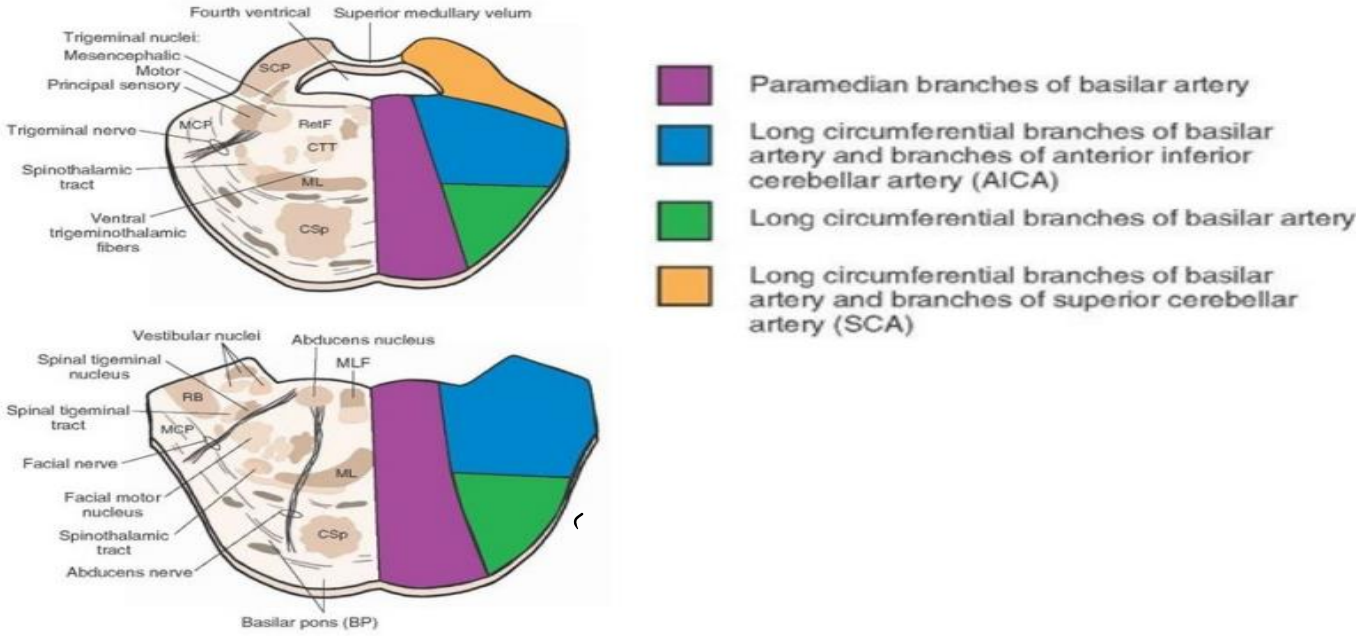

Foville syndrome

Due to occlusion of the paramedial branches

Symptoms

• ipsilateral abducens nerve paralysis (the abducent nucleus is found posteriorly close to the floor of the 4th ventricle and the abducent nerve moves anteriorly and emerges from the pontomedullary junction close to the midline).

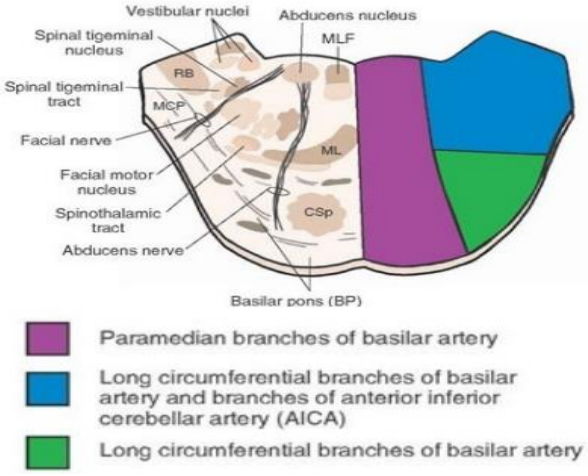

• contralateral hemiparesis

The anterior part of the purple color is the basilar part which contains corticospinal fibers and these fibers decussate in the lower part of the medulla so fibers on the right supply left side (symptoms related to long tracts are contralaterally and symptoms related to cranial nerves ipsilaterally).

• variable contralateral sensory loss reflecting various degrees of damage to the medial lemniscus.

Millard-Gubler syndrome (or just Gubler syndrome)

If the area of damage is shifted somewhat laterally to include the **root of the facial nerve** along with **corticospinal fibers**, the patient has a *contralateral hemiparesis* and an *ipsilateral paralysis of the facial muscles*.

Syndrome of the midpontine base Cranial part

Due to occlusion of the paramedial branches and short circumferential branches.

• Corticospinal fibers (which are passing through the basilar part) are affected causing *contralateral* hemiparesis.

• Sensory and motor trigeminal roots (trigeminal nuclei, the motor nuclei medially and slightly laterally the sensory nucleus) are affected causing *ipsilateral* loss of pain and thermal sense and paralysis of the masticatory muscles.

Loss of coordination

• Fibers of the middle cerebellar peduncle *(ataxia)*.

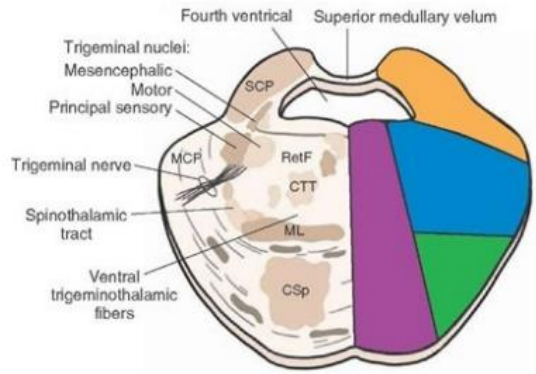

Paramedian branches of basilar artery

Long circumferential branches of basilar artery and branches of anterior inferior cerebellar artery (AICA)

Long circumferential branches of basilar artery

Long circumferential branches of basilar artery and branches of superior cerebellar artery (SCA)

(Syndrome of the midpontine base hallmark of brainstem vascular lesions, ipsilateral cranial nerve sign coupled with a contralateral long tract sign).

In movements that need highly coordination such as movement of eye, leg and lips" slurred speech"

* Common in cerebellum lesion

Blood supply of the midbrain

• Basilar artery (gives direct branches to the midbrain in addition to the following branches):

-quadrigeminal artery (this artery could arise from both the basilar artery at the bifurcation and the posterior cerebellar artery)

-superior cerebellar arteries

• Internal carotid: anterior choroidal artery (not seen in this picture go back to the 2nd pic in page 7 to see it)

• Posterior cerebral artery (is divided into parts, in the pic you can see P1 and P2): *medial posterior choroidal artery*.

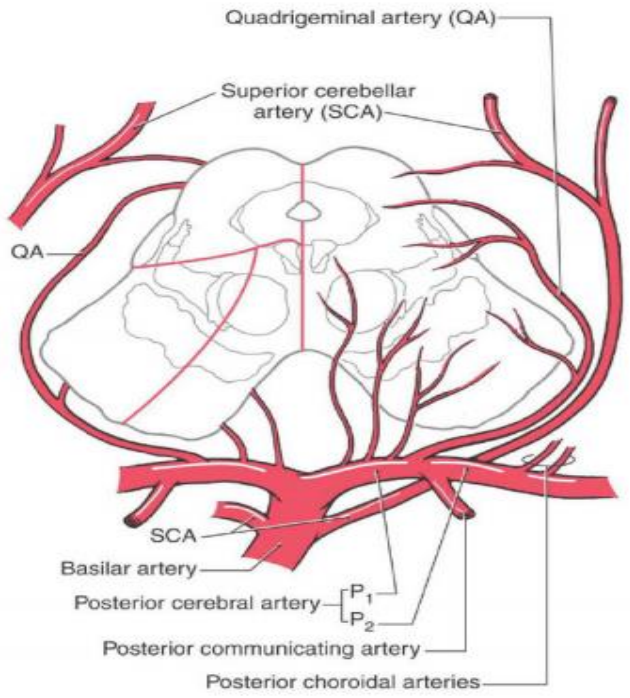

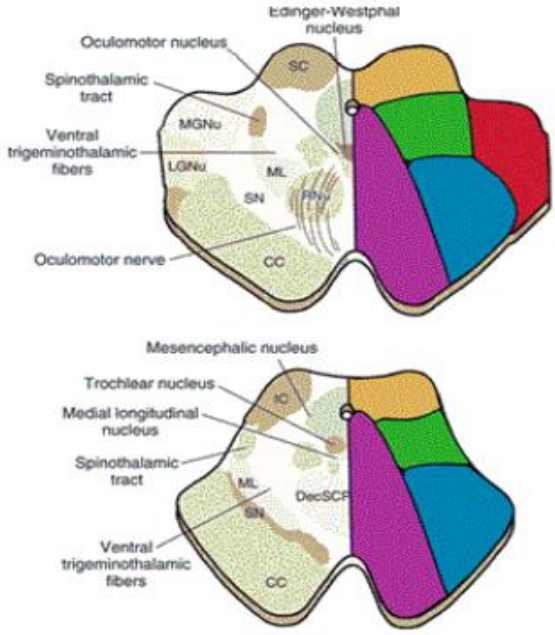

Anteromedial (paramedian) branches of basilar bifurcation and posterior cerebellar artery (paramedian branches)

Anterolateral (short circumferential) branches of the quadrigeminal and medial posterior choroidal arteries

Lateral branches of quadrigeminal (level of inferior colliculus) and posterior medial choroidal arteries (level of superior colliculus)

Quadrigeminal and superior cerebellar arteries (level of inferior colliculus), quadrigeminal and posterior medial choroidal arteries (level of superior colliculus)

Thalamogeniculate artery posterior cerebral artery

paramedian branches are the oculomotor, trochlear, and Edinger-Westphal nuclei; the exiting oculomotor fibers; the red nucleus; and medial aspects of the substantia nigra and crus cerebri

Medial regions of the midbrain receive numerous small branches from posterior cerebral artery and from the **posterior communicating artery**

Ventrolateral regions of the midbrain are served by penetrating branches of the **quadrigeminal artery the anterior choroidal artery, and the medial posterior choroidal artery.** The region served by these branches includes the lateral parts of the crus and substantia nigra and the medial lemniscus

The posterior midbrain is served primarily by the **quadrigeminal artery** which typically arises from posterior cerebral artery Much of the periaqueductal gray, the nuclei of the superior and inferior colliculi, the anterolateral system, and the brachium of the inferior colliculus are served by quadrigeminal branches. Additional blood supply medial branches of the **superior cerebellar artery**

233

The parts closer to the midline (purple) are supplied by paramedian branches from the bifurcation of the basilar artery. Anterolateral (blue) parts are supplied by circumferential branch of the quadrigeminal and posterior choroidal arteries.

Posterolateral parts (green) are supplied by medial posterior choroidal arteries.

The posterior part (yellow) which is the tectum, is supplied by the quadrigeminal artery and superior cerebellar artery.

The difference between the 2 levels shown in the picture (above at the level of superior colliculus and below at the level of inferior colliculus) is that in the superior section the most lateral (red) parts are supplied by the Thalamogeniculate artery, a branch of the posterior cerebral artery.

Weber syndrome

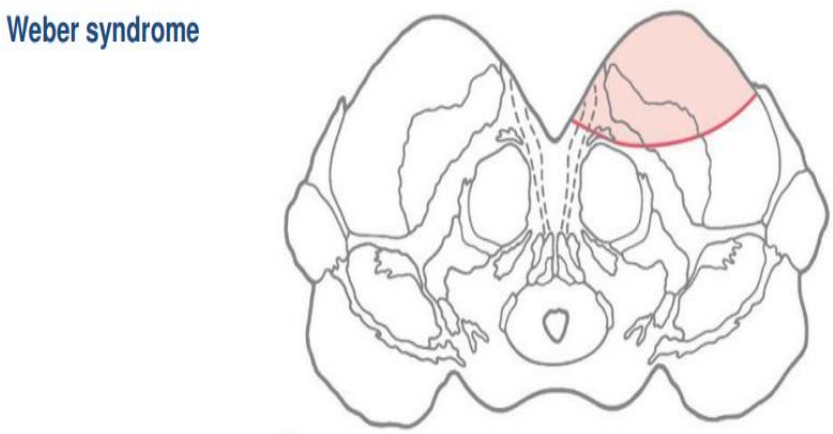

Due to occlusion of vessels serving the medial portions of the midbrain involving the oculomotor nerve and the crus cerebri.

Symptoms:

• Ipsilateral paralysis of all extraocular muscles except the lateral rectus (supplied by the abducent) and superior oblique (by the trochlear).

• Paralysis of the *contralateral* extremities.

Corticospinal fibers in midbrain pass through crus cerebri and the crus cerebri on the right is related to the left side of the body (عدنا الفكرة الف مرة) decussation happens inferior to this level

• Ipsilateral dilatation of pupil (oculomotor nerve has parasympathetic fibers supplying the constrictor pupillae muscle, so dilation occurs when damaged).

• Contralateral weakness of the facial muscles of the lower half of the face.

This goes against the principle we explained multiple times, and this is the explanation:

The crus cerebri contains the corticonuclear fibers going to the motor nucleus of the facial nerve and these fibers are **upper motor neurons**.

Cranial nerve nuclei receive bilateral corticoneclear fibers (nucleus on the right receives fibers from both right and left cortex), the part of motor nucleus related to the lower face receives fibers only from the contralateral cortex, this is why the weakness in lower face is contralateral but if the lesion was in a lower level like one of the previously mentioned it would be ipsilaterally because it is at the level of lower motor neuron, the same concept applies for the tongue.

• Contralateral deviation of the tongue when it is protruded

The tongue is supplied by the hypoglossal nerve and its nucleus receives bilateral fibers from the both cortexes, the part of nucleus related to the *genioglossus* muscle receives fibers only from the contralateral cortex.

Weber syndrome hallmark of brainstem vascular lesions, **ipsilateral cranial nerve sign** coupled with a **contralateral long tract sign.**

Claude syndrome

Due to occlusion of vessels serving the central area of the midbrain which includes the oculomotor nerve and the red nucleus.

Symptoms:

• ipsilateral paralysis of most eye movements; the eye is directed down and out (laterally), because 2 muscles are spared, superior oblique and lateral rectus and these muscles cause the eye to be directed that way.

• Ipsilateral dilatation of pupil (oculomotor nerve has parasympathetic fibers supplying the constrictor pupillae muscle, so dilation occurs when damaged)

• contralateral ataxia, tremor, and incoordination

Caused by involvement of the red nucleus which receives input from the cerebellum (cerbellorubral tract) and even the levels slightly below the red nucleus which have the superior cerebellar peduncle decussation.

The last lesion is **Benedikt syndrome** (basically the previous 2 syndromes together).

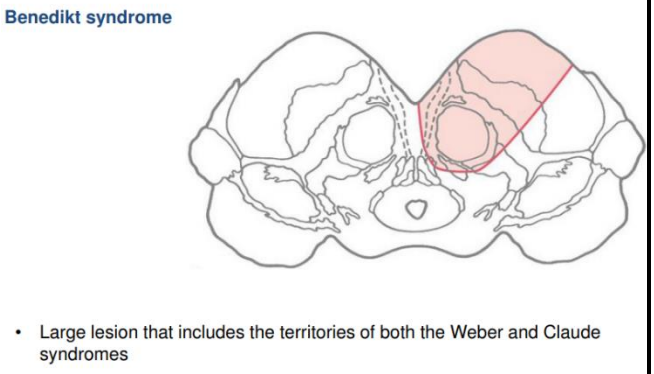

TONSILLAR HERNIATION

There is a part of the cerebellum called tonsils, when it is pushed out of its normal location the condition is called tonsillar herniation (notice in the picture the direction of herniation which is downward towards the foramen magnum), this will cause pressure on the medulla oblongata in that area.

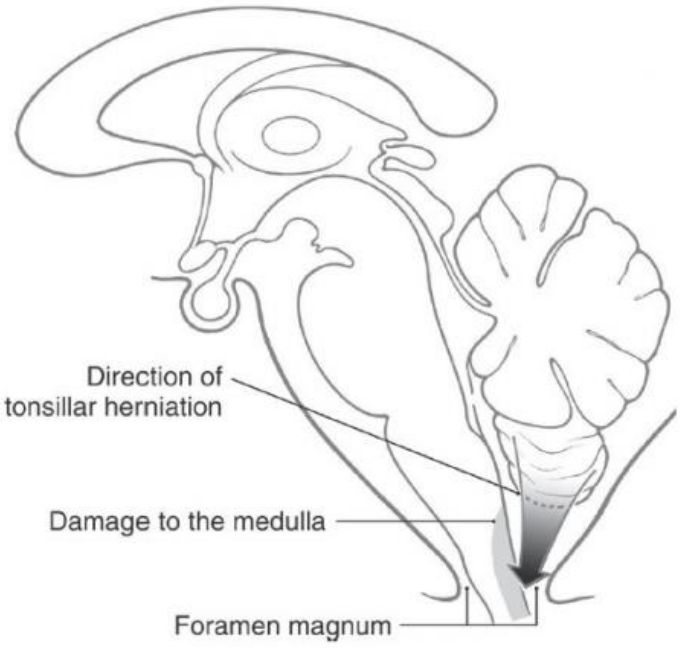

Causes:

any mass in the posterior cranial fossa (tumor, hemorrhage)

increase in intracranial pressure

The major concern in acute herniation is damage to the **ventrolateral reticular area** (heart rate and respiration)

Symptoms:

(caused either directly by pressure from the herniation or indirectly through occlusion to the arteries that supply the medulla)

sudden change in heart rate and respiration

hypertension

hyperventilation

rapidly decreasing levels of consciousness (part of the reticular formation is connected to the reticular nuclei which project to the cortex and are responsible for keeping you alert)

If sever, death

In addition to variable amounts of sensory and motor deficits according to the severity.

Arnold-Chiari Phenomenon

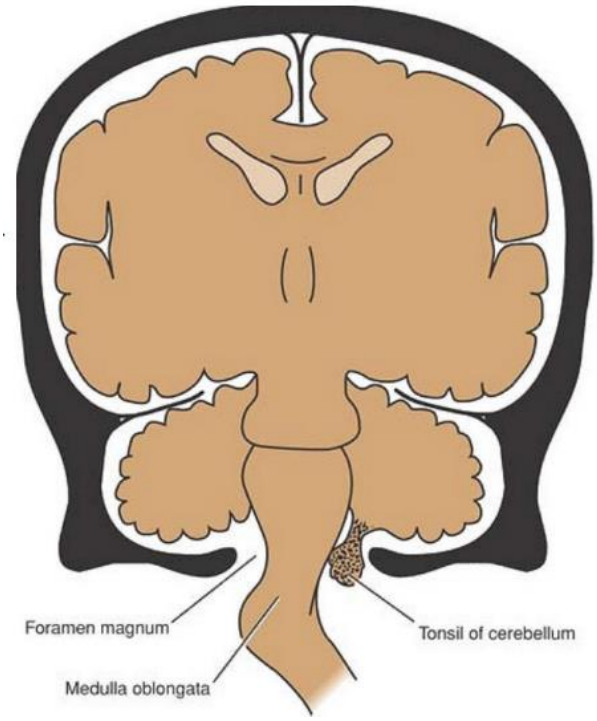

Congenital anomaly in which there is a herniation of the tonsils of the cerebellum and the medulla oblongata through the foramen magnum into the vertebral canal.

It is less severe, and some people may be asymptomatic but as people get older symptoms might start appearing (symptoms are similar to above).

If a person is diagnosed with this there is surgical treatment and prognosis is great, however in tonsillar herniation treatment is directed to hemorrhage or tumor causing the herniation and so it is more difficult.

Central herniation

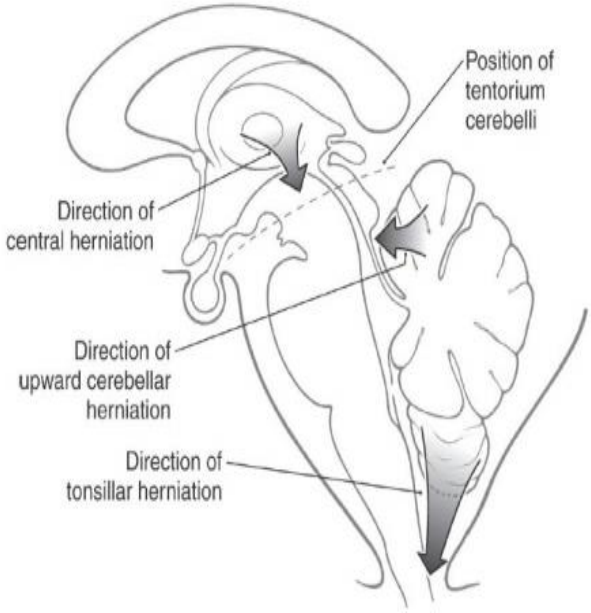

Notice the direction of herniation.

Cause: space occupying lesion in the hemisphere (supratentorial compartment, above the tentorium cerebri) elevates intracranial pressure and forces the diencephalon downward through the tentorial notch and into the brainstem affecting the midbrain mainly.

Symptoms: change in respiration, eye movements are irregular.

As the damage progresses downward into the brainstem, there is significant change in respiration

Tachypnea and apnea

profound loss of motor and sensory functions.

probable loss of consciousness

Decorticate posture may occur as the pressure affects the fibers heading to the brainstem (UMN), where the lower limbs are extended and upper limbs are flexed but as herniation develops decerebrate may occur and this is a bad sign because it means the lesion is close to the vital centers.

Upward Cerebellar Herniation

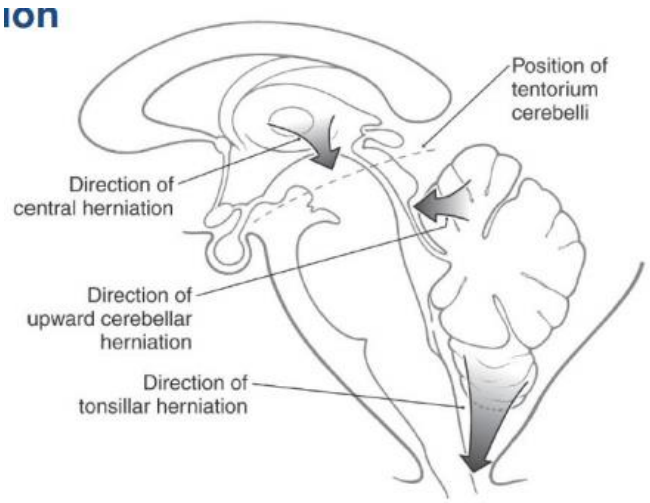

A mass in the posterior cranial fossa may force portions of the cerebellum upward through the tentorial notch (upward cerebellar herniation) and compress the midbrain rather than causing tonsillar herniation.

The result may be occlusion of branches of the superior cerebellar artery with resultant infarction of cerebellar structures or obstruction of the **cerebral aqueduct** and *hydrocephalus*.

accumulation of fluids will lead to an increase in intracranial pressure causing vomiting, headache, lethargy, decreased levels of consciousness.

Uncal Herniation

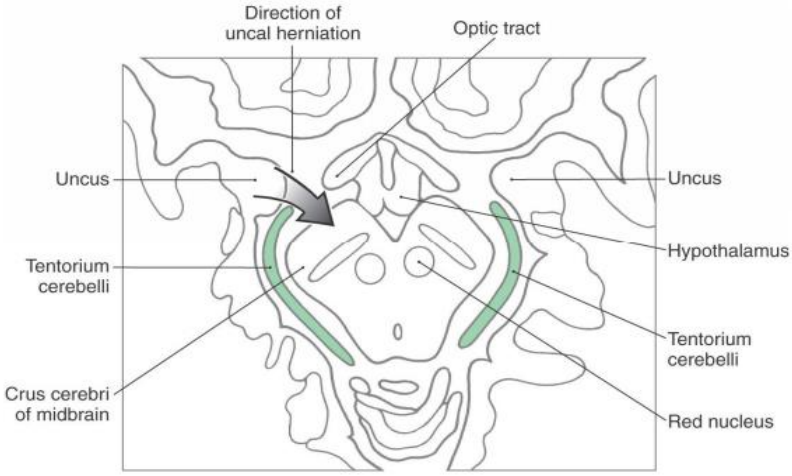

Movement of the uncus (anteromedial part of the temporal lobe) downward over the edge of the tentorium cerebelli, causing pressure on the midbrain.

Early signs:

dilated pupil ipsilateral to the herniation (involvement of oculomotor)

abnormal eye movements ipsilateral to the herniation (oculomotor nerve)

double vision ipsilateral to the herniation (loss of synchrony of movement of the eyes).

Weakness of the extremities (corticospinal fiber involvement) opposite to the dilated pupil.

Later:

respiration is affected

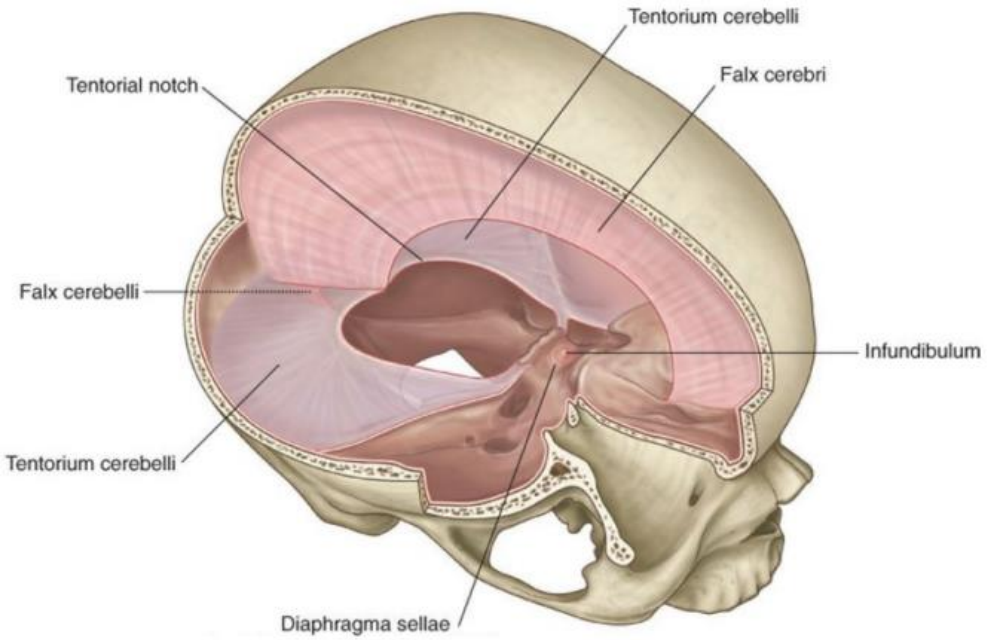

- **Falx cerebri:** crescent-shaped, Attachments:
  - **Anterior**: crista galli **Posterior**: tentorium cerebelli
- **Tentorium cerebelli:** horizontal, Attachments:
  - **Anteriolateral**: superior border of the petrous. **Posterior**: occipital bone, **Anteriolmedial:** free, tentorial notch