ANATOMY

SHEET NO. 9

WRITER : Doctor 018

CORRECTOR : Rawan Fratekh

DOCTOR : Mohammad Alsalem

Midbrain (superior part of brainstem)

It lies between the diencephalon and the pons.
There are 2 peduncles called **cerebral peduncles** (NOT cerebellar).
Between the two cerebral peduncles there is the **interpeduncular fossa** (Oculomotor nerve #3 originate from this fossa anteriorly).

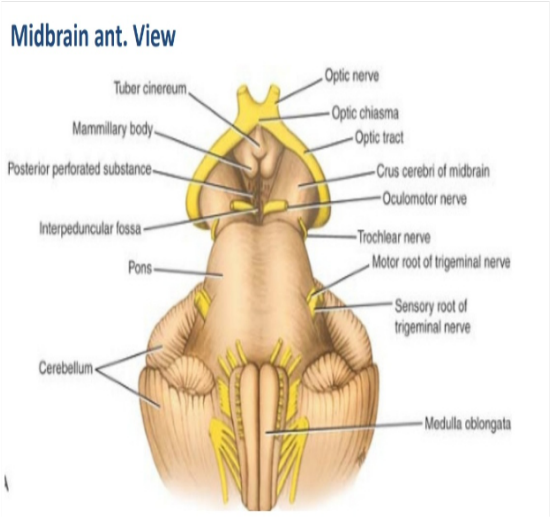

The cavity of the midbrain is known as the cerebral aqueduct. The cerebral aqueduct is the passageway between the 3rd (superiorly) and 4th ventricle (inferiorly).

- 3rd ventricle is the cavity of the diencephalon, 4th ventricle is the cavity of hind brain

Posterior to the cerebral aqueduct is the **tectum.** The tectum consists of 4 colliculi, 2 superior colliculi and 2 inferior colliculi (refer to page 4)

Anterior to the cerebral aqueduct is collectively known as the cerebral peduncle.

The cerebral peduncle is divided by the substantia nigra to **crus cerebri** (anterior) and **tegmentum** (between cerebral aqueduct and substantia nigra)

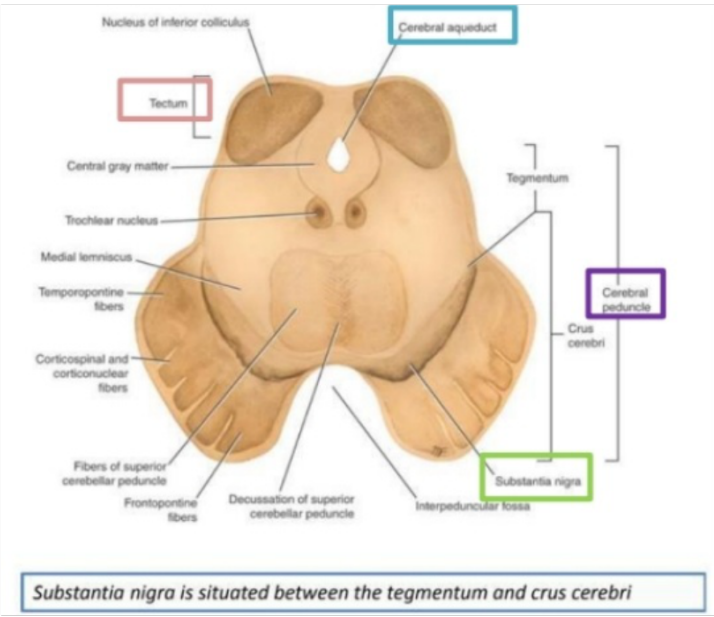

Posterior view of midbrain

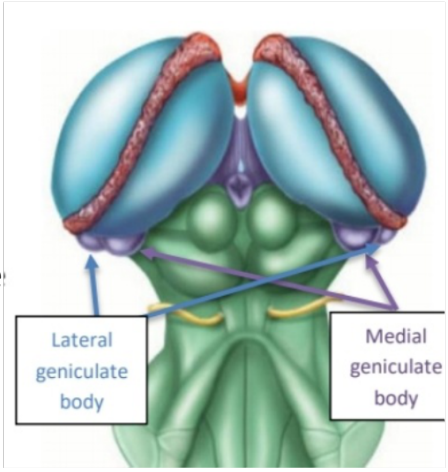

In this view, the 4 colliculi of the tectum can be seen.

The trochlear nerve (CN4) is the only cranial nerve that arises posteriorly. It arises from the posterior aspect of the midbrain.
Supplies superior oblique muscle of the eye.

In the figure on the right, the two thalami can be seen. They are divided into right and left thalami by the 3rd ventricle. Third ventricle is connected to the fourth ventricle by cerebral aqueduct.

The thalami are egg-shaped pieces of grey matter and contain multiple nuclei. It contains the medial geniculate body (part of the auditory pathway) and lateral geniculate body (part of thevisual pathway).

Superior brachium (brachium=الذراع) connects the superior colliculus with the lateral geniculate body. (connecting the visual with visual)
Inferior brachium connects the inferior colliculus with the medial geniculate body. Both are pieces of white matter.

It is important to be able to recognize the midbrain in a cross-section.
Notice the left and right crus cerebri with the interpeduncular fossa between them.
The cavity of the midbrain is the cerebral aqueduct.
Substantia nigra can be seen, which is a very important structure for the motor system.
Substantia nigra is anatomically located in the midbrain. However, it is related to the **basal nuclei functionally**. It is responsible for initiating movements. (more details in next lecture)

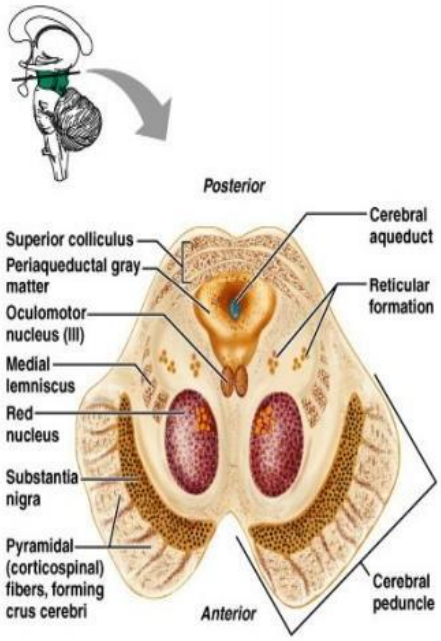

(a) Midbrain

1. Level of inferior colliculus

The cavity of the section is the cerebral aqueduct.

Anything posterior to the cerebral aqueduct is the tectum, anything anterior to it is the cerebral peduncle (substantia nigra divides the cerebral peduncle to tegmentum (posterior) and crus cerebri (anterior))

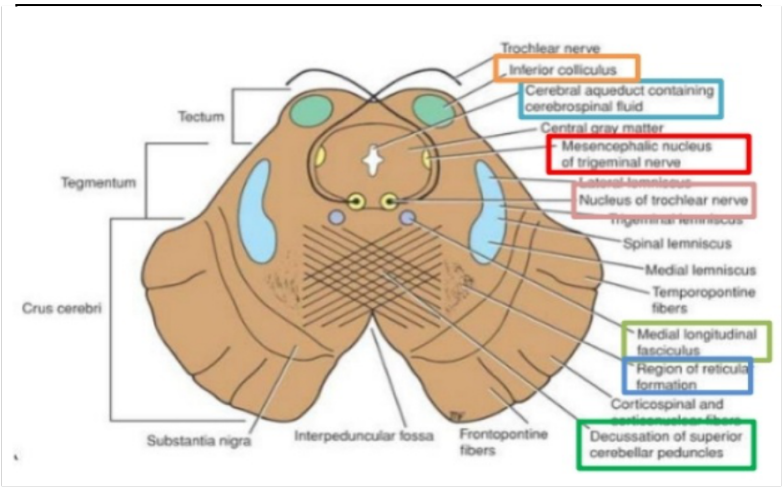

Regarding this section, posterior to the cerebral aqueduct are the inferior colliculi.

Anterior to the cerebral aqueduct is the nucleus of trochlear nerve (CN4) which is **motor**.
Notice the route of the lower motor neuron of the trochlear nerve. Upon the synapsis of the upper motor neuron of trochlear nerve at this nucleus, lower motor neurons arise and they turn posteriorly around the cerebral aqueduct & the mesencephalic nucleus of trigeminal nerve to emerge from the posterior aspect of the midbrain. (CN4 is the only cranial nerve arising from the posterior aspect of brainstem)

Medial longitudinal fasciculus (MLF) is anterolateral to the trochlear nucleus. It connects the motor nuclei of cranial nerves responsible for eyeball movement (CN3, CN4, CN6) with the vestibular nuclei and the upper cervical segments.

In this section you can see the decussation of superior cerebellar peduncles [at the level of the inferior colliculus], which willeventually form the superior cerebellar peduncle and move towards the cerebellum.
Example on fibers found in the superior cerebellar peduncle are the **dentothalamic** (from dentate nucleus to the thalamus) **fibers** and the fibers of the **globose-emboliform-rubral pathway**.
The dentate nucleus is located most laterally and it's the biggest of the cerebellar nuclei. Globose and emboliform are two very similar nuclei located near the midline, Together they're called Interposed nucleus. Fastigial nucleus is located in the middle.

Just a reminder: (not very important as it was explained in previous lectures)
The cerebellum is formed from gray matter (outside) known as the cerebellar cortex and beneath it is the subcortical white matter. Within this white matter, there are 4 deep cerebellar nuclei. Dentate (most lateral), globose, emboliform, and fastigial (most medial)
Don't Eat Greasy Food

The reticular formation can be seen lateral to the decussation of the superior cerebellar peduncle. The reticular formation extends from the medulla oblongata to the midbrain.

On either side of the cerebral aqueduct, the mesencephalic nucleus of trigeminal nerve can be seen. This nuclei is named so because it exists in the midbrain. (mesencephalon=midbrain)
Therefore, the trigeminal nerve has 3 sensory nuclei:

1. Main/principle nucleus
2. Spinal nucleus of trigeminal nerve
3. Mesencephalic nucleus of trigeminal nerve

It also has one motor nuclei.

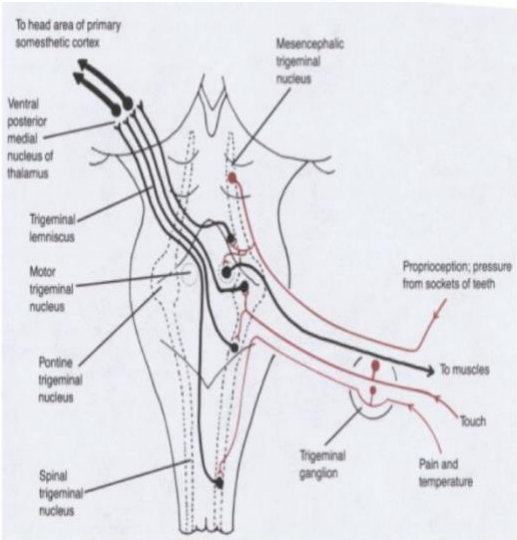

Crus cerebri

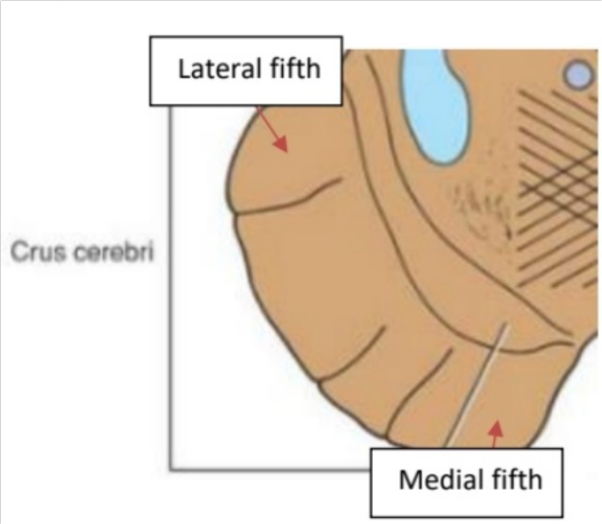

The crus cerebri, which is found on the anterior surface of the midbrain, is divided into 5 sections (five fifths). There is the lateral fifth, medial fifth, and the middle 3 fifths.
The middle 3 fifths are where the fibers of corticospinal tract descended.
The lateral fifth is the **Temporopontine fibers.**
The medial fifth is the **Frontopontine fibers.**
All of these tracts are descending.
These descending tracts connect the cerebral cortex with the spinal cord, cranial nerve nuclei, pons, and cerebellum.

Substantia Nigra

Posterior to the crus cerebri is the **susbtantia nigra**, which separates it from the tegmentum. It is darkly stained due to the presence of dopaminergic neurons & the high levels of melanin.

Anatomically, it is part of the **midbrain**. However, it is part of the **basal nuclei functionally.**

The basal nuclei [pieces of grey matter within the white matter] includes the caudatenucleus, lentiform nucleus, and the amygdala.

Its function is related to the motor activity.

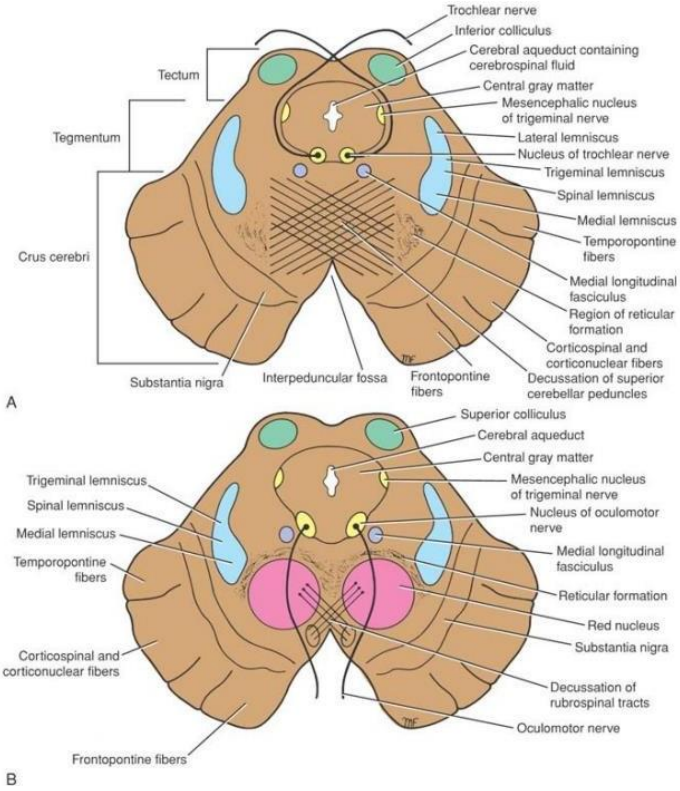

The function of the substantia nigra is to **initiate the movement (muscle tone)**. Degeneration of the substantia nigra will cause difficulty in **initiating movements** and is known as **Parkinson's disease**. Symptoms of Parkinson's disease include tremor and bradykinesia (difficulty in initiating movement) or even akinesia (inability to initiate movement).

Posterior to the substantia nigra, the four lemnisci are seen.

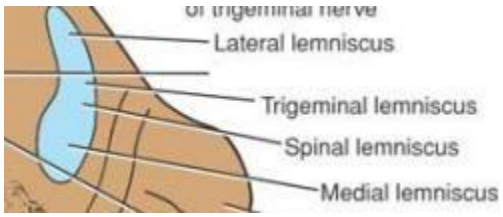

Medial lemniscus[1] is the most anterior and closest to the midline, followed by the **spinal lemniscus**[2] posteriorly, then the **trigeminal lemniscus**[3], and finally the **lateral lemniscus**[4] most posterior and lateral.

We're able to know that this is the level of the inferior colliculus because we don't see the **red nucleus** in this section.

2. Level of superior colliculus

Most features are shared with the previous level. Focus on the differences.

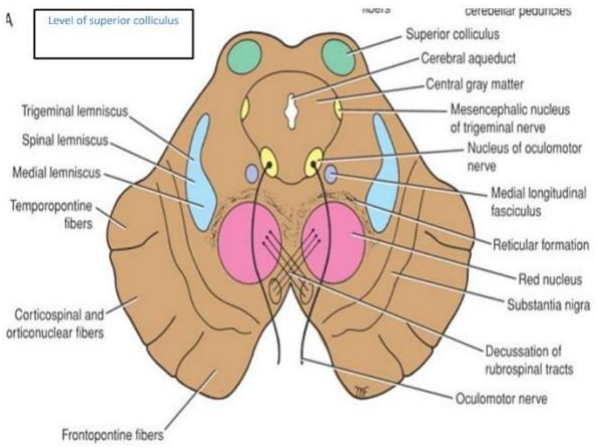

The cavity of this section is the cerebral aqueduct.
Posterior to the cerebral aqueduct is the **superior colliculus** (part of tectum)

The mesencephalic nucleus of trigeminal nerve is found on either side of the cerebral aqueduct.

Anterolateral to the cerebral aqueduct is the **nucleus of oculomotor nerve (CN3)**. It replaced the trochlear nucleus from the previous level. This nucleus is also motor.

Anterolateral to the oculomotor nucleus is the **medial longitudinal fasciculus (MLF).**

Notice that the **lateral lemniscus cannot be seen** on this level. This is because the lateral lemniscus route is towards the **inferior colliculus** of the previous section.

The **red (rubral) nucleus** is the main structure of this level. It is located **posterior** to the substantia nigra. (between substantia nigra & cerebral aqueduct)
It is the biggest nucleus in the **reticular formation** and round mass of gray matter.
The red nucleus named so because of its high **vascularity** and **iron containing pigment**).
The early **decussation of the rubrospinal tract** is seen on this level.
It receives afferent fibers from the cerebral cortex, cerebellum, substantia nigra, thalamic nuclei, and spinal cord.
It also gives off efferent fibers to the spinal cord, reticular formation, thalamus, and substantia nigra. It is involved in motor coordination.

The pretectal nucleus (close to the tectum) is associated with the light reflexes. It is close to the lateral part of the superior colliculus. (It is posterior to the superior colliculus)

Now we will start discussing the cranial nerves.

Oculomotor nerve (CN3):

It has a main motor nucleus located posterolaterally (discussed previously)
The oculomotor nerve has a **parasympathetic** component, which makes it different from the trochlear and the abducent nerves.
The **accessory parasympathetic nucleus of oculomotor nerve** is also known as the **Edinger-Westphal nucleus**.
This nucleus is located **posterolateral** to the main motor nucleus.

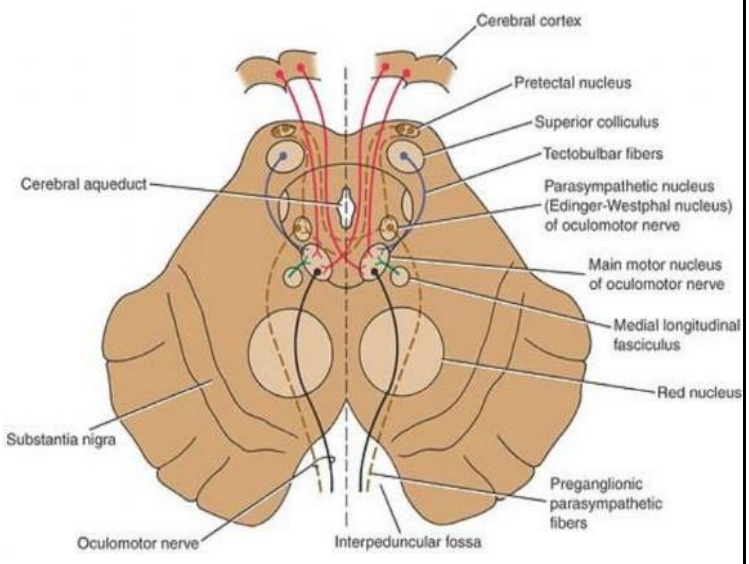

The fibers from the Edinger-Westphal nucleus and the motor fibers from the oculomotor nuclei pass through the red nucleus **(without synapse)** and emerge from the interpeduncular fossa.

The oculomotor nerve supplies **extrinsic muscles** such as the levator palpebrae superioris, superior rectus, medial rectus, inferior rectus, and inferior oblique (all eyeball muscles except the lateral rectus and superior oblique).
It also supplies **intrinsic muscles** such as the constrictor pupillae of the iris and ciliary muscles

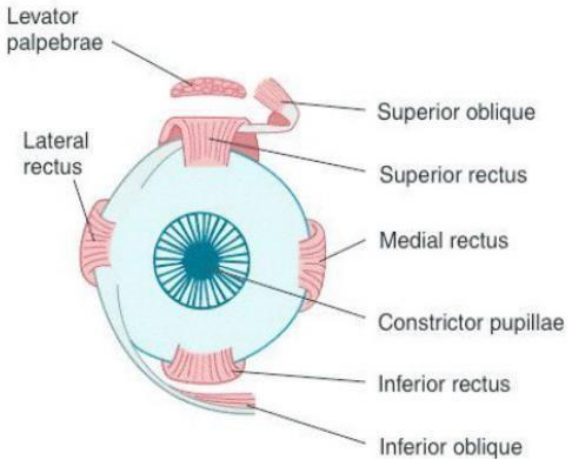

The action of the muscles supplied by the oculomotor nerve is lifting the upper eyelid, turning the eye upward, downward, and medially, ***constricting the pupil, and accommodating the eye*****.**

Remember that the corticonuclear tract (corticobulbar) is mainly a **bilateral tract**. Each cranial nerve nuclei (except part of CN12 & part of CN7) received bilateral (from both sides) of the cortex.

Nerve Course:

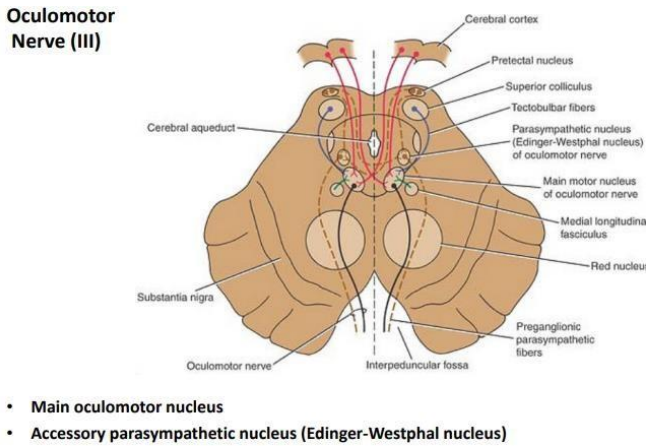

The motor and parasympathetic fibers from the two nuclei will **pass** through red nucleus **without synapse**. From the red nucleus, they then pass via the substantia nigra exiting **through the interpeduncular fossa**. Then they enter the middle cranial fossa in the **lateral wall of the cavernous sinus**.The nerve leaves the cranial cavity and enters the orbital cavity via the **superior orbital fissure** between the greater and lesser wing of sphenoid. Once there, it divides into two branches: superior and inferior rami, which supply most of the **extraocular muscles** .

Remember: the cavernous sinus is one of the Dural sinuses located on either side of the Sella turcica

NOTE:the parasympathetic fibers(**preganglionic**) pass through inferior ramus and synapse in the ciliary ganglion. They will come outas **postganglionic** fibers through **short ciliary nerve** which eventually will innervate the **intrinsic muscles of the eye**.

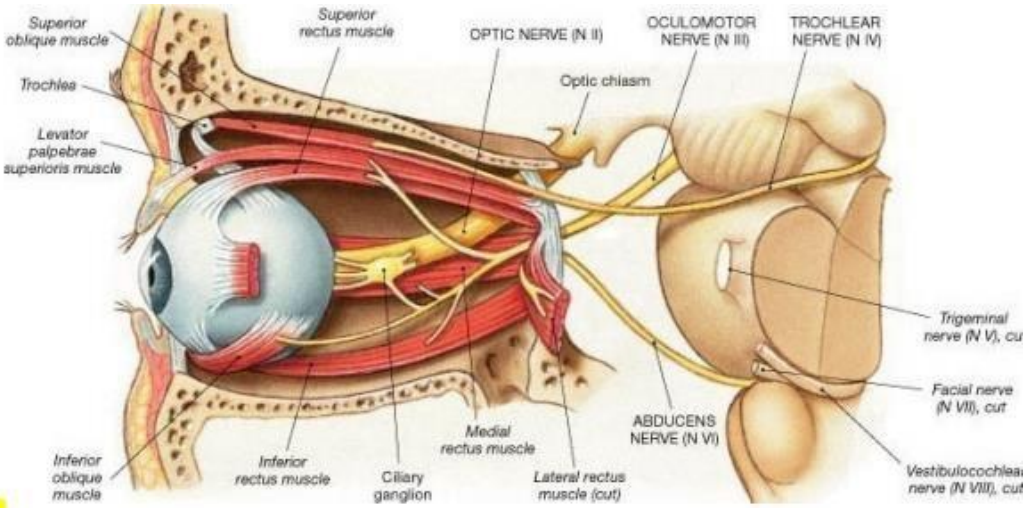

Course of occulomotor nerve

- Red nucleus
- Interpeduncular fossa
- Middle cranial fossa in the lateral wall of the cavernous sinus (Two rami)
- superior orbital fissure

Oculomotor nerve injury:

1) Complete lesion of oculomotor nerve:

Complete cut of the oculomotor nerve.

All of the muscles are paralyzed except lateral rectus and superior oblique.

Symptoms:

- ✓ **External strabismus**: in the resting position, the affected eye will turn laterally (externally). Occurs due to abduction via the **unopposed lateral rectus**, that is supplied by the abducent nerve, and that causes **diplopia**.

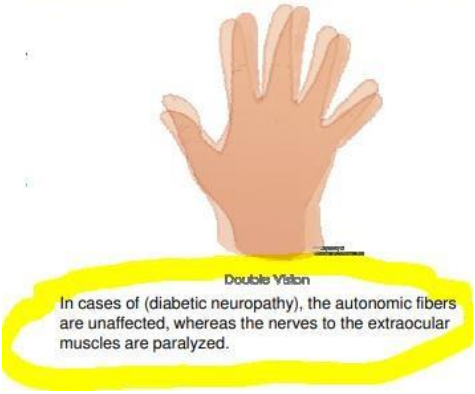

{The movement of the eye must be synchronized, oculomotor nerve complete lesion → loss of synchronization → Diplopia}.

- ✓ **Diplopia** (double vision)
- ✓ **Ptosis:** drooping of the upper eyelid due to paralysis of levator palpebrae superioris.
- ✓ **Mydriasis:** The pupil is widely dilated and nonreactive to light. Dilation is overriding.
- ✓ **Paralyzed accommodation**

Ophthalmoplegia: paralysis of one or more of the eye muscles.

2) Incomplete lesions:

- ❖ **Internal ophthalmoplegia**: Loss of the autonomic innervation of the sphincter pupillae and ciliary muscle.
  Symptoms → the pupil will be widely dilated and nonreactive to light only
  The parasympathetic fibers run superficial in the oculomotor nerve. So, if there was pressure applied on the nerve, the parasympathetic will be affected without the motor component. (The parasympathetic is more susceptible to injury).

- ❖ **External ophthalmoplegia**: paralysis of the extraocular muscles due to paralysis of the motor part of the oculomotor nerve.
  Symptoms → External strabismus, diplopia and ptosis ***only***

Example: ***diabetic neuropathy affects the motor fiber only.***

To sum up:

External ophthalmoplegia affects the motor part of the oculomotor nerve.

Internal ophthalmoplegia affects the autonomic (parasympathetic) part of the oculomotor nerve.

Total ophthalmoplegia affects both parts and occurs if the whole nerve is injured.

Trochlear Nerve (CN4):

It has one nucleus (motor nucleus), it receives inputs from both cortex: **Bilateral**.

- Location of the nucleus: it is found **anterior** to the cerebral aqueduct, at the **level of the inferior colliculi in the midbrain**.

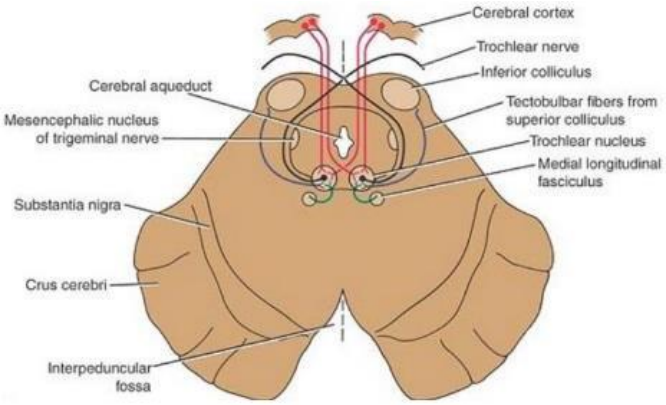

- Pass **posteriorly** around the central gray matter
- Immediately decussates

Nerve Course: Fibers go **posteriorly** around the cerebral aqueduct and mesencephalic nucleus and then they emerge from the posterior aspect of the midbrain. The fibers then turn around crus cerebri and move alongthelateralwallof the cavernoussinus (along withtheoculomotor nerve) entering the orbit of the eye via the superior orbital fissure to innervate the **superior oblique muscle.**

MSS RECALL the nerves that pass through superior orbital fissure: CN3 + CN4+ CN6 and the ophthalmic division of trigeminal

The superior oblique muscle passes through a structure called the **trochlea**, which is a pulley-like structure. This pulley-like system gives the superior oblique muscle its action, which is the **depression of the eyeball** (despite being inserted on its superior surface) and **lateral rotation** of eyeball. (moves the eye downward & lateral)

Trochlear nerve injury symptoms:

1- **Diplopia**
2- Difficulty in turning the eye downward and laterally.
So, at rest the patienteye will go **upward & medially**.

3- **Difficulty in descending stairs. Normally when you are descending stairs, only your eyes move downward, but in the case of this injury,** patient willtilt his head to the side opposite the paralyzed eye (**compensatory adjustment**). He will tilt his head to look at the floor.

Abducent nerve (CN6):

- Has **one motor nucleus** found **underneath the floor of fourth ventricle**,at the levelofthefacial colliculus (caudal part) of the pons.
It receives inputs from both cortex (bilateral).

Course of the nerve:

The abducent nerve leaves the brainstem anteriorly at the pontomedullary junction medial to the facial nerve. It then enters the cavernous sinus below and lateral to the internal carotid artery. From there it enters the orbit through the superior orbital fissure and innervates the **lateral rectus** muscle of the eye that turns the eye laterally.

Abducent Nerve injury symptoms:

1- **Diplopia**.
2- **Internalstrabismus:** Difficulty in turning the eye **laterally**, because the eye at rest is pulled medially by the overriding of medial rectus that is supplied by the oculomotor.