Valvular heart disease
and
prosthetic valve

Surface anatomy

MV: behind the Lt ½ of the sternum opp. the 4 th coastal cartilage

AV: behind the Lt ½ of the sternum opp. The 3 rd ICS

TV: behind the Rt ½ of the sternum opp. The4th ICS

PV: behind the medial end of the 3 rd LT CC & adjoining part of the sternum

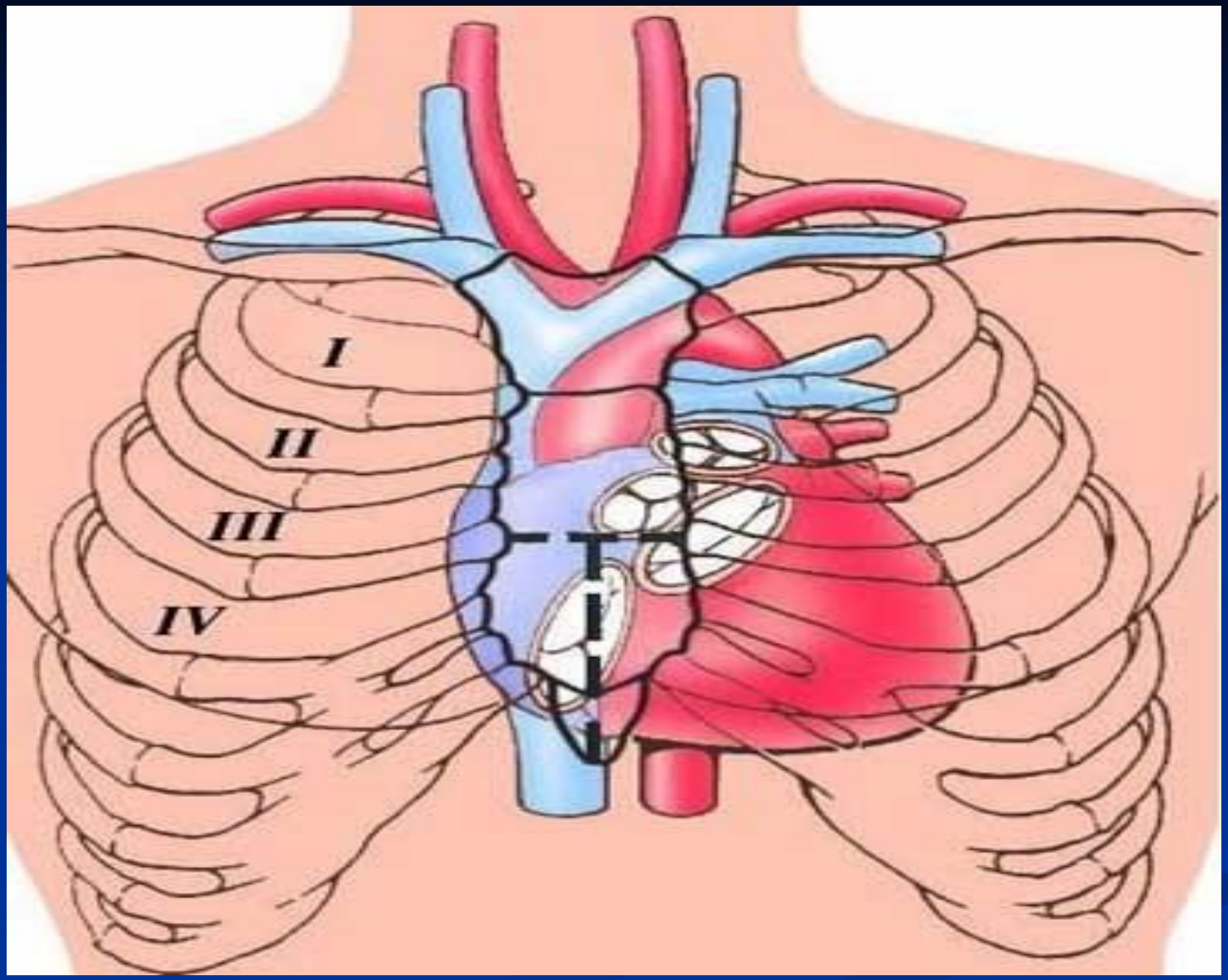
I
II
III
IV

Anatomy

MV:

2Cusps, Anterior and posterior

The Ant is the larger

Intervenes bet. A-V and aortic orifice

AV:

3 semilunar cusps, ant (RT), post. Wall (LT and post)

TV;

3cusps, ant, septal ,post.

PV;

3 semilunar cusps one post. (lt) tow ant(ant and rt)

Figure 3. The relationships of the mitral valve are important.

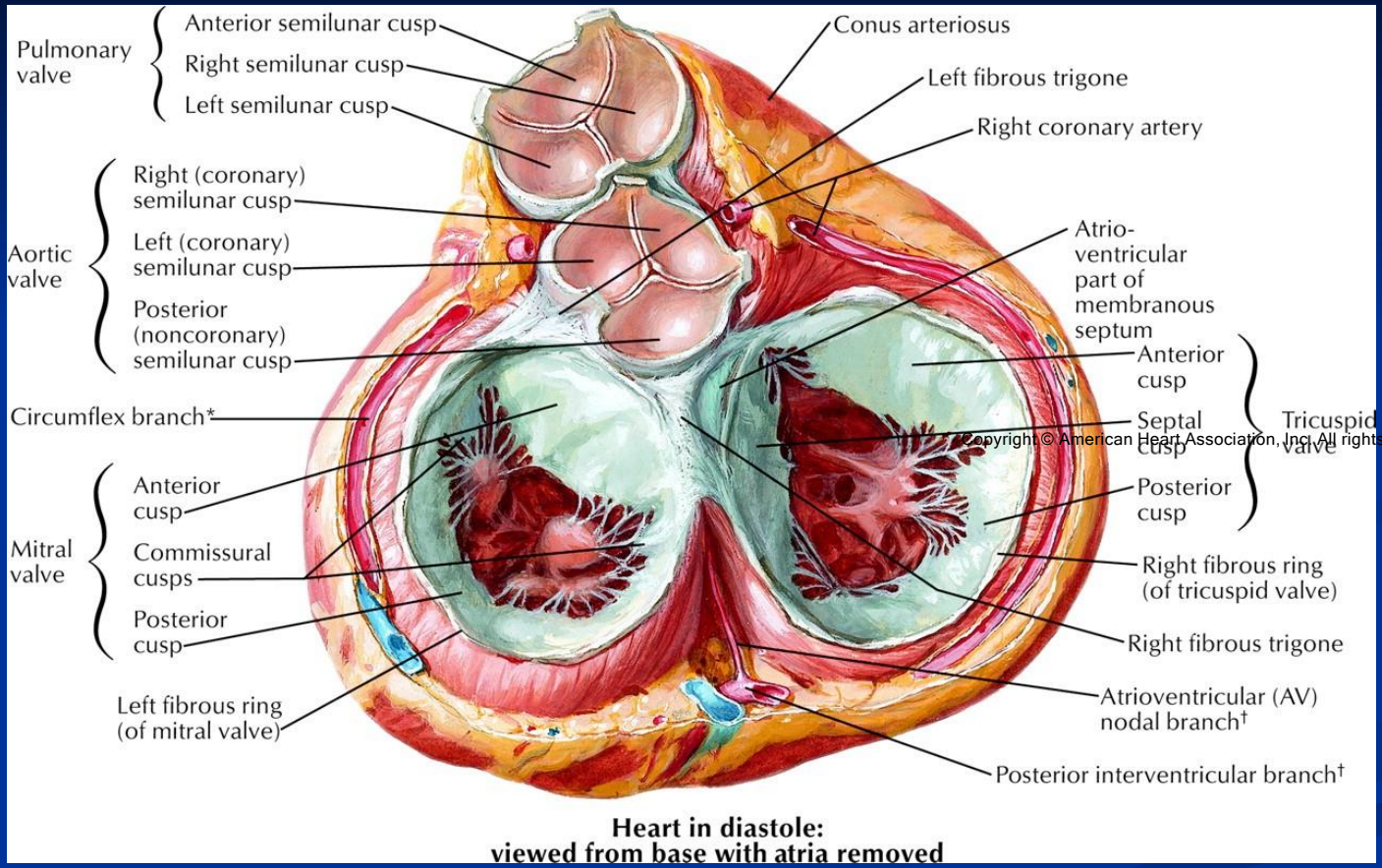

Fedak P W et al. Circulation. 2008;117:963-974

Aortic stenosis

Aetiology

Infants,children,adolescents

- Congenital aortic stenosis
- Congenital subvalvular aortic stenosis
- Congenital supravalvular aortic stenosis

Young adults to middle aged

Calcification and fibrosis of congenitally bicuspid valve

Rheumatic aortic disease

Middle aged to elderly

Calcification of bicuspid valve

Senile degenerative aortic stenosis

Rheumatic aortic disease

AS

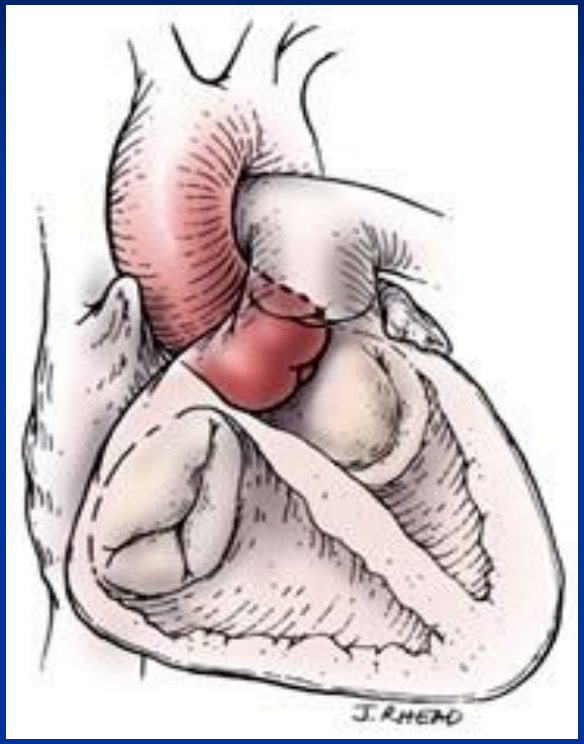

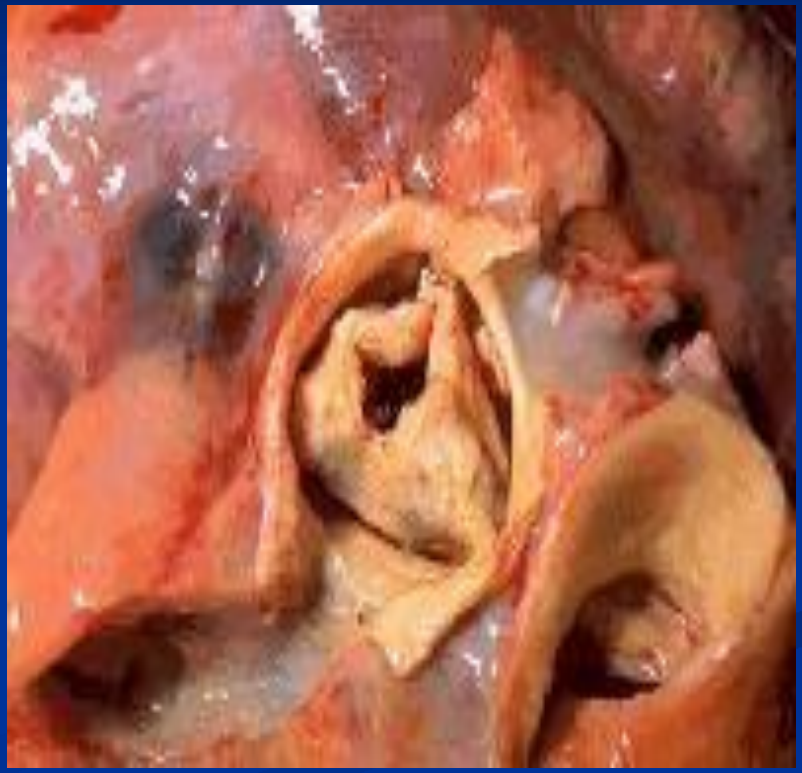

AVS

tricuspid and bicuspid calcifications

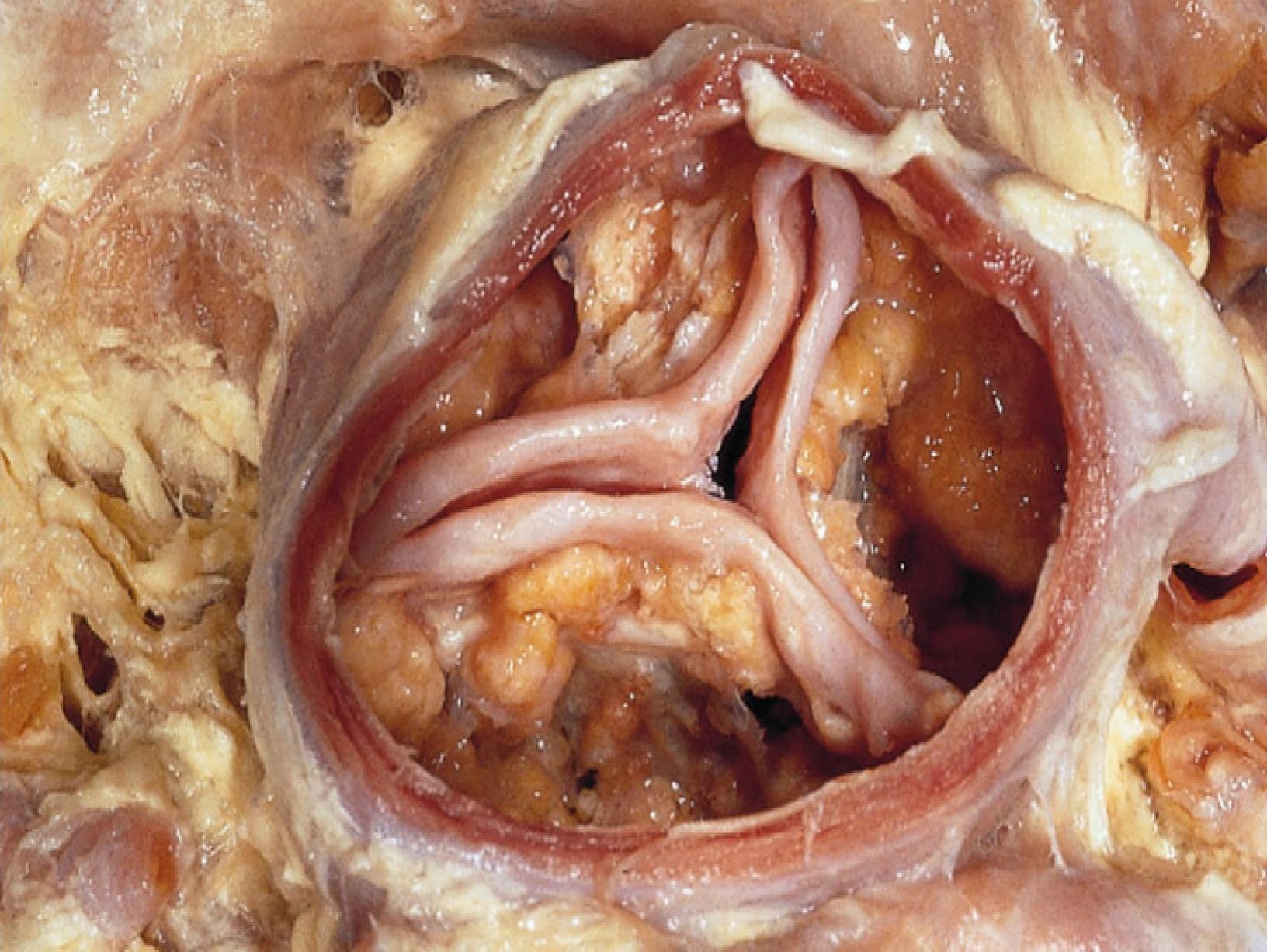

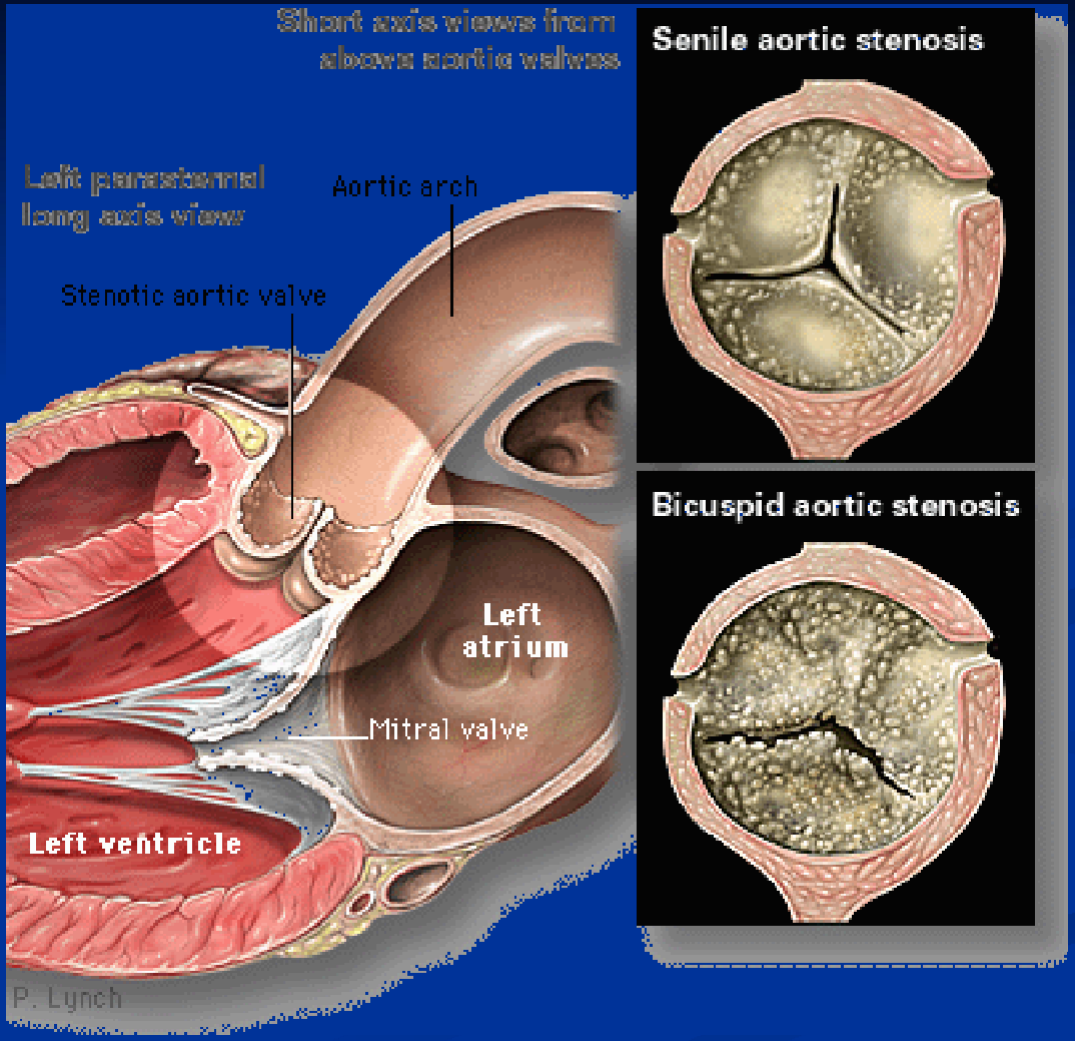
Short axis views from above aortic valves
Left parasternal long axis view
Aortic arch
Stenotic aortic valve
Left atrium
Mitral valve
Left ventricle
P. Lynch
Senile aortic stenosis
Bicuspid aortic stenosis

Pathophysiolgy of AS

Except in the congenital forms, AS develops slowly

The LV becomes increasingly hypertrophied, and coronary blood flow may become inadequate

The fixed outflow obstruction limits the increase in C.O required on exercise.

The progressive LV outflow obstruction results in increased LV mass.

Symptoms of AS

- Exertional dyspnoea
- Angina
- Pulmonary edema
- Exertional syncope
- Sudden death

Signs of AS

- Ejection systolic murmur
- Slow rising carotid pulse
- Reduce pulse pressure
- LV hypertrophy
- Signs of LV failure (crepitations, pulmonary edema)

Investigations

ECG

CXR

ECHO

CATH

ECG in AS

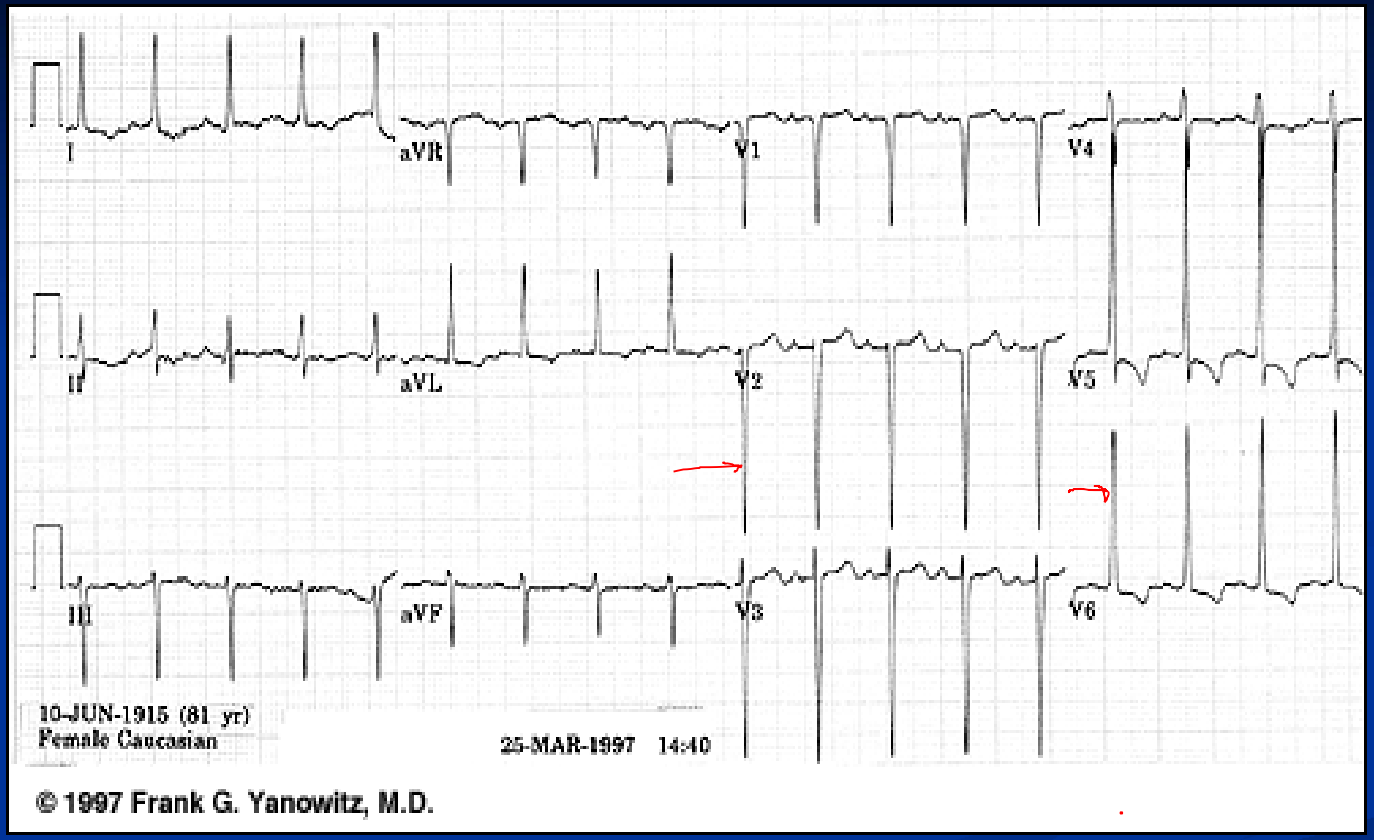

LVH with strain (slightly wide QRS in I,II,III and have increased amplitude)

Large S in V2 and large R in V6 with T wave inversion in V6

CXR in AS

AORTIC STENOSIS ,
dilated ascending aorta,
normal heart size

ECHO criteria for assessment of aortic stenosis

Aortic valve area (cm2)	Mean gradient(mmhg)	severity
>1.5	<25	mild
1-1.5	25-45	moderate
<1	>45	severe
<0.7	>70	critical

Management

Medical; Medical treatment essentially is reserved for patients who have complications of AS such as heart failure, infective endocarditis, or arrhythmias.

Surgical; The primary management of symptomatic patients with valvular AS is interventional

Aortic regurgitation

Aetiology

Congenital

Bicuspid valve, or disproportionate cusps

Acquired

Rheumatic disease

Infective endocarditis

Trauma

Aortic dilatation: marfan syndrome, atheroma, syphilis, ankylosing spondylitis

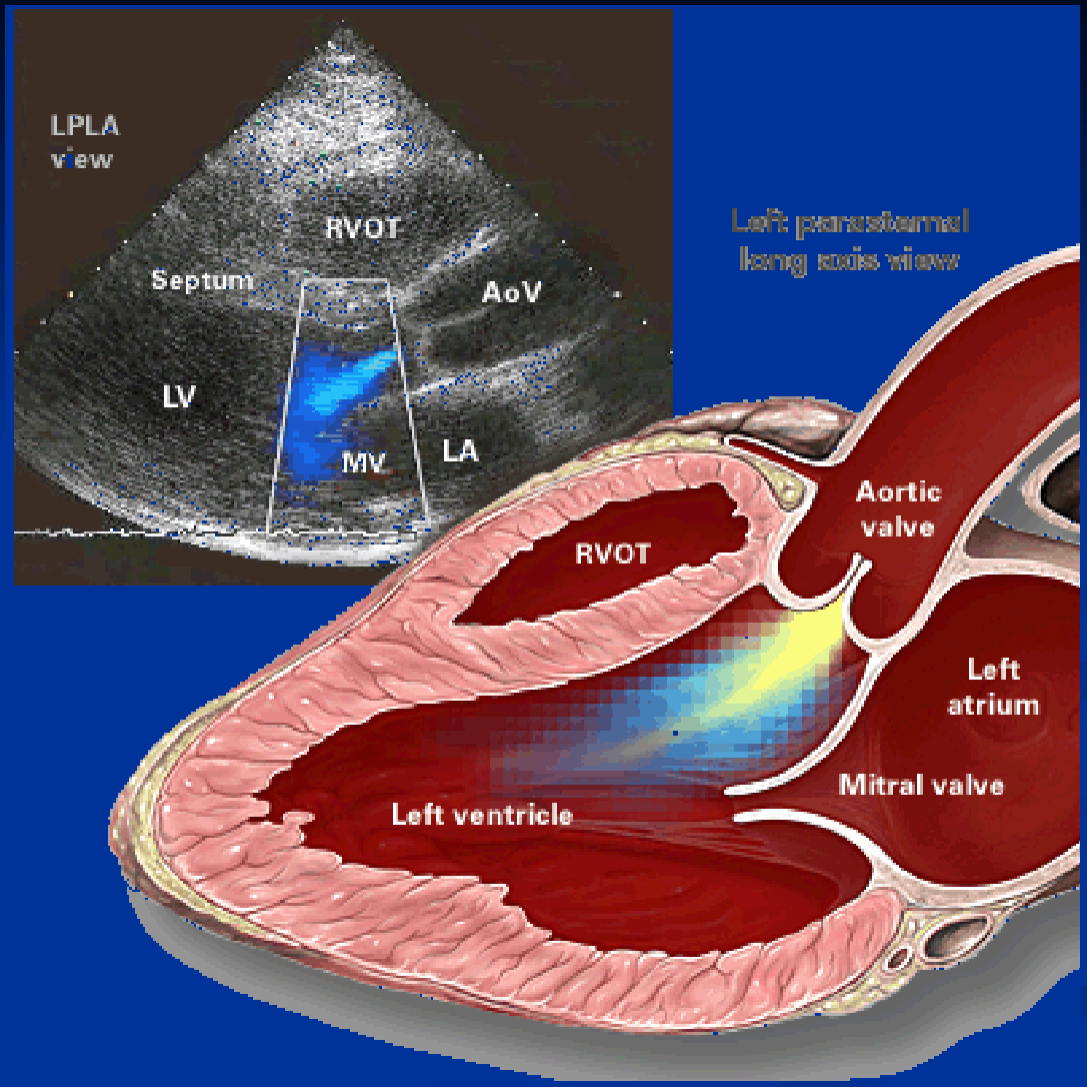
LPLA
view
RVOT
Septum
AoV
LV
MV
LA
Left parasternal
long axis view
Aortic
valve
RVOT
Left
atrium
Mitral valve
Left ventricle

pathophysiology

The stroke output of the LV may be doubled or trebled

LV dilated and hypertrophied

In acute AR, The LV poorly accommodates the abrupt increase in end-diastolic volume, and diastolic filling pressure increases rapidly. The rise in LV filling pressure is transmitted to the LA, pulm. veins, and pulm. capillaries, leading to pulm.edema and congestion.

Clinical features
symptoms :

Mild AR ;

asymptomatic

palpitations

Severe AR ;

Symptoms of heart failure

angina

Signs of AR

- Large volume or ‘collapsing’ pulse
- Bounding peripheral pulses
- Early diastolic murmur
- Systolic murmur of increased stroke volume
- Signs of heart failure

Investigations

ECG

CXR

MRI , CT scan

ECHO

CATH

ECG in AR

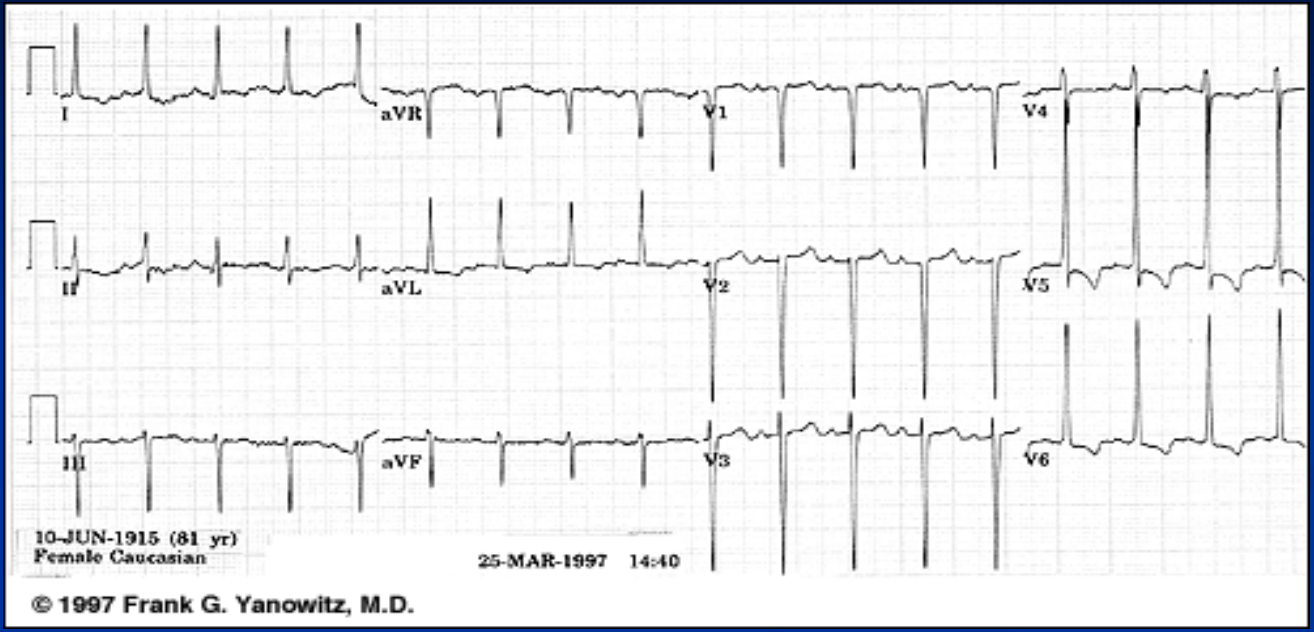

LVH with strain (slightly wide QRS in I,II,III and have increased amplitude

Large S in V2 and large R in V6 with T wave inversion in V6

Left atrial enlargement Left axis deviation

CXR in AR

Enlarged thoracic aorta

cardiomegaly

ECHO in AR

- Dilated LV
- Hyperdynamic ventricle
- Fluttering anterior mitral leaflet
- Doppler detects reflux

Treatment of AR

Medical

Vasodilator therapy.

Treat asymptomatic patients with chronic severe AR and dilated but normal LV systolic function medically, and monitor their cases for development of indications for AVR. Patients with mild AR and normal LV size require no therapy other than endocarditis prophylaxis

The treatment of choice for acute AR is AVR. Medical therapy can be used as a bridge to surgery but should not replace it.

Treatment of AR

Surgical

Surgical treatment of AR almost always requires replacement of the diseased valve with a prosthetic valve

AVR is indicated when AR is beginning to cause sx or when an enlarging heart or progressive ECG changes give evidence of increasing LV overload

Surgical treatment of AR

Asymptomatic patients with evidence of LV systolic dysfunction (EF <0.50) should undergo AVR.

Asymptomatic patients with severe AR and normal LV function but with severe LV dilatation (end-diastolic dimension >75 mm or end-systolic dimension >55 mm) should undergo AVR..

Prosthetic heart valve

The two main prosthetic valve designs include:

mechanical

bioprosthetic(tissue) heart valves

Mechanical valves

ball and cage

bileaflet

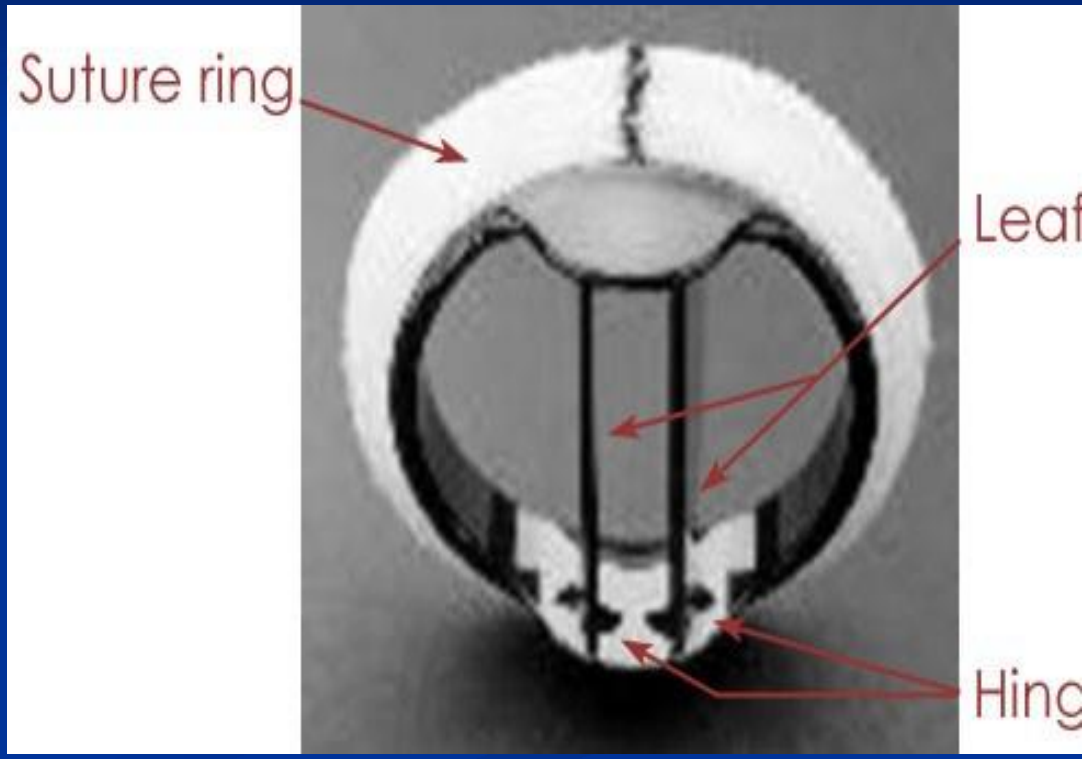

Bioprosthetic Valves

Aortic homograft

Human tissue valves

autograft

homograft

Animal tissue valves

Heterograft or xenograft

Animal Tissue Valves

The most commonly used animal tissues are: porcine, which is valve tissue from a pig, and bovine pericardial tissue, which is from a cow.

The leaflet valve tissue of the animals is inspected, and the highest quality leaflet tissues are then preserved. They are then stiffened by a tanning solution, most often glutaraldehyde.

Transcatheter Aortic Valve Intervention

Recently, percutaneous valve replacement has been developed. TAVI is a reasonable alternative to surgical AVR in patients at high surgical risk. .

Procedure & Hardware

LA + Conscious sedation/ GA, hemodynamic stability [SBP~120 mm Hg / MAP >75 mm Hg]

Vascular access Sites transfemoral transapical

Thoracotomy catheter

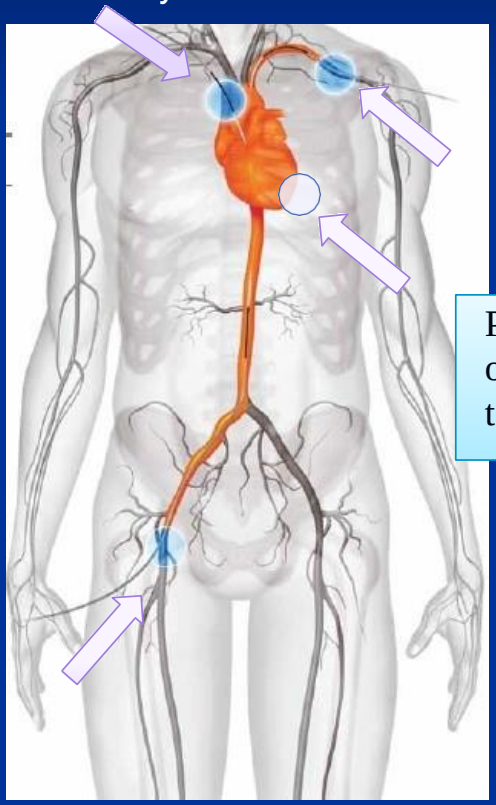

Percutaneous or Cut-down technique

TAVI Route

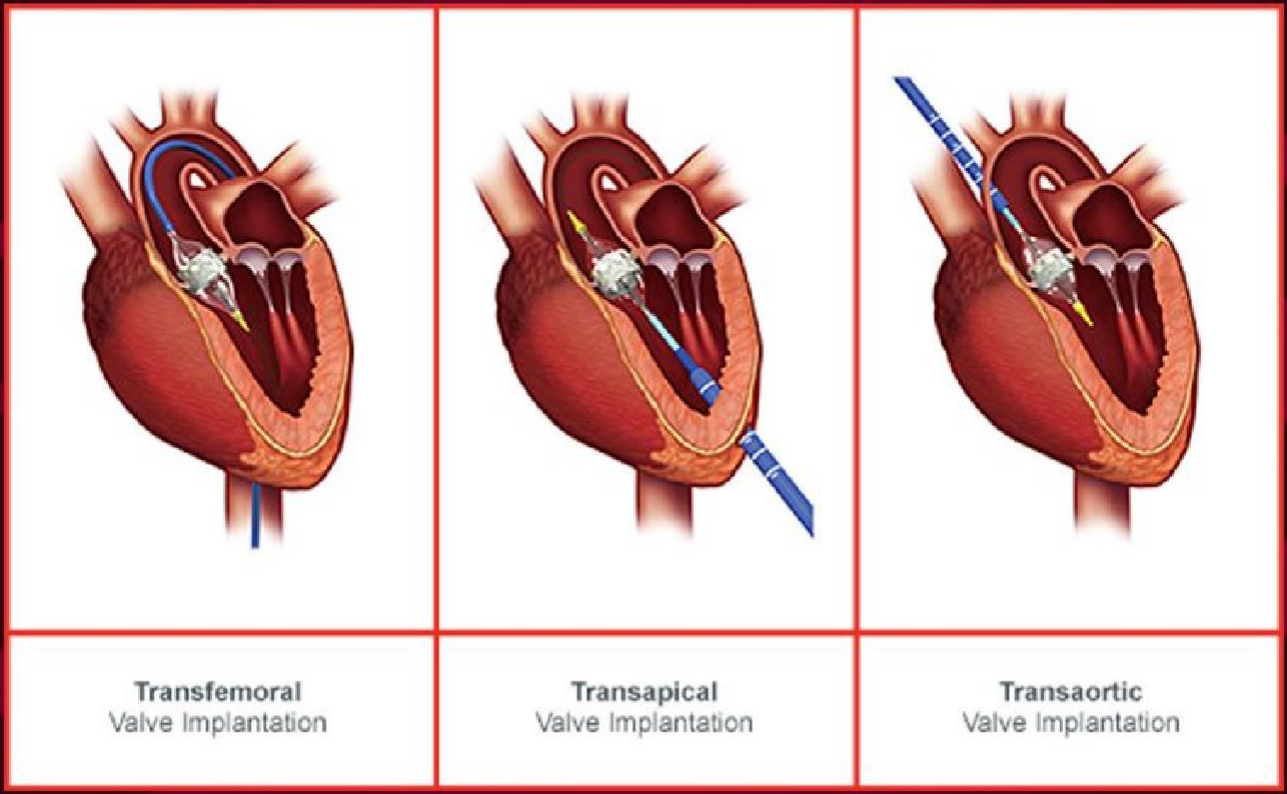
Transfemoral
Valve Implantation
Transapical
Valve Implantation
Transaortic
Valve Implantation

images

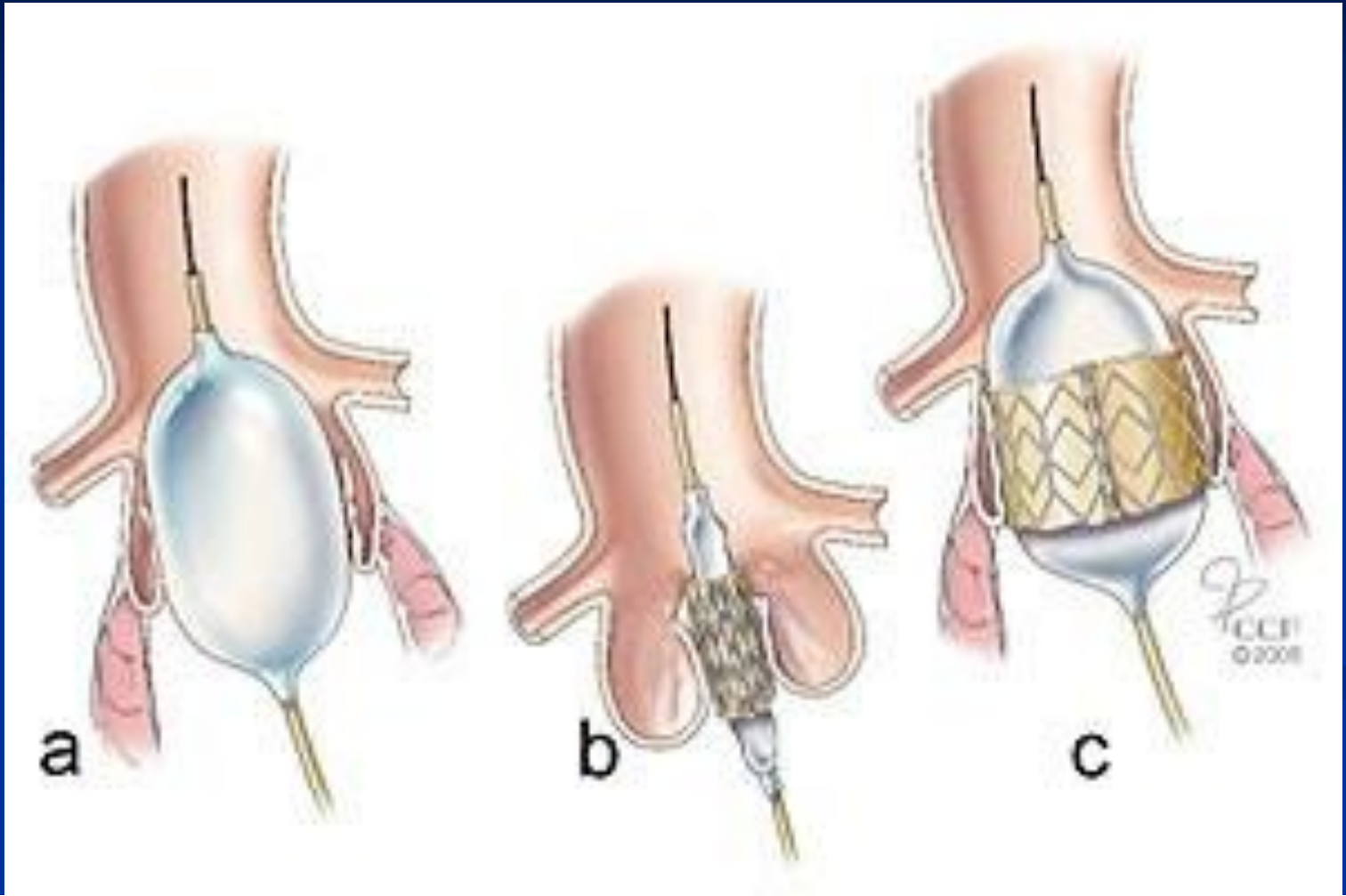

How to choose a valve

Mechanical valve in patients < 65years .

Tissue valves in patients > 65 years

Tissue valves in patients whose life expectancy is < 10 year

Tissue valve in patients who have problems which are likely to cause life threatening bleeding.

Valve types

Bioprosthetic/Tissue

No lifetime warfarin

Less durability

Mechanical valve

Need for warfarin

Better durability

ACC/AHA guideline summary: Antithrombotic therapy in patients with mechanical heart valves

Class I - There is evidence and/or general agreement that antithrombotic therapy in indicated in patients with mechanical heart valves in the following settings:
• Warfarin to achieve a goal INR of 2.0 to 3.0 after:
1. Aortic valve replacement (AVR) with bileaflet mechanical or Medtronic Hall valves if no risk factors* are present.
• Warfarin to achieve a goal INR of 2.5 to 3.5 after:
1. AVR with bileaflet mechanical or Medtronic Hall valves if risk factors* are present.
2. AVR with Starr-Edwards or disc valves other than Medtronic Hall if no risk factors* are present.
3. Mitral valve replacement (MVR) with any mechanical valve.
• Role of aspirin:
1. After AVR or MVR in patients who cannot take warfarin, at a dose of 75 to 325 mg/day.
2. At a dose of 75 to 100 mg/day in addition to warfarin in all patients with mechanical valves and in patients with biological valves who have risk factors*.
Class IIa - The weight of evidence or opinion is in favor of the usefulness of antithrombotic therapy in patients with mechanical heart valves in the following settings:
• In the first three months after AVR, warfarin to achieve a goal INR of 2.5 to 3.5.
Class IIb - The weight of evidence or opinion is less well established for the usefulness of antithrombotic therapy in patients with mechanical heart valves in the following setting:
• In high-risk patients in whom aspirin cannot be used, clopidogrel (75 mg/day) or warfarin to attain a goal INR of 3.5 to 4.5.

* Risk factors include atrial fibrillation, prior thromboembolism, left ventricular dysfunction, and a hypercoagulable state.

Data from Bonow, RO, Carabello, BA, Chatterjee, K, et al. ACC/AHA 2006 guidelines for the management of patients with valvular heart disease. A report of the American College of Cardiology/American Heart Association Task Force on Practice Guidelines (Writing committee to revise the 1998 guidelines for the management of patients with valvular heart disease). J Am Coll Cardiol 2006; 48:e1.

Mitral stenosis

Aetiology

Isolated MS accounts for 25% of all rheum. Heart dis., and an additional 40% have mixed MS and MR

2/3 of cases occurs in women

Acquired MS is almost entirely rheum. in origin

Aetiology of MS

Acquired MS results from long-term damage to the mitral valve and its supporting structures.:

In rheumatic heart disease

SLE

Amyloidosis

Postsurgical acquired MS, such as MS occurring after mitral valve annuloplasty for severe MR.

Sever MS MS

FISH MOUTH (RHD)

Pathophysiology of MS

The normal adult mitral valve orifice cross-sectional area is 4-6 cm2.

When reduced to 2 cm2, hemodynamically significant MS occurs. WHEN <1cm2 it is critical

As a compensating mechanism, pulmonary vasoconstriction develops, causing pulmonary hypertension.

Severe MS results in decreased cardiac output

MS Pathophysiology

Progressive Dyspnea (70%): LA dilation ¾pulmonary congestion (reduced emptying)

worse with exercise, fever, tachycardia, and pregnancy

Increased Transmitral Pressures: Leads to left atrial enlargement and atrial fibrillation.

Right heart failure symptoms: due to Pulmonary venous HTN

Hemoptysis: due to rupture of bronchial vessels due to elevated pulmonary pressure

Signs of MS

AF

Loud 1st heart sound, opening snap, mid-diastolic murmur

Signs of raised pulm capillary pressure (crepitations,pul edema, effusions)

Signs of pul HTN.

Investigations of MS

ECG

LA hypertrophy if not in AF

Left atrial enlargement is illustrated by increased P wave duration in lead II, top ECG, and by the prominent negative P terminal force in lead V1, bottom tracing

Investigations of MS

ECG

RVH

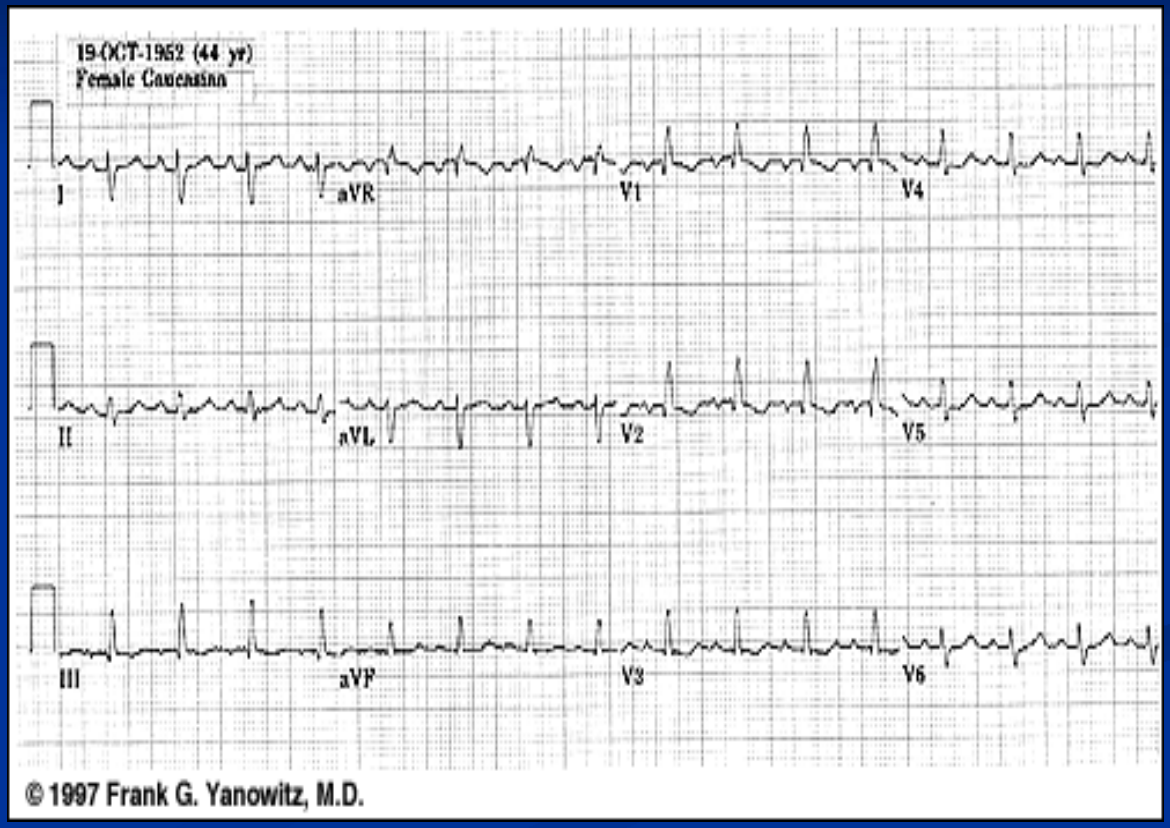

CXR

Chest radiograph of a patient with mitral stenosis shows pulmonary hypertension, mild cardiomegaly and enlargement of the left atrium (arrow) and pulmonary artery

ECHO

Thickened immobile cusps

Reduced rate of diastolic filling

Reduced valve area

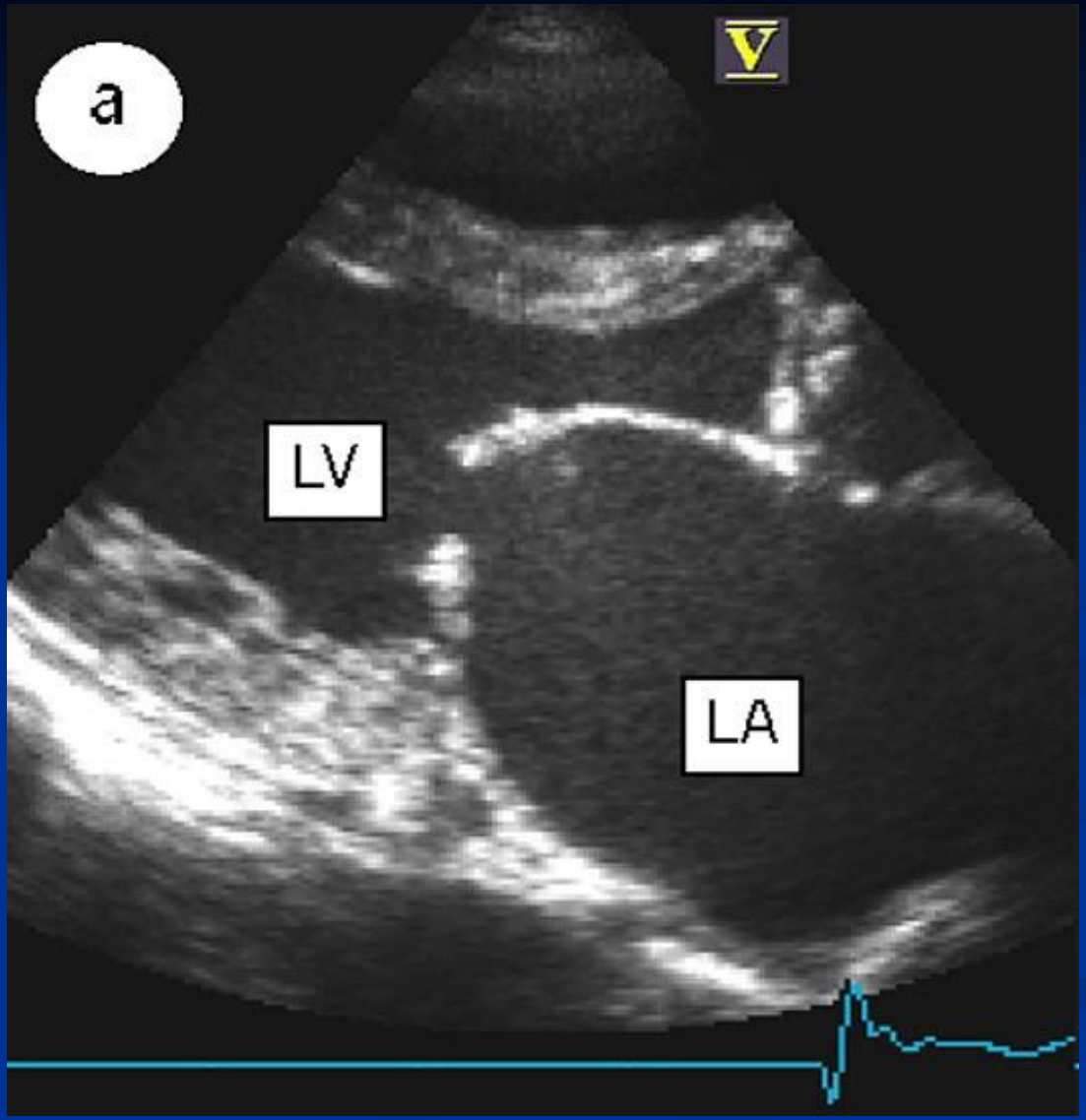
a
V
LV
LA

Treatment of MS

medical

- Asymptomatic patients with mild MS require yearly follow-up
- For the patient with signs or symptoms of CHF, diuretics may provide benefit
- RX of Tachyarrhythmias
- Electrophysiologic ablation of atrial fibrillation or flutter circuits may be performed in the catheterization laboratory

Percutaneous mitral balloon valvuloplasty

Indications for this procedure are similar to those for surgery, including

CHF unresponsive to medical management

asymptomatic patients with a pulmonary artery (PA) systolic pressure of 50 mm Hg or greater.

In some centers, the procedure is successful in 80-90% of selected cases. The procedural mortality rate is 1-2%.

Treatment

surgical

Indications:

Symptomatic mitral stenosis especially if peripheral emboli

Mitral valve area less than 1 cm2

Mitral valvotomy

Commissurotomy consists of an incision of fused mitral valve commissures and shaving of thickened mitral valve leaflets

Fused chordae tendineae and papillary muscles can be divided to relieve subvalvular stenosis.

Supravalvular tissue contributing to the MS should be resected.

Treatment

surgical

Mitral valve replacement with mechanical valve or bioprosthesis

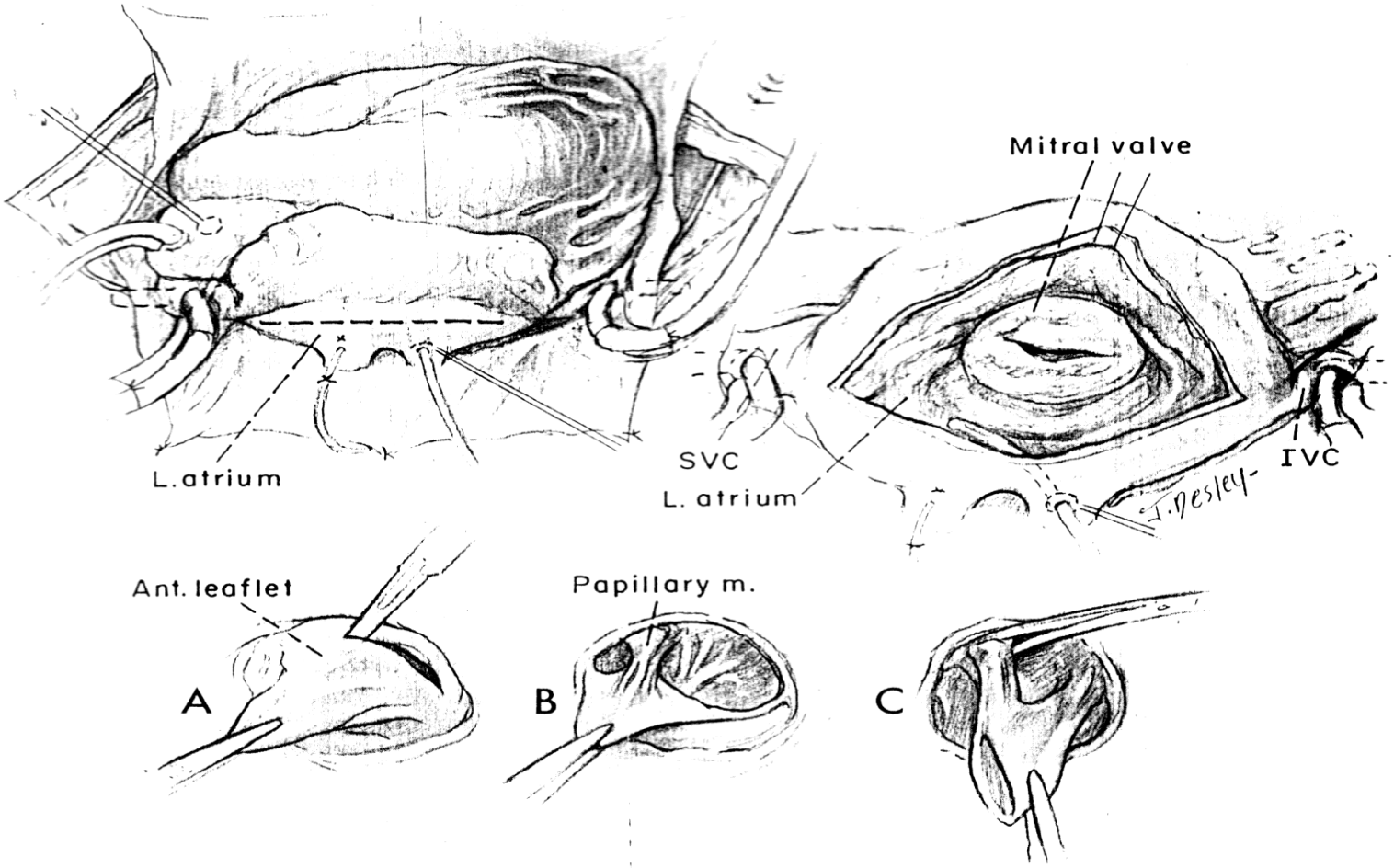

Figure 11-7 Mitral valve replacement, through a median sternotomy incision and opening into left atrium from the right side anterior to the right pulmonary veins (see legend of Fig. 11-4 for details). Two-venous cannulae are illustrated, but a single venous cannula can be used instead. A Cooley left atriotomy retractor is used (not shown).

(a) As described in the text, the incision in the mitral leaflet is begun with the knife anteriorly and about 2 mm from the anulus, where nearly always the leaflet is pliable and relatively free of disease.

(b) As the incision is carried leftward with the knife or scissors toward the anterolateral commissure, the underlying papillary muscle and fused chordae come into view and are cut.

(c) As the incision is carried across the anterolateral (illustrated here) and posteromedial commissural areas, care is taken to stay close to the anulus so that the valve is kept in one piece. This greatly facilitates completing the valve excision.

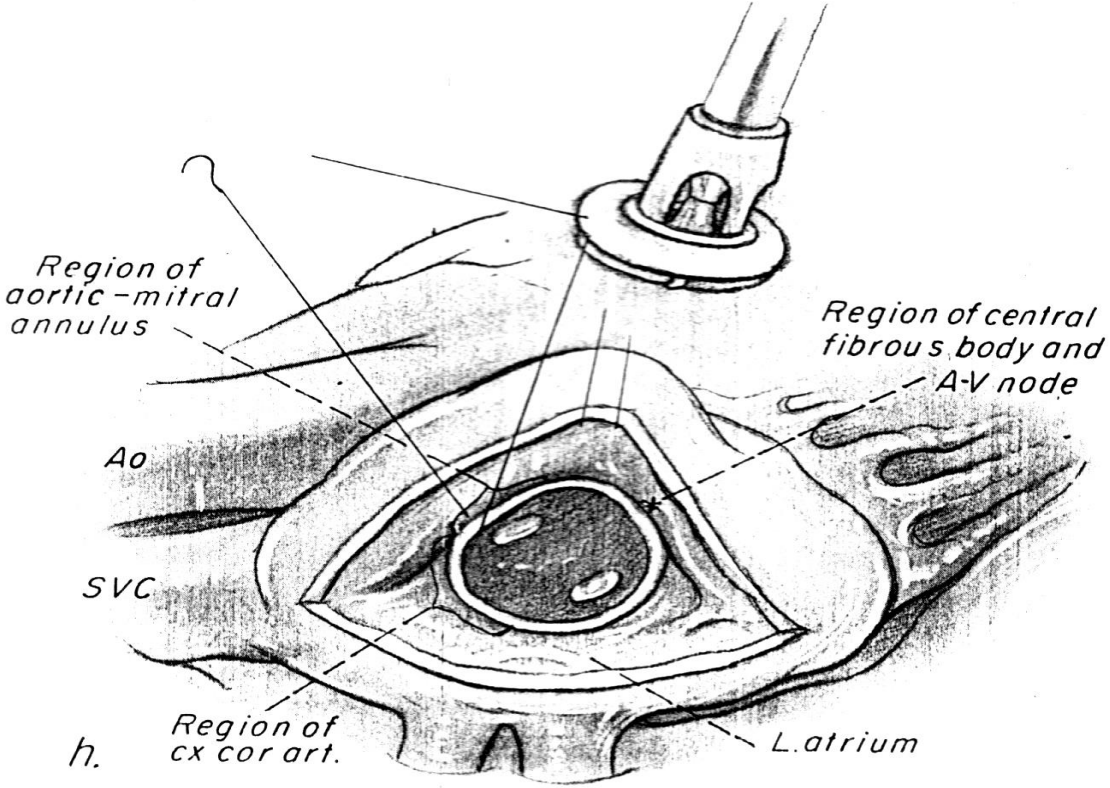

Figure 11-7 *(continued).*
(h) When an interrupted suture line technique is chosen (GLH), the first suture is placed at the anterolateral commissure in the 10-o'clock position. Each stitch (No. 2 silk) is passed first through the sewing ring of the valve (the valve remains outside the chest, being held by the assistant with the aid of a valve holder) and then through the anulus of the patient, with the needle held in reverse (backhand) fashion and passed from the left ventricular to the left atrial side. Each stitch passes just inside the anulus, and emerges through the adjacent portion of the atrial wall; care is taken that it not pass deeply enough to damage the underlying circumflex coronary artery. Suturing continues in a counterclockwise direction around exactly half the circumference of the host valve ring (to the 4-o'clock position), as well as around one-half the circumference of the sewing ring of the prosthesis. When the sutures are placed between the 6-o'clock and 4-o'clock positions, the needle is best passed forehand. The two ends of each of these sutures are clipped together with a hemostat just after the suture is placed; the handle of the hemostat is threaded onto a large "safety pin" outside the chest, to prevent the sutures from becoming crossed when they are tied later. With all the posterior sutures in position, the safety pin is closed. *(Figure continues.)*

MVR

True supra-annular valve–Supra-X™	Intra-annular valves	
23 mm valve	21 mm valve	21 mm valve
		
Supra- and extra-annular valve and stent = • ***Implant larger valve*** • ***Maximizes flow area***	Intra-annular valve with intra-annular stent = ***Reduced flow area***	Supra-annular sewing ring with intra-annular stent = ***Reduced flow area***

Mitral Regurgitation

Aetiology

Acute MR :

Ruptured chordae or papillary muscle due to acute myocardial infarction or trauma

Perforation of the mitral valve leaflet

Acute failure of a prosthetic valve

Mitral Regurgitation

Aetiology

Chronic MR :

- Mitral valve prolapse
- Rheumatic heart disease
- Coronary artery disease
- Connective-tissue disorder
- Prosthetic valves

MR

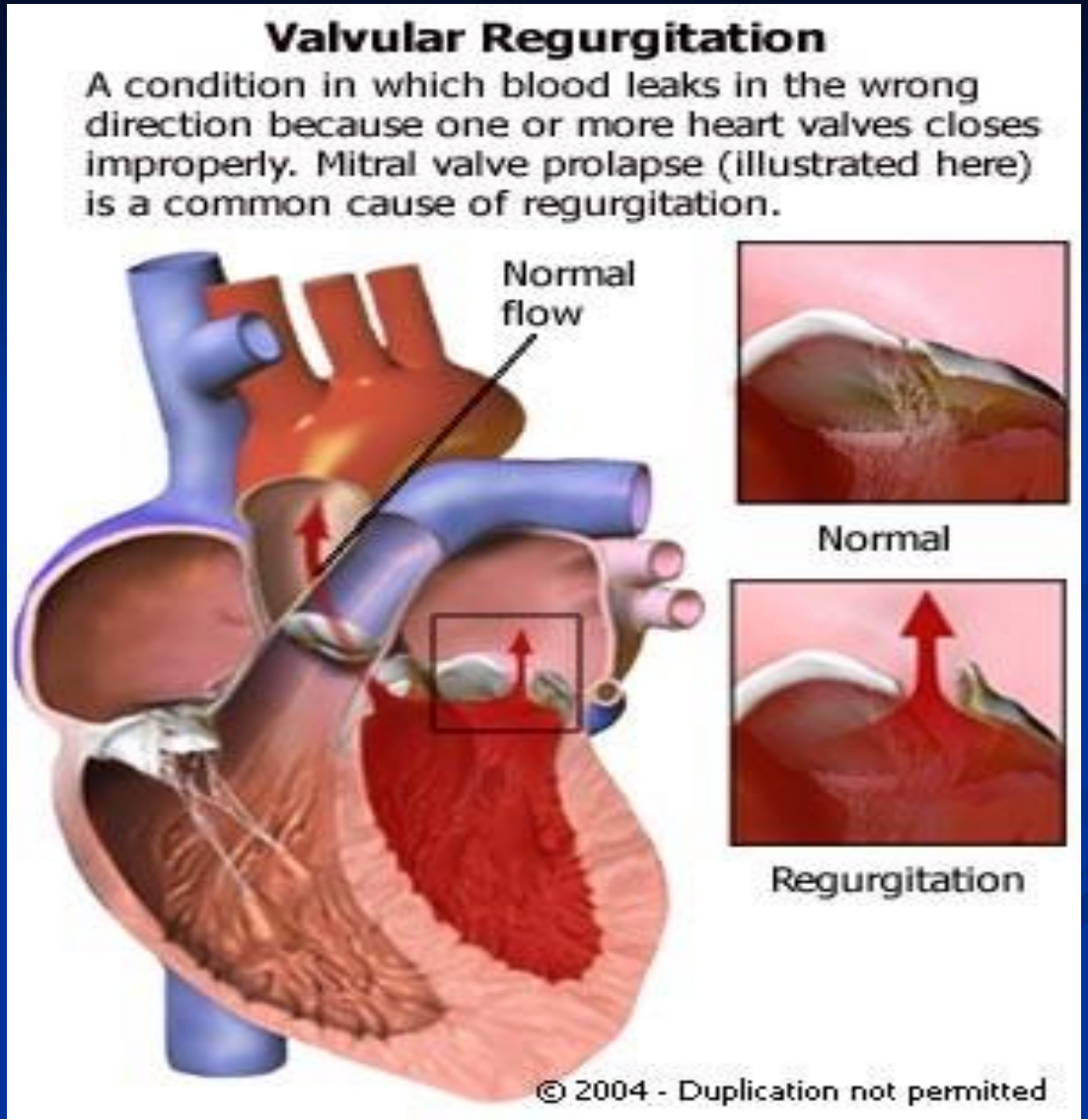
Valvular Regurgitation
A condition in which blood leaks in the wrong direction because one or more heart valves closes improperly. Mitral valve prolapse (illustrated here) is a common cause of regurgitation.
Normal flow
Normal
Regurgitation
© 2004 - Duplication not permitted

Pathophysiology

In chronic MVR, the distensibility of the LA and LV are increased over time.

This dilatation of the left atrium decreases left atrial pressures, thus increasing preload.

The left ventricle dilatates and, hypertrophied generates a larger stroke volume without a significant rise in wall stress.

CLINICAL

Symptoms

Acute MR

Sx of acute pulm edema and reduced CO

Chronic progressive MR

Exertional dyspnea, nocturnal dyspnea, palpitations(AF, atrial flutter, increased stroke volume)

Sx of pulm edema

Sx of diminished CO

Sx of right sided HF

Signs of MR

- AF/ Flutter
- Cardiomegaly- displaced hyperdynamic apex beats
- Apical systolic murmur, thrill
- Signs of raised pulm capillary pressure (crepitations, pulm edema, effusions)
- Signs of pulm HTN

Investigations for MR

ECG

LAH (if not in AF)

LVH

CXR

Enlarged LA, LV

Signs of pulm venous HTN

Signs of pulm edema if acute

ECHO

Dilated LA, LV

Dynamic LV(UNLESS AF PREDOMINATE)

Regurgitation detected on Doppler

CXR
MR

Marked cardiomegaly

Pulm venous HTN

LA appendage enlargement

TREATMENT of MR

Medical

Any patient with acute or chronic mitral valve regurgitation with hemodynamic compromise should be evaluated for acute myocardial infarction.

Afterload-reducing agents

If atrial fibrillation is encountered, digitalis therapy is considered

Prophylactic antibiotics are administered prior to any interventional treatment

TREATMENT OF MR
SURGICAL

Indications for surgical Intervention

Acute MR with congestive heart failure or cardiogenic shock

Acute endocarditis

Class III/IV symptoms (ie, patient symptomatic while at rest or with minimal activity)

Systemic emboli

MITRAL RECONSTRUCTIVE SURGERY

REPAIR TECHNIQUES

LEVEL	MANEUVER
ANNULUS	REDUCTION
LEAFLETS	RESECTION ENLARGEMENT
CHORDS	RESECTION SHORTENING TRANSPOSITION REPLACEMENT
COMMISSURES	SPLITTING RESECTION
PAPPILARY MUSCLES	SPLITTING SHORTENING REPOSITIONING



Figure 4. Correction of a prolapsing anterior leaflet with placement of polytetrafluoroethylene (PTFE) neochordae. (Reprinted with permission from Carpentier A, Adams DH, Filsoufi F. *Carpentier's Reconstructive Valve Surgery. From Valve Analysis to Valve Reconstruction. 2010 Saunders Elsevier.*).

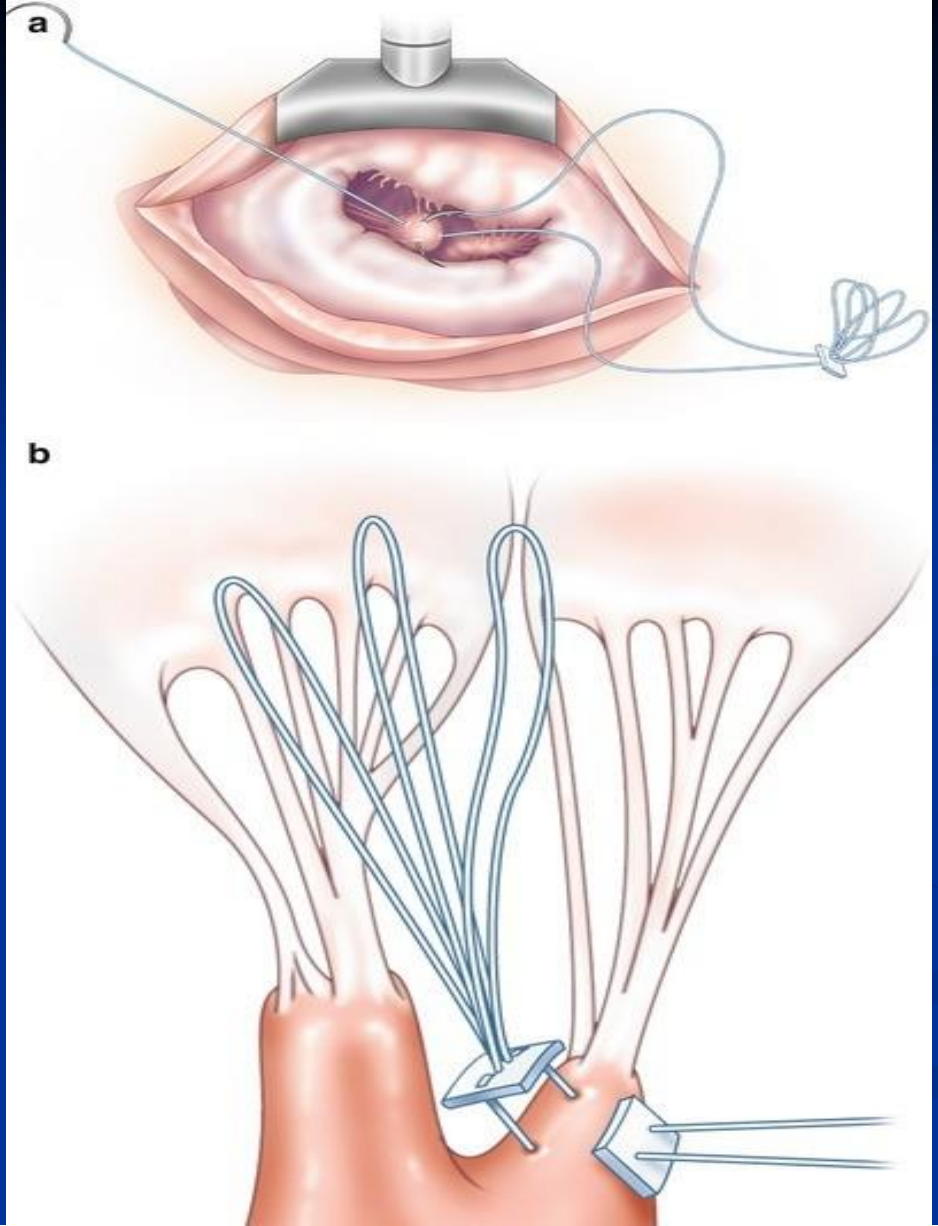
a
b

Repaired mitral valve