Diverticular disease

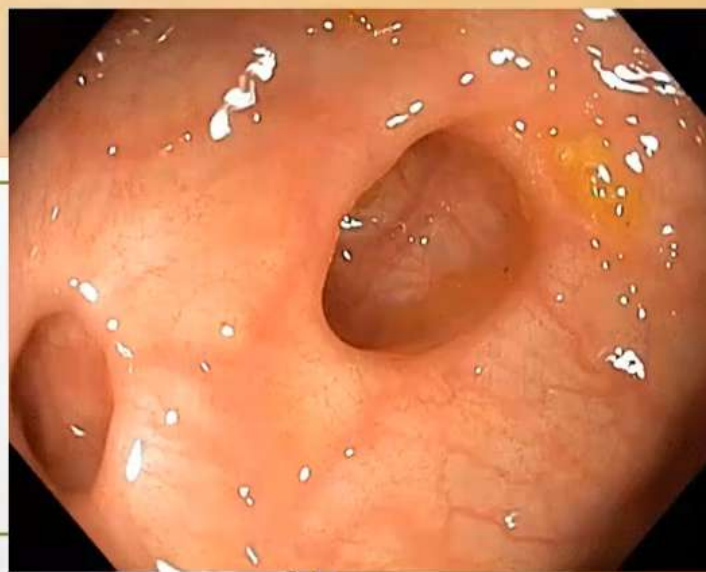

Short notes

* This is a colonic pathology and not a rectal one because tinea coli cover the rectum

false diverticulum (2 layers only → mucosa + submucosa)

- Common anatomical disorder Characterized by acquired , sac-like mucosal protrusions (diverticula) through the muscle wall.
- Traditionally thought to be related :
  - Western world
  - Mature age group
  - Meat rich Fiber poor diet
- Parks , based on 300 dissections :
  - In the Lateral intertaenial areas
  - Mainly in the sigmoid
  - A blood vessel pierce the wall at the neck of the diverticulum.

→ nearby mesentry

→ especially the colon that usually covered by peritoneum but sometimes we can see diverticula in the retroperitoneal part of the colon for example: cecum or sigmoid

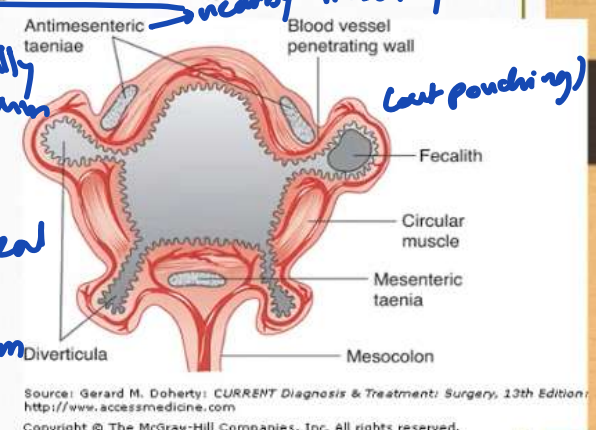

Race and geography

- Geographic disparities in the incidence imply that it is predominantly a disease of industrialised societies associated with an ageing population and Western diet
- The incidence has increased in North America by up to 50% in the past two decades, and more so in younger people. IT is extremely rare in Asia and Africa compared to Europe and the USA

  *Less In East
- Immigration to Western countries results in an increase in the incidence of diverticular disease

Age and gender

- Males are more likely to develop diverticulitis at a younger age whereas there is a female predominance in older patients

- younger age is a risk factor for recurrent disease rather than an indication for early intervention in the acute setting, as these patients are just as likely to settle with conservative management

Diet

→ No evidence that giving the patient a high fiber diet will cure the problem, it only helps in constipation

- Low-fibre diet has an epidemiological association with the development of diverticular disease. However, recommending fibre as a treatment for diverticulosis is largely based on outdated, poorly controlled studies.

Etiology and pathogenesis

- luminal trauma, elevated colonic pressures, altered bacterial flora. cholinergic smooth muscle excitation and neurohumoral signalling (serotonin, nitric oxide, VIP)
- Lifestyle (Obesity)
- Smoking
- NSAID

Diverticular disease (Diverticulosis) can cause:

1. Diverticulitis → inflammation of the diverticula (outpouching) + microperforation of it
2. Peritonitis
3. Abscess

(depending on the degree)

Intestinal obstruction → because of fibrosis following inflammation and it mimics cancer

Haemorrhage → rectal bleeding

Fistula formation (ex. colovesical fistula)

→ sticking to adjacent structures

Diverticulitis

caused by microperforation of the diverticulum

- Acute inflammatory condition characterised by left iliac fossa or suprapubic pain, malaise and fever (inflammatory response) (pain)
  + tachycardia and hypotension
- Annual incidence of 1/1000
- Male predominance aged under 45 but female predominance in those older
- Increasing incidence in the under-45 age group

Hinchey classification

- Grade I Mesenteric or pericolic abscess
- Grade II Pelvic abscess
- Grade III Purulent peritonitis (with pus only)
- Grade IV Faecal peritonitis (full rupture of colon)

* Patient with abdominal pain → left iliac fossa or suprapubic + tenderness at the site of the pain + fever + leukocytosis

Diagnosis and imaging

→ it could be more: peritonitis, guarding or even shock

- CT in rapid, multiple slice scanners capable of variable plane reconstruction became the gold standard in determining the diagnosis and staging of diverticulitis

for diverticular diseases other than diverticulitis

- Colonic imaging (either colonoscopy or CT colonography) is still performed routinely following an episode of diverticulitis to rule out neoplasia

- Timing and indication of Colonoscopy is questionable .

chronic patient or no signs of diverticulitis

No colonscopy for a patient suspected to have acute diverticulitis

Barium Enema

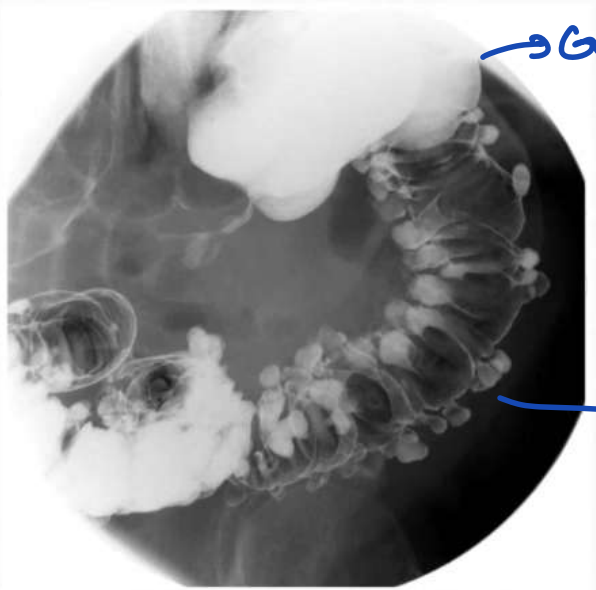

→ Gas and Barium passed into the abdomen

→ used to be done, not used anymore

→ outpouching

Hinchey I diverticulitis (No inflammation at wall, gas or peritonitis)

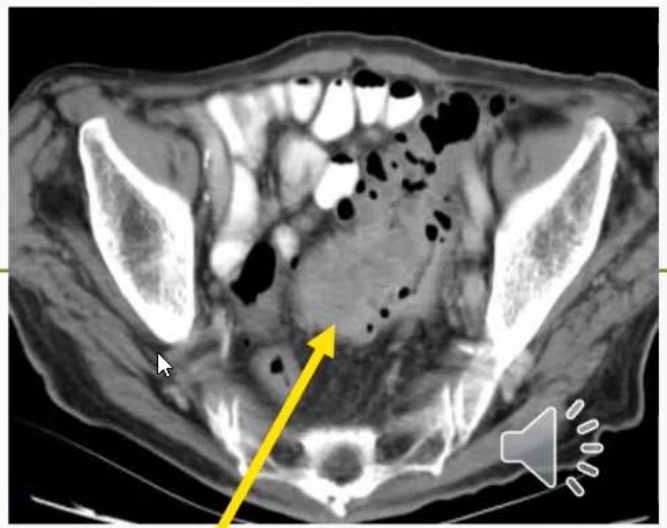

(thickened wall)
Inflammation at sigmoid colon fat around colon is whitish and thickened

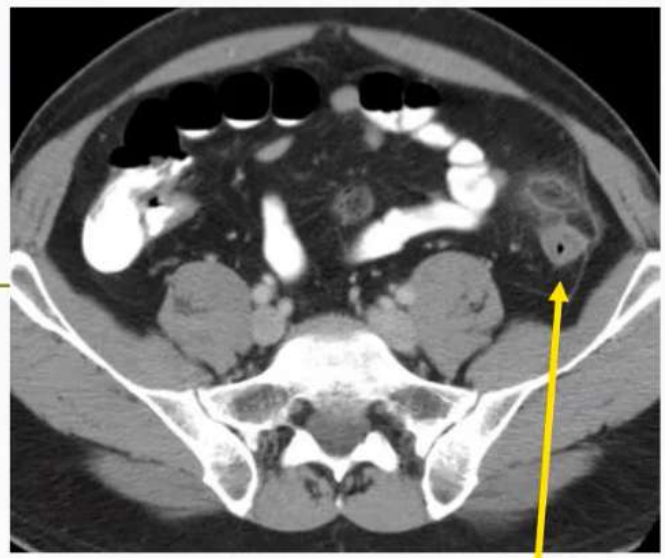

fat pouching of sigmoid with thickened wall

Treatment

- Asymptomatic patients with diverticulosis do not require treatment (incidental finding)
  - Avoiding nuts and seeds : No scientific basis or fact
  - higher fibre intake does not change the course of symptomatic diverticular problems

- There is currently no consensus on the most appropriate antibiotic regimen or route (oral/intravenous) for diverticulitis but , broad-spectrum agents covering Gram-negative and anaerobic organisms are advised

for Healthy

- Two randomised trials have found that antibiotic treatment for acute uncomplicated diverticulitis neither accelerates recovery nor prevents complications or recurrence. As such, observational treatment without antibiotics can be considered appropriate in non-septic patients

	Uncomplicated diverticullitis	Chronic complicated disease	** Acute complicated diverticullitis
Clinical presentation	LIF pain Fever Altered bowel habit	Constipation Fistula Bleeding Recurrent (smouldering disease) High-risk patients	– Fever – Abdominal mass – Ileus/obstruction – Severe rectal bleeding – Generalised peritonitis
Imaging and/or investigations	Ultrasound CT abdomen Colonoscopy	CT Colonoscopy Barium contrast study	CT (abscess, obstruction, peroration) CT angiogram (bleeding) Colonoscopy (bleeding)
Treatment	Conservative Antibiotics High fibre Mesalazine Rifaxamin	Elective intervention Sigmoid resection + primary anastomosis (open/laparoscopic)	Abscess → ① Percutaneous drainage ② Sigmoid resection (Grade 2) Bleeding → Endoscopic intervention (Before endoscopic or endovascular procedure do a CT angiogram to localize the site of bleeding) Endovascular coiling Laparoscopy + lavage (Hinchey III) Peritonitis → Resection/primary anastomiosis or Hartmann's procedure

large amount of fresh blood per rectum

Hinchey Grade 3 or 4

Hartmann's operation

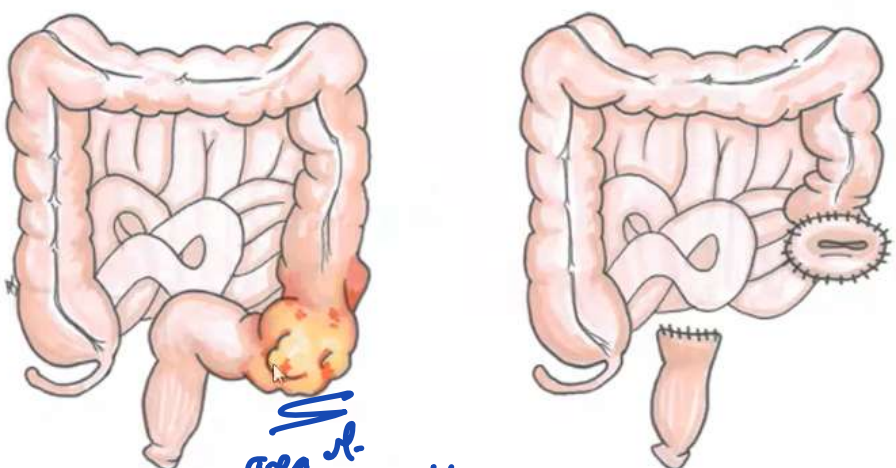

area of inflammation at the site of sigmoid colon

then anastomosis

Elective resection

- Recurrent Diverticulitis ??? → Recurrent hospitalization with antibiotics → then resection is required
  - The natural history of diverticulitis is such that one in six patients undergo surgery at presentation while approximately 20–25% re-present, with a similar proportion requiring surgery, such that less than 5% have more than two episodes
  - Decision of surgery is based on an individualized basis

No. of episodes before surgery → not determined depend on its impact on their life, complications ...

- Diverticular fistula → surgical resection is required, diverticular stricture and disease refractory to conservative management.

Diverticular haemorrhage

- 3-5 %
- The majority of diverticular haemorrhages cease spontaneously
- My need angiography , emergency resection.
- Elderly patient with high mortality

→ large amount of blood loss per rectum → sometimes he's unstable

→ Treatment: resuscitation then angiography → blood continued → Surgery

* In most cases bleeding stopped after stabilizing the patient

- Drops of blood presenting to the clinic → this is not hemorrhagic diverticulitis

Thank You