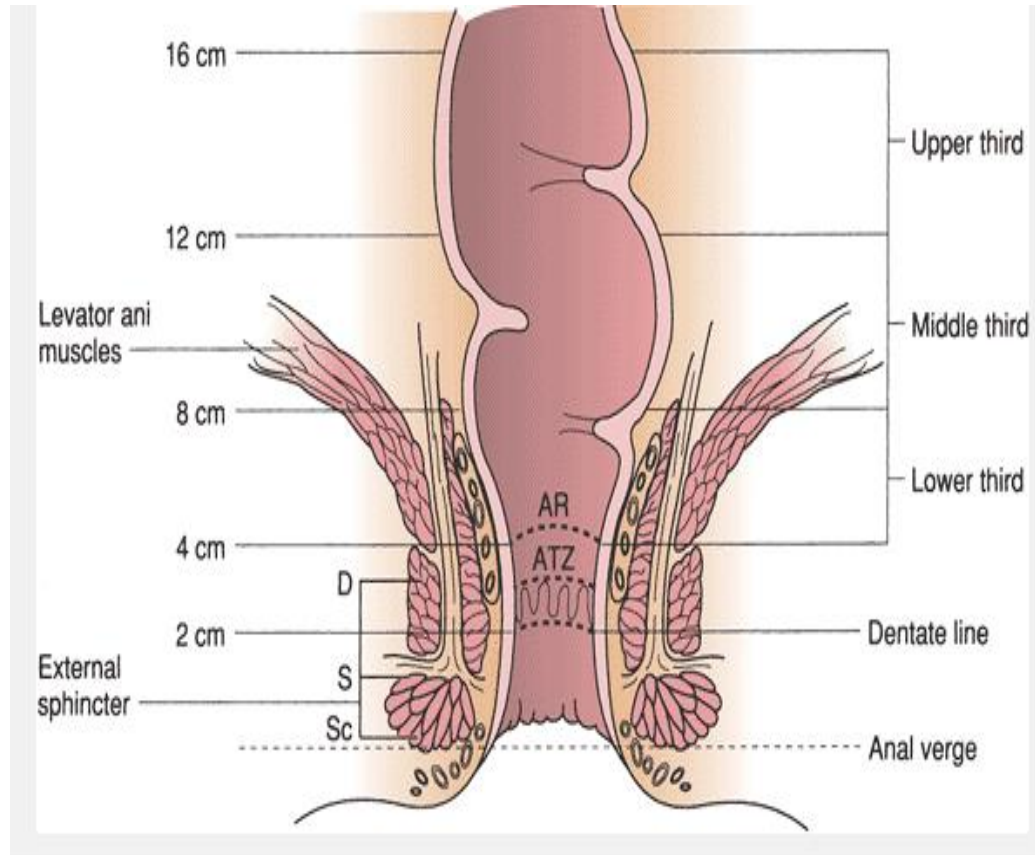


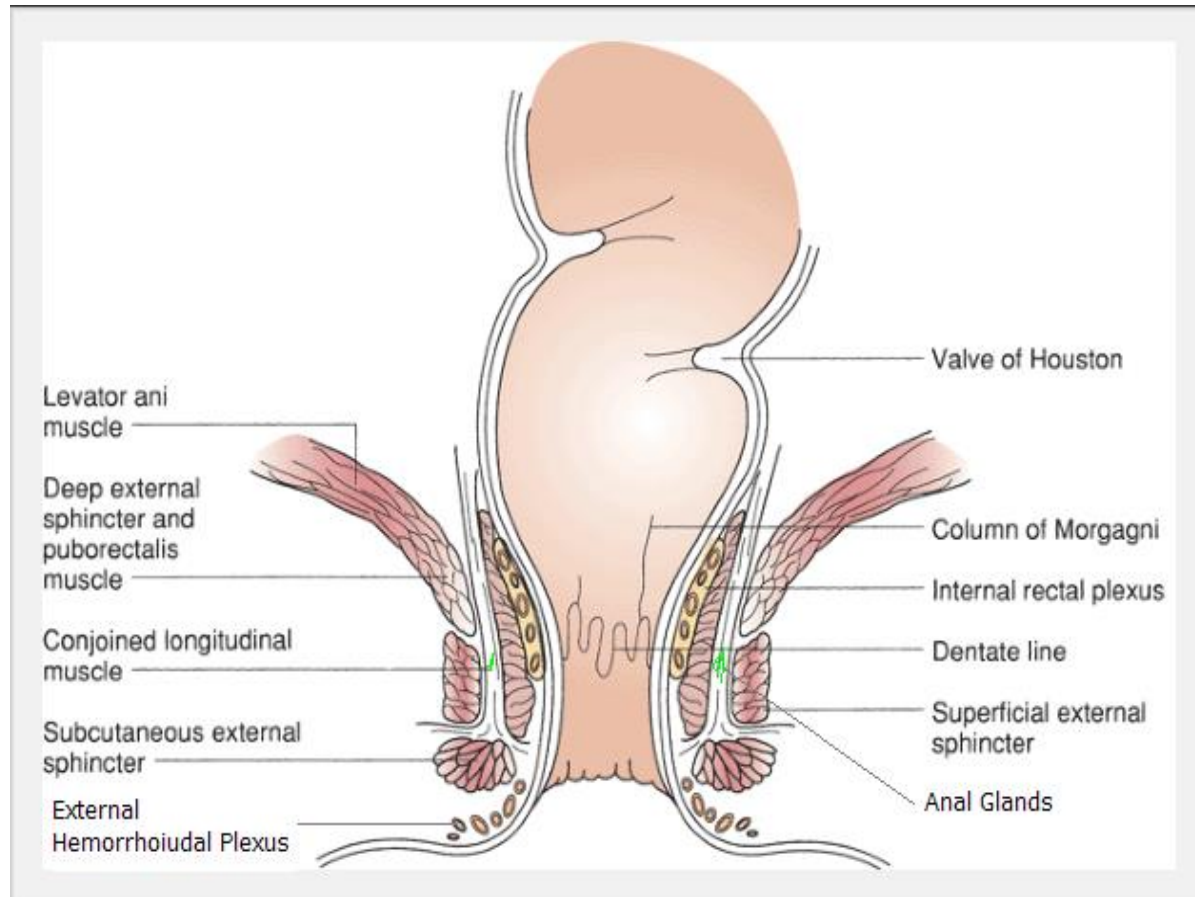
HEMORRHOIDS



Anatomy of the anal canal



Anatomy



Anatomy

- Hemorrhoids are not varicose veins.
- everyone has anal cushions. The anal cushions are composed of blood vessels (erectile tissue), smooth muscle (Treitz's muscle), and elastic connective tissue in the submucosa
- They are located in the upper anal canal, from the dentate line to the anorectal ring

Anatomy

- Three cushions lie in the following constant sites:
- left lateral (3), right anterolateral (1 1), and right posterolateral (7).
- Smaller discrete secondary cushions may be present between the main cushions.
- The configuration is remarkably constant and apparently bears no relationship to the terminal branching of the superior rectal artery

PREVALENCE

- prevalence rate of 4.4%.
- peak between age 45 and 65 years
- Hemorrhoidectomies are performed 1.3 times more commonly in males than in females

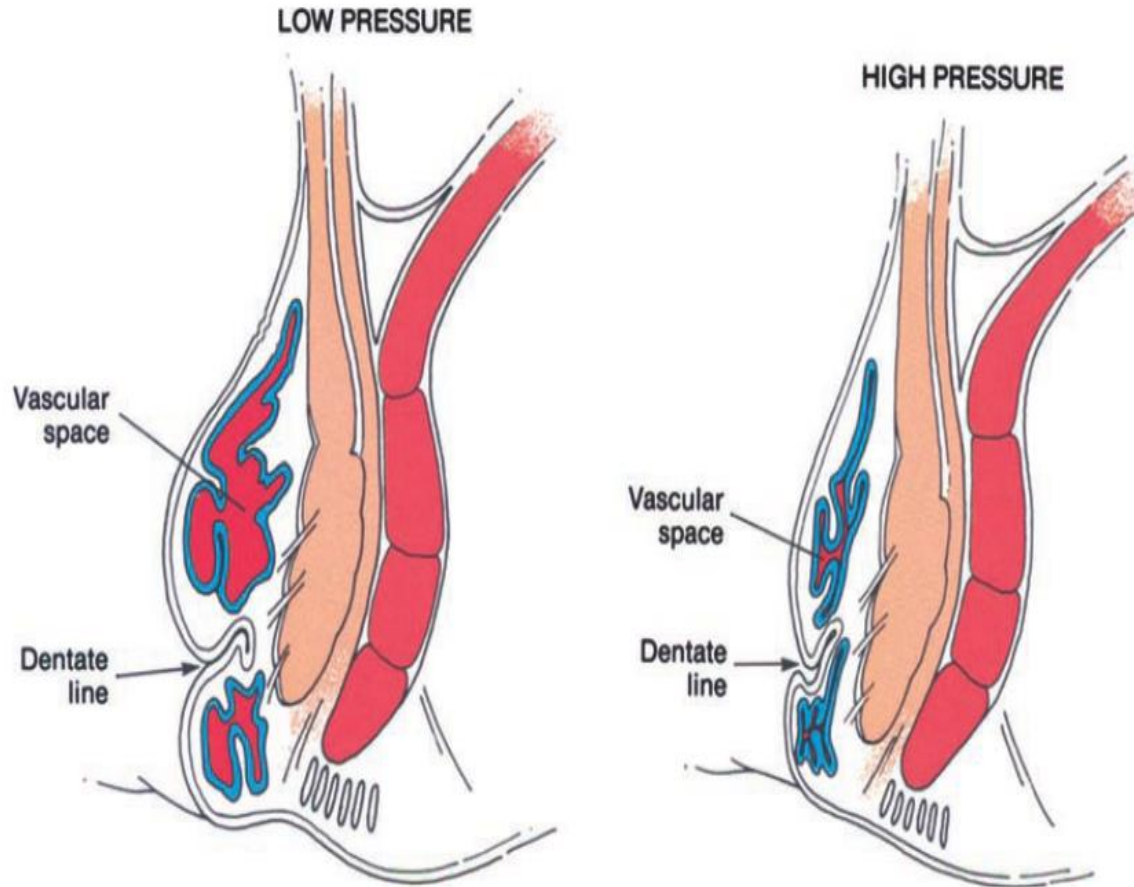
ETIOLOGY AND PATHOGENESIS

- hemorrhoids are no more common in patients with portal hypertension than in the population at large
- Thomson concluded that a sliding downward of the anal cushions is the correct etiologic theory (**shearing**)
- Hemorrhoids result from disruption of the anchoring and flattening action of the musculus submucosae ani (**Treitz's muscle**) and its richly intermingled elastic fibers. Hypertrophy and congestion of the vascular tissue are secondary
- higher anal resting pressures in patients with hemorrhoids

ETIOLOGY AND PATHOGENESIS

- Constipation
- Prolonged straining
- Diarrhea
- Pregnancy
- Heredity
- Erect posture
- Absence of valves within the hemorrhoidal sinusoids,
- Increased intra-abdominal pressure
- Aging (deterioration of anal supporting tissues)
- Internal sphincter abnormalities

FUNCTION OF ANAL CUSHIONS



FUNCTION OF ANAL CUSHIONS

- compliant and conformable plug.
Hemorrhoidectomy impairs continence to infused saline
- account for approximately 15%–20% of the anal resting pressure
- sensory information that enables individuals to discriminate between liquid, solid, and gas (anal sampling)

NOMENCLATURE AND CLASSIFICATION

- External skin tags are discrete folds of skin arising from the anal verge.
 - ▣ independent of any hemorrhoidal problem.
- External hemorrhoids comprise the dilated vascular plexus that is located below the dentate line and covered by squamous epithelium.

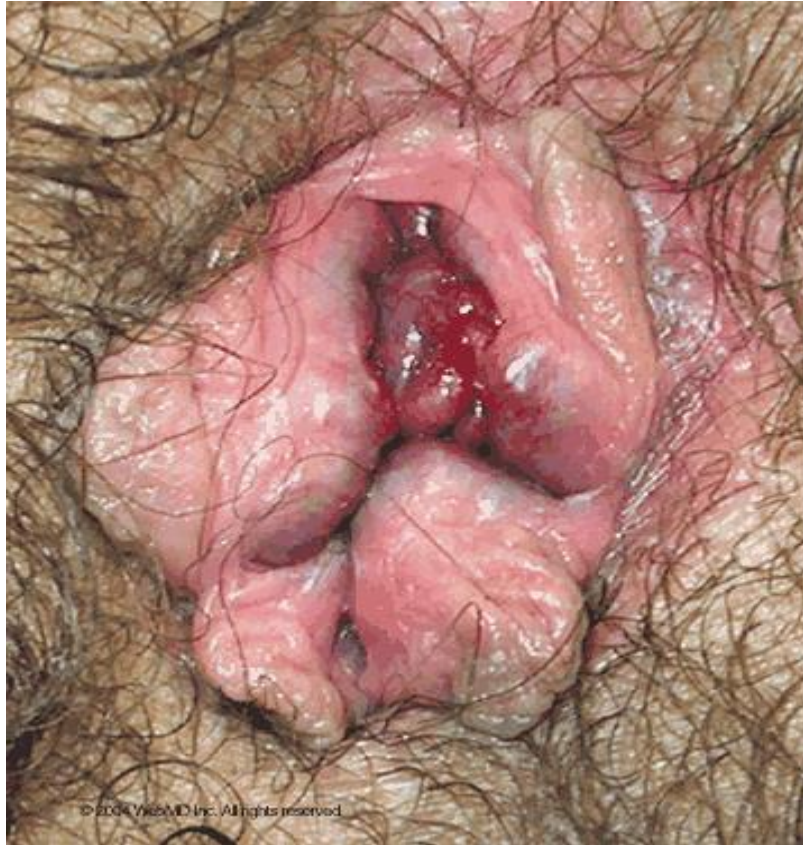NOMENCLATURE AND CLASSIFICATION

Internal hemorrhoids are the symptomatic, exaggerated, submucosal vascular tissue located above the dentate line and covered by transitional and columnar epithelium.

NOMENCLATURE AND CLASSIFICATION

- **Grade 1** internal hemorrhoids are those that bulge into the lumen of the anal canal and may produce painless bleeding.
- **Grade 2** internal hemorrhoids are those that protrude at the time of a bowel movement but reduce spontaneously.
- **Grade 3** internal hemorrhoids are those that protrude spontaneously or at the time of a bowel movement and require manual replacement.
- **Grade 4** internal hemorrhoids are those that are permanently prolapsed and irreducible despite attempts at manual replacement. They may or may not be complicated

Classic sites



© 2004 WebMD Inc. All rights reserved.

DIFFERENTIAL DIAGNOSIS

- Rectal mucosal prolapse
- Hypertrophied anal papillae
- Rectal polyps
- melanoma
- carcinoma
- rectal prolapse
- Fissure

Symptoms: **Bleeding**

- Bleeding is bright red and painless and occurs at the end of defecation.
- The patient complains of blood dripping or squirting into the toilet bowl.
- Is rarely massive.
- The bleeding also may be occult, resulting in anemia, which is rare, or guaiac-positive stools

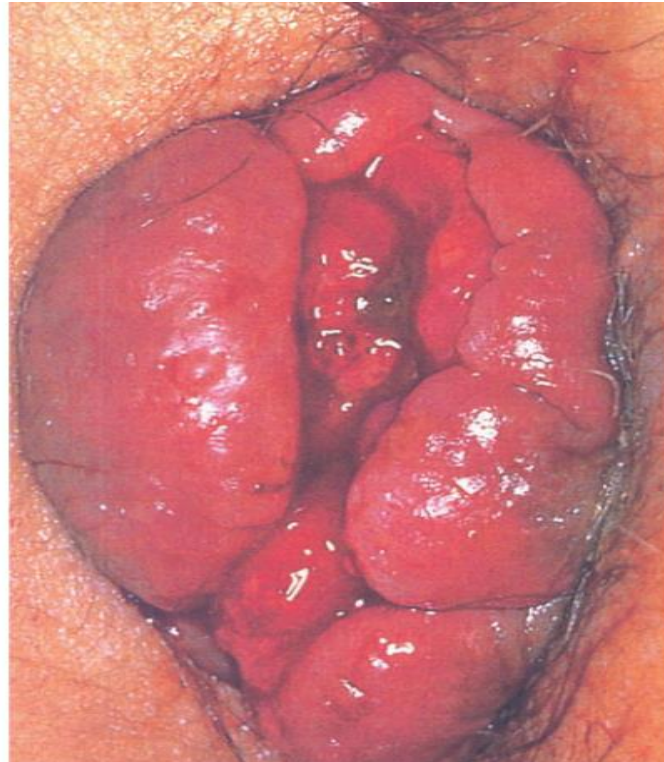
Other symptoms

- Prolapse
- Pruritus
- Pain when complicated
- Mucous and fecal leakage
- Excoriation of the perianal skin

EXAMINATION

- Inspection; Straining
- Digital examination; **SOFT IMPALPABLE**
- Anoscopy
- Proctoscopy or flexible sigmoidoscopy
- Colonoscopy

Complicated Grade 4 hemorrhoids



Treatment in general

- Medical; 1st and 2nd degree
- Minor procedures; failed medical Rx 1st and 2nd degree, some 3rd degree
- Surgery; 3rd and 4th degree

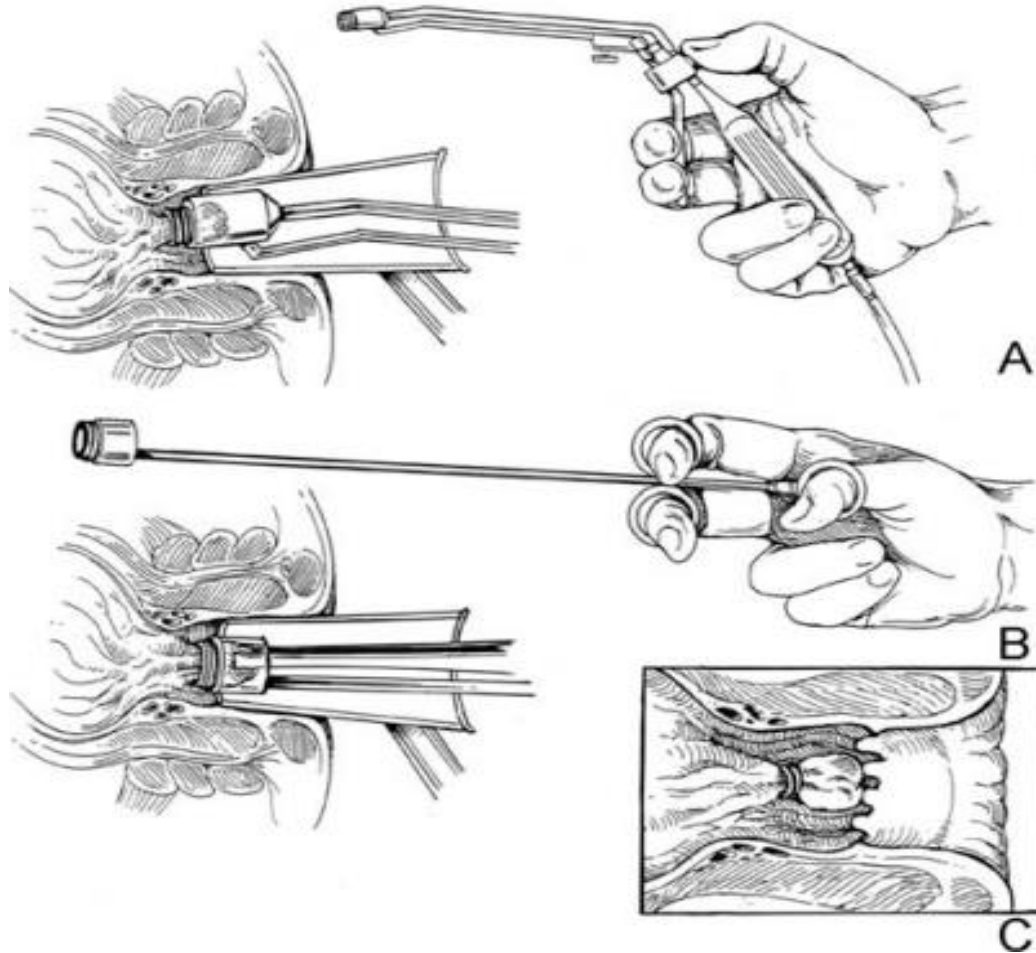
Medical

- Warm Sitz baths
- Diet and bulk-forming agents
- Ointments, creams, gels, suppositories, foams, and pads
- Vasoconstrictors, Protectants, Astringents, Antiseptics, Keratolytics, Analgesics, Corticosteroids.

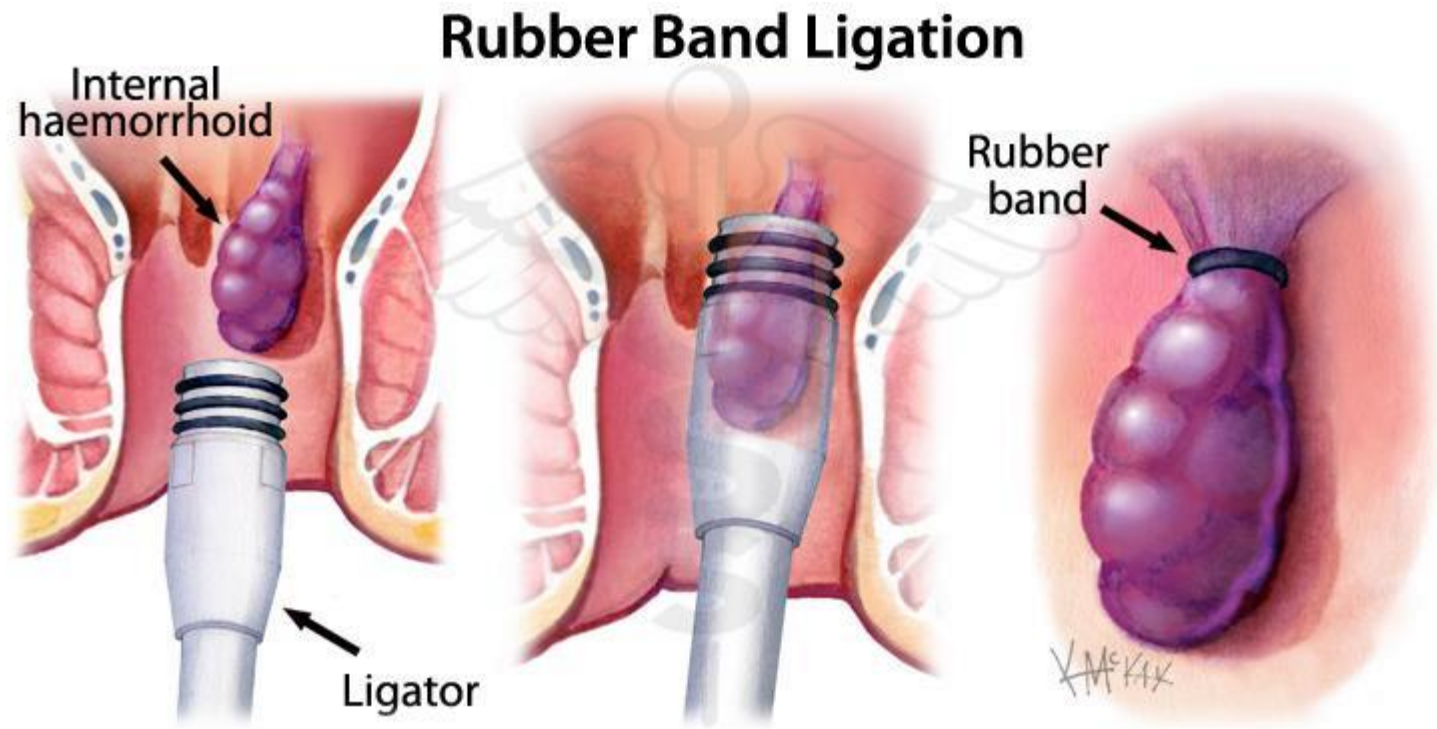
Other procedures

- Sclerotherapy
- Cryotherapy???
- Infrared coagulation
- Doppler guided hemorrhoidal artery ligation
- Anal Stretch; ??? obsolete

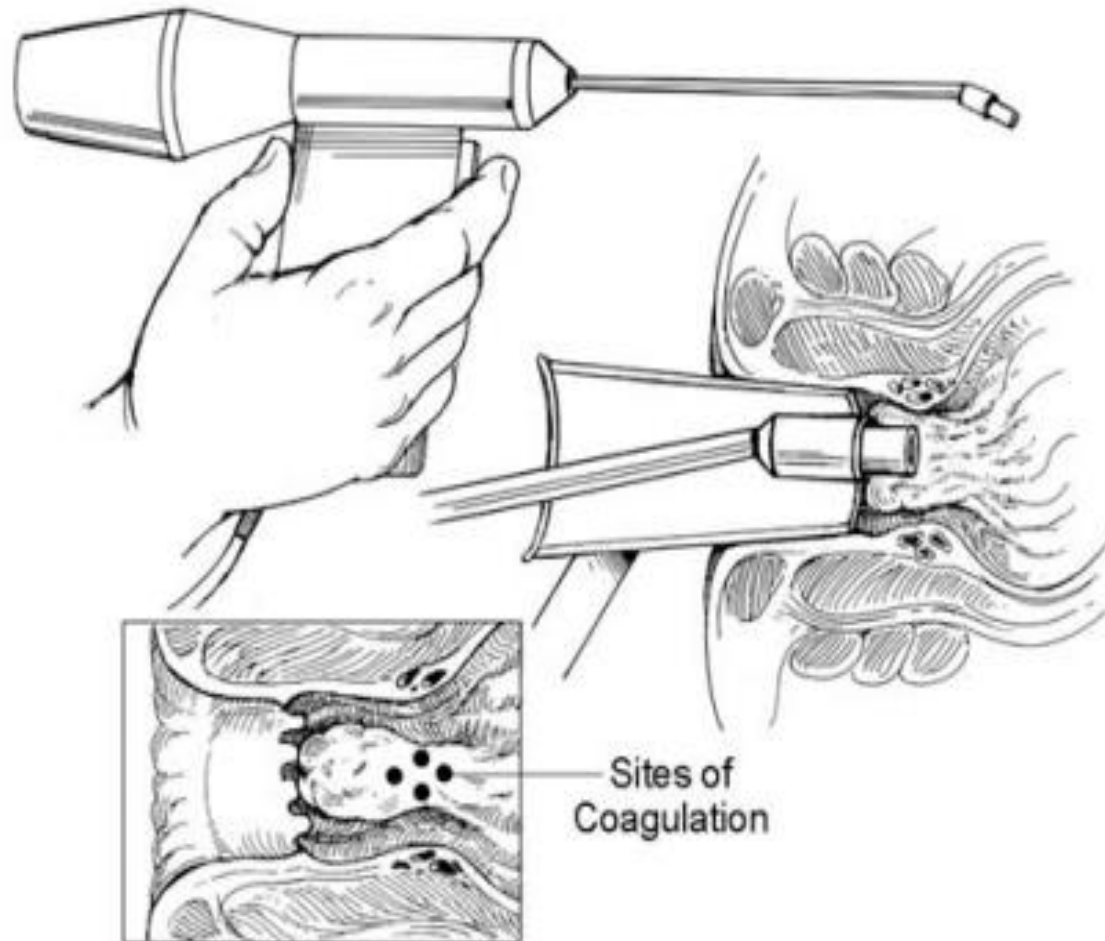
Rubber Band Ligation



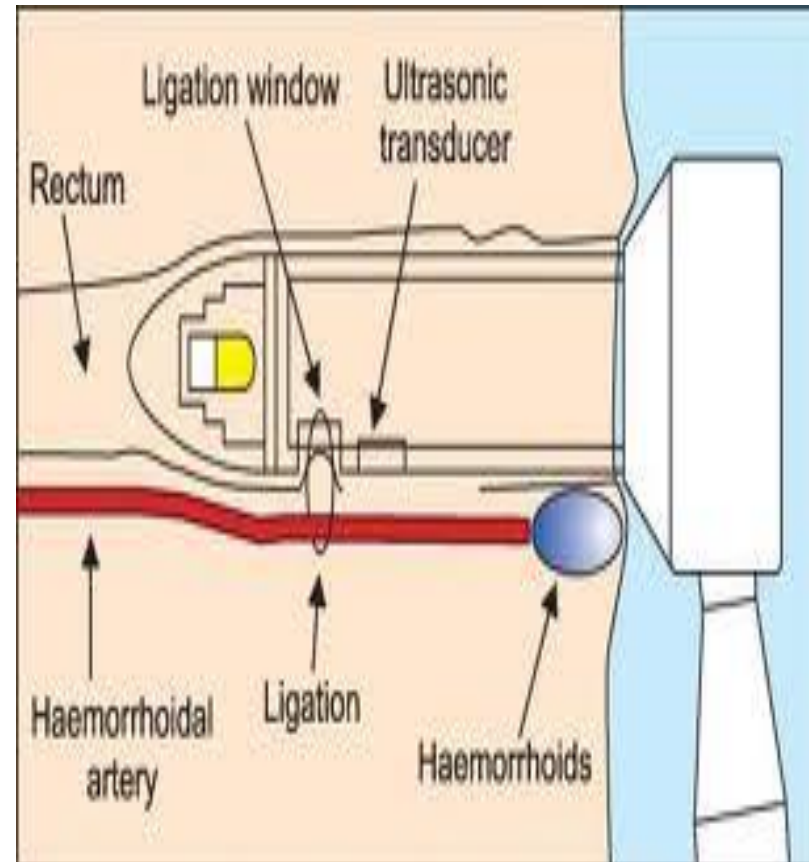
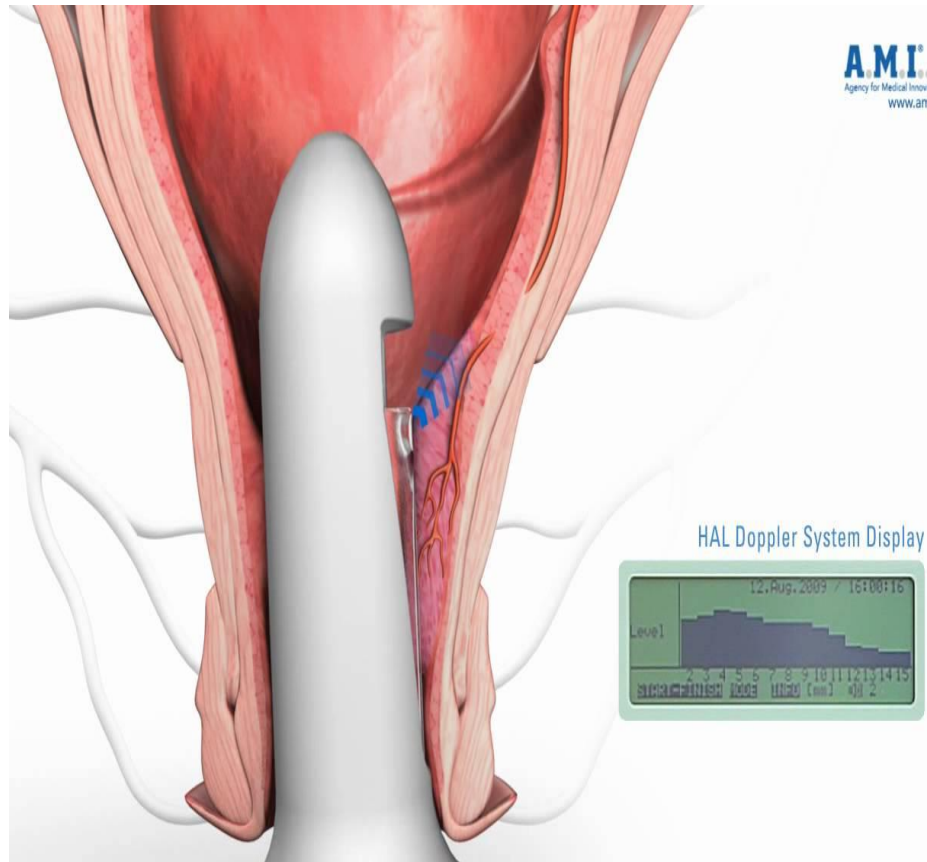
Rubber Band Ligation



Infrared Photocoagulation



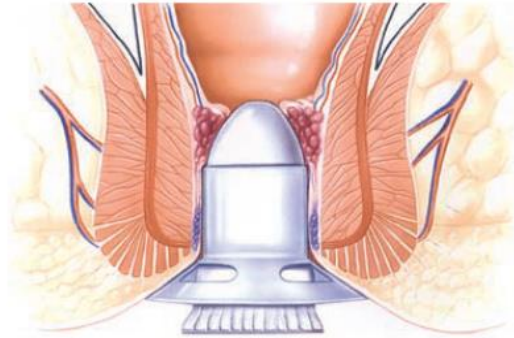
Doppler guided hemorrhoidal artery ligation



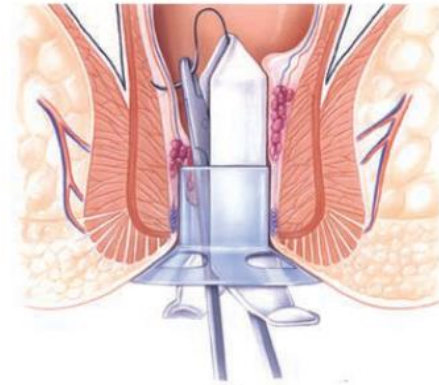
Hemorrhoidectomy

- Closed hemorrhoidectomy
- Open hemorrhoidectomy = Excision and Ligation
- Laser Hemorrhoidectomy
- Stapled hemorrhoidectomy

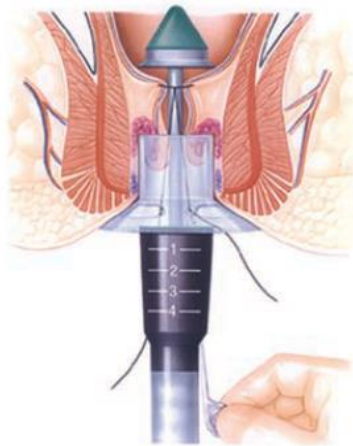
Stapled Hemorrhoidectomy



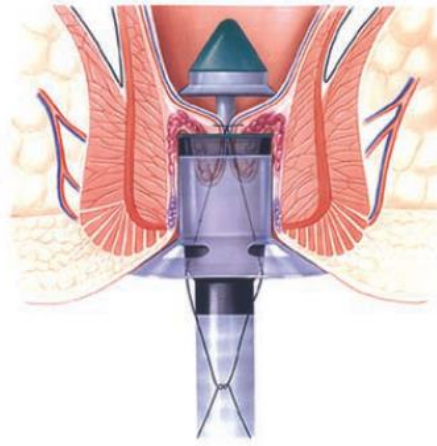
A



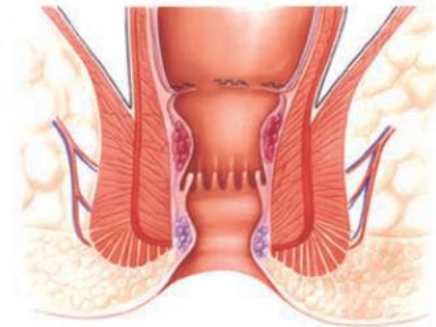
B



C



D

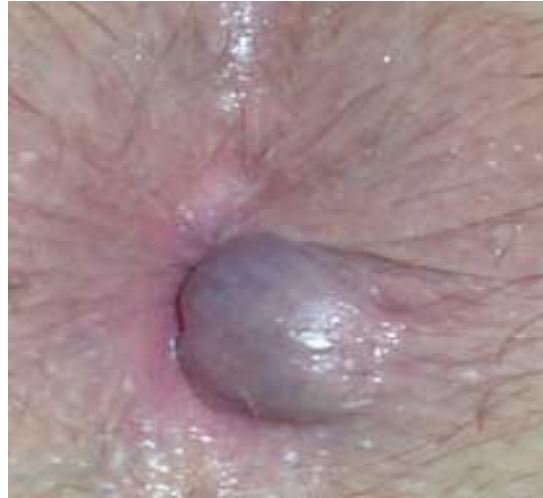

E

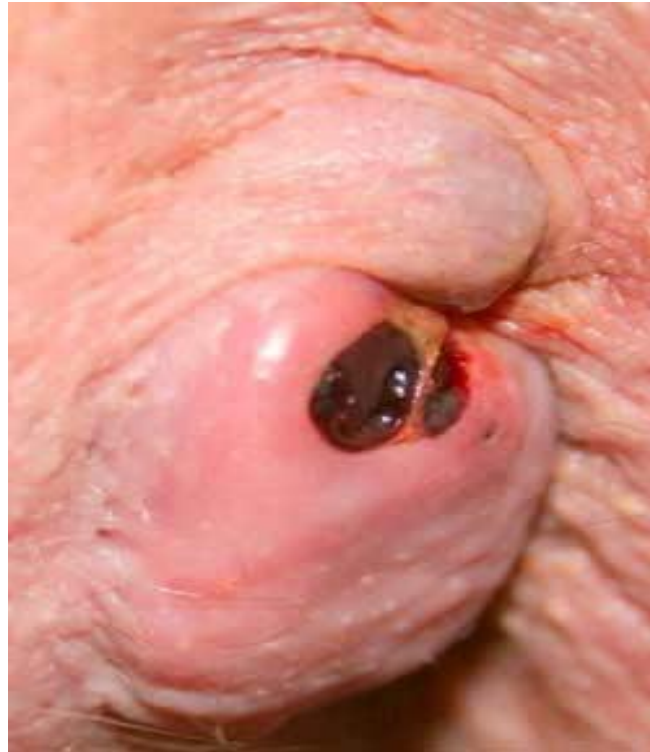THROMBOSED EXTERNAL HEMORRHOIDS

- an abrupt onset of an anal mass and pain that usually peaks within 48 hours and subsides in 5 days.
- The pain becomes minimal after the fourth day.
- If left alone, the thrombus will shrink and dissolve in a few weeks.
- Occasionally, the skin overlying the thrombus becomes necrotic, causing bleeding and discharge or infection, which may cause further necrosis and more pain.
- A large thrombus can result in a skin tag

THROMBOSED EXTERNAL HEMORRHOIDS



THROMBOSED EXTERNAL HEMORRHOIDS



THROMBOSED EXTERNAL HEMORRHOIDS

management

- Early may be incised
- Late
 - ▣ local anesthetics
 - ▣ Warm Sitz baths

Anal Fissure

- Occur in young and middle aged adults but also may occur in infants, children, and the elderly.
- Fissures are equally common in both sexes.
- Anterior fissures are more common in women than in men
- Posterior fissures are more common than posterior in both sexes.

Anal Fissure

- Acute fissure; a tear
- Chronic fissure; sentinel pile, hypertrophied anal papilla, fibrous induration
- complications: Abscess and fistula

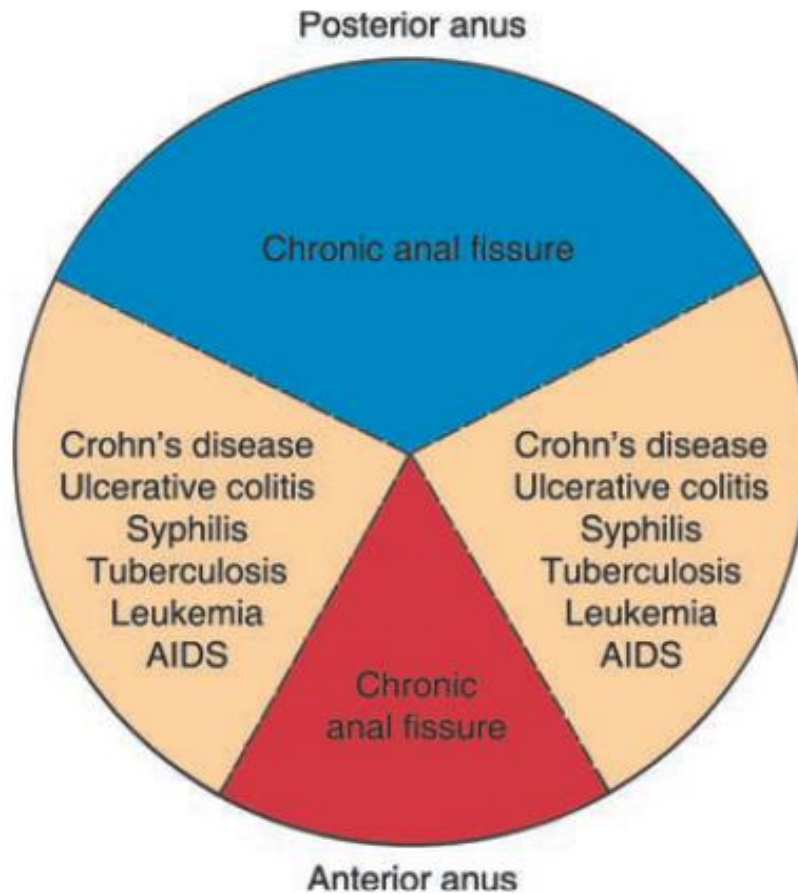
PREDISPOSING FACTORS

- Primary; hypertonic Internal anal sphincter (IAS)
- Secondary fissures (low pressure fissure)
 - Anatomic anal abnormality (e.g. postpartum)
 - Inflammatory bowel disease
 - HIV
 - Other chronic infections
 - leukemia

symptoms

- **PAIN** in the anus during and after defecation
- Bleeding; streaks
- Constipation; cause and consequence
- large sentinel pile
- Discharge

site

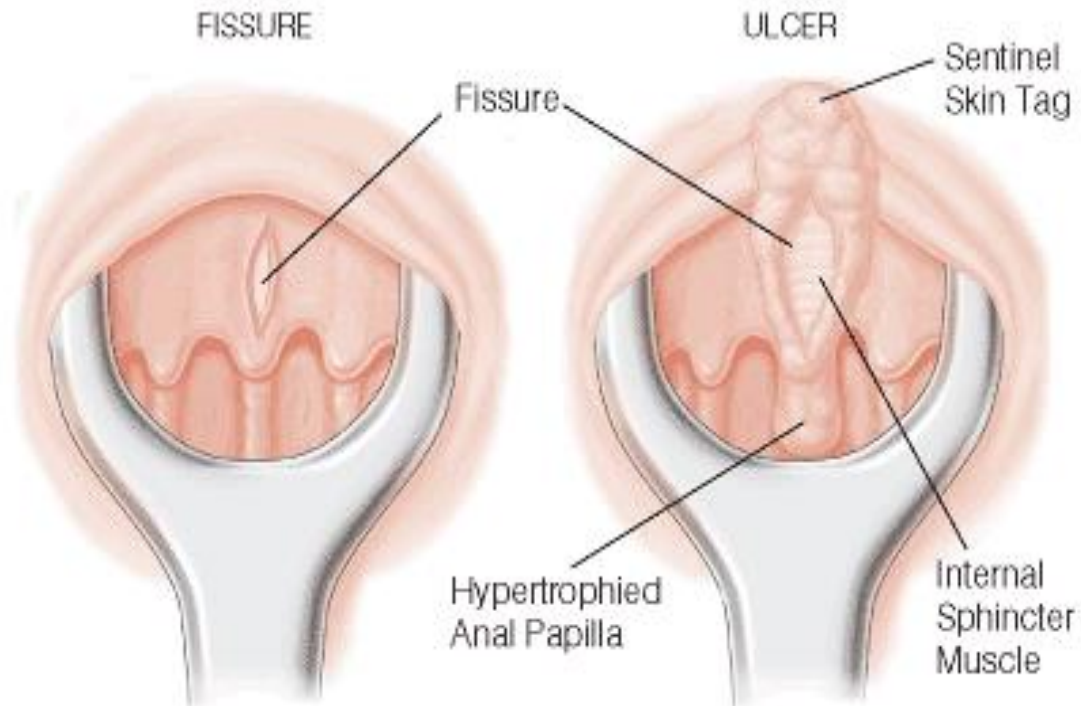


When is it chronic

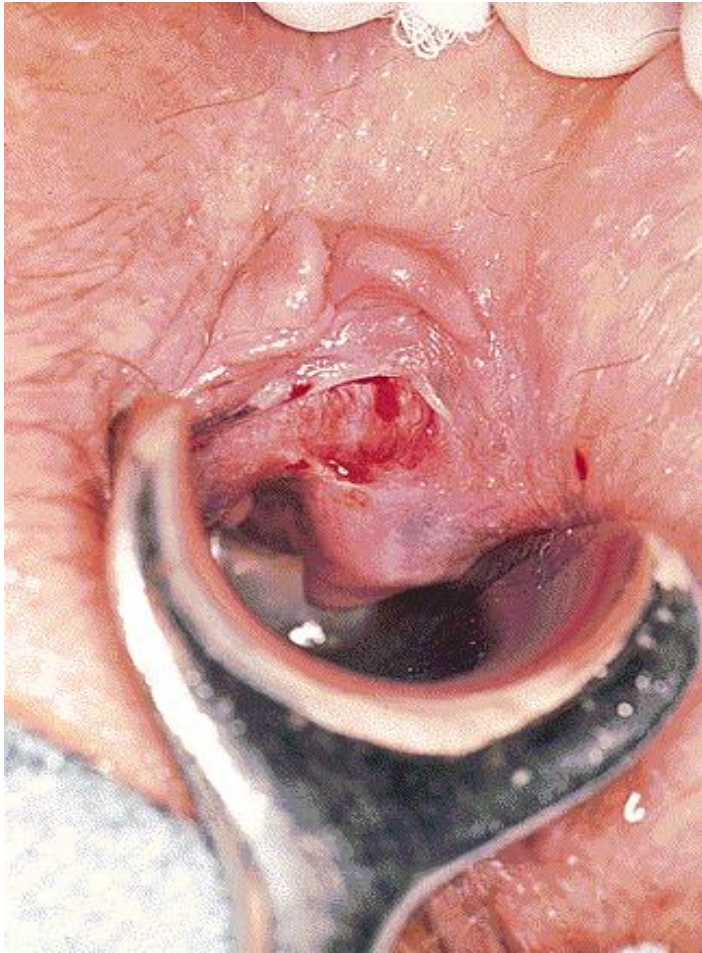- History more than 1 month
- Presence of
 1. Sentinel pile
 2. Hypertrophied anal papilla
 3. Fibrosis
 4. Submucous fistula

anal fissure

Acute vs. chronic



Chronic anal fissure



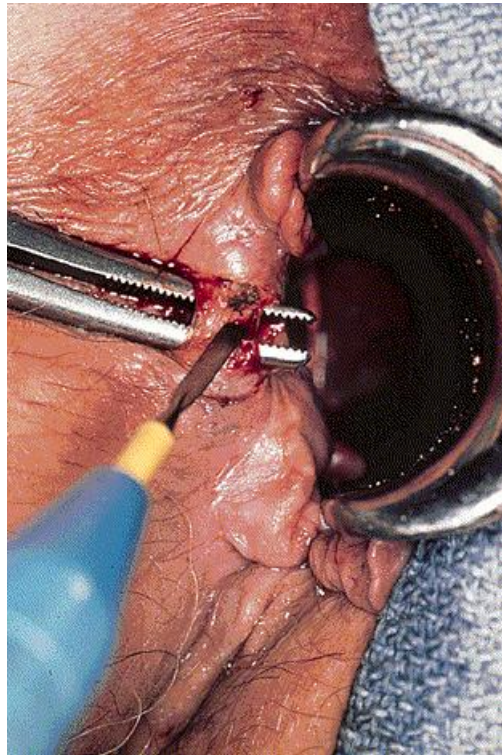
Treatment; Acute fissure

- Conservative
 - Bulk-forming agents
 - Local preparations, local anesthetics
 - Warm Sitz baths
- Pharmacologic Sphincterotomy; Glycerol Trinitrate, Calcium Channel Antagonists, Botulinum Toxin
- Sphincterotomy

Treatment Chronic fissure

- Conservative; same as acute
- Internal sphincterotomy (**lateral partial**) the **standard surgery**
- Classic Excision
- V-Y Anoplasty (Advancement Flap Technique)
- Finger Anal Sphincter Stretch; ??? Obsolete
- Controlled intermittent anal dilatation

Partial lateral internal sphincterotomy



Treatment Chronic fissure fissurectomy and V-Y Anoplasty

