



# Test Bank



**Subject:**

**Medicine miniOSCE**

**018-1<sup>st</sup> & 2<sup>nd</sup>**

**Collected by:**

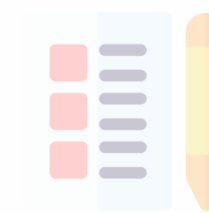
**Leen Hajeer**

**Ruba Alshawabkeh**

**Ameen Alsaras**

**Laila Nazzal**

**Mohammad Sallam**



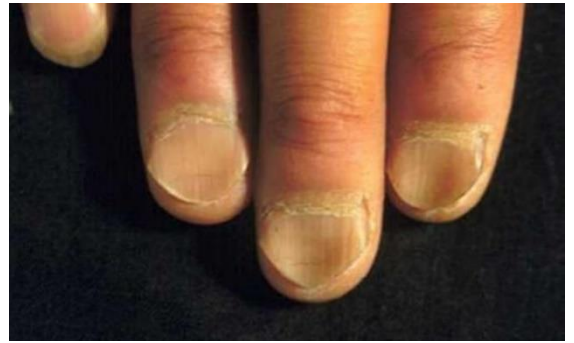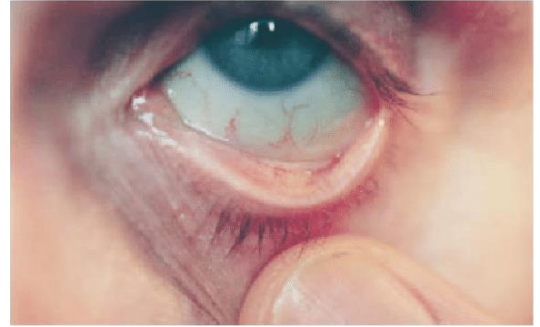
جامعة  
البيروت

1<sup>st</sup> Semester

Question-1

A 60-year old man came with fatigue and conjunctival pallor. He has been suffering from chronic constipation for 3 months with weight loss. MCV=70, RDW= 19, MCH= 25

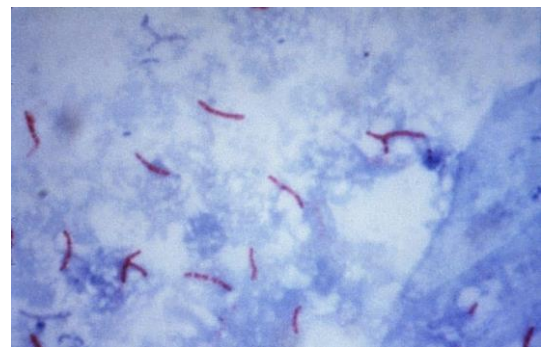
- 1) What is the diagnosis?
  - 2) What is the next step?
- A. Measuring serum B12 levels
  - B. Folate deficiency
  - C. Vitamin B12 deficiency
  - D. Colonoscopy
  - E. Bone marrow biopsy
  - F. Thalassemia
  - G. Iron deficiency anemia
  - H. Genetic testing



Question-2

A patient presents with a recent history of cough, fatigue, night sweats, and weight loss. Microscopy of his sputum with Ziel-Nelsen stain shows the following:

- 1) What is the diagnosis?
  - 2) What is the next step?
- A. Lung cancer
  - B. Tuberculosis
  - C. Perform a chest CT scan
  - D. Wait for the blood culture result
  - E. Streptococcal pneumonia
  - F. Start treatment
  - G. Redo the sputum microscopy

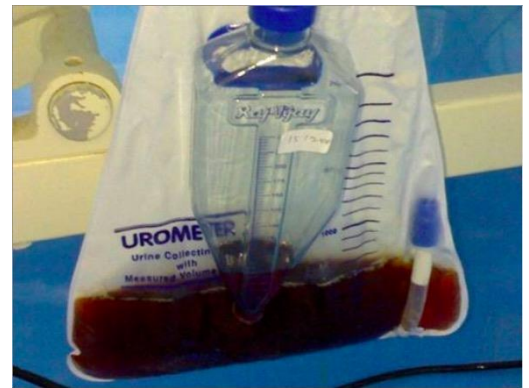

## H. Fungal infection

### Question-3

A patient who came with third-degree burns, vitally stable, oliguric, with dark red urine

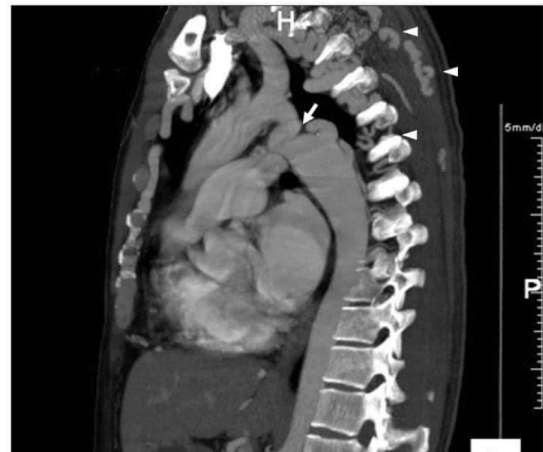- 1) What is the diagnosis?
- 2) The least likely to be found on urine analysis:
  - A. Hemolysis
  - B. Renal infarction
  - C. Rhabdomyolysis
  - D. Kidney stones
  - E. 3+ blood
  - F. RBC
  - G. Trace protein
  - H. No sugar



### Question-4

A patient presented with very severe hypertension, investigations were done and the result is as follows:

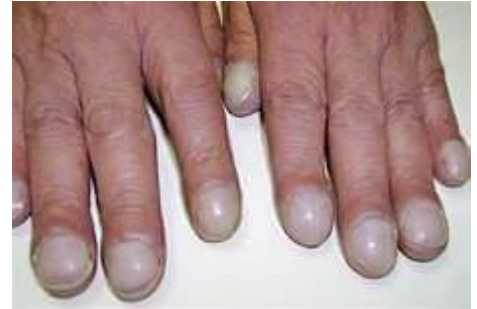- 1) What is the diagnosis
- 2) Found on Physical exam:
  - A. Coarctation of aorta
  - B. Renal artery stenosis
  - C. Ankylosing spondylitis
  - D. Aortic stenosis
  - E. Different BP readings in both arms
  - F. ESM murmur at the second intercostal space
  - G. Limited range of motion
  - H. Renal artery bruits



### Question-5

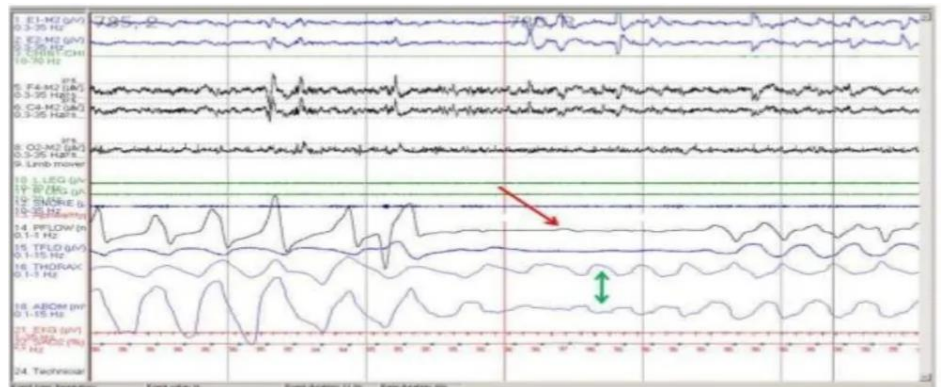
A 22-year-old female is present with a history of diarrhea of one year. Stool analysis showed multiple RBCs and WBCs but was negative for cysts and trophozoites. CRP= 56

- 1) What is the diagnosis?
- 2) The most appropriate next step:
  - A. Crohn's disease
  - B. Celiac disease
  - C. Colonoscopy
  - D. Hyperthyroidism
  - E. Amebiasis
  - F. Rapid antigen testing
  - G. Serology for anti-TTG IgA
  - H. Serum TSH



### Question-6

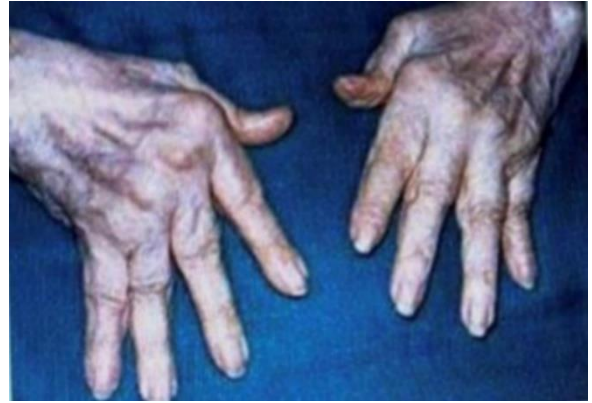A 40-year-old man complains of snoring and shortness of breath while sleeping. His BMI=40. Polysomnography was done and the results are shown:



- 1) What is the diagnosis?
- 2) Not a treatment option:
  - A. Hypoventilation
  - B. Central sleep apnea
  - C. Positive airway pressure
  - D. Obstructive sleep apnea
  - E. O2 therapy
  - F. Weight reduction
  - G. Mixed sleep apnea
  - H. Dental appliances
  - I. Exercise

### Question-7

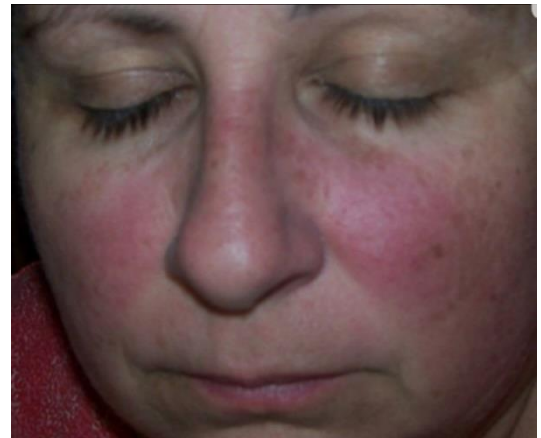A female patient presented with swelling and pain in her hands with morning stiffness lasting for about 30 minutes



- 1) What is the diagnosis?
  - 2) Which of the following is not a feature of her disease?
- A. Gout
  - B. Glomerulonephritis
  - C. Amyloidosis if not treated
  - D. Pericarditis
  - E. Rheumatoid arthritis
  - F. Osteoarthritis
  - G. Erosive changes on X-ray
  - H. Psoriatic arthritis

### Question-8

A young female is present with fatigue, facial rash, and thinning of her hair.

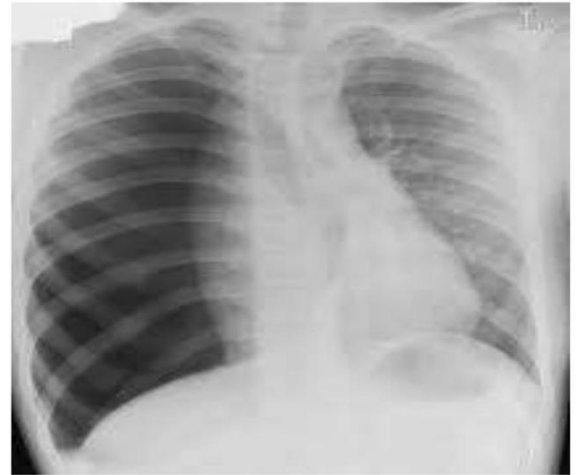

- 1) What is the diagnosis?
  - 2) Not a feature of the disease:
- A. Seizure
  - B. Hypothyroidism
  - C. Gastric antral vascular ectasia
  - D. Endocarditis
  - E. Systemic lupus erythematosus
  - F. Transverse myelitis
  - G. Dermatomyositis



### Question-9

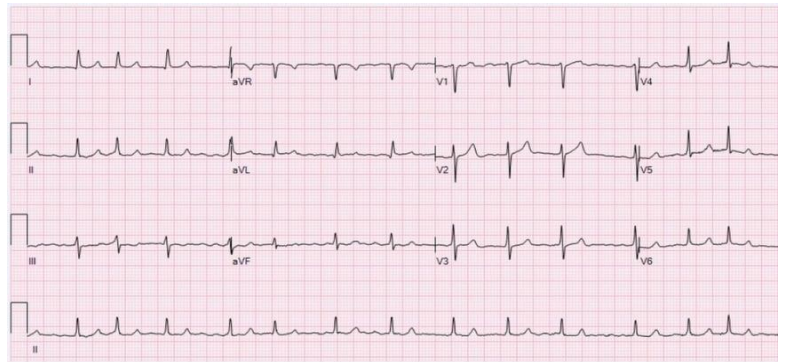
A 25-year-old male came to the ER with sudden onset shortness of breath and chest pain. X-rays showed the following:



- 1) What is the diagnosis?
- 2) Not present in the physical exam:
  - A. Pneumonia
  - B. Pneumothorax
  - C. COPD exacerbation
  - D. Lung mass
  - E. Fine inspiratory crackles with bronchial breathing
  - F. Tachycardia
  - G. Tachypnea
  - H. Resonant percussion notes

### Question-10

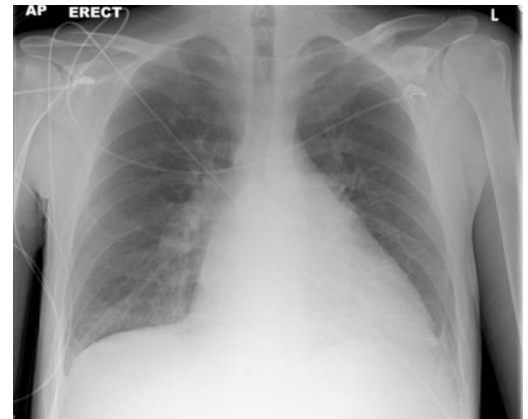A 60-year-old female has been suffering from palpitations for years.



- 1) What is the diagnosis?
- 2) Calculate the heart rate:
  - A. Atrial fibrillation
  - B. Multifocal atrial tachycardia
  - C. 80 bpm
  - D. 90 bpm
  - E. 100 bpm
  - F. 60 bpm
  - G. Premature atrial contraction
  - H. Sinus arrhythmia

### Question-11

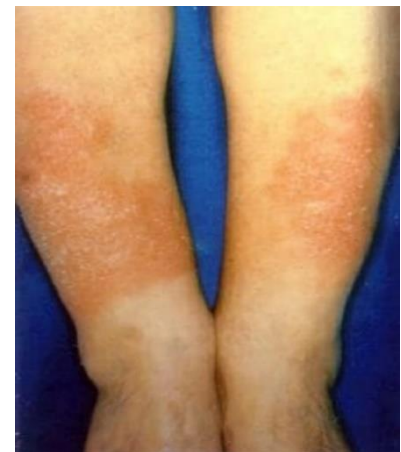A 62-year-old man is complaining of shortness of breath and orthopnea. He has a history of ischemic heart disease that dates to 10 years ago.



- 1) What is the diagnosis?
- 2) Worst case scenario:
  - A. Pneumonia
  - B. Cold and dry
  - C. Cold and wet
  - D. Pulmonary embolism
  - E. Warm and wet
  - F. Heart failure
  - G. Cold only
  - H. COPD

### Question-12

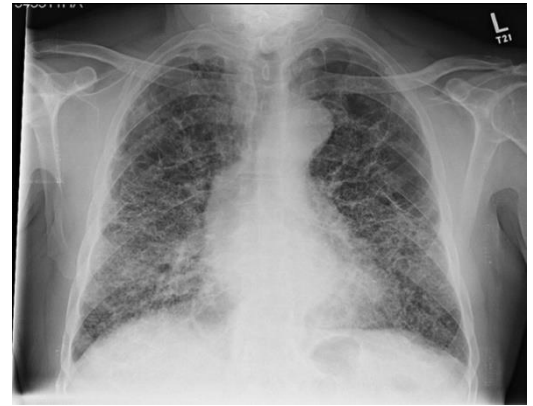A 25-year-old lady is complaining of loosening of bowel movements for 3 months. On physical examination, she has a pruritic maculopapular rash.



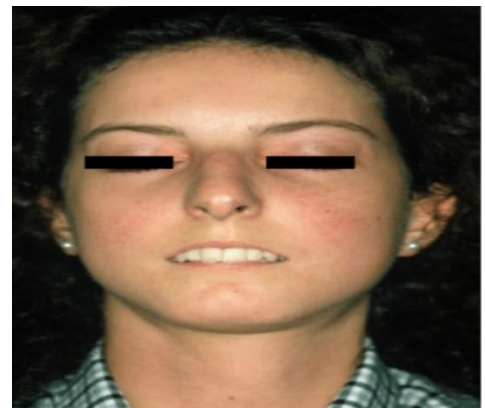- 1) Not likely to be present in history:
- 2) Not pathognomonic of grave's disease:
  - A. Lid retraction
  - B. Thyroid bruit
  - C. Exophthalmos
  - D. Constipation
  - E. Thyroid acropachy/ changes in her nails
  - F. Pretibial myxedema
  - G. Heat intolerance
  - H. Palpitations

### Question-13

The patient shown in the image below presented with shortness of breath and dry cough that she's been suffering from recently for the first time. She is otherwise healthy with no other symptoms.



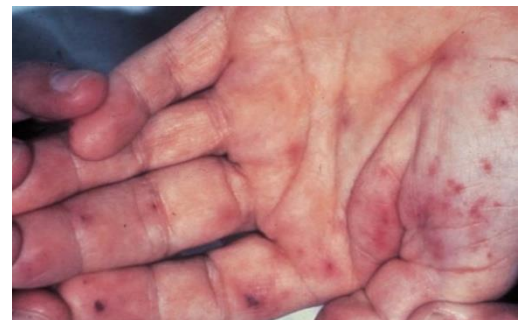- 1) What is the cause of her symptoms?
- 2) Diagnosis is made by:
  - A. Pleuritis
  - B. High-resolution CT scan
  - C. Lung collapse
  - D. CXR
  - E. Pulmonary edema
  - F. Interstitial lung disease
  - G. Conventional CT without contrast
  - H. Bronchoscopy



### Question-14

A patient who has a prosthetic mitral valve presented with fever as well as painless nodules on his arms.

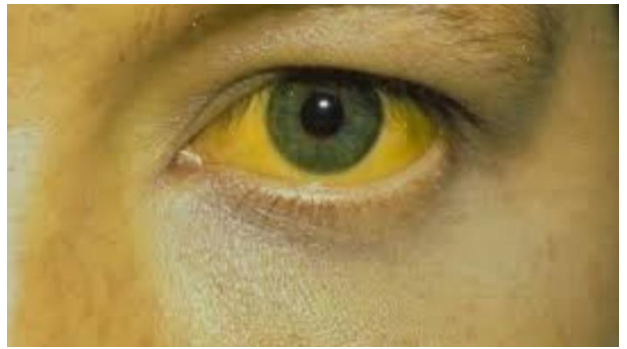- 1) Likely to be found on heart auscultation:
- 2) Diagnosis of the nodules
  - A. Inspiratory crackles
  - B. Ejection systolic murmur that radiates to the carotids
  - C. Janeway lesions
  - D. Ecchymoses
  - E. Loud s1
  - F. Splinter hemorrhage
  - G. Pansystolic murmur that radiates to the axilla
  - H. Osler's nodes



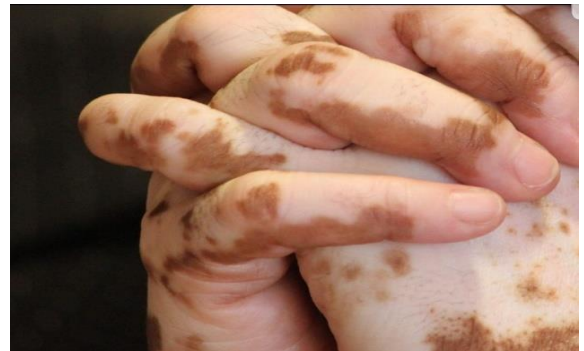

### Question-15

A 40-year-old lady presented with jaundice and right upper quadrant pain. The liver edge is palpable, smooth, and tender on examination with liver span being 16 cm. She is also a known case of hypothyroidism. AST= 1400, ALT=1300.



- 1) What is the diagnosis?
- 2) The best method for obtaining definitive diagnosis:
  - A. Autoimmune hepatitis
  - B. Antinuclear and Anti-smooth muscle antibodies
  - C. Antimitochondrial antibodies
  - D. Acute B hepatitis
  - E. Acute C hepatitis
  - F. Serum hepatitis B surface antigen
  - G. Antibodies against hepatitis c virus
  - H. Primary sclerosing cholangitis



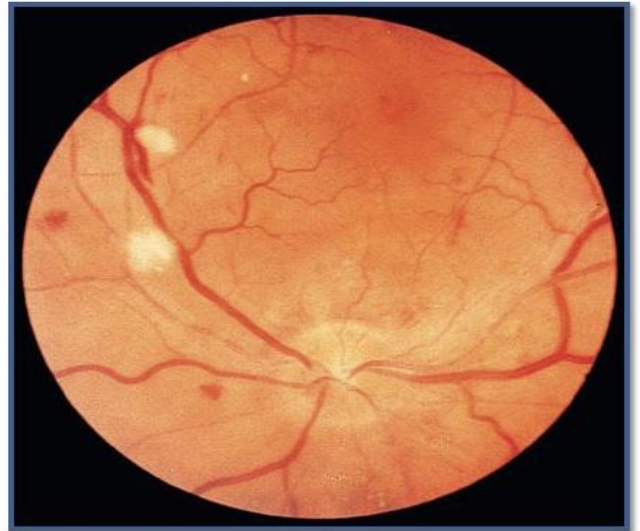## Answers:

Q1	G	D
Q2	B	F
Q3	C	F
Q4	A	E
Q5	A	C
Q6	D	E
Q7	E	B
Q8	F	C
Q9	B	E
Q10	A	C
Q11	F	C
Q12	D	A
Q13	F	B
Q14	G	C
Q15	A	B

## 2<sup>nd</sup> Semester

### Question-1

55 year-old male patient presented to the emergency department complaining of headache, left sided weakness and blurred vision. His blood pressure was 170/110. Fundoscopy showed the following image.

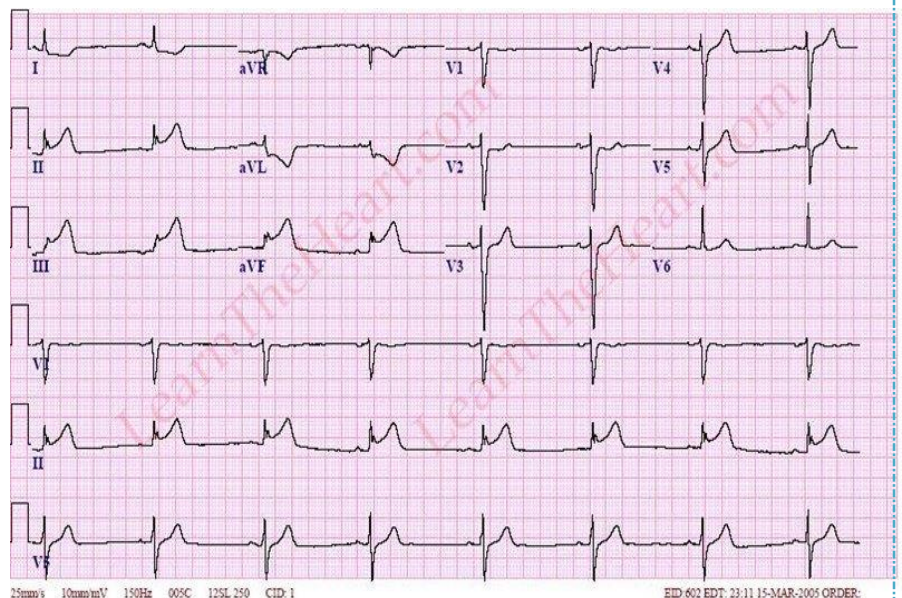


- 1- What is the most likely diagnosis?
- 2- What is the most appropriate next step?

- A- Hypertensive emergency
- B- severe uncontrolled hypertension
- C- ruptured aortic aneurysm,
- D- Chest X-ray
- E- CT coronary angiography
- F- Chest CT
- G- Brain CT without contrast

### Question-2

55 Year-Old male patient presented to the emergency department complaining of chest pain. He has a history of diabetes and hypertension. His ECG as the following:



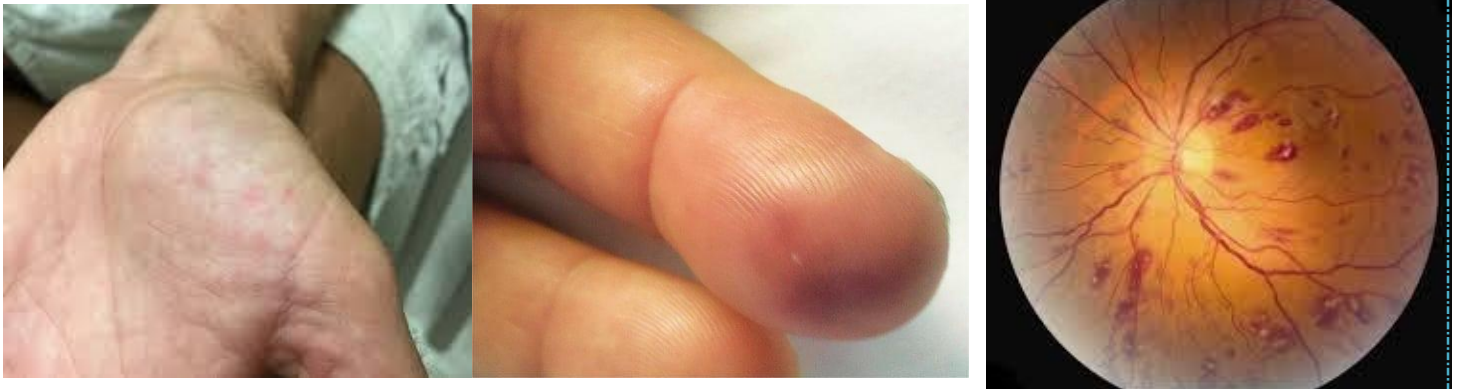- 1- What is the most likely diagnosis?
- 2- Which of the following is the least likely finding in this patient?

- A- Pulmonary embolism
- B- Anterior wall MI

- C- Inferior wall MI
- D- Pericarditis
- E- Clod extremities
- F- Elevated JVP
- G- Pulmonary edema on CXR
- H- Bradycardia
- I- Hypotension

### Question-3

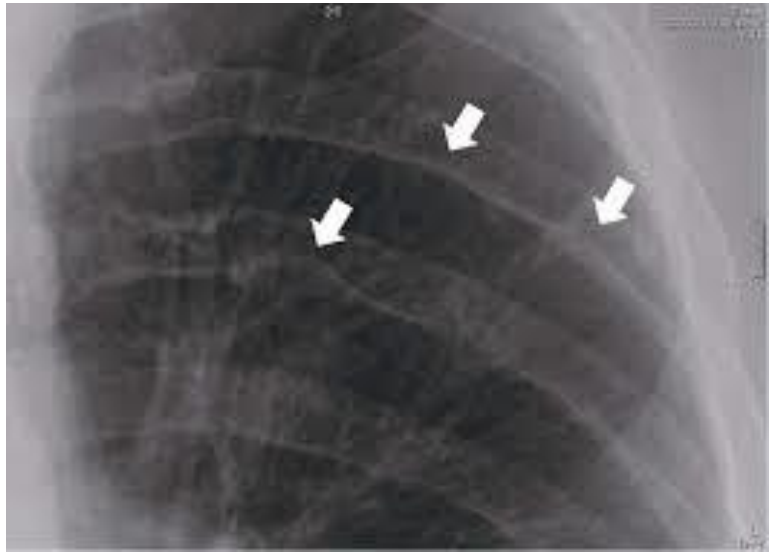A patient was ESRD, presented to the ER with fever, dyspnea, hypotension, and hand lesions. Last week he had dialysis through central line. His physical exam is as follows:



- 1- What is the most likely diagnosis?
- 2- What is the next step in diagnosis?
  - A- Rheumatic fever
  - B- Infective endocarditis
  - C- Atrial fibrillation
  - D- Echocardiography
  - E- Chest X Ray
  - F- ECG
  - G- Chest CT

#### Question-4

Young female patient presented complaining of headache. Physical exam showed ejection systolic murmur at the second right intercostal space, weak lower limb pulses. Her blood pressure was 170/110. Chest x ray showed the following:

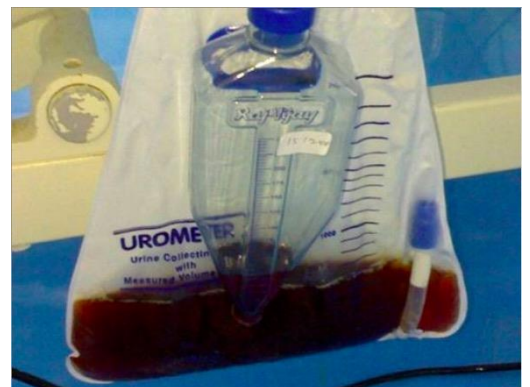

- 1- What is the most likely diagnosis?
- 2- What syndrome is most commonly associated with these findings?
  - A- Aortic dissection.
  - B- Aortic regurgitation.
  - C- Coarctation of aorta.
  - D- Migraine headache.
  - E- Down syndrome.
  - F- Kallman syndrome.
  - G- Turner syndrome.

#### Question-5

A patient who came with third-degree burns, vitally stable, oliguric, with dark red urine

- 1) What is the diagnosis?
- 2) The least likely to be found on urine analysis:
  - A- hemolysis
  - B- renal infarction
  - C- Rhabdomyolysis
  - D- kidney stones
  - E- 3+ blood
  - F- RBC
  - G- Trace protein
  - H- No sugar

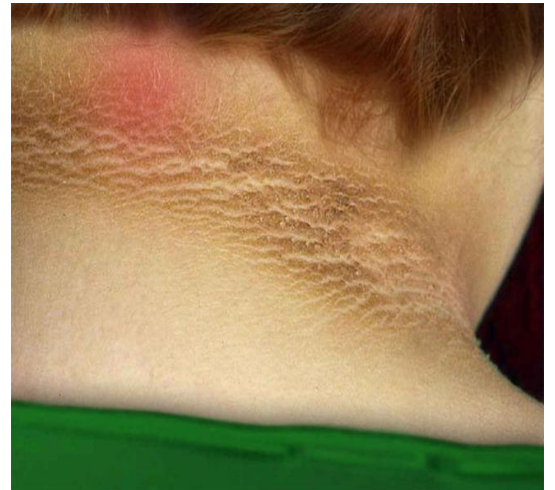



### Question-6

15 year old female patient presented to the clinic complaining of polyuria and polydipsia. Her BMI is 31kg/m<sup>2</sup>. Her physical exam showed the following:

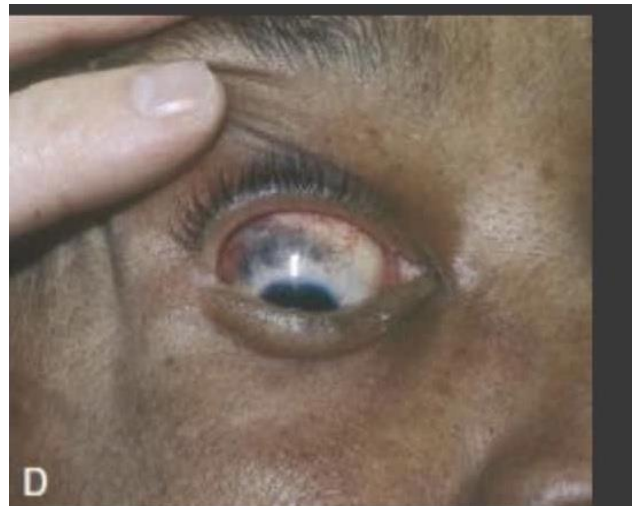- 1- What is the most likely diagnosis?
- 2- Which of the following test is least likely to differentiate between type 1 and type 2 Diabetes?
  - A- She mostly has type 1 diabetes.
  - B- She mostly has type 2 diabetes.
  - C- She needs further testing.
  - D- She has. MODY
  - E- Anti-insulin receptor antibodies.
  - F- Anti-glutamic acid decarboxylase.
  - G- Islet cell antibodies.
  - H- Ketone bodies in urine.



### Question-7

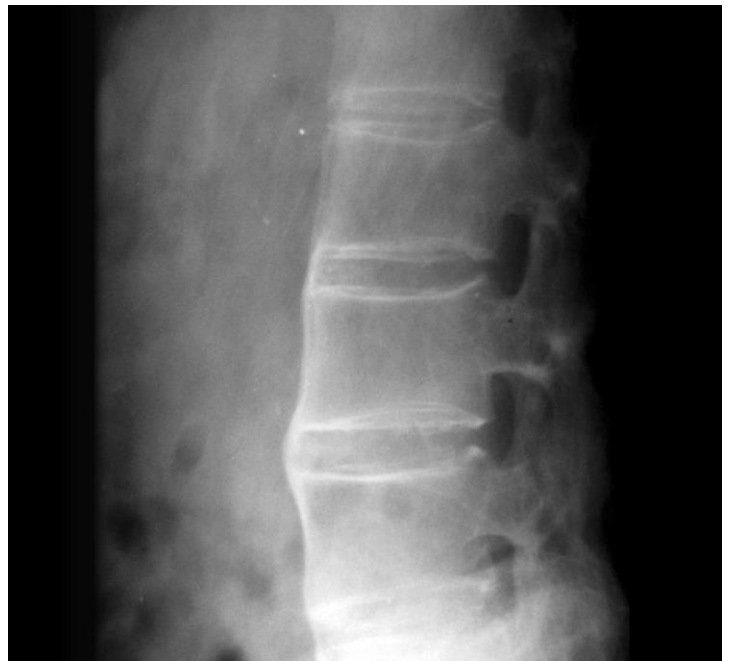Patient with long standing rheumatoid arthritis taking hydroxychloroquine. . presented complaining of painful eyes. Exam showed the following finding.

- 1- What is the most likely diagnosis?
- 2- What is the most likely complication?
  - A- Hydroxychloroquine retinopathy.
  - B- Scleromalacia
  - C- Sicca syndrome
  - D- Eye perforation



### Question-8

25 year old male patient presented to the clinic complaining of back morning stiffness for 1 hour that improves with movement and exercise and relieved by NSAIDS. Lumbar spine X Ray is shown:

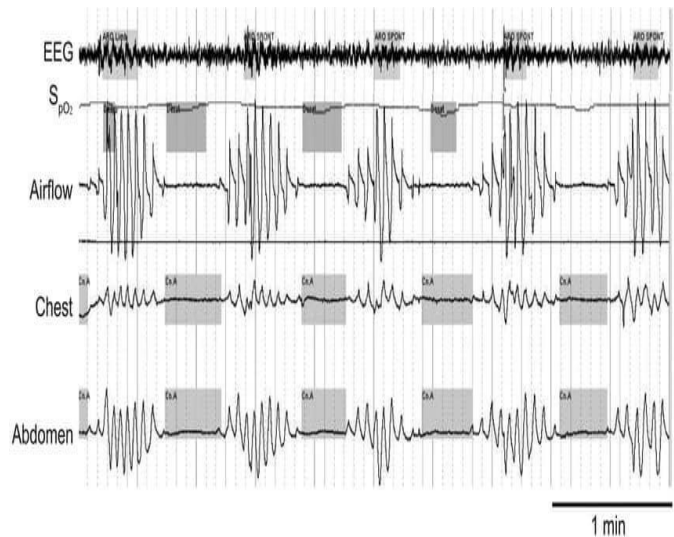


- 1- What does the x ray shows?
  - 2- Which of the following is a complication of his condition?
- A-osteophytes.
  - B-Disc prolapse.
  - C-syndesmophytes.
  - D-enthesitis.
  - E-neuropathy.
  - F-amyloidosis.
  - G-Neutropenia.

### Question-9

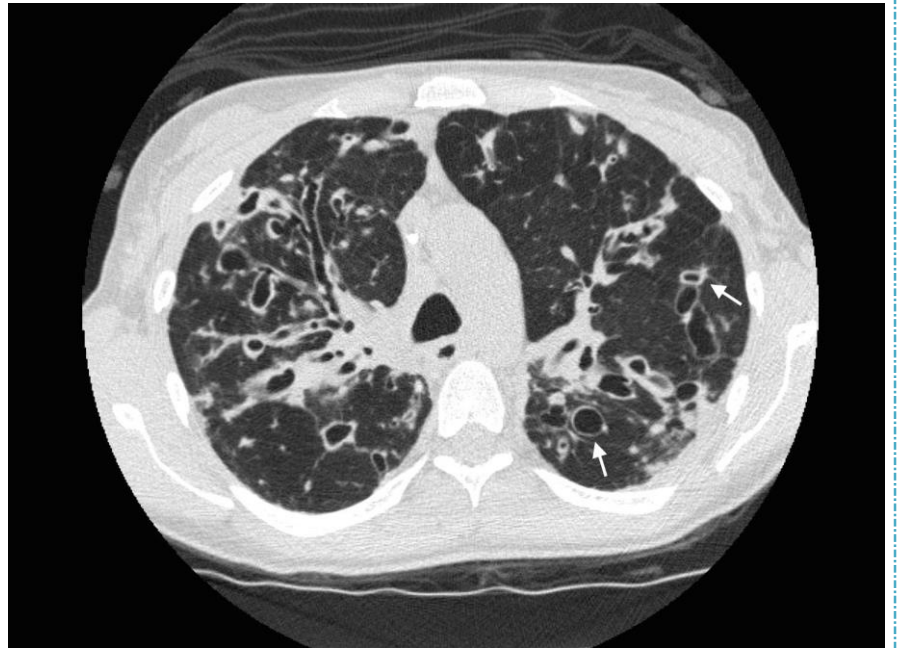
Polysomnography as shown below:

- 1- Which if the following patients least likely to have this PSG?
  - 2- What differentiates between type (1) and type (2) PSG?
- A-Male post Lap chole on opioids.
  - B-male with BMI 45 for bariatric surgery.
  - C-Patient with brain tumour.
  - D-Patient with neurological problems.
  - E-ECG
  - F-EEG
  - G-O2 sat
  - H-nasal cannula
  - I-Abdominal and thoracic bel



### Question-10

20 year old female presented to the clinic with a long history of productive cough, she has no history of bird exposure. No allergies. Her imaging is show below.



1- What is the most likely diagnosis?

2- What is the imaging modality?

A- primary ciliary dyskinesia.

B- cystic fibrosis.

C- allergic pulmonary aspergillosis .

D- alpha-1 anti trypsin deficiency.

E- Chest CT w/o contrast

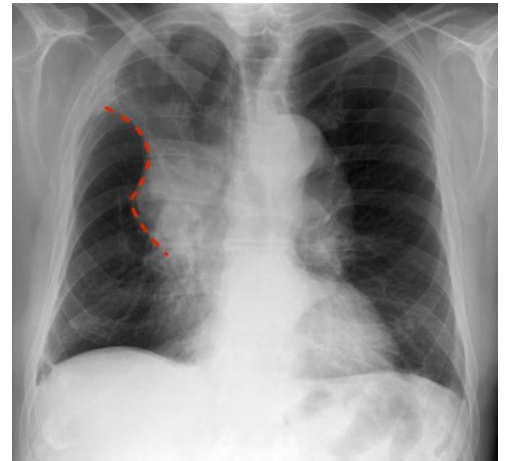F- High resolution CT scan

G- X-ray

H- CT coronary angiogram

### Question-11

A 56 year-old man presented complaining of cough and hemoptysis of 1 month duration. He is a smoker for 30 years. His x ray is shown.



1. What is the most likely diagnosis?

2. What is the most appropriate next step?

A- Adenocarcinoma of the lung

B- Tuberculosis

C- Pulmonary embolism

D- Squamous cell carcinoma

E- Pneumonia

F- Chest CT

G- Chest tube

H- D dimer

I- Bronchoscopy

### Question-12

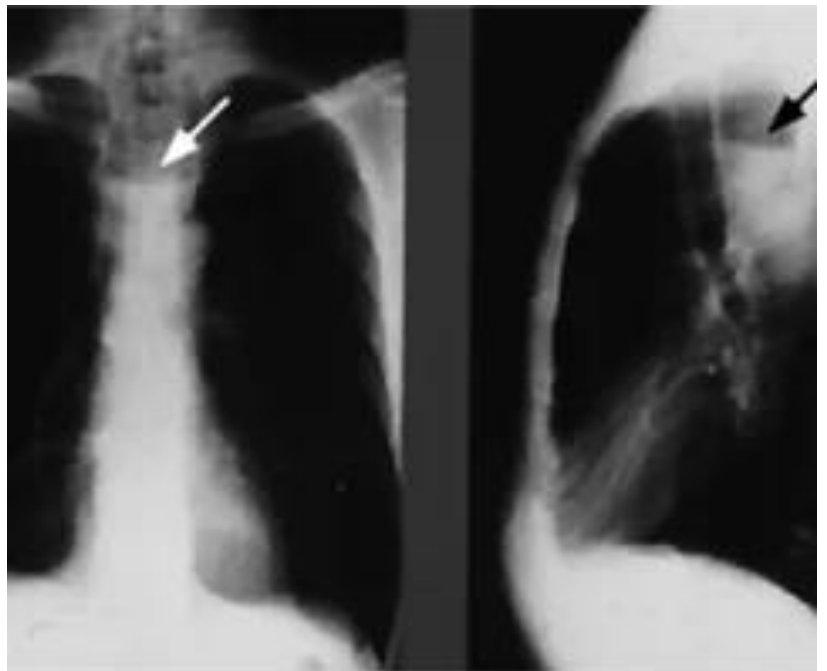
A healthcare worker presented to the clinic for regular check up. In his last visit he underwent a PPD skin test which yielded an induration of 5mm. In this visit he undergoes another ppd test and the result is shown ( an image with an induration of 18mm was shown).

- 1- What is the best next test?
  - 2- If the above test you ordered was negative what does that mean?
- A- X-ray.
  - B- Repeat PPD six months later.
  - C- Sputum acid fast bacilli smear
  - D- The patient is vaccinated.
  - E- The patient has Active TB.
  - F- The patient has Latent TB.

### Question-13

A 35 year old female patient presented to the clinic complaining of progressive dysphagia for 2 years. X-ray is shown.

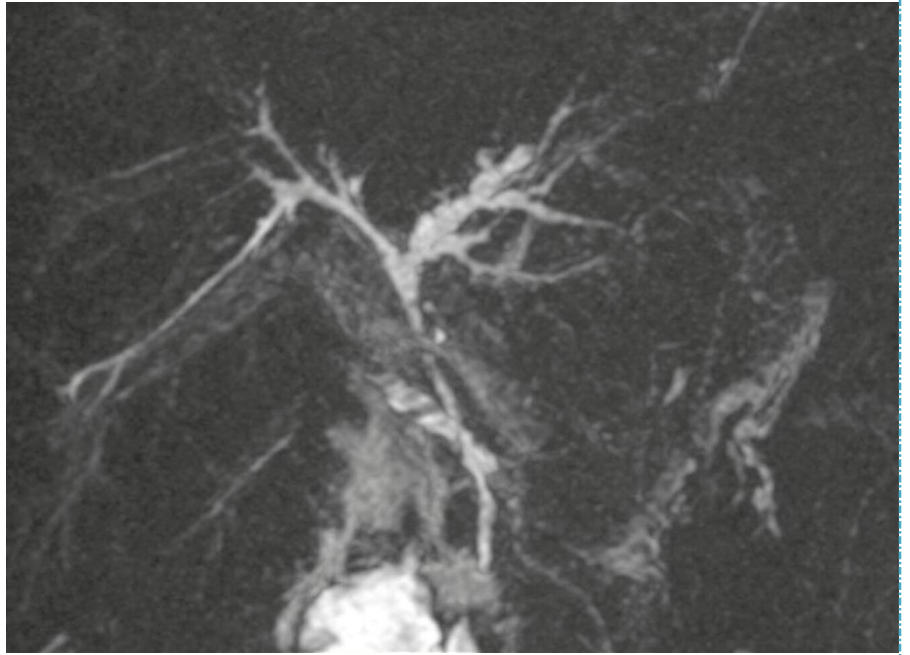
- 1- What is shown in the image?
  - 2- What is the most appropriate next step?
- A- Air-fluid level in the esophagus.
  - B- Beard beaks sign.
  - C- Hiatal hernia
  - D- Chest CT
  - E- Upper GI endoscopy.
  - F- Barium swallow
  - G- None of the above





### Question-14

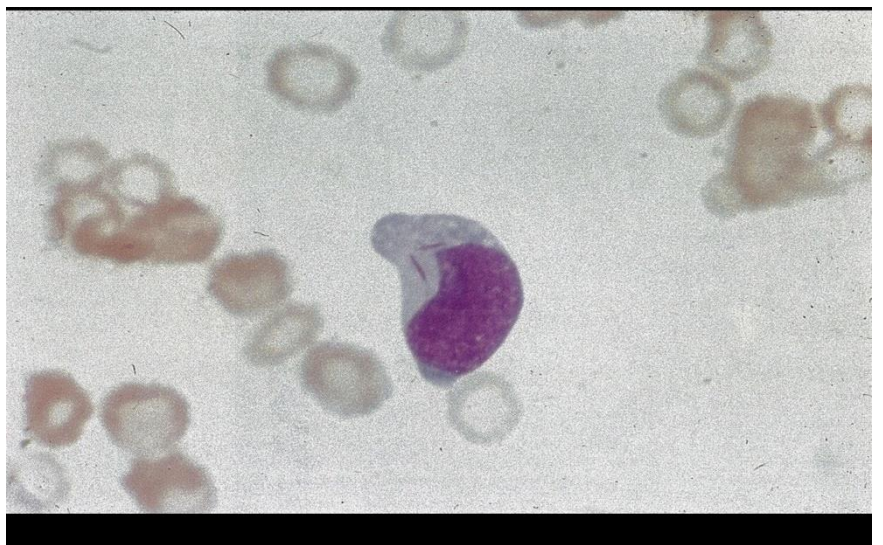A 40 year old male patient presented to the clinic complaining of fatigue, pruritus, and yellowing of the skin and sclera. He has a long history of ulcerative colitis. Labs showed elevated ALP and GGT and normal ALT and AST. MRCP is shown.



- 1- What is the most likely diagnosis?
- 2- What is the most likely complication?
  - A- Primary biliary cholangitis.
  - B- Primary sclerosing cholangitis.
  - C- Autoimmune-hepatitis.
  - D- Alcoholic cirrhosis.
  - E- Hepatocellular carcinoma.
  - F- Cholangiocarcinoma.
  - G- Gallbladder carcinoma.
  - H- Pancreatic cancer

### Question-15

A 65 Year old male presented complaining of a few weeks onset of fatigue, pallor, weakness, epistaxis, and bleeding gums. Physical examination showed hepatosplenomegaly. Labs: HB: 9g/dl. Plt:80,000/mm<sup>3</sup>. Peripheral blood smear is shown below.



- 1-What is the most likely diagnosis?



2-What is the name of the cell shown?

- A- Chronic myeloid leukaemia.
- B- Acute lymphoblastic leukaemia.
- C- Acute myeloid leukaemia.
- D- Multiple myeloma.
- E- Chronic lymphocytic leukaemia.
- F- Smudge cells
- G- Auer rods cells
- H- Popcorn cells
- I- Hairy cell

Answers:

Question	Part 1	Part 2
Q1	A	G
Q2	C	G
Q3	B	D
Q4	C	G
Q5	C	F
Q6	B	H
Q7	B	D
Q8	C	F
Q9	B	F
Q10	B	F
Q11	D	I
Q12	A	F
Q13	A	E
Q14	B	F
Q15	C	G

اذكرونا بدعوة ✨