Vascular diseases of the central nervous system

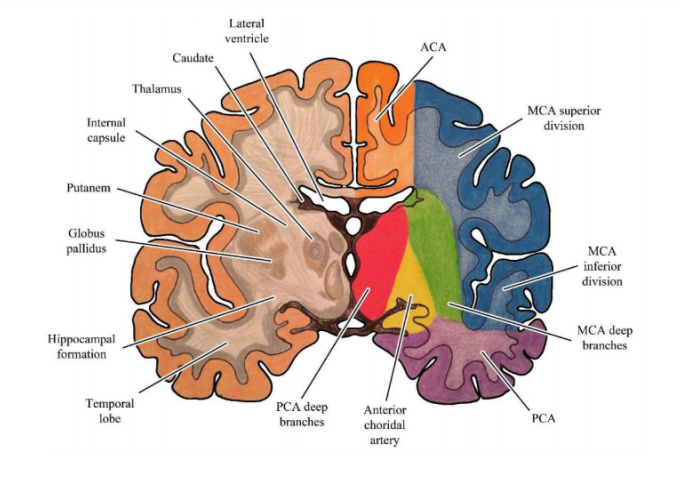

-ICA gives rise to : ophthalmic artery, anterior choroidal , posterior communicating
-ACA supplies the anterior medial cerebral hemispheres , the caudate nuclei and the basal frontal lobes.
-MCA > lenticulostriate > basal ganglia and internal capsule.
-MCA > 2branches >superior to the sylvian fissure+ to parietal and temporal
-vertebral A> PICA
-basialrA > AICA + medial of midbrain and thalami
-PCA > midbrain and thalamus +occipital+ nferior surface of the temporal lobe

i

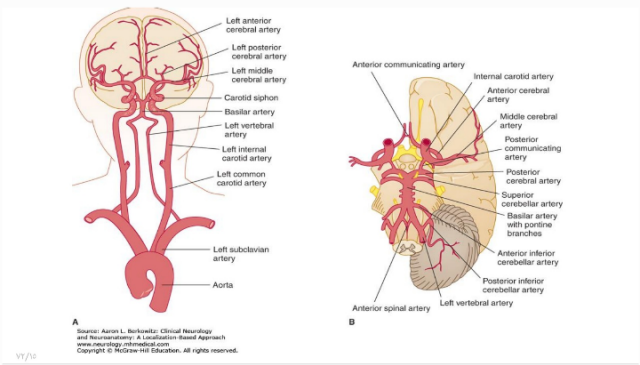

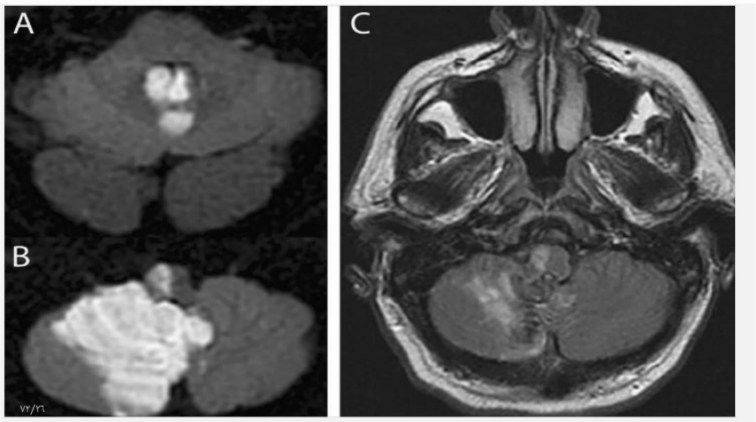

Occlusion of Posterior circulation
-Lateral medullary stroke (Wallenberg syndrome)
-VA or PICA occlusion
Face:
-Ipsilateral facial pain, or reduced pain and temperature
-Ipsilateral Horner
-nystagmus
Body
-decreased pain and temperature in the contralateral limbs
-Incoordination of the ipsilateral arm
- ataxia
-dysphagia and hoarseness

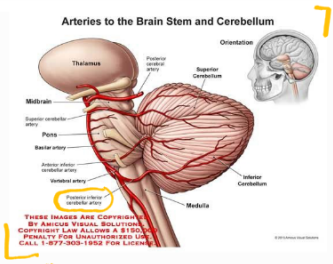

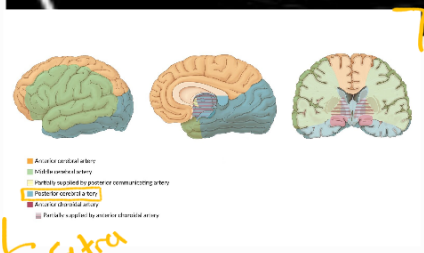

Extra

Left PCA stroke

- Right homonymous hemianopia
-amnesia
-Alexia(can't read) without agraphia(can't write) when the splenium of the corpus callosum is involved
-often caused by embolism arising from the heart, aorta or VAs

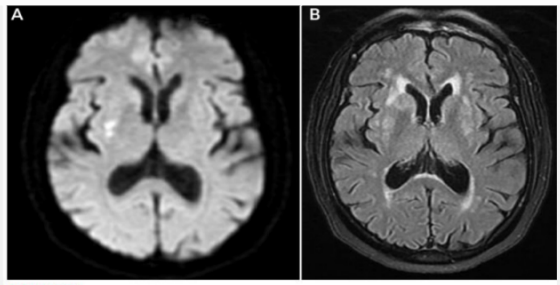

FIGURE 5-2
Imaging of the patient in CASE 5-1. Axial diffusion-weighted MRI (A) shows an acute infarct involving the right lentiform nucleus and internal capsule, and axial fluid-attenuated

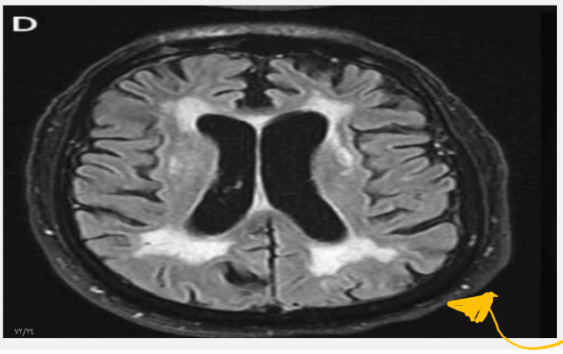

lacunar stroke syndromes
1. Pure motor stroke
Weakness of the contralateral arm, face and leg
corona radiata, posterior limb of the internal capsule and pons
2. Pure sensory stroke
-Paresthesiae of the contralateral body,
-ventral posterior thalamus
3. Sensorimotor stroke
-ventral posterior thalamus and adjacent posterior limb of the internal capsule
4. Dysarthria-clumsy hand syndrome
5.ataxic hemiparesis
-pons, posterior of internal capsule and corona radiata
-cerebral small vessel disease leads to lacunar infarction

- normal brain CT with calcified choroid plexus

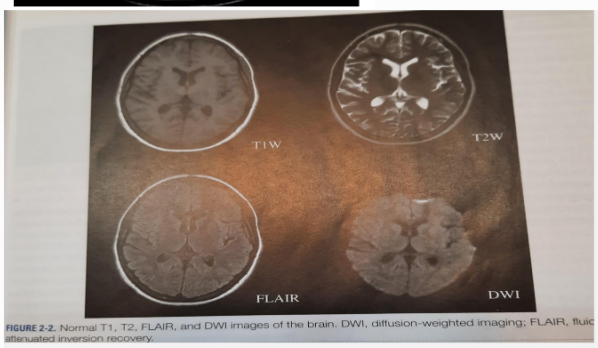

FIGURE 2-2. Normal T1, T2, FLAIR, and DWI images of the brain. DWI, diffusion-weighted imaging; FLAIR, fluid attenuated inversion recovery.

- normal brain MRI

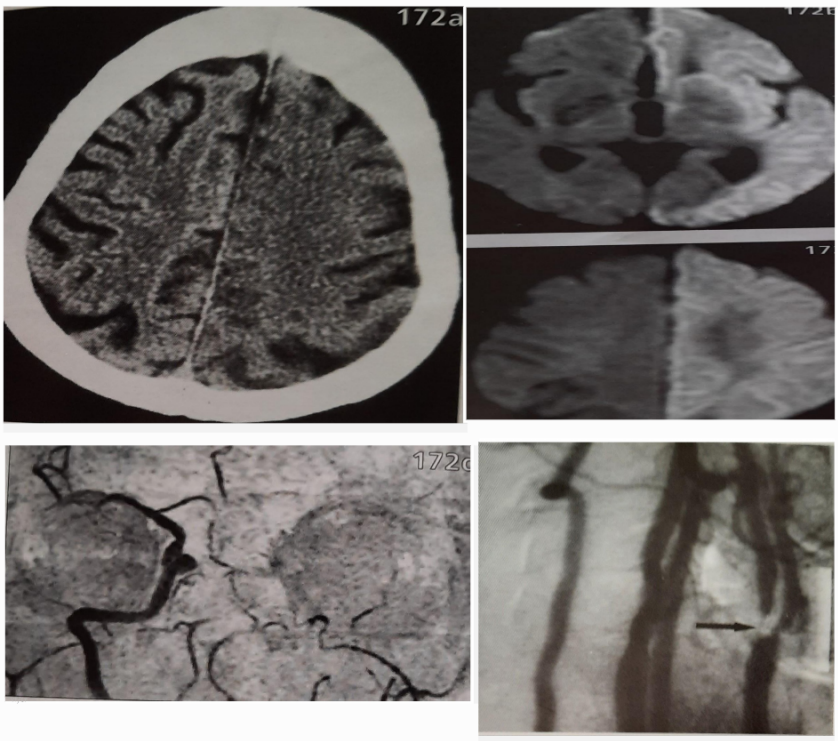

- infarction on the left hemisphere due to occlusion of the left ICA
- Subtle changes are seen on CT
- occluded ICA on angiography

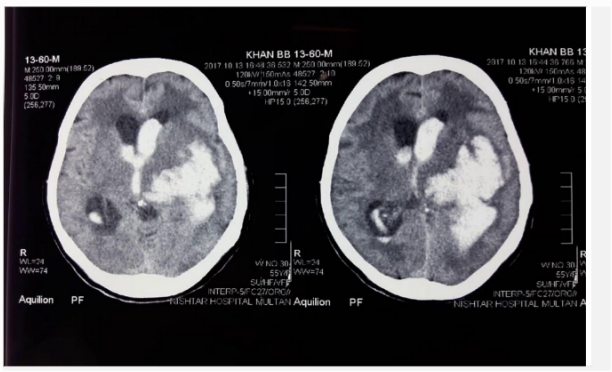

-CT
-hemorrhage

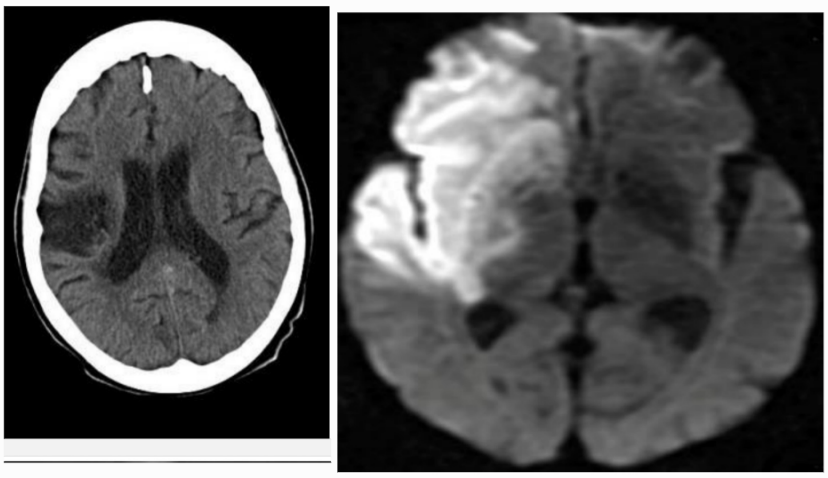

Occlusion of Right MCA small branches leading to infarction

Subarachnoid hemorrhage
- traumatic injury of aneurysm at circle of Willis
-sudden-onset, severe headache, vomiting

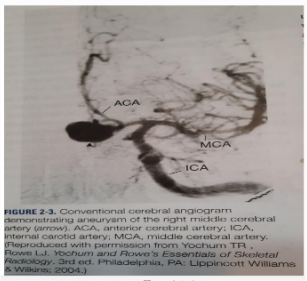

FIGURE 2-3. Conventional cerebral angiogram demonstrating aneurysm of the right middle cerebral artery (arrow). ACA, anterior cerebral artery; ICA, internal carotid artery; MCA, middle cerebral artery. (Reproduced with permission from Yochum TR, Rowe LJ. *Yochum and Rowe's Essentials of Skeletal Radiology*. 3rd ed. Philadelphia, PA: Lippincott Williams & Wilkins; 2004.)

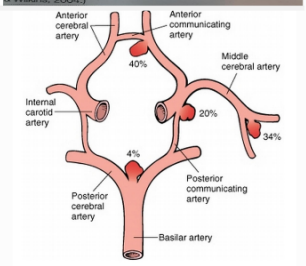

Aneurysms

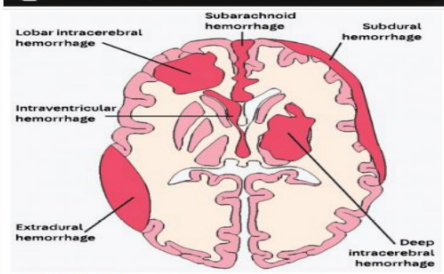

FIGURE 3-2
Locations and types of intracranial hemorrhage that may be seen on noncontrast CT.

Intracerebral hemorrhage
-headache and neurologic signs
- most common cause: Hypertension (Charcot-Bouchard microaneurysms)
- locations :basal ganglia, internal capsule, caudate nucleus, thalamus, pons and cerebellum.
- common cause in elderly is Cerebral amyloid angiopathy

« ذلك سر قوة العقيدة في النفس ، وسر قوة النفس بالعقيدة . سر تلك الخوارق التي صنعتها العقيدة في الأرض وما تزال في كل يوم تصنعها . الخوارق التي تغير وجه الحياة من يوم إلى يوم ، وتدفع بالفرد وتدفع بالجماعة إلى التضحية بالعمر الفاني المحدود في سبيل الحياة الكبرى التي لا تفنى ؛ وتقف بالفرد القليل الضئيل أمام قوى السلطان وقوى المال وقوى الحديد والنار ، فإذا هي كلها تنهزم أمام العقيدة الدافعة في روح فرد مؤمن . وما هو الفرد الفاني المحدود الذي هزم تلك القوى جميعاً ، ولكنها القوة الكبرى الهائلة التي استمدت منها تلك الروح ، والينبوع المتفجر الذي لا ينضب ولا ينحسر ولا يضعف » [1] .

— سيّد قُطب