

Surgical Complications

Reducing the risks of complication

- Good pre-operative evaluation
- Optimizing the general condition of patients
- Medical issues
- Nutritional issues (malnutrition, obesity)
- Minimizing preoperative hospital stay
- Good surgical technique
- Early mobilization

Complications

- What operation did the patient have?
- What are the most common complications of this operation?
- What is most life-threatening?
- What co-morbidities does the patient have?

Overview

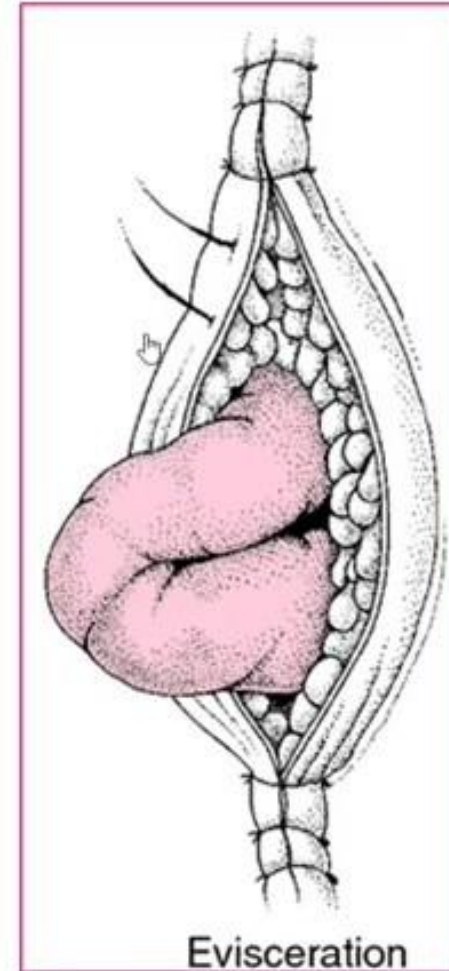
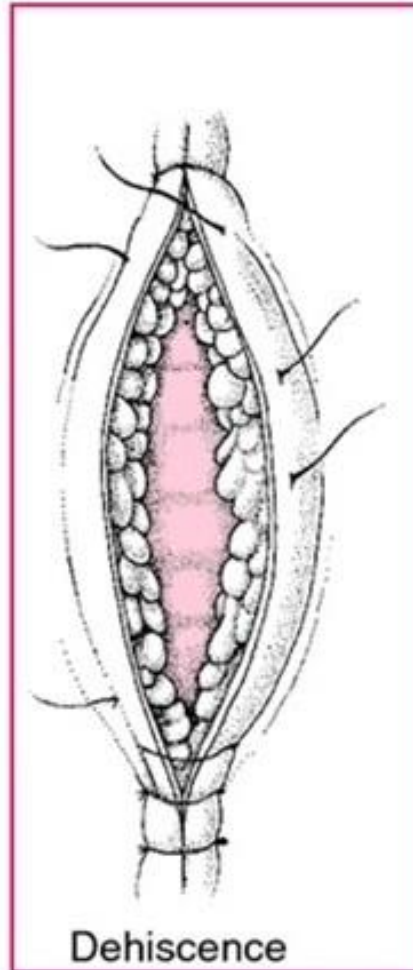
- Post op care has 3 phases
 - Immediate post op care (Recovery phase)
 - Care in the ward before discharging from the hospital
 - Continued care after discharge from the hospital

Classification

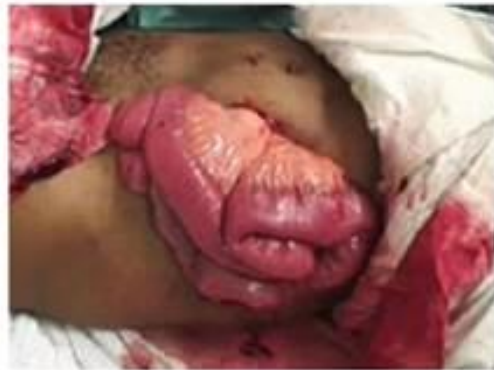- Wound
- Thermal regulation
- Postoperative fever
- Pulmonary
- Cardiac
- Gastrointestinal
- Metabolic
- Neurological

Wound Complications

- Dehiscence
- Evisceration
- Seroma
- Hematoma
- Infection
- Incisional Hernia

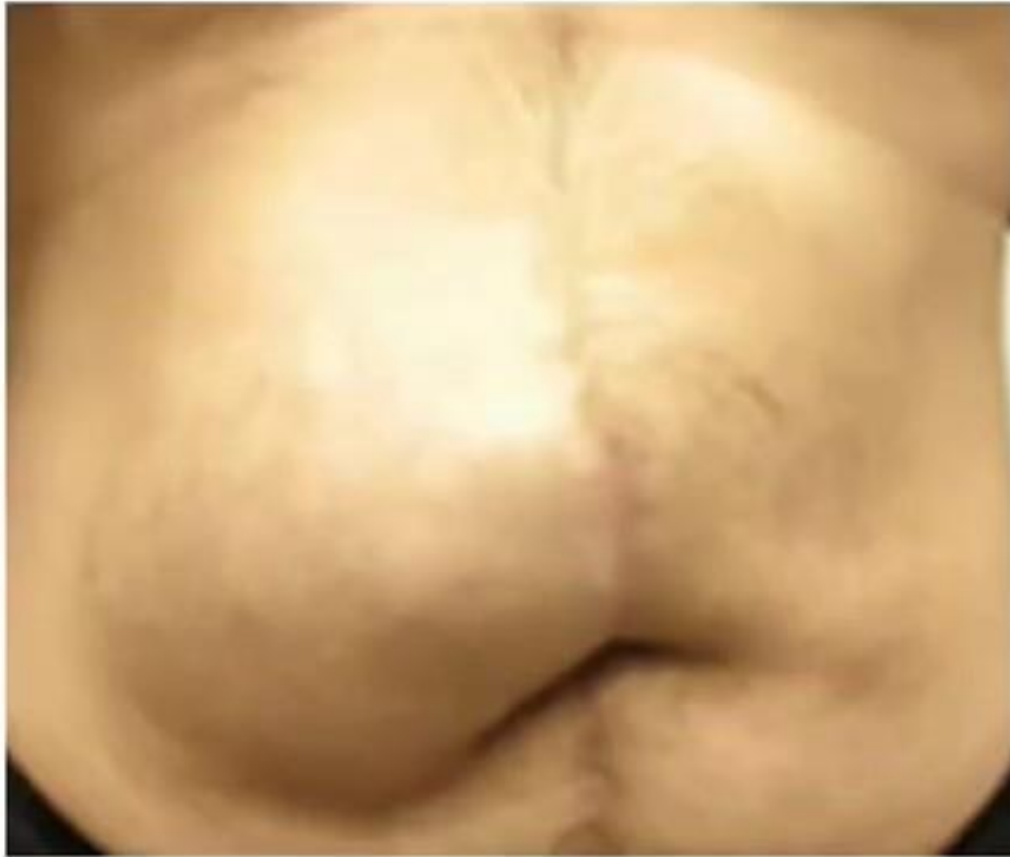

What do you do?



http://www.google.com/url?sa=i&ict=j&q=&esrc=s&frm=1&source=images&cd=&cad=rja&uact=8&ved=0CAcQjRw&url=http://medical-dictionary.thefreedictionary.com/dehiscence&ei=X5-IVezGMuvggTUo4CICQ&bv=bv.96339352.d.cw&psig=AFQjCNEcvCFmP3NkgXq@up1-_xS2_1j-A&ust=1435074756451535

Seroma

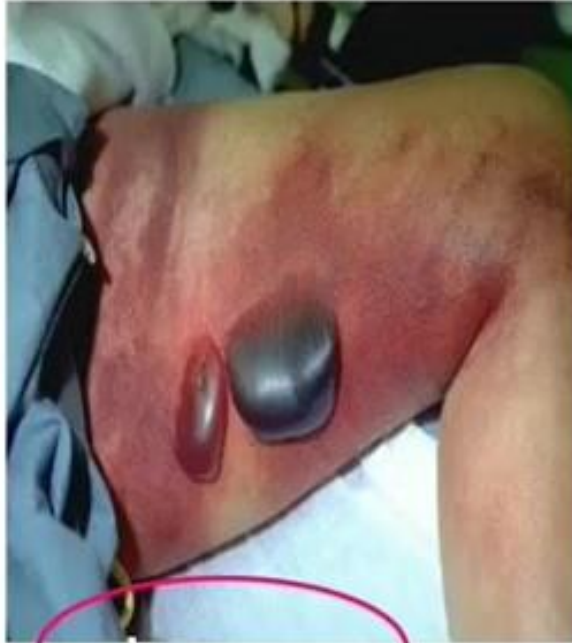

- Collection of liquefied fat, serum and lymphatic fluid under the incision
- Benign
- No erythema or tenderness
- **Associated procedures:** mastectomy, axillary and groin dissection
- Treatment: evacuation, pack, suction drains

Hematoma

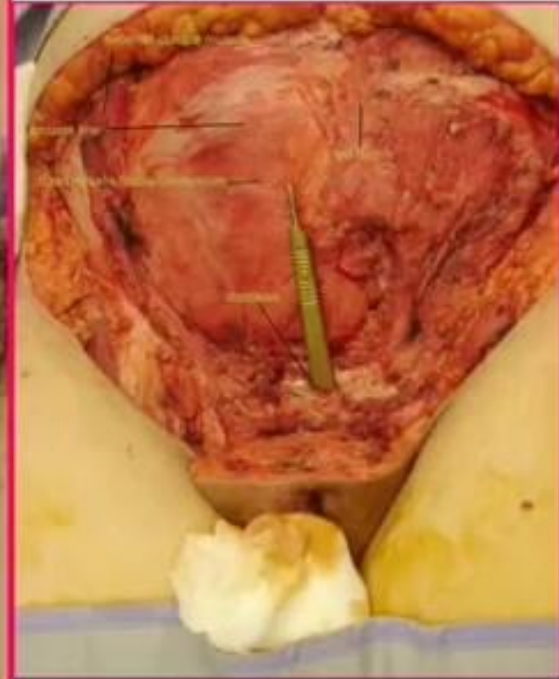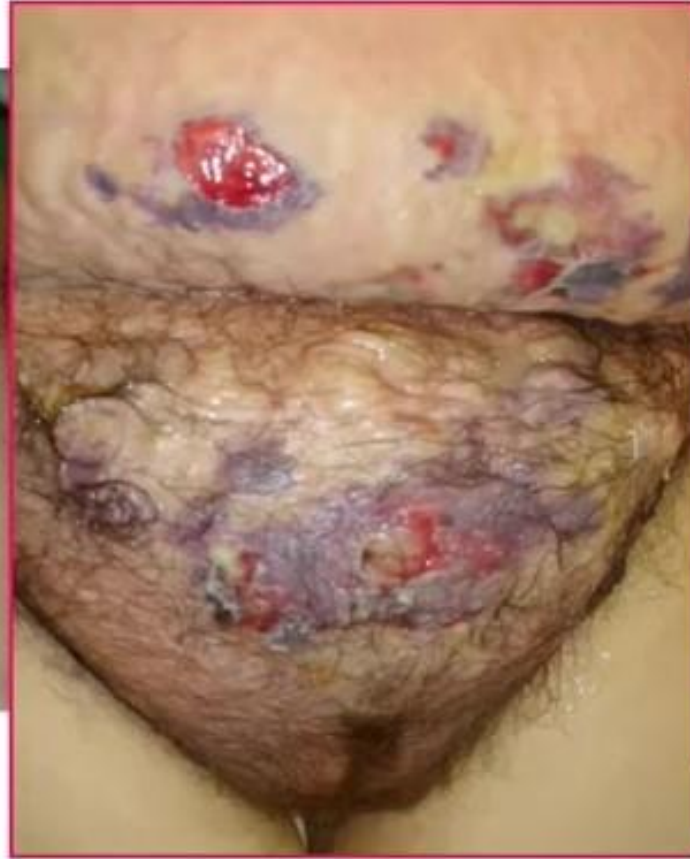- Abnormal collection of blood
- Presentation: discoloration of the wound edges (purple/blue), blood leaking through sutures
- Etiology: imperfect hemostasis
- What is the biggest concern with retained hematoma in the wound?

Necrotizing Fasciitis



These large, dark, boil-like blisters are a diagnostic symptom of necrotizing fasciitis (also known as flesh-eating disease).

(Source: EMBES, 1996 <http://medfasc.com/>)



Wound Infection

- Group A β -hemolytic streptococcal gangrene – following penetrating wounds
- Clostridial myonecrosis – postoperative abdominal wound
- Presentation: sudden onset of pain at the surgical site following abdominal surgery, crepitus \rightarrow edema, tense skin, bullae = EMERGENCY
- Necrotizing fasciitis – associated with strep, Polymicrobial, associated with DM and PVD
- Management: aggressive early debridement, IV antibiotics

Complications of Thermal Regulation

Hypothermia

- Drop in temp by 2° C
- Temp below 35 ° C → coagulopathy, platelet dysfunction

- Risks:
 - (1) 3x risk increase of cardiac events
 - (2) 3x risk increase of SSI
 - (3) increase risk of blood loss and transfusion requirement

Malignant hyperthermia

- Autosomal dominant, rare
- Presentation: fever, tachycardia, rigidity, cyanosis
- Treatment: Dantrolene 1 to 2 mg/kg
→ 10 mg/kg total until symptoms subside

Postoperative Fever

- What is the number #1 cause of fever POD #1?
- Atelectasis
- Management: IS (incentive spirometry), early ambulation

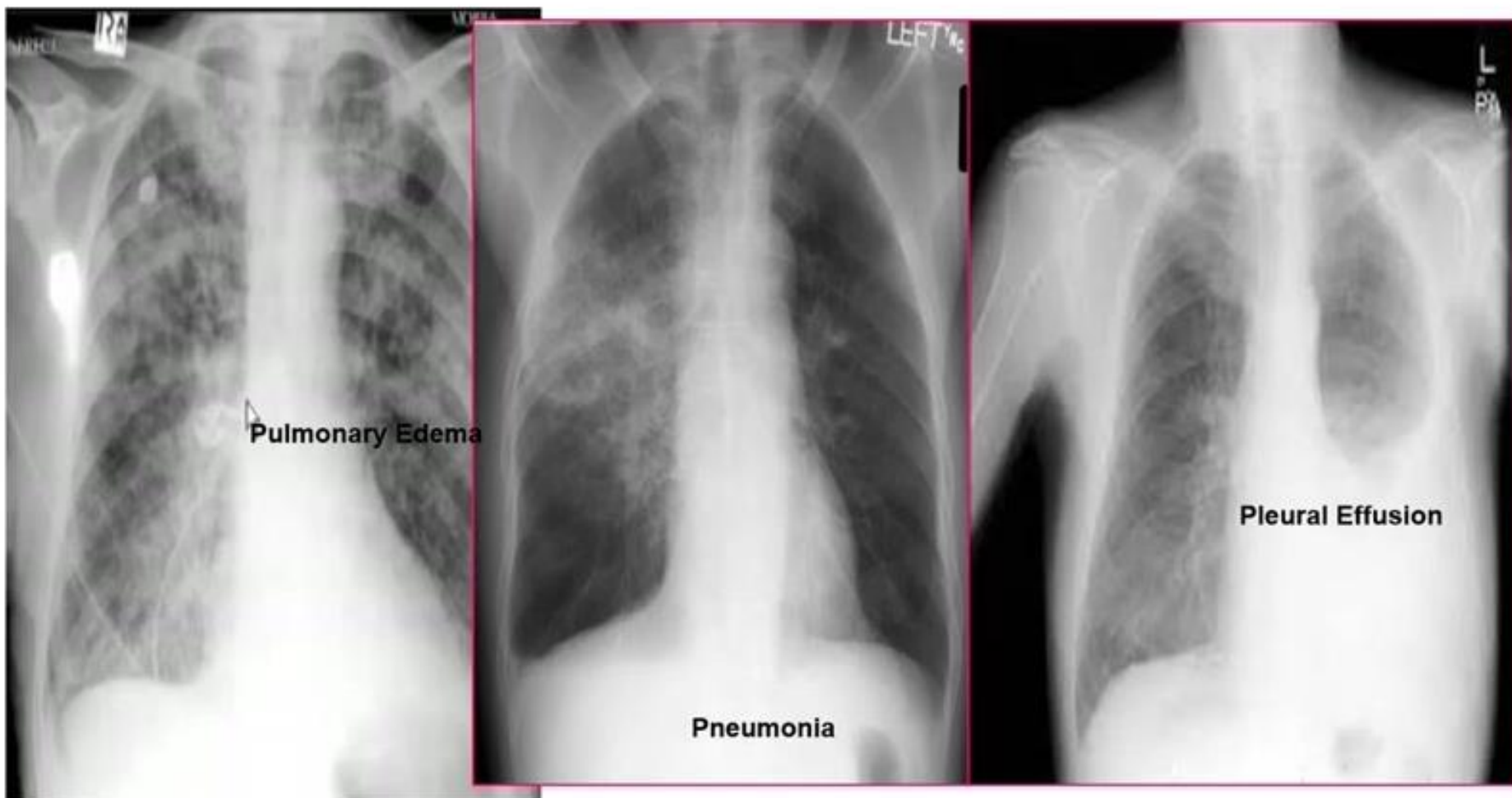
- Work-up > 48h:
 - H&P
 - Blood cultures
 - UA/urine culture
 - CXR
 - Sputum culture
 - ...then Treat the Fever

- The 6 W's
- WIND– pneumonia, atelectasis
- WOUND – infection
- WATER – UTI
- WALKING – DVT, possible PE
- WASTE – Abscess
- **What day do we expect abscesses?**
- WONDER – medications

Pulmonary complications

- Atelectasis – peripheral alveolar collapse due to shallow tidal breaths, MC cause of fever within 48h
- Aspiration pneumonitis – only requires 0.3 ml per kilogram of body weight (20 to 25 ml in adults)
- Nosocomial pneumonia
- Pulmonary edema – CHF, ARDS
- Pulmonary embolus – 1/5 are fatal
greatest management = prevention

Chest X-ray



Cardiac Complications

- Hypertension
 - Ischemia/Infarction
 - Leading cause of death in any surgical patient
 - Key to treatment = prevention
-
- Arrhythmias
 - 30 seconds of abnormal cardiac activity
 - Key to treatment = correct underlying medical condition, electrolyte replacement (Mg > 2, K > 4)

Renal Complications

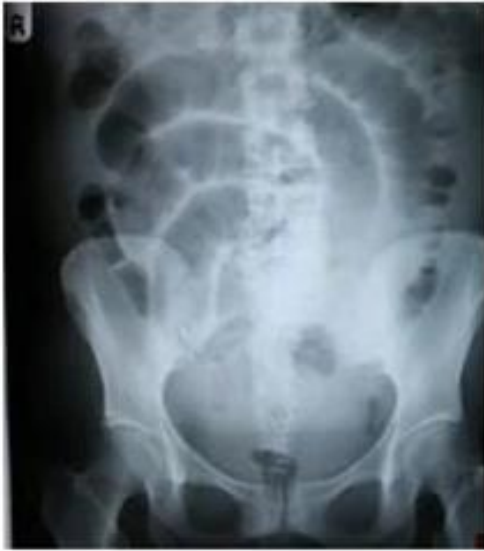- Urinary retention
- Inability to evacuate urine-filled bladder after 6 hours
- 250-300 mL urine → catheterization
- >500 mL trigger foley replacement

- Acute renal failure
- Oliguria < 0.5 cc/kg/hr
- Pre-renal (FeNa < 1)
- Intrinsic (FeNa > 1)
- Post-renal (FeNa > 1)

Gastrointestinal Complications

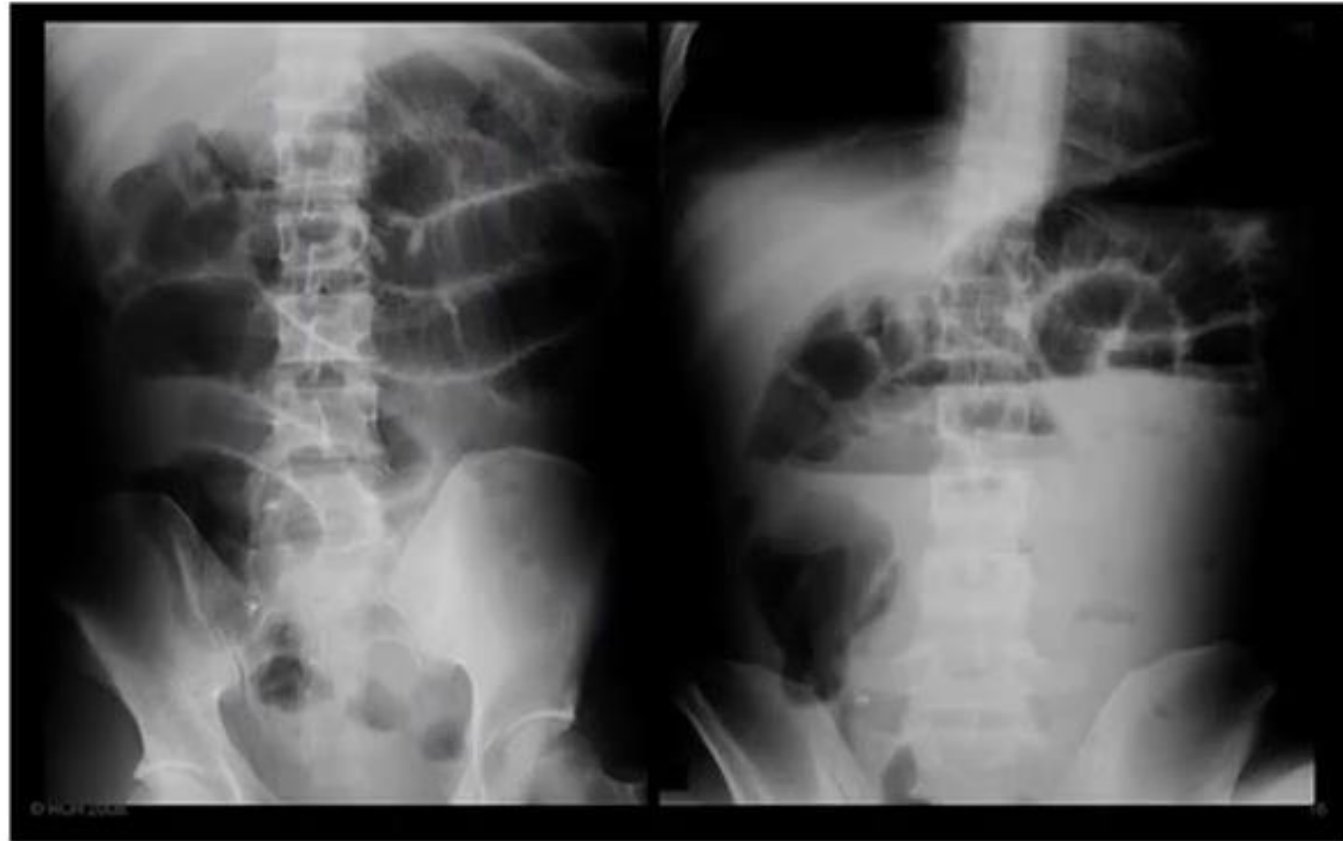
- Postoperative ileus
- GI bleeding
- Pseudomembranous colitis
- Ischemic colitis
- Anastomotic leak
- Enterocutaneous fistula

Postoperative Ileus



- Lack of function without evidence of obstruction
- Prolonged by extensive operation/manipulation, SB injury, narcotic use, abscess and pancreatitis
- Must be distinguished from SBO

Small bowel obstruction

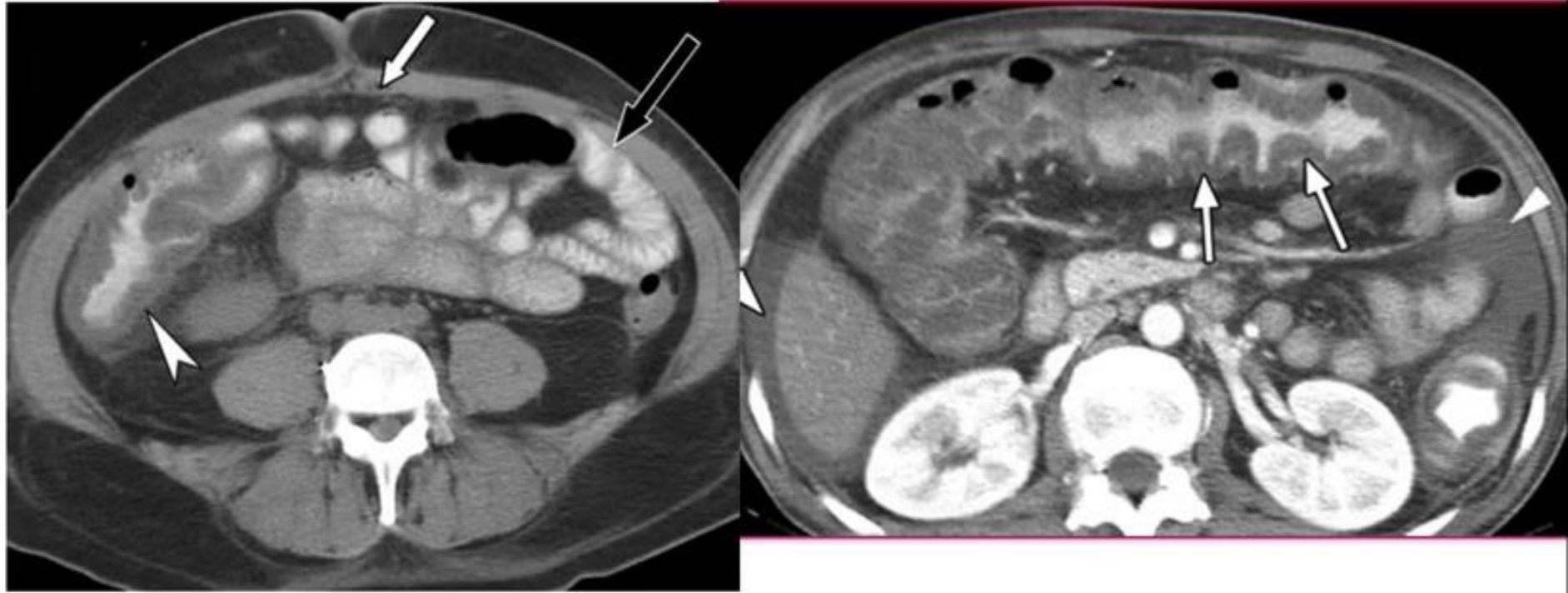


Gastrointestinal complications

- GI Bleeding
- From any source → get detailed history, place NG tube
- Etiology: Cushing's ulcer (less common with PPI use)

- Pseudomembranous colitis
- Superinfection with C difficile due to alteration in normal flora
- Toxic colitis is a surgical EMERGENCY (mortality 20-30%)

C Diff Colitis



Gastrointestinal complications

- Ischemic colitis
- Bowel affected helps determine cause
- Surgical devascularization, hypercoagulable states, hypovolemia, emboli

- Anastomotic leak
- POD# ?

- Enterocutaneous fistula
- The most complex and challenging complication

Metabolic complications

- Adrenal insufficiency
- Uncommon but potentially lethal
- Sudden cardiovascular collapse
- Presentation: hypotension, fever, confusion, abdominal pain
- Work-up: Stim test with administration of hydrocortisone (baseline cortisol at 30 minutes and 60 minutes)

- Hyper/Hypothyroidism

- SIADH
- Continue ADH secretion despite hyponatremia
- Neurosurgical procedures, trauma stroke, drugs (ACEI, NSAIDs)

Neurologic Complications

- Beware the drugs that you will be subscribing
- Delirium, dementia, psychosis
- Seizure disorders
- Stroke and TIA

Haemorrhage

Immediate:

Inadequate haemostasis , unrecognized damage to blood vessels

Early postoperative:

defective vascular anastomosis , clotting factor deficiency ,
intraoperative anticoagulants

surgical re-exploring is usually required

Secondary hemorrhage:

Related to infection which erodes blood vessel Several days
postoperative

treatment of infection