

Test Bank



Subject:

ENT miniOSCEs-018



Collected by:

Ahmad Adel

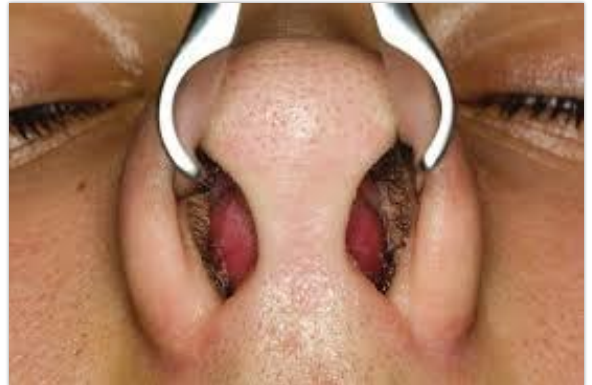Dana Alnasra



Summer semester

1st rotation

1. A patient presented with a history of facial trauma 3 days ago.

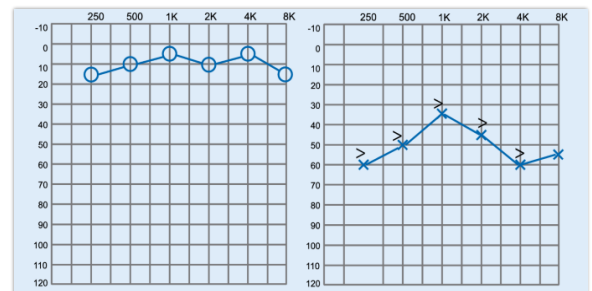


- I. *Diagnosis?*
- II. *Treatment?*
- III. *Mention 2 complications?*

○ **Answers:**

- I. *Septal hematoma.*
- II. *Incision & drainage of the blood.*
- III. *Infection with abscess formation; septal perforation.*

2. A 55-year-old man complaining of vertigo & episodes of fluctuating hearing loss.



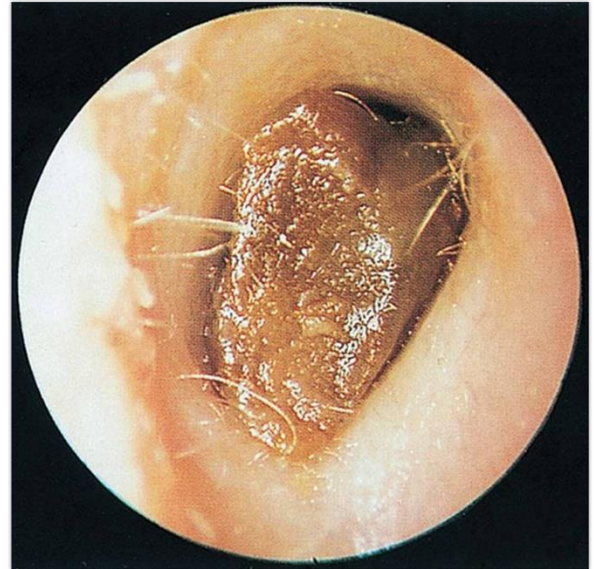
- I. *Name of this test?*
- II. *Diagnosis?*
- III. *Mention 2 treatment options?*

○ **Answers:**

- I. *Pure tone audiometry.*
- II. *Left ear Meniere's disease.*
- III. *Lifestyle modification (low salt diet, limit alcohol intake, ...); diuretics.*

3. A 20-year-old complaining of ear fullness for 2 days after swimming.

- I. *Diagnosis?*
- II. *Treatment?*

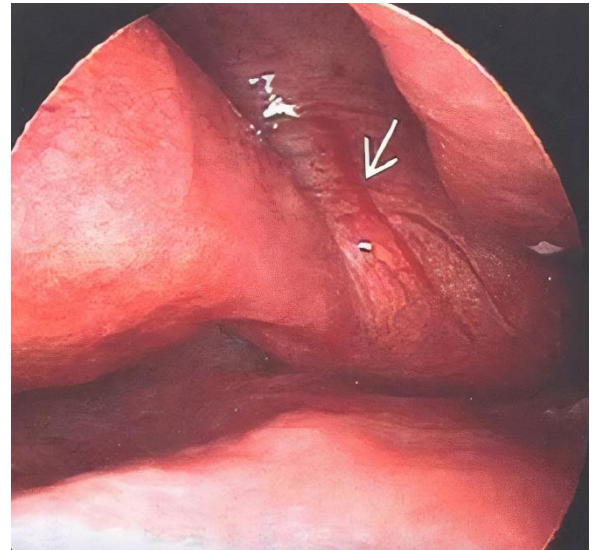


○ **Answers:**

- I. *Wax impaction.*
- II. *Suctioning of the wax.*

4. ...

- I. *Mention 3 differential diagnoses?*
- II. *How do you confirm your diagnosis?*

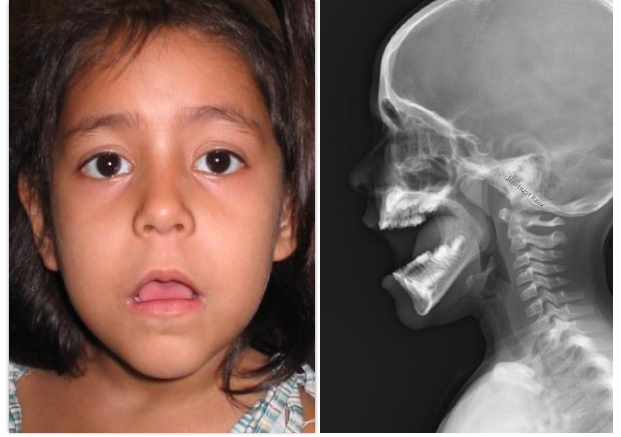

○ **Answers:**

- I. *Polyp, inverted papilloma, rhabdomyosarcoma.*
- II. *Biopsy & histopathology.*

5. A child presented with inability to breathe through her nose.

- I. *What's the name of the imaging modality?*
- II. *Diagnosis?*

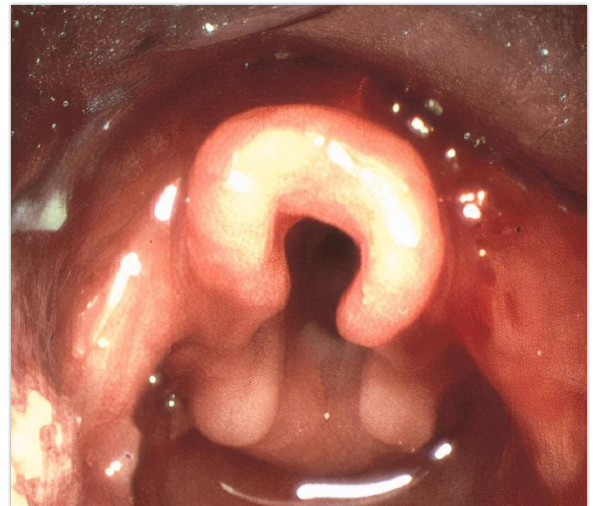


○ Answers:

- I. *Lateral paranasal sinuses X-ray.*
- II. *Adenoid hypertrophy.*

6. An infant presented with inspiratory stridor. This is his fiber-optic laryngoscopy during the inspiratory phase.

- I. *Diagnosis?*
- II. *Prognosis?*



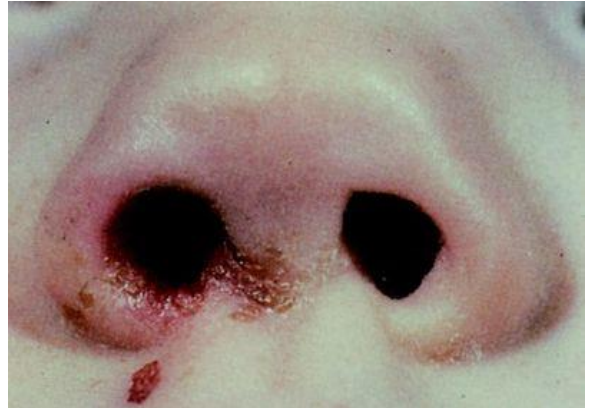○ Answers:

- I. *Laryngomalacia.*
- II. *Good prognosis (they usually resolve on their own at the age of 1 year)*

2nd rotation

1. A 27-year-old presented with a 3-month history of right nostril discharge.

- I. Diagnosis?
- II. Treatment?

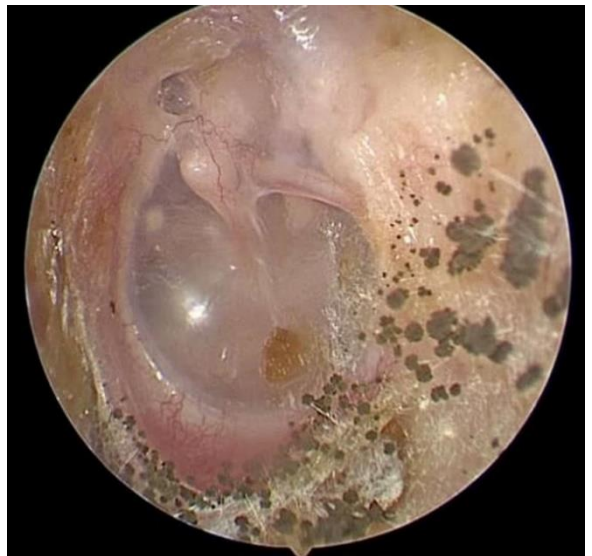

○ **Answers:**

- I. Foreign body in the nasal cavity.
- II. Removal of the foreign body.

2. A patient with a history of ear itching.

- I. Diagnosis?
- II. Organism?
- III. Treatment?



○ **Answers:**

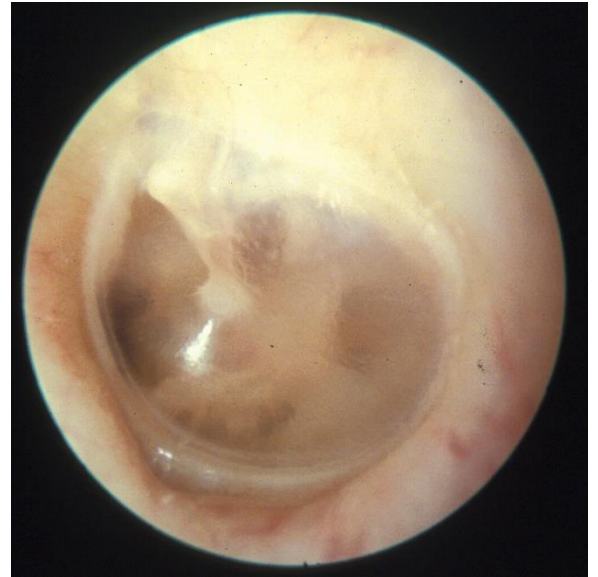
- I. Otitomycosis.
- II. Aspergillus.
- III. Aural toilet & topical antifungal.

3. A patient with decreased hearing.

- I. *Diagnosis?*
- II. *What are 2 other organs you should examine other than the ear?*

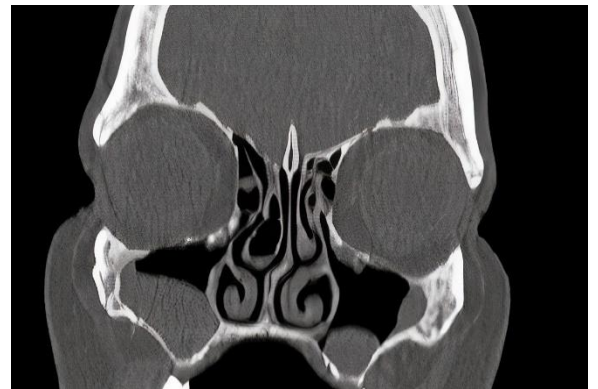
○ **Answers:**

- I. *Otitis media with effusion.*
- II. *Nose & nasopharynx.*



4. A 47-year-old boy presented with a 5-month history of fever & thick, yellow nasal discharge.

- I. *Name of the test?*
- II. *Diagnosis?*
- III. *Treatment?*



○ **Answers:**

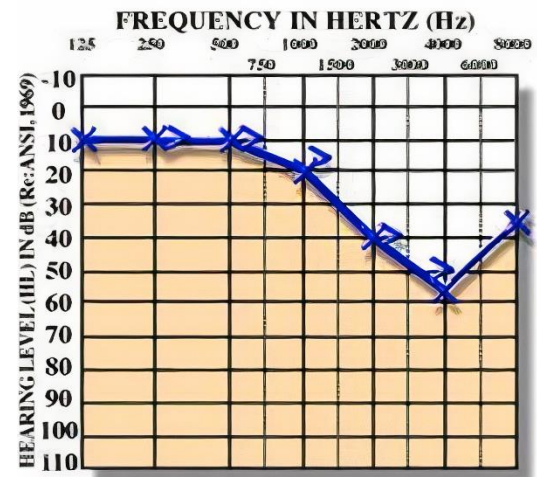
- I. *Paranasal sinuses CT scan, coronal cut.*
- II. *Chronic maxillary sinusitis & septal deviation.*
- III. *Surgery (FESS) & septoplasty.*

5. A 35-year-old complaining of decreased hearing.

- I. *Diagnosis?*
- II. *Important things to ask about in the history?*

○ **Answers:**

- I. *Noise-induced sensorineural hearing loss.*
- II. *Ask about his occupation.*

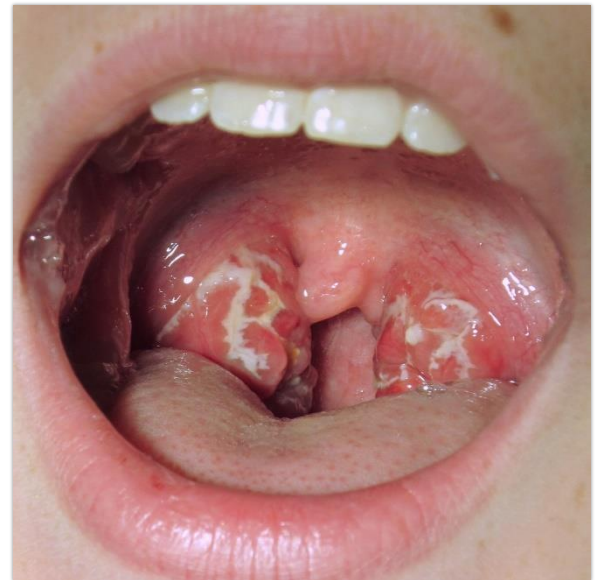

6. A 23-year-old came complaining of sore throat & odynophagia.

- I. *Diagnosis?*
- II. *After a week if there's no improvement after taking antibiotics, & there's trismus, what's the most likely diagnosis?*

○ **Answers:**

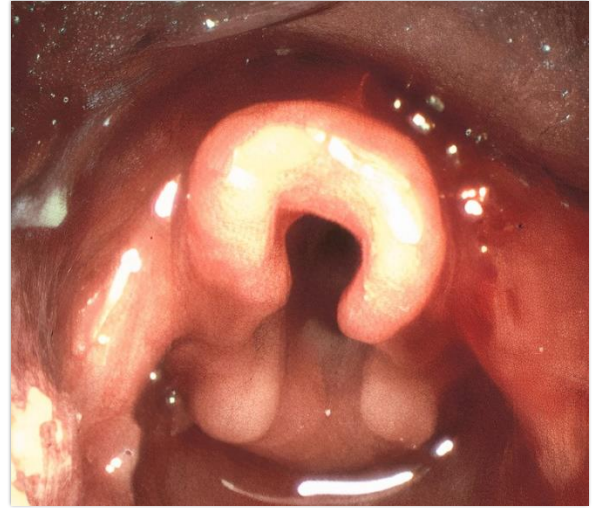
- I. *Follicular tonsillitis.*
- II. *Peri-tonsillar abscess.*



7. An infant presented with inspiratory stridor. This is his fiber-optic laryngoscopy during the inspiratory phase.

I. *Diagnosis?*

II. *Prognosis?*



○ **Answers:**

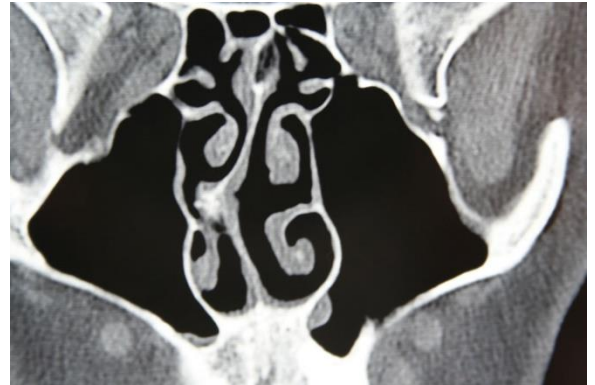
I. *Laryngomalacia.*

II. *Good prognosis (they usually resolve on their own at the age of 1 year).*

3rd rotation

1. ...

- I. *Diagnosis?*
- II. *Treatment?*

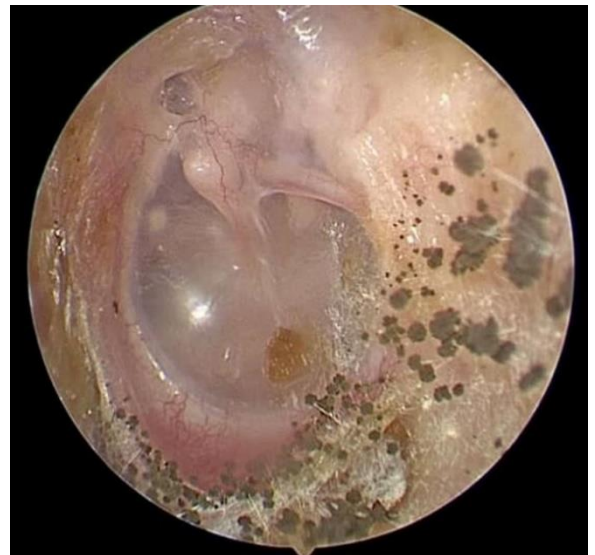

○ **Answers:**

- I. *Septal deviation.*
- II. *Septoplasty.*

2. A patient with a history of ear itching.

- I. *Diagnosis?*
- II. *Organism?*
- III. *Treatment?*
- IV. *Duration of treatment?*

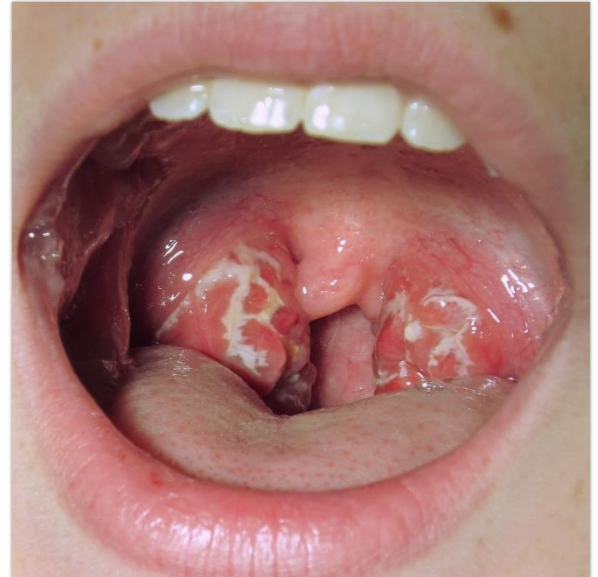

○ **Answers:**

- I. *Otomycosis.*
- II. *Aspergillus.*
- III. *Aural toilet & topical antifungal.*
- IV. *~ 14 days.*

3. A 23-year-old came complaining of sore throat & odynophagia.

- I. *Diagnosis?*
- II. *After a week if there's no improvement after taking antibiotics, & there's trismus, what's the most likely diagnosis?*

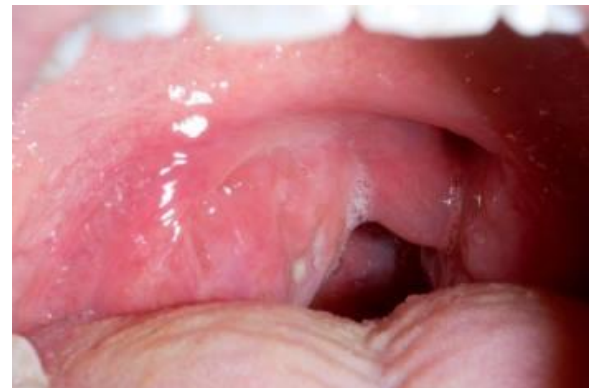

○ Answers:

- I. *Follicular tonsillitis.*
- II. *Peri-tonsillar abscess.*

4. ...

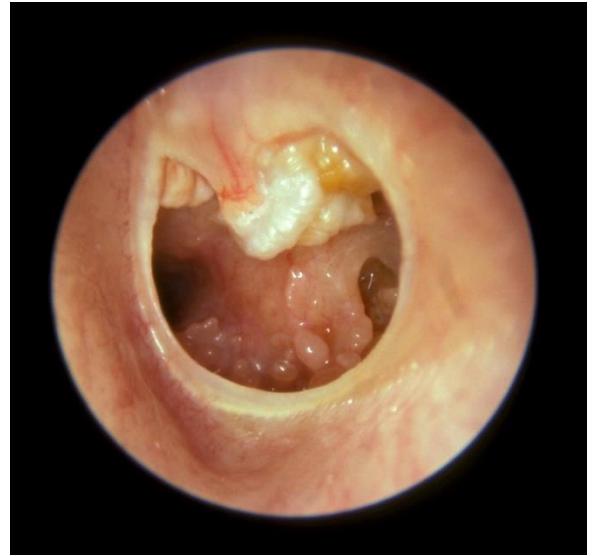- I. *Diagnosis?*
- II. *What is the most important thing to do for treatment?*
- III. *What is the most important complication?*



○ Answers:

- I. *Peritonsillar abscess.*
- II. *Drainage of the abscess.*
- III. *Blockage of the airway/sepsis.*

5. A patient presented to the clinic complaining of ear discharge that is foul smelling.

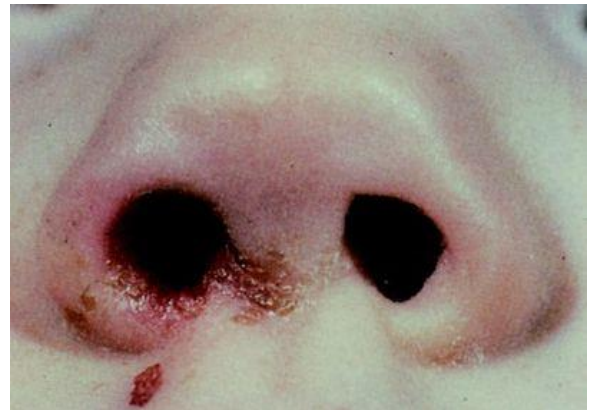

- I. *Diagnosis?*
- II. *Treatment?*
- III. *Complication?*

○ **Answers:**

- I. *Cholesteatoma.*
- II. *Surgical excision + tympanoplasty + mastoidectomy.*
- III. *Intratemporal (petrositis, facial paralysis, labyrinthitis) & intracranial (lateral sinus thrombosis, meningitis, abscess formation).*

6. A 27-year-old presented with a 3-month history of right nostril discharge.

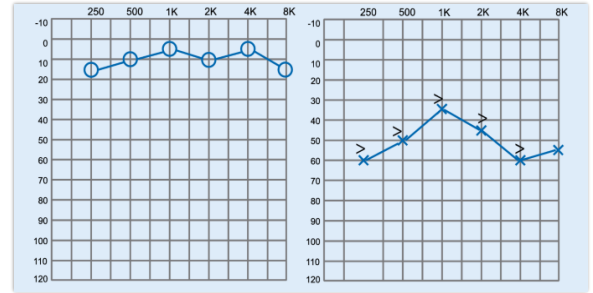


- I. *Diagnosis?*
- II. *Treatment?*

○ **Answers:**

- I. *Foreign body in the nasal cavity.*
- II. *Removal of the foreign body.*

7. A 55-year-old man complaining of vertigo & episodes of fluctuating hearing loss.



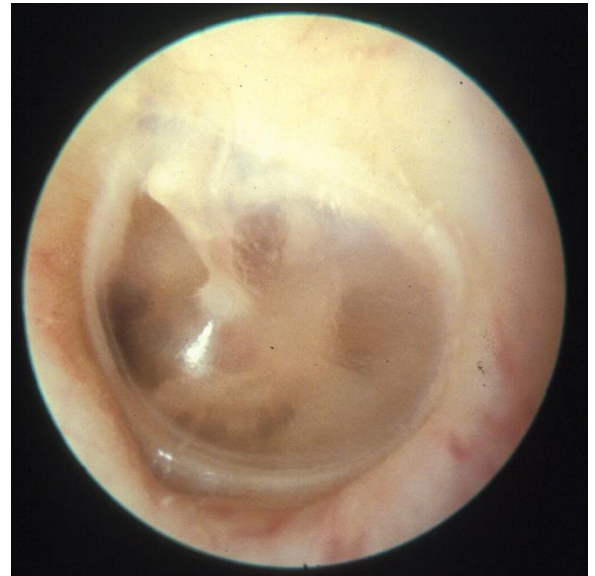
- I. Name of this test?
- II. Diagnosis?
- III. Mention 2 treatment options?

○ Answers:

- I. Pure tone audiometry.
- II. Left ear Meniere's disease.
- III. Lifestyle modification (low salt diet, limit alcohol intake, ...); diuretics.

8. A patient with decreased hearing.

- I. Diagnosis?
- II. What are 2 other organs you should examine other than the ear?



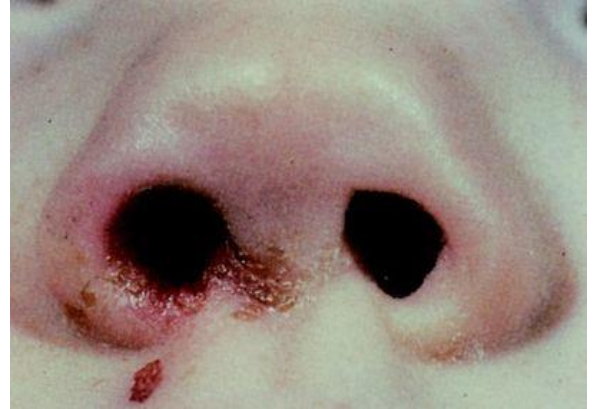○ Answers:

- I. Otitis media with effusion.
- II. Nose & nasopharynx.

4th rotation

1. A 27-year-old presented with a 3-month history of right nostril discharge.

- I. Diagnosis?
- II. Treatment?

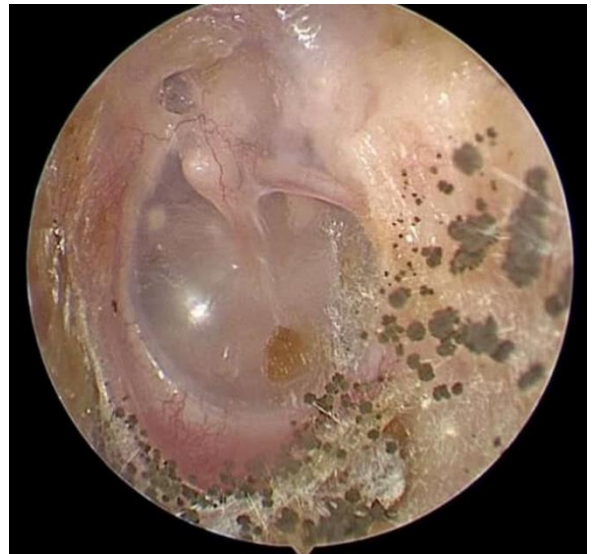

○ **Answers:**

- I. Foreign body in the nasal cavity.
- II. Removal of the foreign body.

2. A patient with a history of ear itching.

- I. Diagnosis?
- II. Organism?
- III. Treatment?

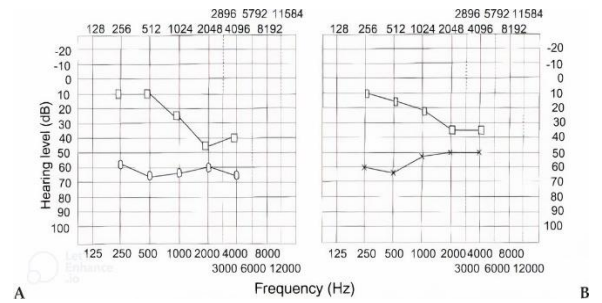


○ **Answers:**

- I. Otomycosis.
- II. Aspergillus.
- III. Aural toilet & topical antifungal.

3. ...

- I. *Diagnosis?*
- II. *What is the name of this test?*
- III. *What is the type of hearing loss?*

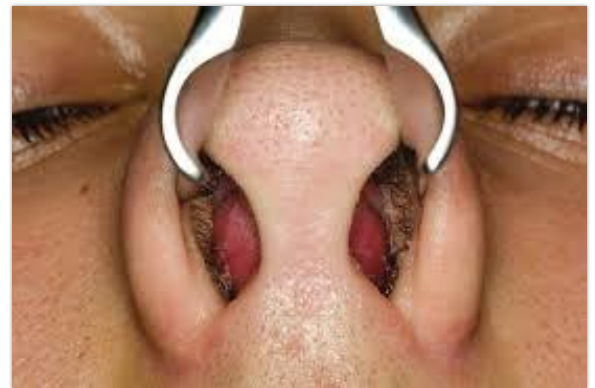

○ Answers:

- I. *Otosclerosis.*
- II. *Pure tone audiometry.*
- III. *Conductive hearing loss. As hearing loss progresses, a sensorineural component is sometimes seen, resulting in a mixed hearing loss.*

4. A patient presented with a history of facial trauma 3 days ago.

- I. *Diagnosis?*
- II. *Cause?*
- III. *How to treat saddle nose deformity?*
- IV. *Mention 2 complications?*



○ Answers:

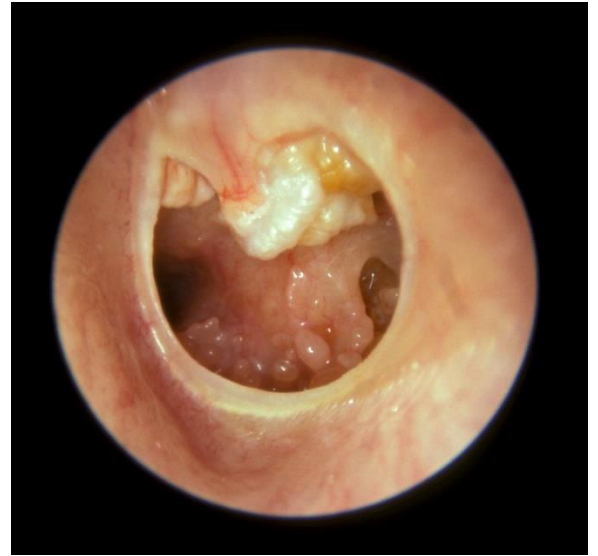- I. *Septal hematoma.*
- II. *Facial trauma.*
- III. *Rhinoplasty.*
- IV. *Infection with abscess formation; septal perforation.*

5. A patient presented to the clinic complaining of ear discharge that is foul smelling.

- I. *Diagnosis?*
- II. *Treatment?*

○ **Answers:**

- I. *Cholesteatoma.*
- II. *Surgical excision + tympanoplasty + mastoidectomy.*

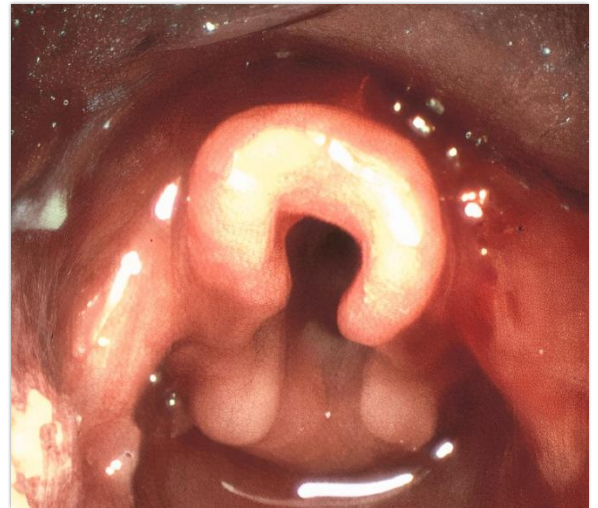


6. An infant presented with inspiratory stridor. This is his fiber-optic laryngoscopy during the inspiratory phase.

- I. *Diagnosis?*
- II. *Prognosis?*

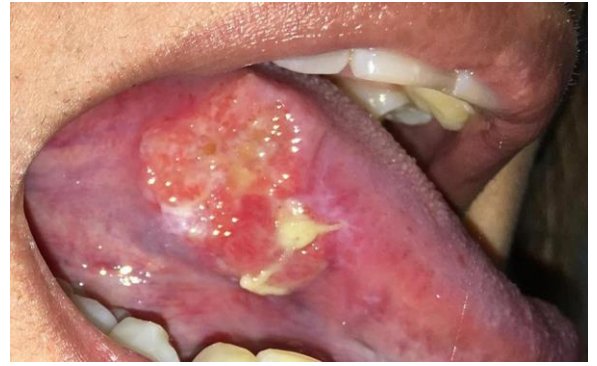○ **Answers:**

- I. *Laryngomalacia.*
- II. *Good prognosis (they usually resolve on their own at the age of 1 year).*



7. ...

- I. *Diagnosis?*
- II. *How to confirm the diagnosis?*
- III. *Treatment?*



○ **Answers:**

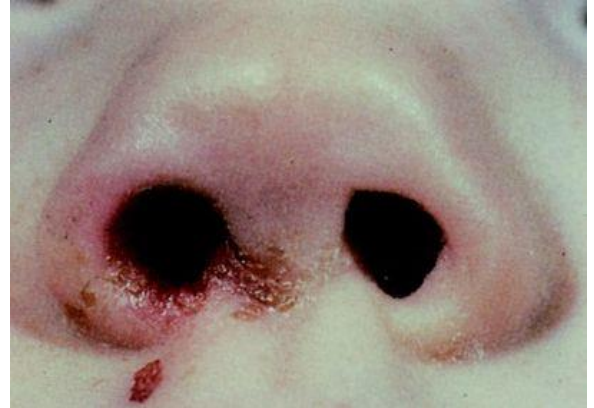- I. *Squamous cell carcinoma of the tongue.*
- II. *Biopsy.*
- III. *Excision & radiotherapy.*

First semester

1st rotation

1. A 27-year-old presented with a 3-month history of right nostril discharge.

- I. *Diagnosis?*
- II. *Treatment?*

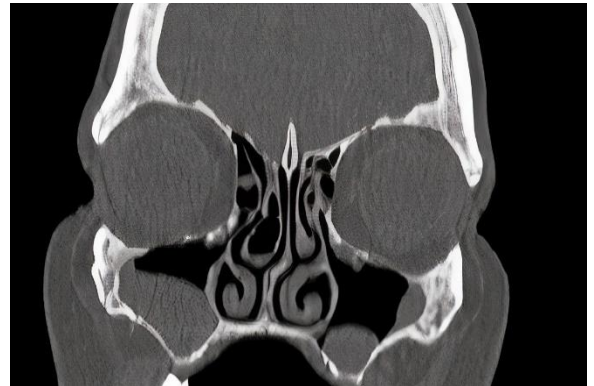


○ **Answers:**

- I. *Foreign body in the nasal cavity.*
- II. *Removal of the foreign body.*

2. A 47-year-old boy presented with a 5-month history of fever & thick, yellow nasal discharge.

- I. *Name of the test?*
- II. *Diagnosis?*
- III. *Treatment?*



○ **Answers:**

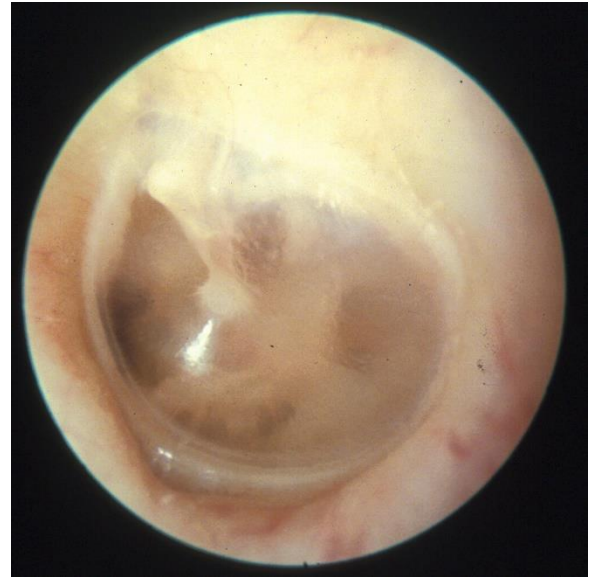
- I. *Paranasal sinuses CT scan, coronal cut.*
- II. *Chronic maxillary sinusitis & septal deviation.*
- III. *Surgery (FESS) & septoplasty.*

3. A patient with decreased hearing.

- I. *Diagnosis?*
- II. *What are 2 other organs you should examine other than the ear?*

○ **Answers:**

- I. *Otitis media with effusion.*
- II. *Nose & nasopharynx.*

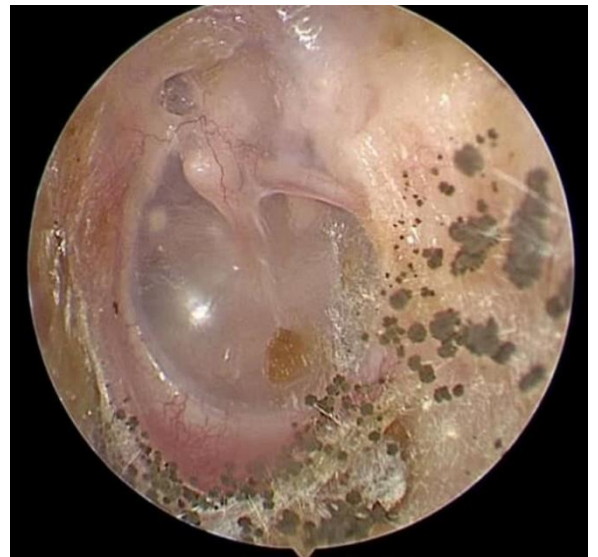

4. A patient with a history of ear itching.

- I. *Diagnosis?*
- II. *Organism?*
- III. *Treatment?*

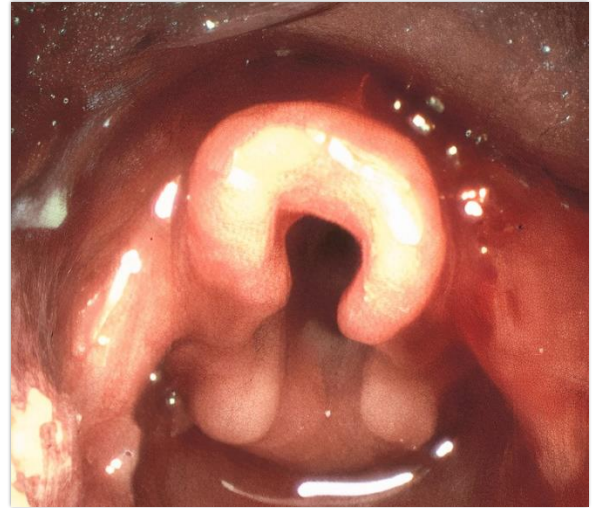
○ **Answers:**

- I. *Otomycosis.*
- II. *Aspergillus.*
- III. *Aural toilet & topical antifungal.*



5. An infant presented with inspiratory stridor. This is his fiber-optic laryngoscopy during the inspiratory phase.

- I. *Diagnosis?*
- II. *Prognosis?*

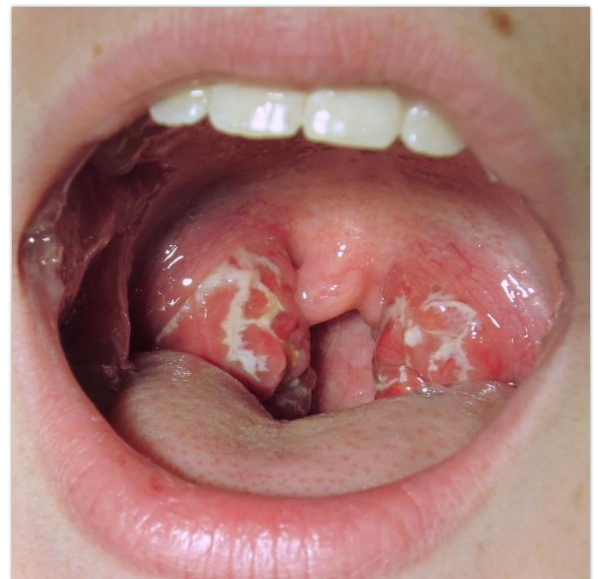

○ **Answers:**

- I. *Laryngomalacia.*
- II. *Good prognosis (they usually resolve on their own at the age of 1 year).*

6. A 23-year-old came complaining of sore throat & odynophagia.

- I. *Diagnosis?*
- II. *After a week if there's no improvement after taking antibiotics, & there's trismus, what's the most likely diagnosis?*



○ **Answers:**

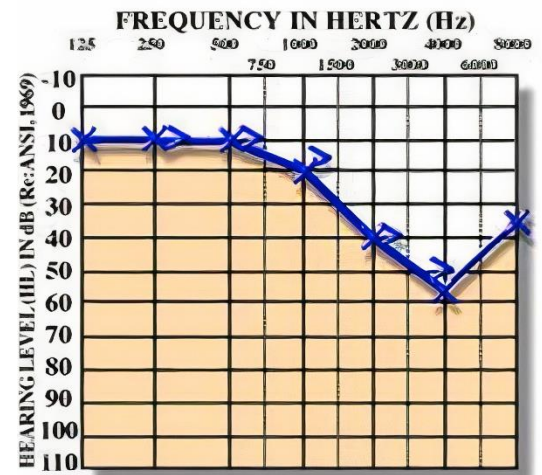
- I. *Follicular tonsillitis.*
- II. *Peri-tonsillar abscess.*

7. A 35-year-old complaining of decreased hearing.

- I. *Diagnosis?*
- II. *Important things to ask about in the history?*

○ **Answers:**

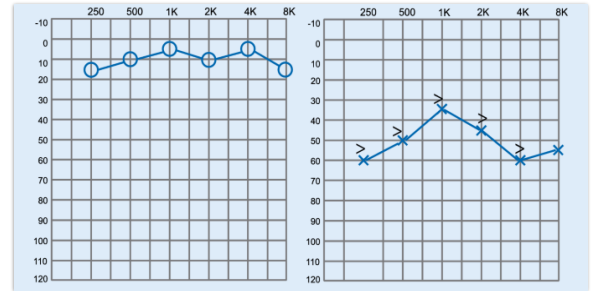
- I. *Noise-induced sensorineural hearing loss.*
- II. *Ask about his occupation.*



2nd rotation

1. A 55-year-old man complaining of vertigo & episodes of fluctuating hearing loss.

- I. Name of this test?
- II. Diagnosis?
- III. Mention 2 treatment options?

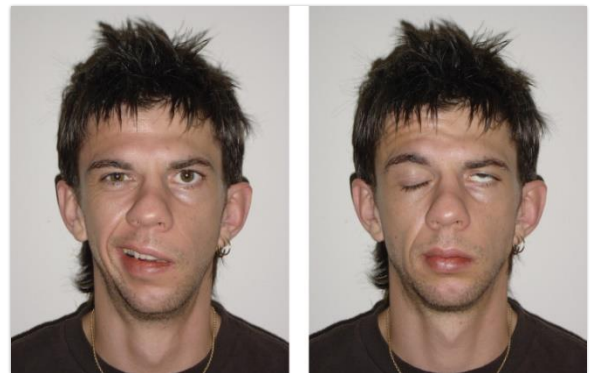

○ Answers:

- I. Pure tone audiometry.
- II. Left ear Meniere's disease.
- III. Lifestyle modification (low salt diet, limit alcohol intake, ...); diuretics.

2. ...

- I. Diagnosis?
- II. What is the best medical treatment?

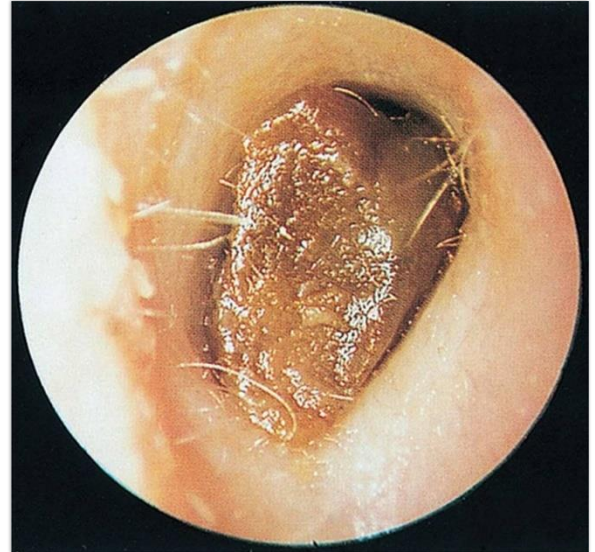


○ Answers:

- I. Left facial nerve palsy.
- II. Corticosteroids.

3. A 20-year-old complaining of ear fullness for 2 days after swimming.

- I. *Diagnosis?*
- II. *Treatment?*

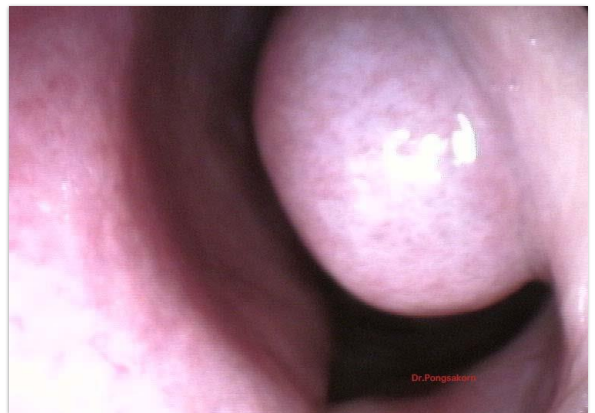

○ **Answers:**

- I. *Wax impaction.*
- II. *Suctioning of the wax.*

4. A child complaining of nasal blockage for 2 months.

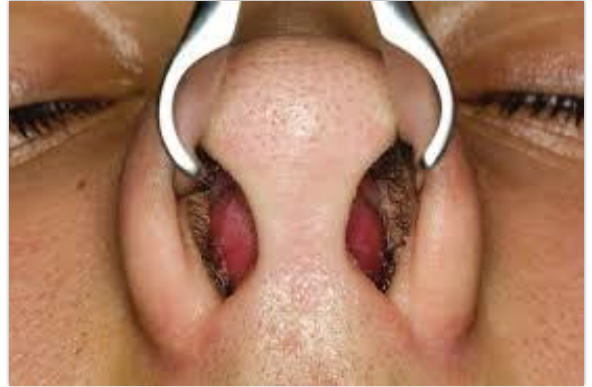- I. *Give 3 differential diagnoses?*
- II. *What is the best investigation to confirm the diagnosis?*



○ **Answers:**

- I. *Nasal polyp; allergic rhinitis; tumour.*
- II. *Biopsy & histopathology.*

5. A patient presented with a history of facial trauma 3 days ago.

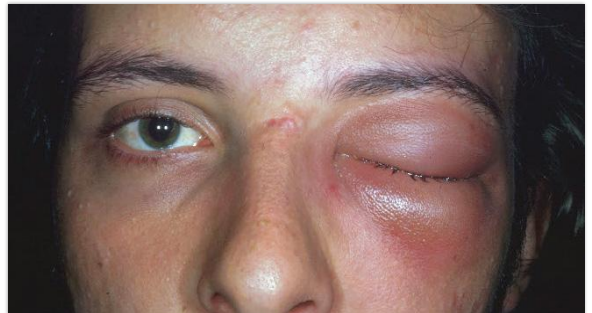

- I. *Diagnosis?*
- II. *Treatment?*
- III. *Mention 2 complications?*

○ **Answers:**

- I. *Septal hematoma.*
- II. *Incision & drainage of the blood.*
- III. *Infection with abscess formation; septal perforation.*

6. A patient with a history of an URTI presented with the following.



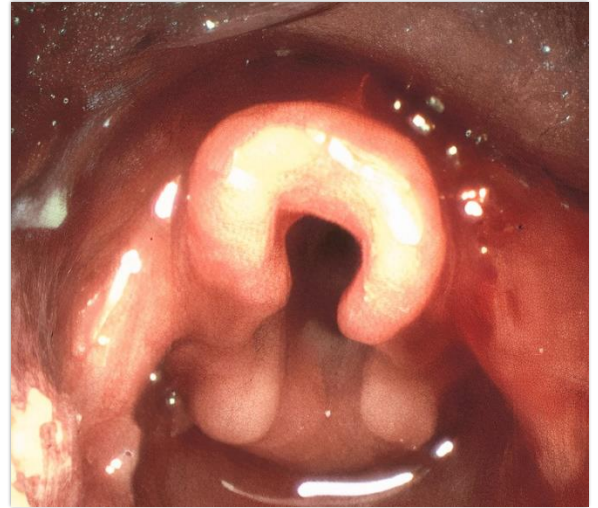
- I. *Diagnosis?*
- II. *Treatment?*

○ **Answers:**

- I. *Peri-orbital cellulitis.*
- II. *IV antibiotics (anti-streptococcus antibiotics?).*

7. An infant presented with inspiratory stridor. This is his fiber-optic laryngoscopy during the inspiratory phase.

- I. *Diagnosis?*
- II. *Prognosis?*

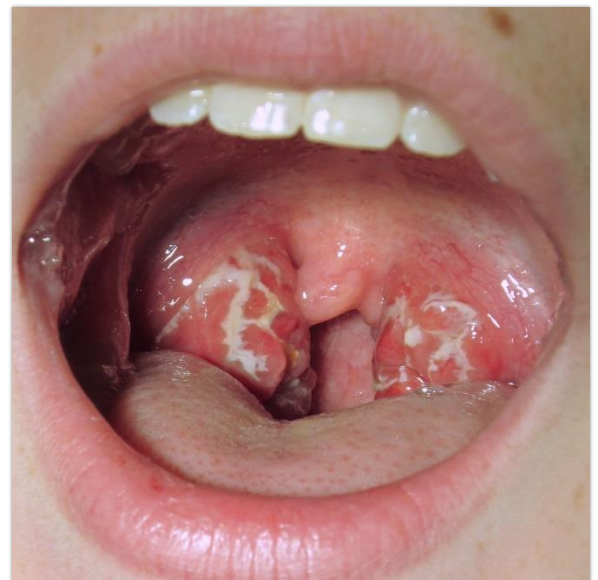

○ **Answers:**

- I. *Laryngomalacia.*
- II. *Good prognosis (they usually resolve on their own at the age of 1 year).*

8. A 23-year-old came complaining of sore throat & odynophagia.

- I. *Diagnosis?*
- II. *After a week if there's no improvement after taking antibiotics, & there's trismus, what's the most likely diagnosis?*

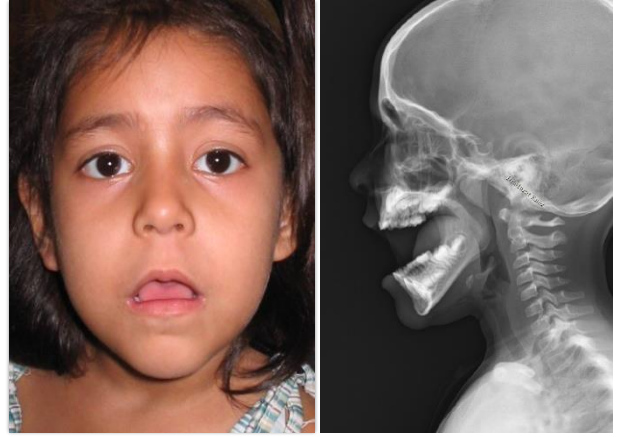

○ **Answers:**

- I. *Follicular tonsillitis.*
- II. *Peri-tonsillar abscess.*

9. A child presented with inability to breathe through her nose.

- I. *What's the name of the imaging modality?*
- II. *Diagnosis?*



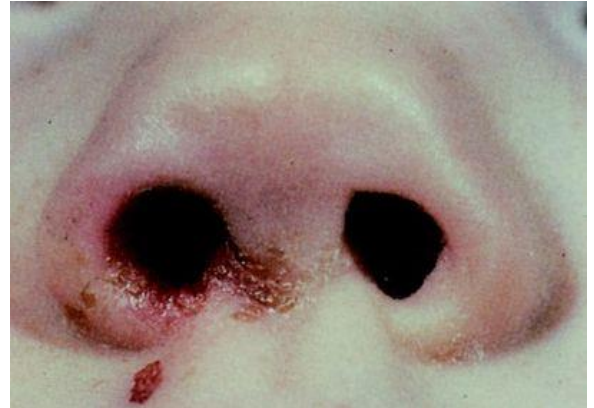○ **Answers:**

- I. *Lateral paranasal sinuses X-ray.*
- II. *Adenoid hypertrophy.*

3rd rotation

1. A 27-year-old presented with a 3-month history of right nostril discharge.

- I. *Diagnosis?*
- II. *Treatment?*

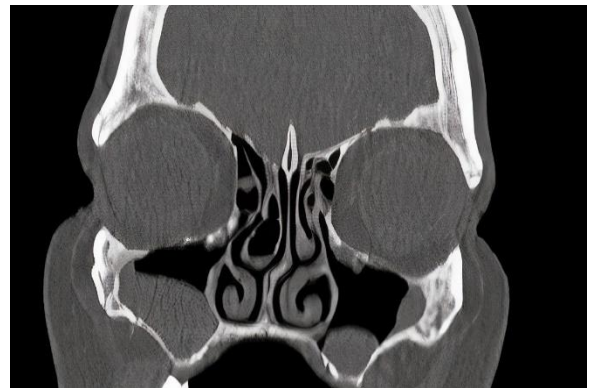

○ **Answers:**

- I. *Foreign body in the nasal cavity.*
- II. *Removal of the foreign body.*

2. A 47-year-old boy presented with a 5-month history of fever & thick, yellow nasal discharge.

- I. *Name of the test?*
- II. *Diagnosis?*
- III. *Treatment?*



○ **Answers:**

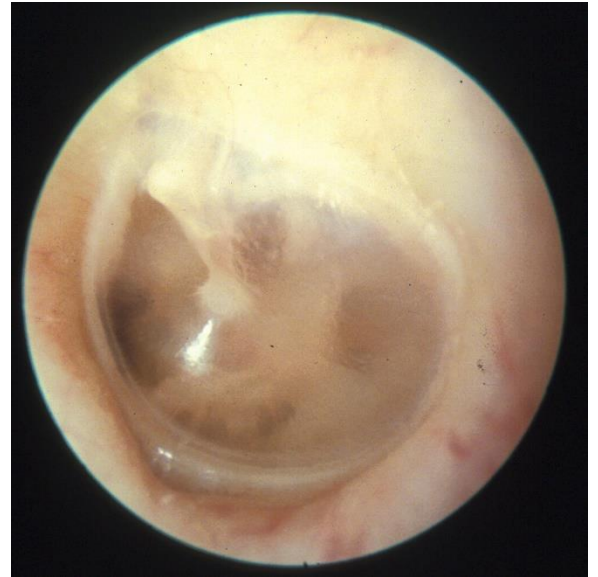
- I. *Paranasal sinuses CT scan, coronal cut.*
- II. *Chronic maxillary sinusitis & septal deviation.*
- III. *Surgery (FESS) & septoplasty.*

3. A patient with decreased hearing.

- I. *Diagnosis?*
- II. *What are 2 other organs you should examine other than the ear?*

○ **Answers:**

- I. *Otitis media with effusion.*
- II. *Nose & nasopharynx.*



4. A patient with a history of ear itching.

- I. *Diagnosis?*
- II. *Organism?*
- III. *Treatment?*

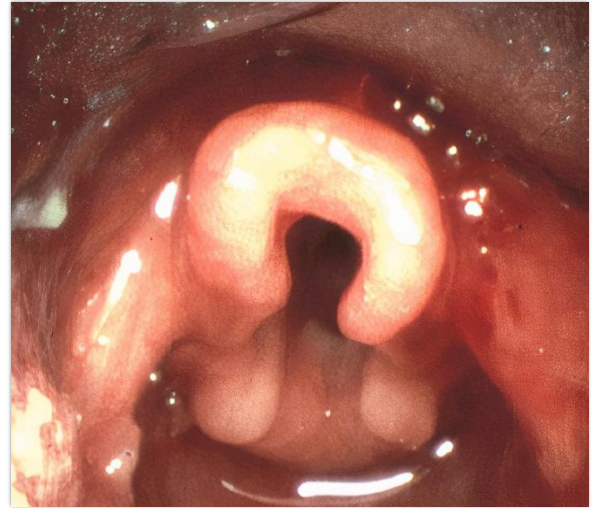
○ **Answers:**

- I. *Otomycosis.*
- II. *Aspergillus.*
- III. *Aural toilet & topical antifungal.*



5. An infant presented with inspiratory stridor. This is his fiber-optic laryngoscopy during the inspiratory phase.

- I. *Diagnosis?*
- II. *Prognosis?*

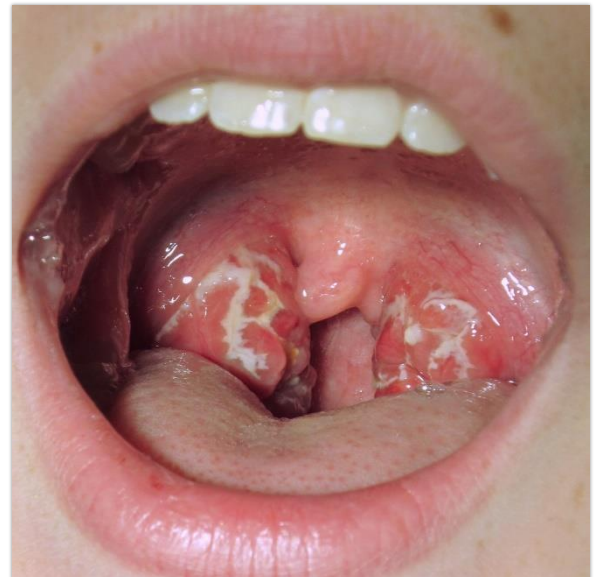

○ **Answers:**

- I. *Laryngomalacia.*
- II. *Good prognosis (they usually resolve on their own at the age of 1 year).*

6. A 23-year-old came complaining of sore throat & odynophagia.

- I. *Diagnosis?*
- II. *After a week if there's no improvement after taking antibiotics, & there's trismus, what's the most likely diagnosis?*



○ **Answers:**

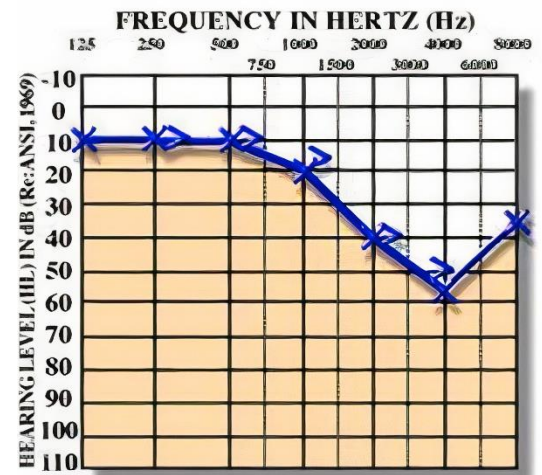
- I. *Follicular tonsillitis.*
- II. *Peri-tonsillar abscess.*

7. A 35-year-old complaining of decreased hearing.

- I. *Diagnosis?*
- II. *Important things to ask about in the history?*

○ **Answers:**

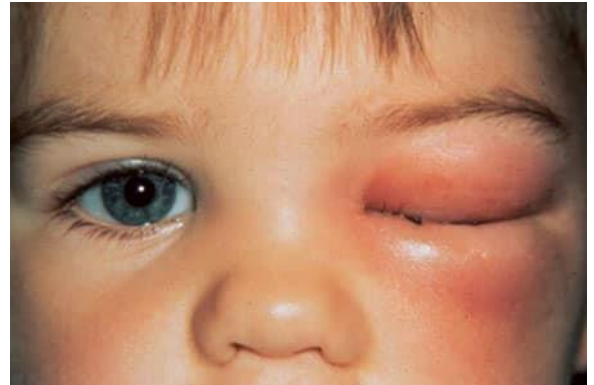- I. *Noise-induced sensorineural hearing loss.*
- II. *Ask about his occupation.*



4th rotation

1. A patient with a history of an URTI presented with the following.

- I. *Diagnosis?*
- II. *Treatment?*

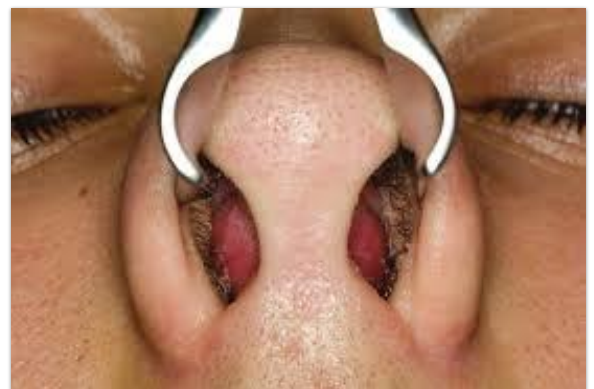

○ **Answers:**

- I. *Peri-orbital cellulitis.*
- II. *IV antibiotics.*

2. A patient presented with a history of facial trauma 3 days ago.

- I. *Diagnosis?*
- II. *Cause?*
- III. *How to treat saddle nose deformity?*
- IV. *Mention 2 complications?*

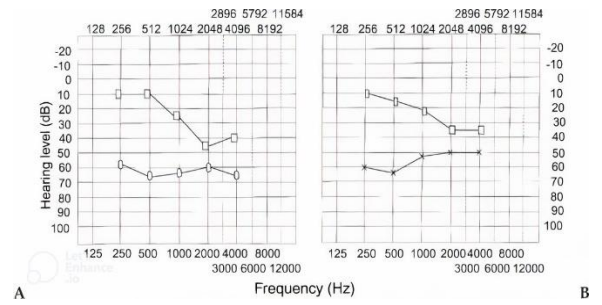


○ **Answers:**

- I. *Septal hematoma.*
- II. *Facial trauma.*
- III. *Rhinoplasty.*
- IV. *Infection with abscess formation; septal perforation.*

3. ...

- I. *Diagnosis?*
- II. *What is the name of this test?*
- III. *What is the type of hearing loss?*



○ Answers:

- I. *Otosclerosis.*
- II. *Pure tone audiometry.*
- III. *Conductive hearing loss. As hearing loss progresses, a sensorineural component is sometimes seen, resulting in a mixed hearing loss.*

4. ...

- I. *Name of the procedure?*
- II. *Name one indication?*
- III. *Name one contraindication?*

○ Answers:

- I. *Syringing.*
- II. *Wax removal.*
- III. *Tympanic membrane perforation.*

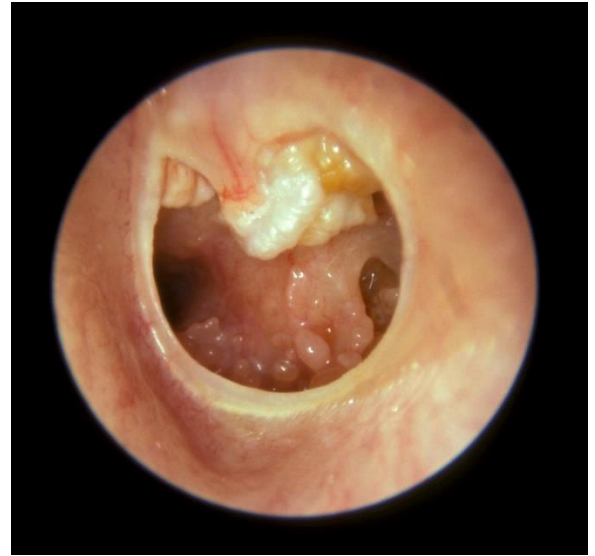

5. A patient presented to the clinic complaining of ear discharge that is foul smelling.

- I. *Diagnosis?*
- II. *Treatment?*

○ **Answers:**

- I. *Cholesteatoma.*
- II. *Surgical excision + tympanoplasty + mastoidectomy.*

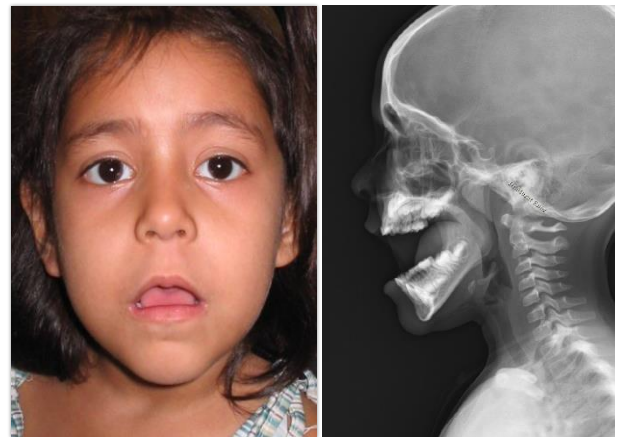

6. A child presented with inability to breathe through her nose.

- I. *What's the name of the imaging modality?*
- II. *Diagnosis?*

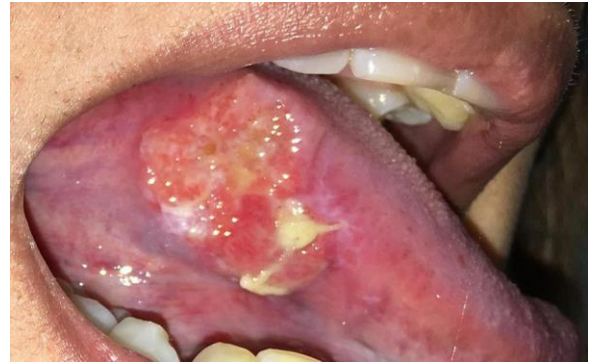○ **Answers:**

- I. *Lateral paranasal sinuses X-ray.*
- II. *Adenoid hypertrophy.*



7. ...

- I. *Diagnosis?*
- II. *How to confirm the diagnosis?*
- III. *Treatment?*



○ **Answers:**

- I. *Squamous cell carcinoma of the tongue.*
- II. *Biopsy.*
- III. *Excision & radiotherapy.*

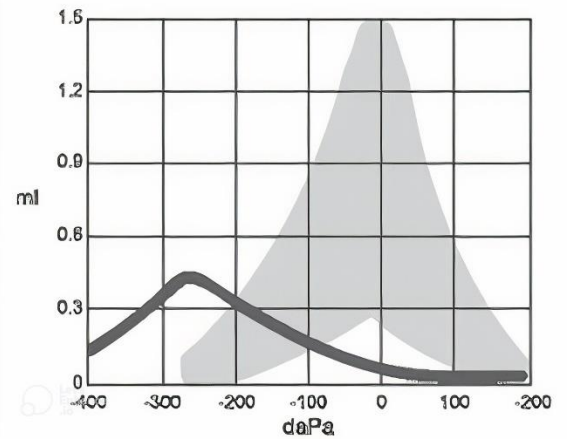
5th rotation

1. ...

- I. What does this measure?
- II. What is the pathology in this graph?
- III. What is the most common cause of this pathology?

○ Answers:

- I. Compliance of the tympanic membrane.
- II. Eustachian tube dysfunction.
- III. Adenoid hypertrophy.

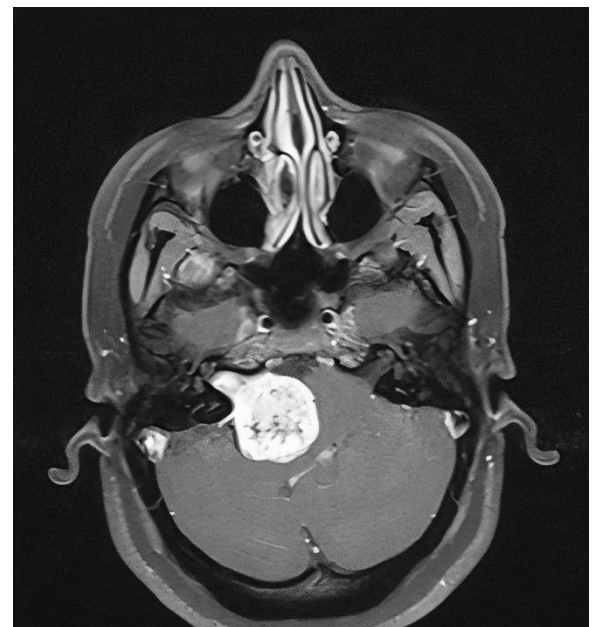

2. ...

- I. What's the name of the imaging modality?
- II. Diagnosis?
- III. Treatment?

○ Answers:

- I. Brain MRI, coronal cut.
- II. Acoustic neuroma.
- III. Surgical excision & radiotherapy.

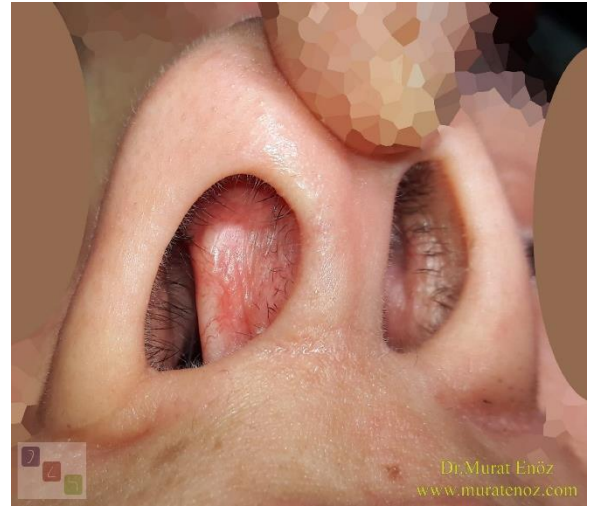

3. ...

- I. *Diagnosis?*
- II. *Treatment?*

○ **Answers:**

- I. *Septal deviation.*
- II. *Septoplasty.*

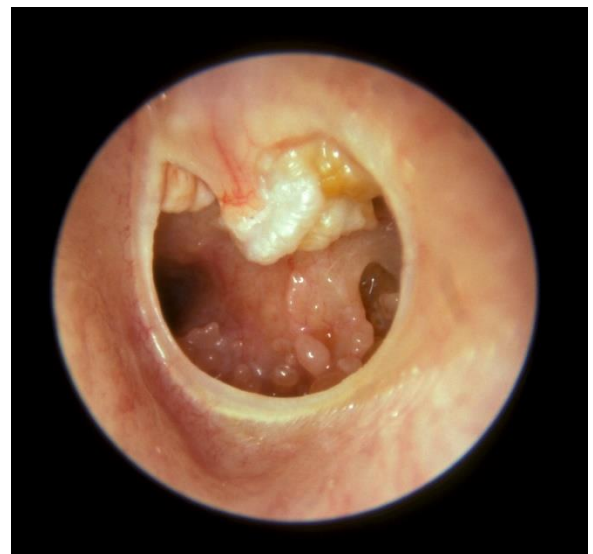

4. A patient presented to the clinic complaining of ear discharge that is foul smelling.

- I. *Diagnosis?*
- II. *Treatment?*

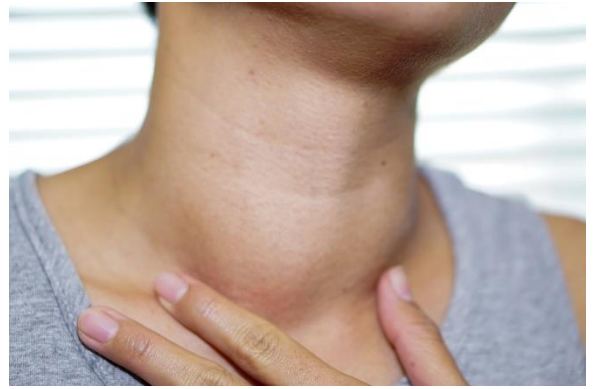○ **Answers:**

- I. *Cholesteatoma.*
- II. *Surgical excision + tympanoplasty + mastoidectomy.*



5. ...

- I. What are 3 structures of head & neck that could be affected?
- II. First step in diagnosis?

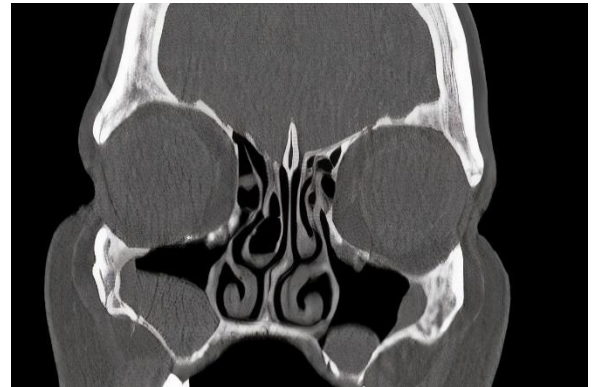

○ Answers:

- I. Nasopharynx; thyroid; nose.
- II. Ultrasound then FNA.

6. A 47-year-old boy presented with a 5-month history of fever & thick, yellow nasal discharge.

- I. Name of the test?
- II. Diagnosis?
- III. Treatment?



○ Answers:

- I. Paranasal sinuses CT scan, coronal cut.
- II. Chronic maxillary sinusitis & septal deviation.
- III. Surgery (FESS) & septoplasty.

7. ...

- I. *Diagnosis?*
- II. *How to confirm the diagnosis?*
- III. *Treatment?*



○ **Answers:**

- I. *Squamous cell carcinoma of the tongue.*
- II. *Biopsy.*
- III. *Excision & radiotherapy.*

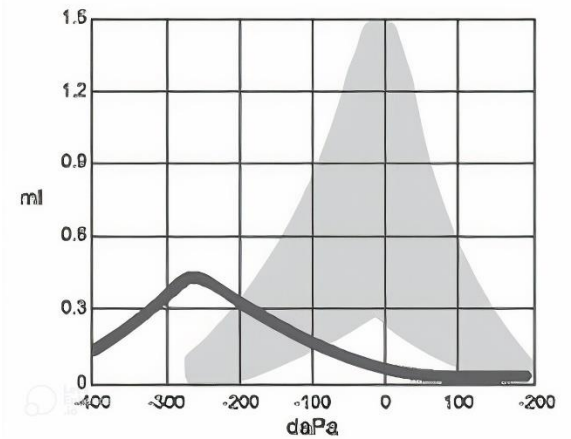
6th rotation

1. ...

- I. What is the name of this test?
- II. What does it measure?
- III. What is the pathology in this graph?

○ Answers:

- I. Tympanometry.
- II. Compliance of the tympanic membrane.
- III. Eustachian tube dysfunction.

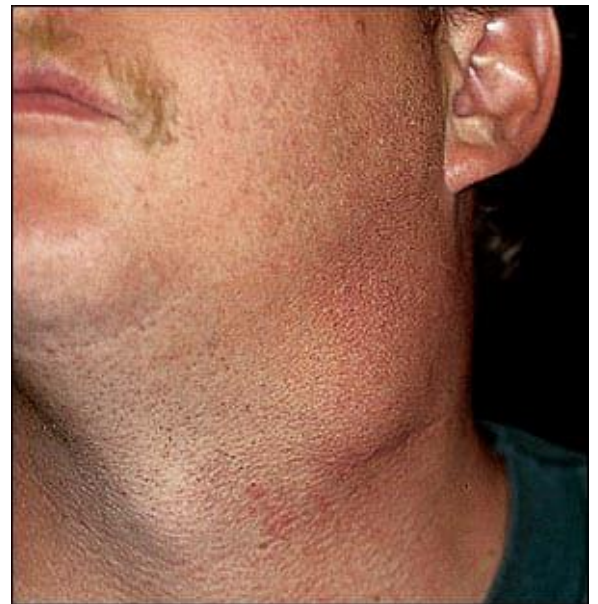

2. ...

- I. What is the best first investigation?
- II. What is the best next step for investigation?

○ Answers:

- I. Ultrasonography.
- II. FNA & biopsy.

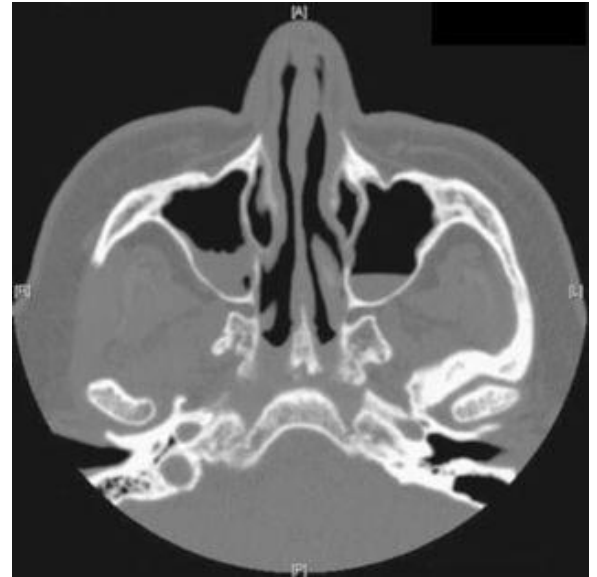

3. A 47-year-old boy presented with a 5-month history of fever & thick, yellow nasal discharge.

- I. *Name of the test?*
- II. *Diagnosis?*
- III. *Treatment?*

○ **Answers:**

- I. *Paranasal sinuses CT scan, axial cut.*
- II. *Bilateral acute maxillary sinusitis & septal deviation.*
- III. *Antibiotic & septoplasty.*

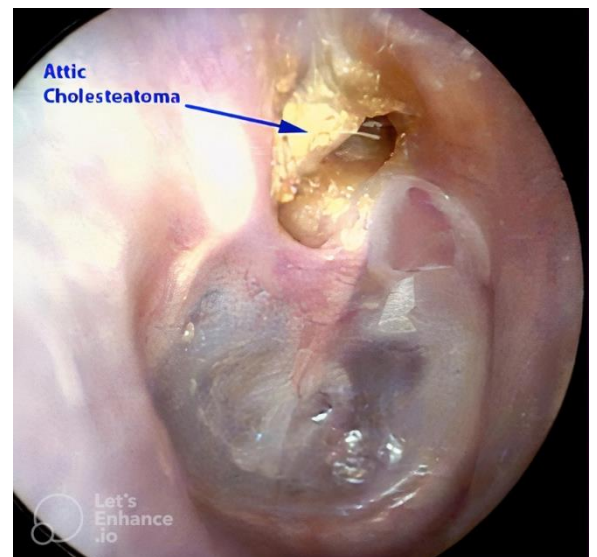


4. A patient presented to the clinic complaining of ear discharge that is foul smelling.

- I. *Diagnosis?*
- II. *Treatment?*
- III. *Which ear is the affected in this picture?*

○ **Answers:**

- I. *Cholesteatoma.*
- II. *Surgical excision + tympanoplasty + mastoidectomy.*
- III. *Right ear.*

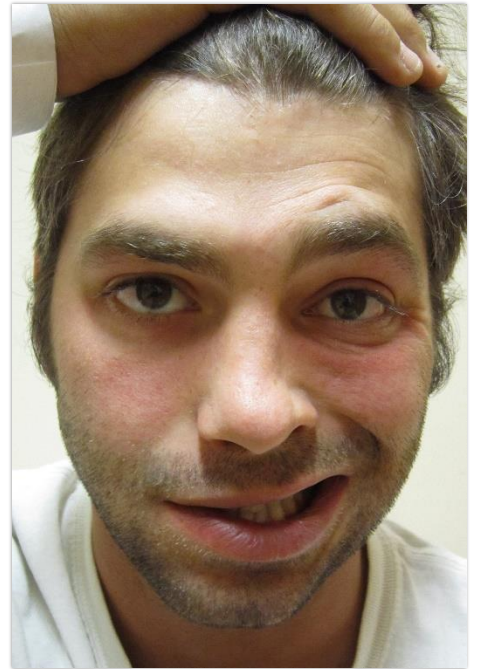


5. ...

- I. *Diagnosis?*
- II. *What is the best medical treatment?*

○ **Answers:**

- I. *Right facial nerve palsy.*
- II. *Corticosteroids.*

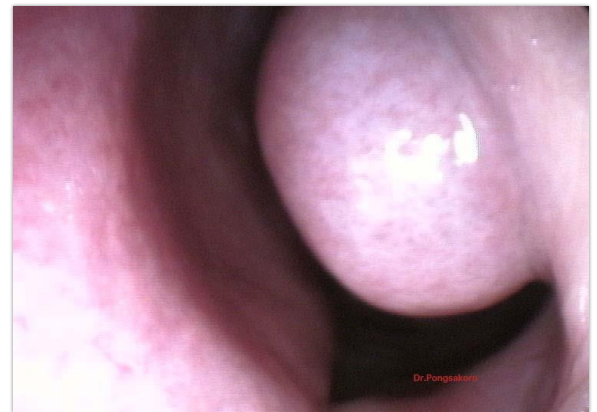

6. A patient with bilateral nasal blockage.

- I. *Diagnosis?*
- II. *Treatment?*
- III. *Which side is affected in this picture?*

○ **Answers:**

- I. *Bilateral nasal polyps.*
- II. *Corticosteroids & surgical excision.*
- III. *Right side.*



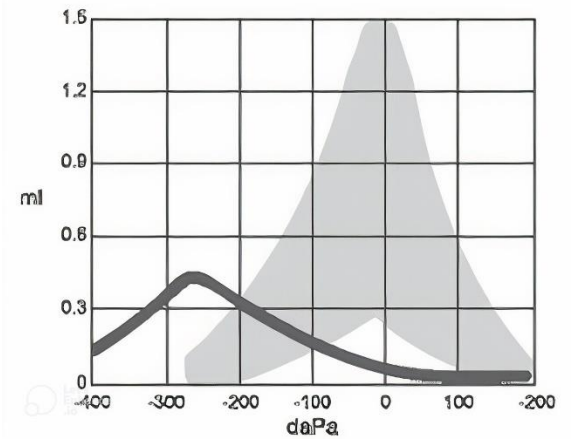
7th rotation

1. ...

- I. What is the name of this test?
- II. What does it measure?
- III. What is the pathology in this graph?

○ Answers:

- I. Tympanometry.
- II. Compliance of the tympanic membrane.
- III. Eustachian tube dysfunction.

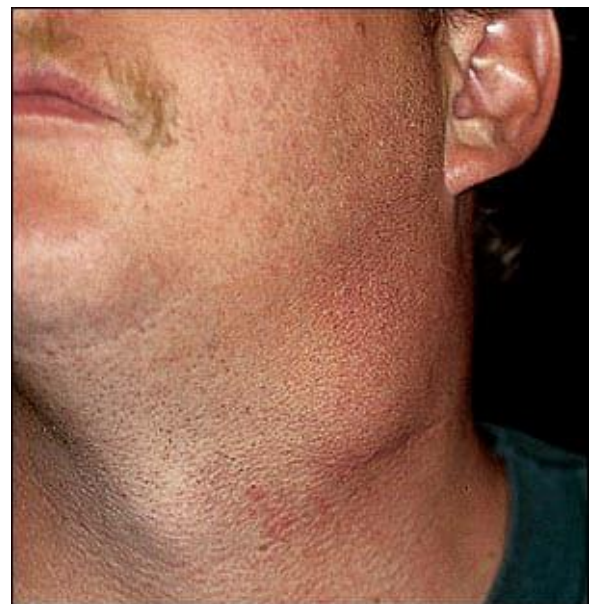


2. ...

- I. What is the best first investigation?
- II. What is the best next step for investigation?

○ Answers:

- I. Ultrasonography.
- II. FNA & biopsy.



3. A 47-year-old boy presented with a 5-month history of fever & thick, yellow nasal discharge.

- I. Name of the test?
- II. Diagnosis?
- III. Treatment?

○ **Answers:**

- I. Paranasal sinuses CT scan, axial cut.
- II. Bilateral acute maxillary sinusitis & septal deviation.
- III. Antibiotic & septoplasty.

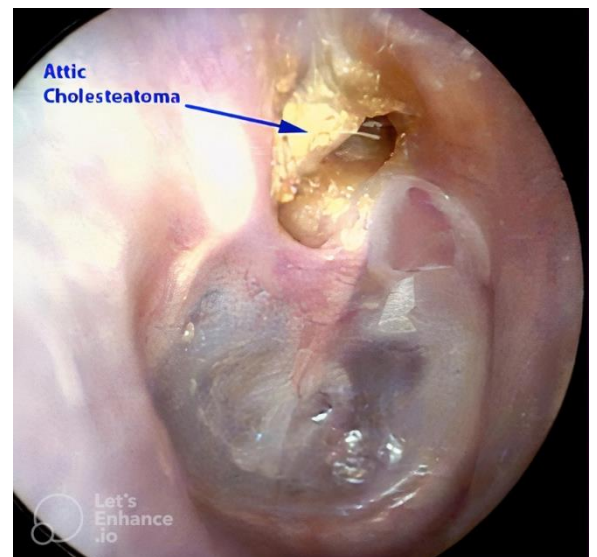


4. A patient presented to the clinic complaining of ear discharge that is foul smelling.

- I. Diagnosis?
- II. Treatment?
- III. Which ear is the affected in this picture?

○ **Answers:**

- I. Cholesteatoma.
- II. Surgical excision + tympanoplasty + mastoidectomy.
- III. Right ear.

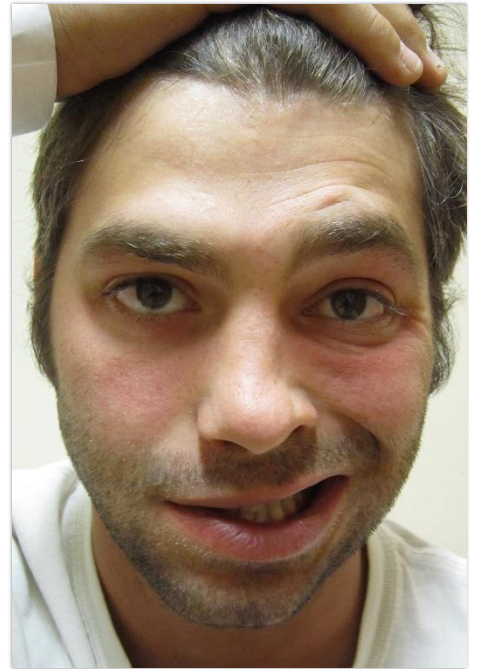


5. ...

- I. *Diagnosis?*
- II. *What is the best medical treatment?*

○ **Answers:**

- I. *Right facial nerve palsy.*
- II. *Corticosteroids.*



6. A patient with bilateral nasal blockage.

- I. *Diagnosis?*
- II. *Treatment?*
- III. *Which side is affected in this picture?*



○ **Answers:**

- I. *Bilateral nasal polyps.*
- II. *Corticosteroids & surgical excision.*
- III. *Right side.*

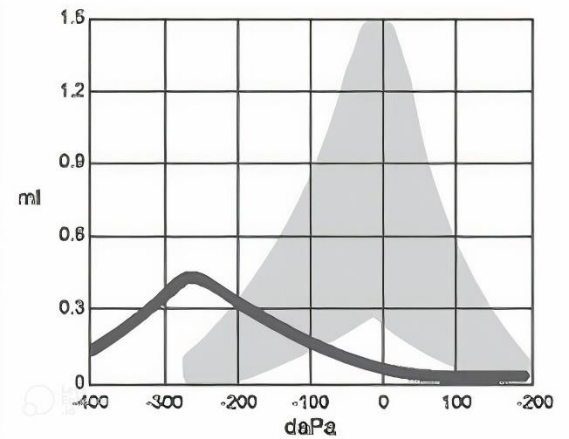
8th rotation

1. ...

- I. What is the name of this test?
- II. What does it measure?
- III. What is the pathology in this graph?

○ Answers:

- I. Tympanometry.
- II. Compliance of the tympanic membrane.
- III. Eustachian tube dysfunction.

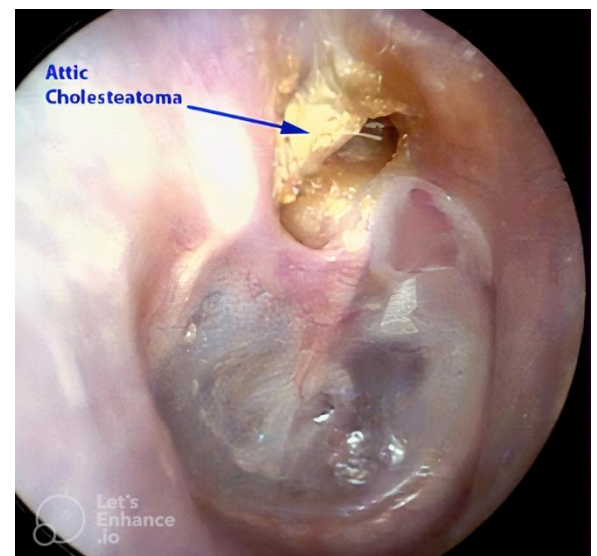


2. A patient presented to the clinic complaining of ear discharge that is foul smelling.

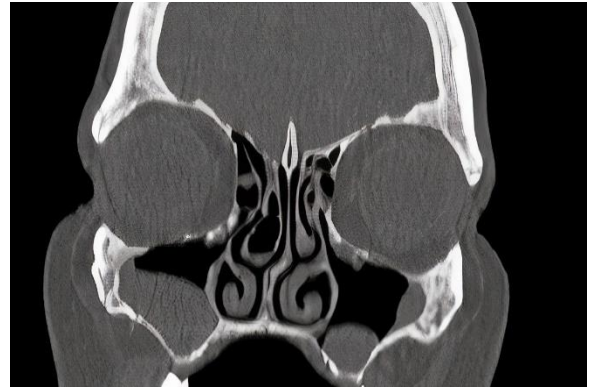
- I. Diagnosis?
- II. Treatment?
- III. Which ear is the affected in this picture?

○ Answers:

- I. Cholesteatoma.
- II. Surgical excision + tympanoplasty + mastoidectomy.
- III. Right ear.



3. A 47-year-old boy presented with a 5-month history of fever & thick, yellow nasal discharge.

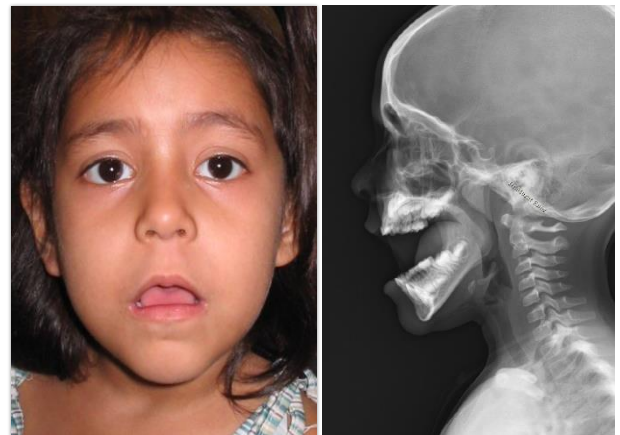

- I. *Name of the test?*
- II. *Diagnosis?*
- III. *Treatment?*

○ **Answers:**

- I. *Paranasal sinuses CT scan, coronal cut.*
- II. *Chronic maxillary sinusitis & septal deviation.*
- III. *Surgery (FESS) & septoplasty.*

4. A child presented with inability to breathe through her nose.



- I. *What's the name of the imaging modality?*
- II. *Diagnosis?*

○ **Answers:**

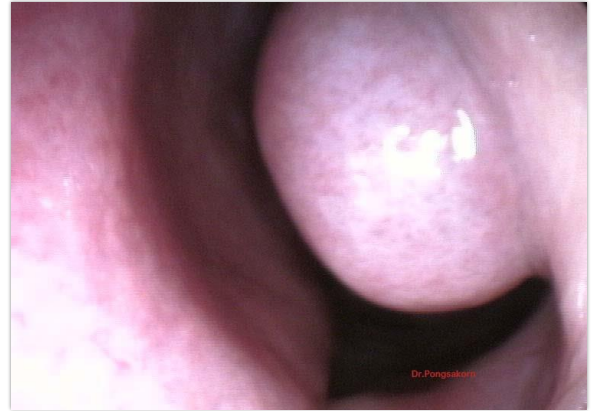- I. *Lateral paranasal sinuses X-ray.*
- II. *Adenoid hypertrophy.*

5. A patient with bilateral nasal blockage.

- I. *Diagnosis?*
- II. *Treatment?*

○ **Answers:**

- I. *Bilateral nasal polyps.*
- II. *Corticosteroids & surgical excision.*

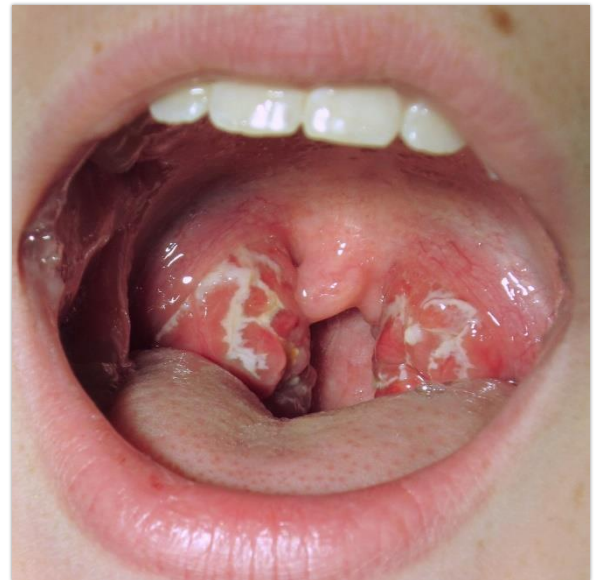

6. A 23-year-old came complaining of sore throat & odynophagia.

- I. *Diagnosis?*
- II. *After a week if there's no improvement after taking antibiotics, & there's trismus, what's the most likely diagnosis?*

○ **Answers:**

- I. *Follicular tonsillitis.*
- II. *Peri-tonsillar abscess.*

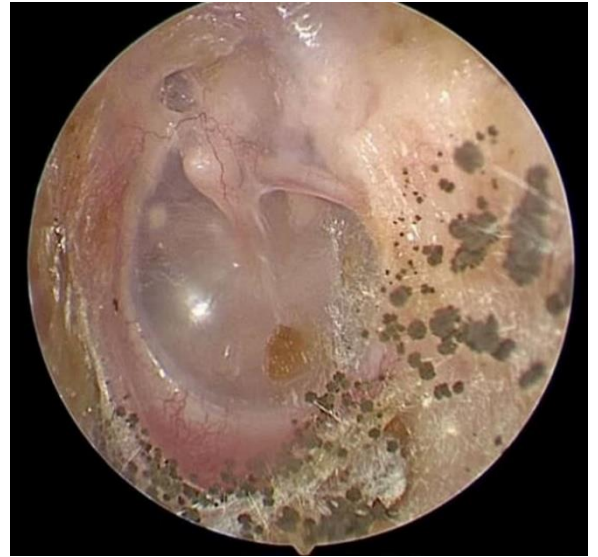

7. A patient with a history of ear itching.

- I. *Diagnosis?*
- II. *Organism?*
- III. *Treatment?*

○ **Answers:**

- I. *Otomycosis.*
- II. *Aspergillus.*
- III. *Aural toilet & topical antifungal.*

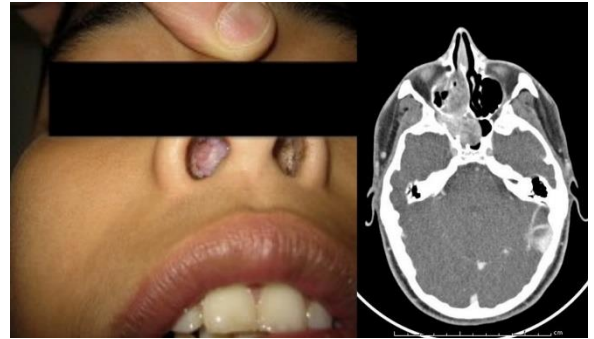


Second semester

1st rotation

1. A 15-year-old boy presents with a few months' history of recurrent epistaxis.

- I. Diagnosis?
- II. What investigation should be done to confirm the diagnosis?

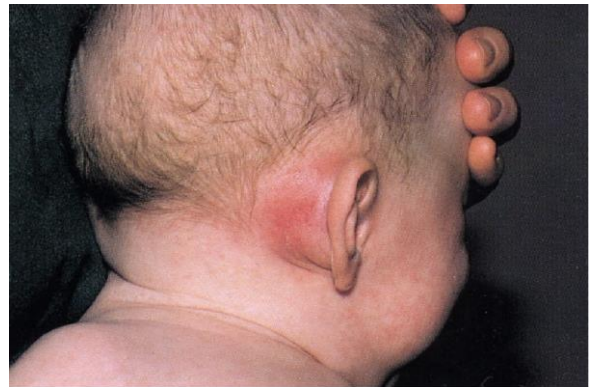

○ **Answers:**

- I. Nasopharyngeal angiofibroma.
- II. Angiography.

2. A 1-year-old baby presents with irritability & high grade fever.

- I. Diagnosis?
- II. Treatment?

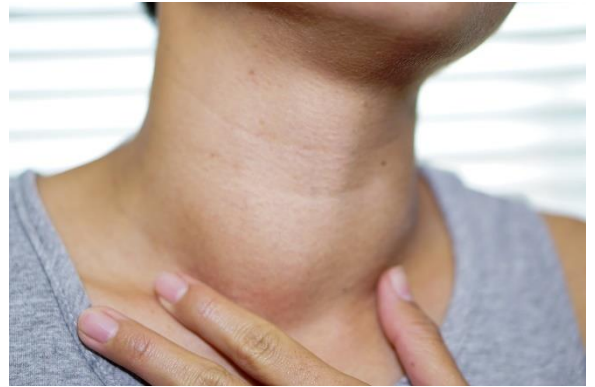

○ **Answers:**

- I. Mastoiditis.
- II. IV antibiotics + tympanostomy tube. Mastoidectomy in severe or refractory cases.

3. ...

- I. What are 3 structures of head & neck that could be affected?
- II. First step in diagnosis?

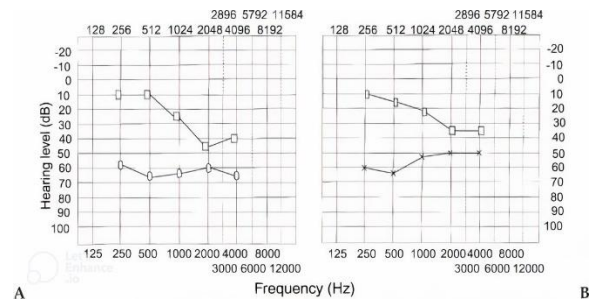


○ Answers:

- I. Nasopharynx; thyroid; nose.
- II. Ultrasound then FNA.

4. ...

- I. Diagnosis?
- II. What is the name of this test?
- III. What is the type of hearing loss?

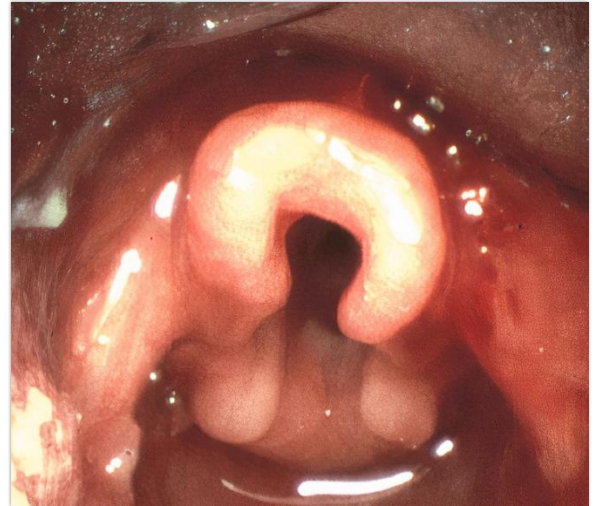


○ Answers:

- I. Otosclerosis.
- II. Pure tone audiometry.
- III. Conductive hearing loss. As hearing loss progresses, a sensorineural component is sometimes seen, resulting in a mixed hearing loss.

5. An infant presented with inspiratory stridor. This is his fiber-optic laryngoscopy during the inspiratory phase.

- I. *Diagnosis?*
- II. *Prognosis?*

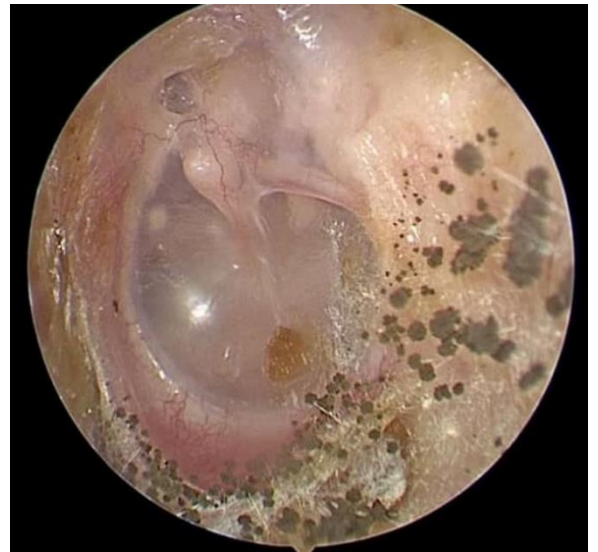

○ **Answers:**

- I. *Laryngomalacia.*
- II. *Good prognosis (they usually resolve on their own at the age of 1 year).*

6. A patient with a history of ear itching.

- I. *Diagnosis?*
- II. *Organism?*
- III. *Treatment?*



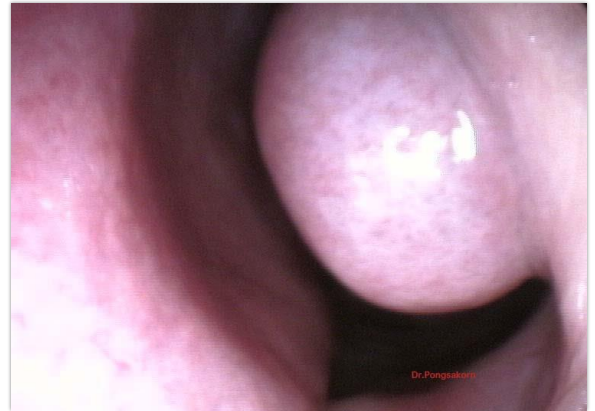○ **Answers:**

- I. *Otomycosis.*
- II. *Aspergillus.*
- III. *Aural toilet & topical antifungal.*

2nd rotation

1. A patient with bilateral nasal blockage.

- I. *Diagnosis?*
- II. *Treatment?*

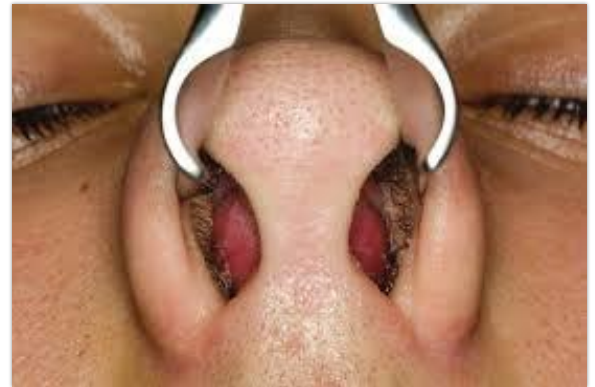

○ **Answers:**

- I. *Bilateral nasal polyps.*
- II. *Corticosteroids & surgical excision.*

2. A patient presented with a history of facial trauma 3 days ago.

- I. *Diagnosis?*
- II. *Cause?*
- III. *How to treat saddle nose deformity?*
- IV. *Mention 2 complications?*

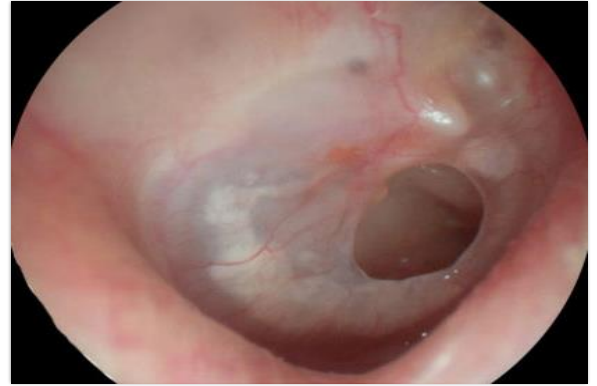

○ **Answers:**

- I. *Septal hematoma.*
- II. *Facial trauma.*
- III. *Rhinoplasty.*
- IV. *Infection with abscess formation; septal perforation.*

3. ...

- I. *Diagnosis?*
- II. *Most common cause of this case?*

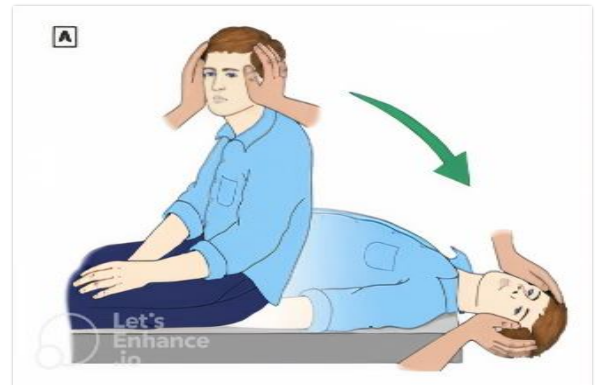

○ Answers:

- I. *Tympanic membrane perforation.*
- II. *Middle ear infection.*

4. ...

- I. *What's the name of this procedure?*
- II. *Which ear is being tested in this picture?*
- III. *Which organ does it test?*
- IV. *What's the diagnosis if the test is positive?*

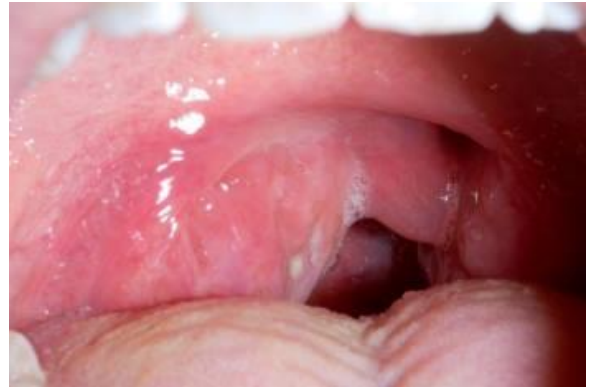

○ Answers:

- I. *Dix Hallpike maneuver.*
- II. *The left ear.*
- III. *The semicircular canals.*
- IV. *BPPV.*

5. ...

- I. *Diagnosis?*
- II. *What is the most important thing to do for treatment?*
- III. *What is the most important complication?*



○ Answers:

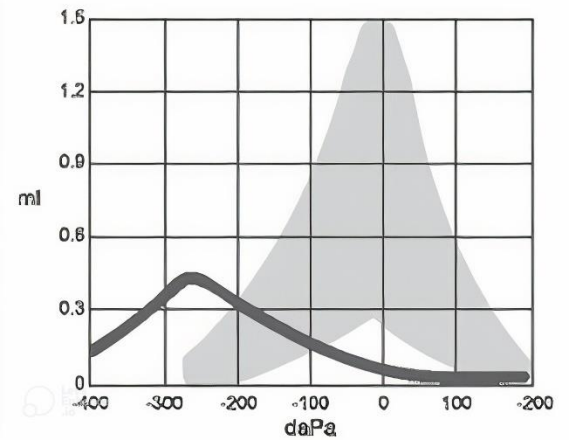
- I. *Peritonsillar abscess.*
- II. *Drainage of the abscess.*
- III. *Blockage of the airway/sepsis.*

6. ...

- I. *What is the name of this test?*
- II. *What does it measure?*
- III. *What is the pathology in this graph?*

○ Answers:

- I. *Tympanometry.*
- II. *Compliance of the tympanic membrane.*
- III. *Eustachian tube dysfunction.*



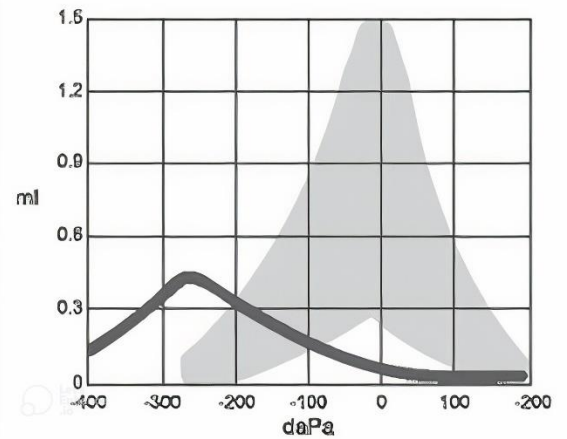
3rd rotation

1. A case of a child complaining of rubbing ear.

- I. *Diagnosis?*
- II. *Underlying cause?*

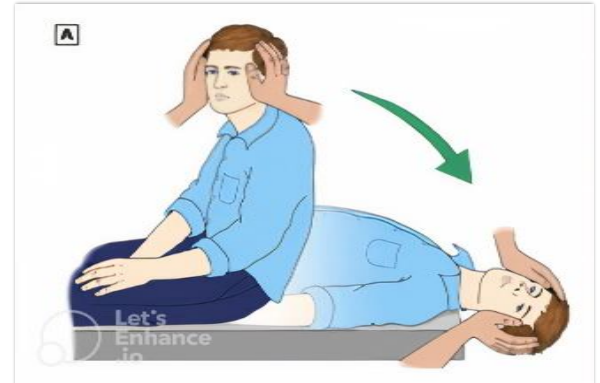○ Answers:

- I. *Eustachian tube dysfunction.*
- II. *URTI; adenoid hypertrophy. (?)*



2. ...

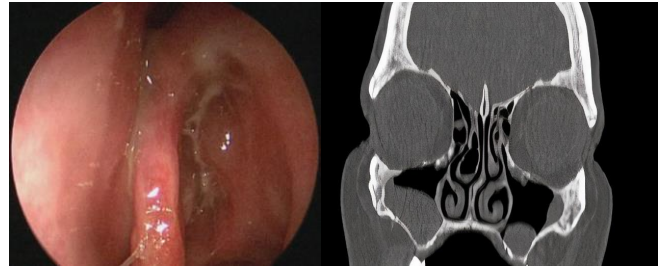
- I. *What's the name of this procedure?*
- II. *Which ear is being tested in this picture?*
- III. *Which organ does it test?*
- IV. *What's the diagnosis if the test is positive?*



○ Answers:

- I. *Dix Hallpike maneuver.*
- II. *The left ear.*
- III. *The semicircular canals.*
- IV. *BPPV.*

3. A 47-year-old boy presented with a 5-month history of fever & thick, yellow nasal discharge.



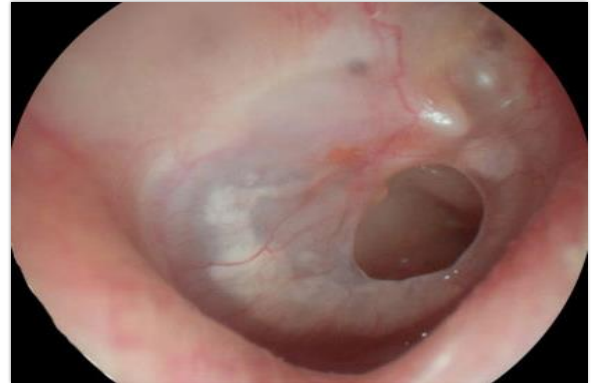- I. *Diagnosis?*
- II. *Treatment?*

○ **Answers:**

- I. *Chronic maxillary sinusitis & septal deviation.*
- II. *Surgery (FESS) & septoplasty.*

4. ...

- I. *Diagnosis?*
- II. *Most common cause?*

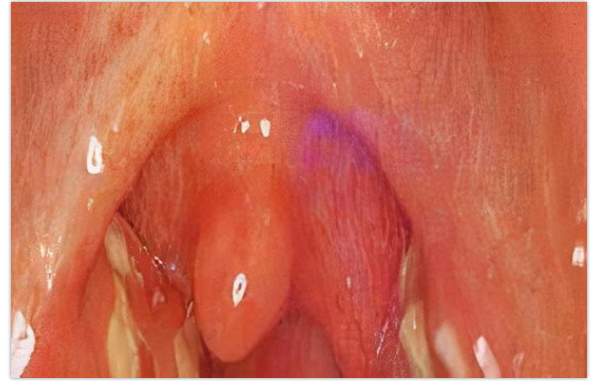

○ **Answers:**

- I. *Tympanic membrane perforation.*
- II. *Middle ear infection.*

5. ...

- I. *Diagnosis?*
- II. *3 other differential diagnoses?*
- III. *2 lines of treatment?*

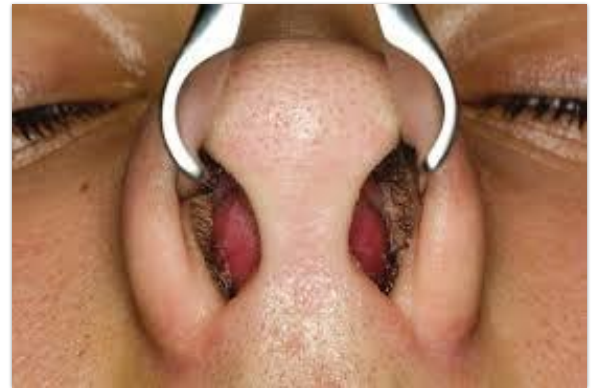

○ **Answers:**

- I. *Follicular tonsillitis.*
- II. *Infectious mononucleosis; diphtheria; scarlet fever.*
- III. *IV antibiotics; tonsillectomy if indicated.*

6. A patient presented with a history of facial trauma 3 days ago.

- I. *Diagnosis?*
- II. *Mention 3 causes?*
- III. *Mention 2 complications?*



○ **Answers:**

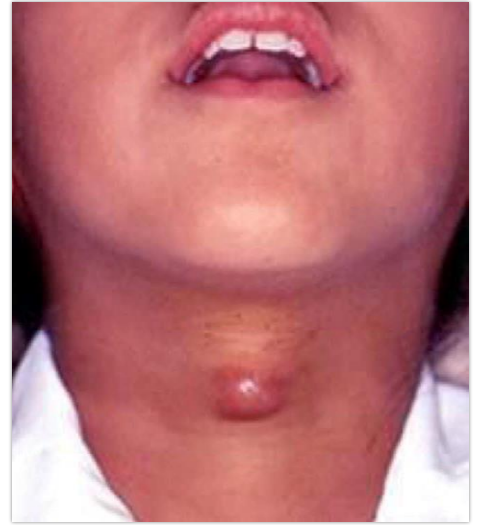- I. *Septal hematoma.*
- II. *Nasal trauma; septal surgery; bleeding disorders.*
- III. *Infection with abscess formation; septal perforation.*

7. ...

- I. *Diagnosis?*
- II. *Treatment?*

○ **Answers:**

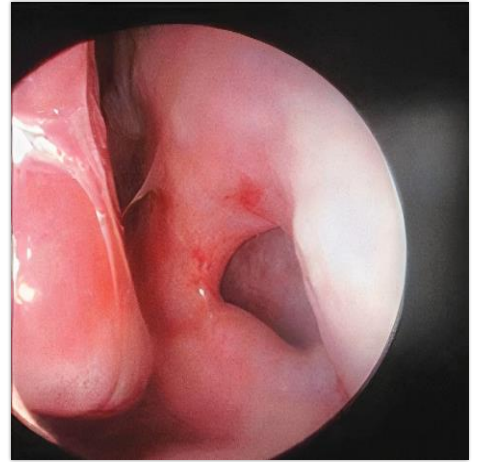
- I. *Thyroglossal duct cyst.*
- II. *Surgical removal of the cyst & central part of the body of hyoid bone (Sistrunk operation) after resolution of any infection.*



4th rotation

1. A patient presented with a history of facial trauma 4 months ago.

- I. *Diagnosis?*
- II. *Cause?*
- III. *Best treatment option?*

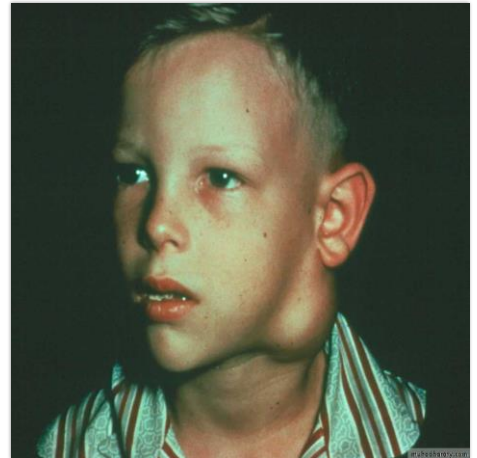

○ **Answers:**

- I. *Septal perforation.*
- II. *Facial trauma.*
- III. *Septoplasty.*

2. A 11-year-old child with a neck mass, night sweats, & liver mass.

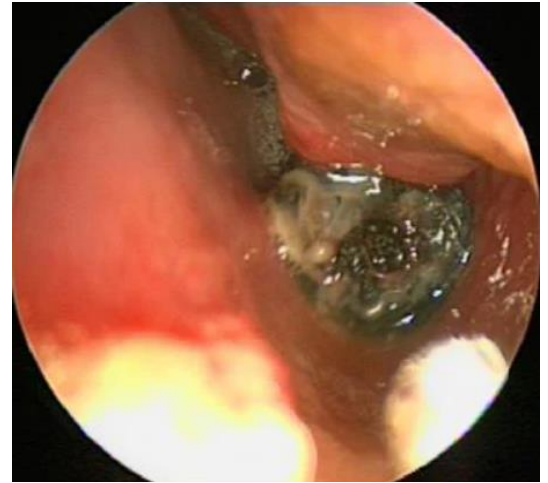- I. *Diagnosis?*
- II. *Best investigations?*



○ **Answers:**

- I. *Lymphoma.*
- II. *Ultrasound & FNA.*

3. A 27-year-old presented with a 3-month history of left nostril discharge.

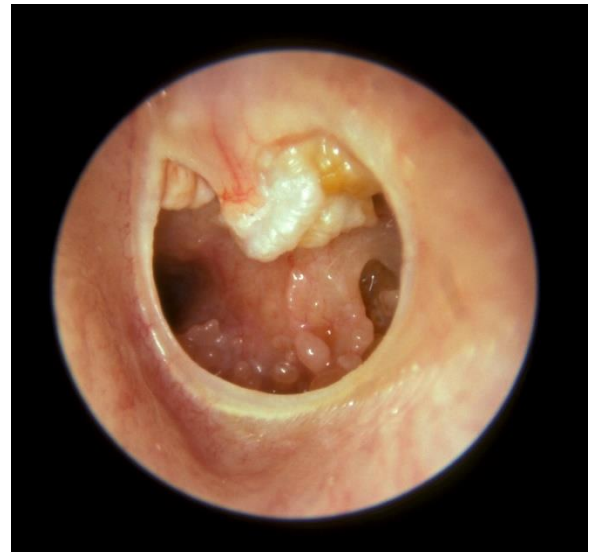

- I. *Diagnosis?*
- II. *Most serious complications?*

○ **Answers:**

- I. *Foreign body in the nasal cavity.*
- II. *Aspiration of the foreign body & airway obstruction.*

4. A patient presented to the clinic complaining of ear discharge that is foul smelling.



- I. *Diagnosis?*
- II. *Treatment?*
- III. *Complication?*

○ **Answers:**

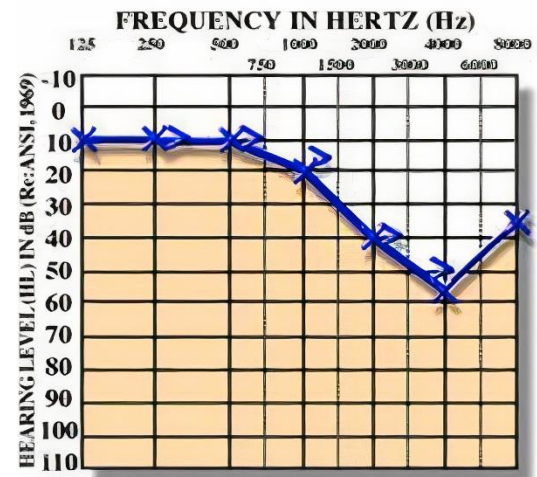
- I. *Cholesteatoma.*
- II. *Surgical excision + tympanoplasty + mastoidectomy.*
- III. *Intratemporal (petrositis, facial paralysis, labyrinthitis) & intracranial (lateral sinus thrombosis, meningitis, abscess formation).*

5. A 35-year-old complaining of decreased hearing.

- I. *Diagnosis?*
- II. *Important things to ask about in the history?*

○ **Answers:**

- I. *Noise-induced sensorineural hearing loss.*
- II. *Ask about his occupation.*

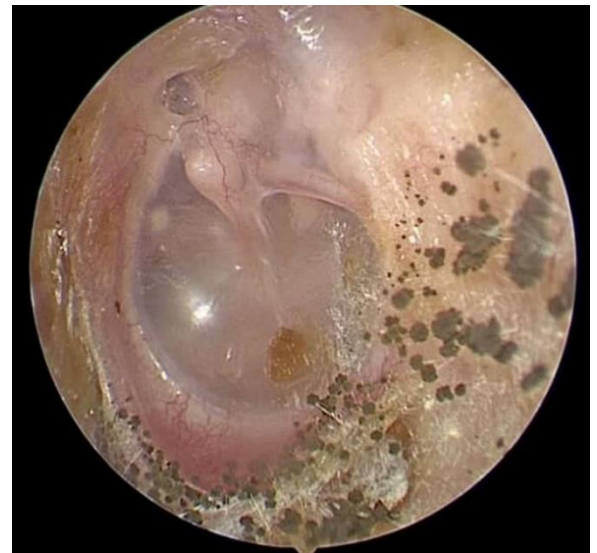

6. A patient with a history of ear itching.

- I. *Diagnosis?*
- II. *Organism?*
- III. *Treatment?*

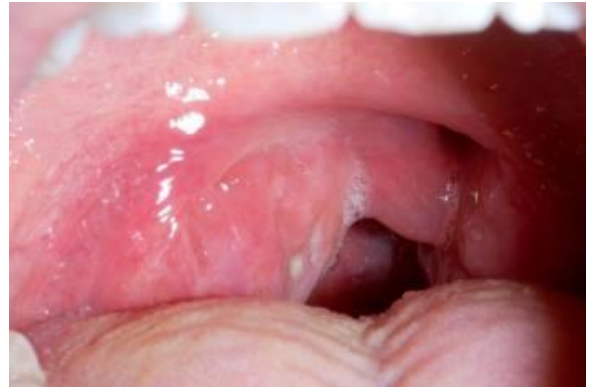○ **Answers:**

- I. *Otomycosis.*
- II. *Aspergillus.*
- III. *Aural toilet & topical antifungal.*



7. ...

- I. *Diagnosis?*
- II. *Best investigation to confirm the diagnosis?*
- III. *Presenting symptoms?*
- IV. *Treatment?*



○ **Answers:**

- I. *Peritonsillar abscess.*
- II. *Needle aspiration of the abscess site.*
- III. *Severe sore throat; dysphagia; very high spiking fever; trismus; hot potato voice; dehydration.*
- IV. *Drainage of the abscess.*