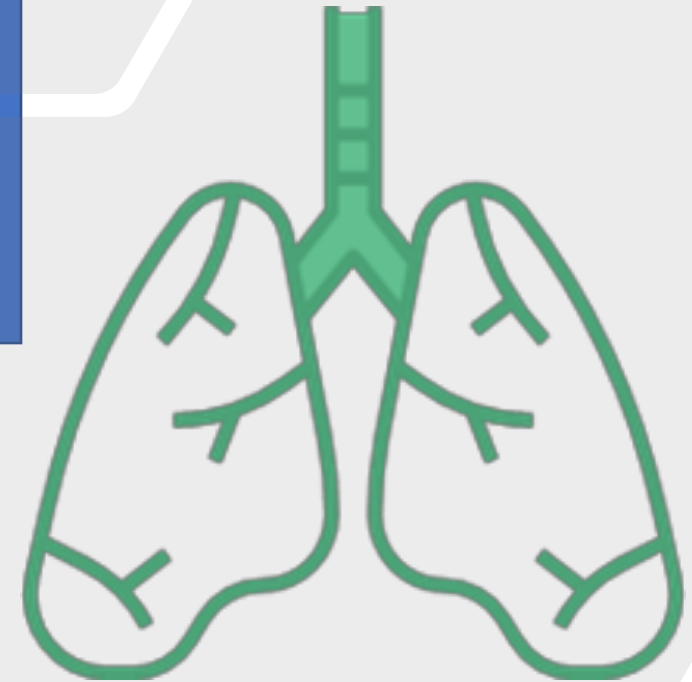
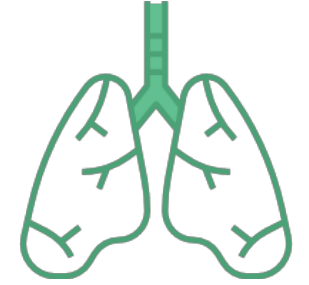

Approach to Wheeze In Children

Enas AL-Zayadneh
Associate Professor
Pediatric Pulmonologist



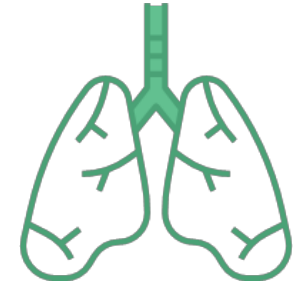
Definition :



- A wheeze is a **continuous musical sound** heard during chest auscultation
- Produced by the oscillation of opposing walls of an airway narrowed almost to the point of closure.
- It can be high pitched or low pitched, consist of single or multiple notes, and occur during inspiration or expiration
- Wheezing requires **sufficient airflow** to generate airway oscillation and produce sound in addition **to narrowing or compression** of the airway.

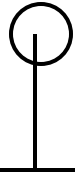Clinical Approach

- Onset
- Timing (expiratory ,Inspiratory)
- Duration
- Frequency/recurrence
- Associated symptoms
- Response to treatment



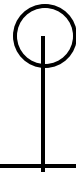Classification of wheezes

Acute wheezing
(hours to days)

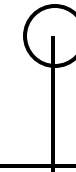

- Asthma
- Infections
- Foreign body aspiration (sudden onset)

Chronic or recurrent
wheezing

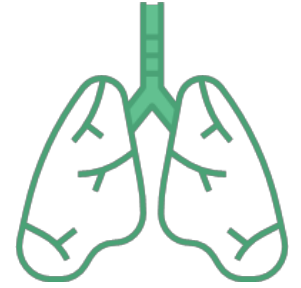

- Structural causes:
 - Anomalies of the tracheobronchial tree
 - Mediastinal masses
 - **Retained foreign body**
 - Cardiovascular disease



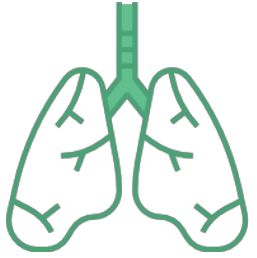- Nonstructural causes:
 - Asthma
 - Aspiration syndromes
 - Bronchopulmonary dysplasia
 - Paradoxical vocal cord motion
 - Cystic fibrosis
 - Primary ciliary dyskinesia
 - Primary immunodeficiencies
 - Bronchiolitis obliterans

Acute: Asthma



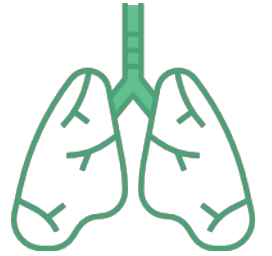- Most frequent cause of **recurrent wheezing** is asthma,
- Supporting findings
 1. Evidence of atopic disease
 2. Intermittent episodes of wheezing that usually are the result of a common trigger (ie, upper respiratory infections, weather changes, exercise, or allergens)
 3. Family history of asthma and/or atopy
 4. Good response to asthma medications
 5. Positive asthma predictive index

Acute: Infections

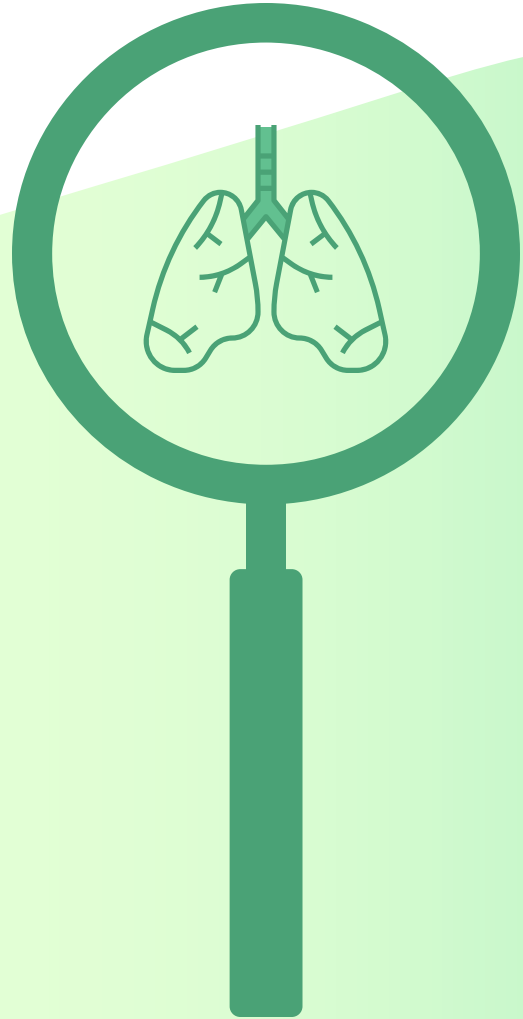

- **Bronchiolitis** :The most common cause of acute wheezing in infants <2 years :syncytial virus RSV (most common) , Rhinovirus and paramyxoviruses, including parainfluenza virus and metapneumovirus
- A typical history is a prodrome of rhinorrhea, cough, and intermittent fever followed by wheezing and tachypnea.
- Physical examination usually reveals nasal congestion, tachypnea, increased work of breathing, and polyphonic wheezes throughout the lungs.
- DDx :Laryngotracheobronchitis
- Atypical pneumonia such as Mycoplasma pneumonia, especially in older children.
- Bacterial tracheitis :other symptoms such as toxic looking, high fever, and severe distress will typically guide the diagnosis.

Acute : Foreign Body Aspiration



- FBA should be suspected in any patient who presents with wheezing of **sudden onset**
- Consider even in the absence of a clear history of a choking episode.
- FBA suspected in any child with a unilateral wheeze or unequal breath sounds.
In children, unlike adults, FB can lodge in any bronchus, without predilection for the right side.
- chronic symptoms if FBA is not recognized in the acute setting.
- Esophageal foreign body. A history of feeding and swallowing difficulties and the presence



Chronic or recurrent wheezing

1. **structural abnormalities** of the tracheobronchial tree or other thoracic structures.
2. **Nonstructural causes** of chronic wheezing include asthma, aspiration syndromes, bronchopulmonary dysplasia, vocal cord dysfunction, and other disorders.

structural abnormalities

- Congenital tracheomalacia and bronchomalacia
- Vascular rings or slings
- Tracheoesophageal fistulae, laryngotracheobronchial clefts
- Mediastinal masses
- Cardiovascular disease

Nonstructural causes (functional)

- Aspiration syndromes,
- FVC : paradoxical vocal cord function,
- Bronchopulmonary dysplasia,
- rare disorders) such as primary ciliary dyskinesia and bronchiolitis obliterans.

Evaluation of a wheezy child

- **Clinical history** and **physical examination** often allow accurate diagnosis.
A therapeutic trial of Most patients who respond will have asthma.
- **Radiographic examination, pulmonary function testing (PFT), bronchoscopy, sweat chloride concentration, and selective laboratory studies** are helpful tools in establishing the underlying etiology of wheezing when used appropriately.




Age at onset? Infancy

- Structural abnormalities
- such as tracheomalacia/bronchomalacia,
- vascular compression/rings,
- tracheal stenosis/webs),
- virus-induced wheezing (bronchiolitis and laryngotracheitis),
- (FBA) are typically seen during infancy and early childhood.

Onset :Later in childhood


- vocal cord dysfunction, tend to present in later childhood to adolescence

Physical examination



- **measurement of weight and height,**
- **vital signs** including oxygen saturation,
- **digital inspection for the presence of cyanosis or clubbing.**

Chest examination




Inspection for the presence of respiratory distress, tachypnea, retractions, or structural abnormalities.

- Pertinent findings include an increased anteroposterior (AP) diameter associated with chronic hyperinflation,
- pectus excavatum caused by chronic airway obstruction and exaggerated swings in intrathoracic pressure, or scoliosis complicated by airway compression.

Palpation to detect supratracheal lymphadenopathy or tracheal deviation.

Percussion to define the position of the diaphragm and detect differences in resonance among lung regions. Percussion is the most underperformed part of the examination.




Auscultation

- A **prolonged expiratory phase** suggests airway narrowing.
- Wheezing caused by a large or central airway obstruction (eg, vascular ring, subglottic stenosis, tracheomalacia) has a constant acoustic character throughout the lung but varies in loudness depending upon the distance from the site of obstruction.
- **Focal wheezing** is usually indicative of a localized and mostly structural airway abnormality, and, therefore, airway evaluation by imaging or bronchoscopy is warranted.



- **Crackles** can be present in conjunction with wheezing in asthma and in a variety of other conditions, such as those leading to bronchiectasis (eg, CF, primary ciliary dyskinesia, immunodeficiency).
- Early inspiratory crackles are often present in patients with asthma due to air flowing through secretions or slightly closed airways during inspiration. Late inspiratory crackles are usually associated with ILD and early congestive heart failure. Thus, the presence of crackles does not exclude the diagnosis of asthma.



The exam should also focus on **extrapulmonary findings** that suggest an etiology for wheezing.

- The **cardiac examination** includes auscultation for murmurs and evaluation for signs of heart failure.
- Examination of the **skin** for eczema (common in atopic patients) or other cutaneous lesions may assist in diagnosis.
- **Nasal examination** may reveal signs of allergic rhinitis, sinusitis, or nasal polyps. The presence of nasal polyps in children necessitates an evaluation for CF.

Radiography


-A chest radiograph (AP and lateral films) should be obtained:

1. in children with new-onset wheezing of undetermined etiology
2. chronic, persistent wheezing not responding to therapies.

-It is not necessary to obtain a chest radiograph with every exacerbation in children with asthma, unless there is a specific indication.

-In most cases, a plain chest radiograph provides a good image of the large airways, including the tracheal air column and main stem bronchi. Plain films can also help differentiate between diffuse and focal disease.

The presence of **generalized hyperinflation** suggests diffuse air trapping and airway disease, seen in asthma, CF, primary ciliary dyskinesia, and aspiration. In contrast, localized findings suggest structural abnormalities or FBA.



- A chest radiograph can also detect parenchymal lung disease, atelectasis, and, in some cases, areas of bronchiectasis.
- Chest radiographs may reveal cardiomegaly, enlarged pulmonary vessels, pulmonary edema, or other signs of cardiac failure.
- Plain radiographs also are helpful in detecting mediastinal masses or enlarged lymph nodes and may suggest the presence of vascular rings (eg, right aortic arch).

