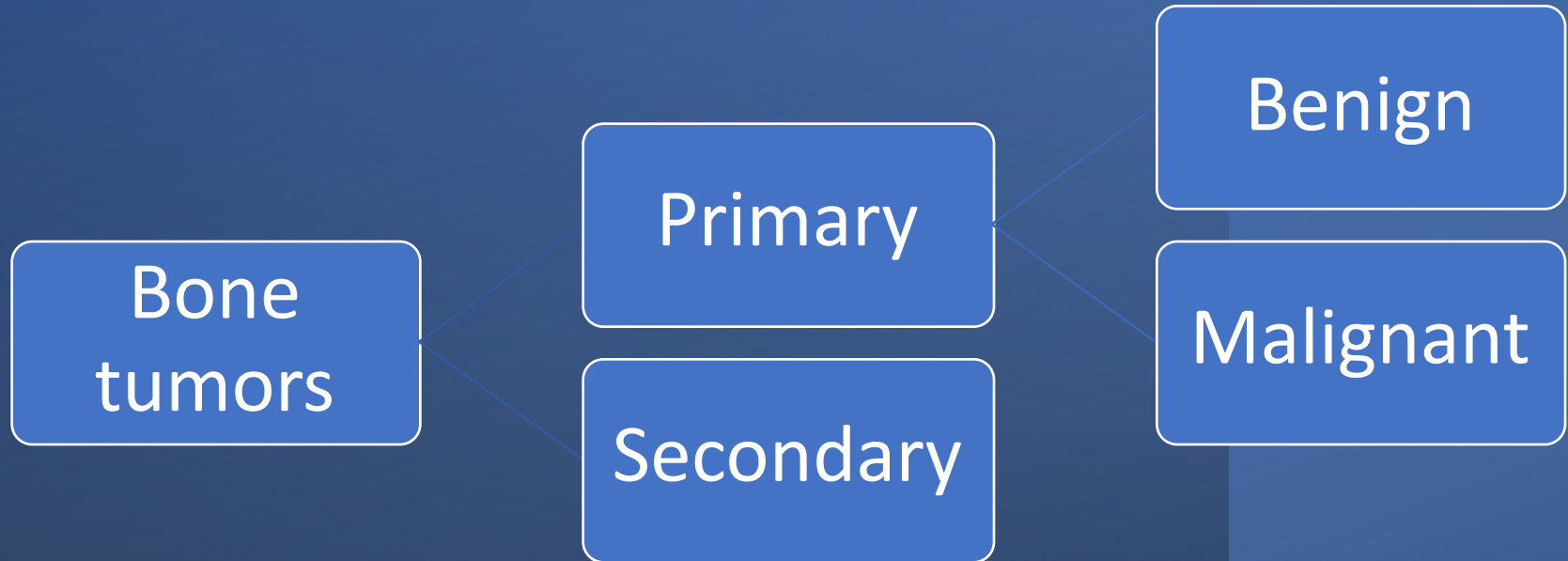


Bone Tumors

Bassem Haddad, MD



General Principles



| HISTOLOGIC TYPE | BENIGN | MALIGNANT |
|-----------------------------|---|--|
| Hematopoietic (40%) | | Myeloma Malignant lymphoma |
| Chondrogenic (22%) | Osteochondroma Chondroma Chondroblastoma Chondromyxoid fibroma | Chondrosarcoma Dedifferentiated chondrosarcoma Mesenchymal chondrosarcoma |
| Osteogenic (19%) | Osteoid osteoma Osteoblastoma | Osteosarcoma |
| Unknown origin (10%) | Giant cell tumor | Ewing tumor Giant cell tumor Adamantinoma |
| Histiocytic origin | Fibrous histiocytoma | Malignant fibrous histiocytoma |
| Fibrogenic | Metaphyseal fibrous defect (fibroma) | Desmoplastic fibroma Fibrosarcoma |
| Notochordal | | Chordoma |
| Vascular | Hemangioma | Hemangioendothelioma Hemangiopericytoma |
| Lipogenic | Lipoma | Liposarcoma |
| Neurogenic | Neurilemmoma | |

Presentation

Pain: usually progressive non-mechanical pain

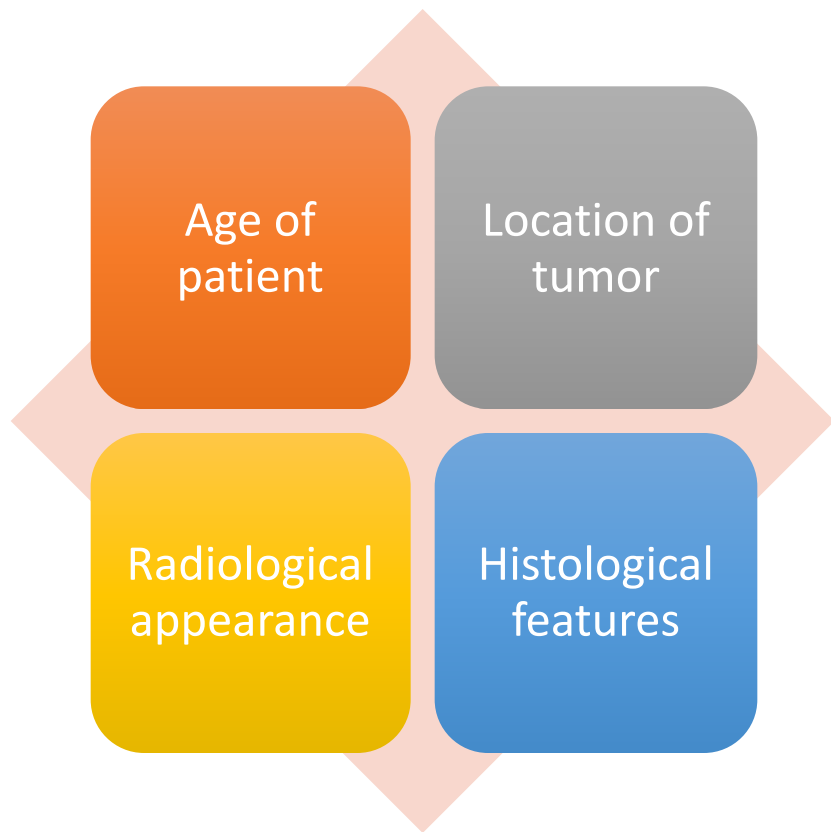
Lump (mass): could be tender or warm

Deformity

Loss of range of motion: could be due to pain, inflammation, or mechanical block

Some benign lesion are completely asymptomatic (incidental findings)

Diagnosis



Differential According to Site

Diaphyseal lesions centered in the cortex:

Osteoid osteoma

Diaphysis

Diaphyseal intramedullary lesions:

Ewing's sarcoma, lymphoma, myeloma.
Common for **fibrous dysplasia** and **enchondroma**

Metaphyseal intramedullary lesions:

Osteosarcoma is usually centered in the metaphysis. Chondrosarcoma and fibrosarcoma often present as metaphyseal lesions. Osteoblastoma, enchondroma, fibrous dysplasia, simple bone cyst, and aneurysmal bone cyst are common in this location.

Metaphysis

Metaphyseal lesions centered in the cortex:

Classic location for a non-ossifying fibroma (NOF). Also, a common site for osteoid osteoma.

Physis

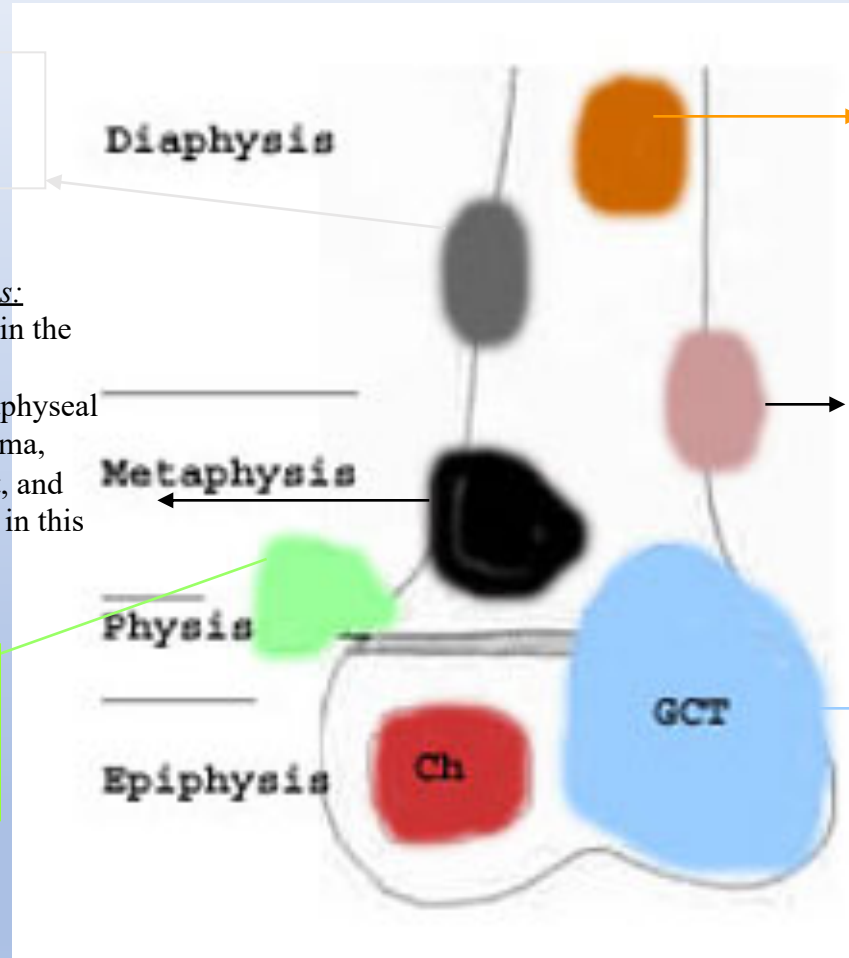
Metaphyseal exostosis:

Osteochondroma

Epiphysis

Epiphyseal lesions:

Chondroblastoma (Ch) and **Giant Cell Tumor (GCT)** are almost invariably centered in the epiphysis. Chondroblastoma is a rare tumor seen in children and adolescents with open growth plates. GCT is the most common tumor of epiphyses in skeletally mature individuals with closed growth plates. GCT often shows metaphyseal extension.



Radiological Appearance

Benign lesions:

- Could be lytic, sclerotic, or mixed.
- Well defined margins (narrow transition zone).
- A sclerotic rim could be present (indicates a long standing stable lesion).
- No cortical destruction (although a fracture might be present). Some lesions cause thinning or ballooning of the cortex.
- No periosteal reaction.

Radiological Appearance

Malignant lesions:

- Could be lytic, sclerotic, or mixed.
- Ill defined margins (wide transition zone).
- Cortical destruction.
- Periosteal reaction.
- A soft tissue mass (shadow) can sometimes be seen.

Further Evaluation

Benign lesions:

- Diagnosis is usually clear based on the history, physical exam, and radiological features.
- Labs: usually normal.
- MRI.
- CT scan (surgical planning mainly).
- A core biopsy is usually not needed.

Further Evaluation

Malignant lesions (primary):

- Labs (alkaline phosphatase, LDH).
- Further local evaluation by a contrasted MRI of the whole involved bone (to detect skip lesions).
- Staging:
 - Bone scan (bone metastases).
 - Chest CT scan (pulmonary metastases).
 - PET scan.
 - Core biopsy: assess grade of the lesion.

Further Evaluation


Malignant lesions (secondary metastases):

- Look for the primary if unknown (history, physical exam, imaging, and blood workup).
- If a primary not found → biopsy.
- Assess the spread/ other locations → bone scan or PET scan.
- Any hot lesion on the scan should be further evaluated radiologically (x-ray, MRI, or CT).

Management in General

Benign lesion:


- If asymptomatic: only observe and do not touch.
- If symptomatic (pain): curettage and grafting.
- Surgically correct deformities if present.



Management in General

Malignant lesions (primary):

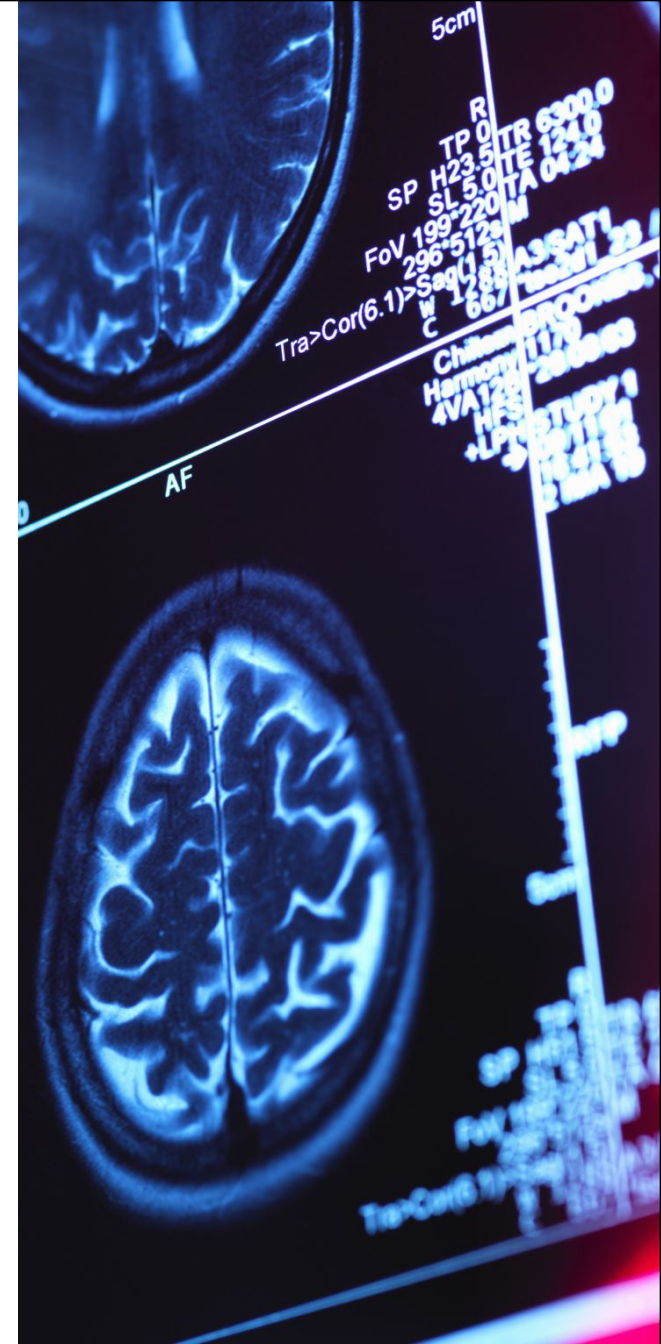
- If chemosensitive: neoadjuvant chemotherapy, surgical resection and reconstruction, followed by adjuvant chemotherapy (e.g. classic osteosarcoma).
- Consider adding radiotherapy if lesion is radiosensitive (e.g. Ewing's sarcoma).
- Surgical resection only in low grade lesions (e.g. most chondrosarcomas).

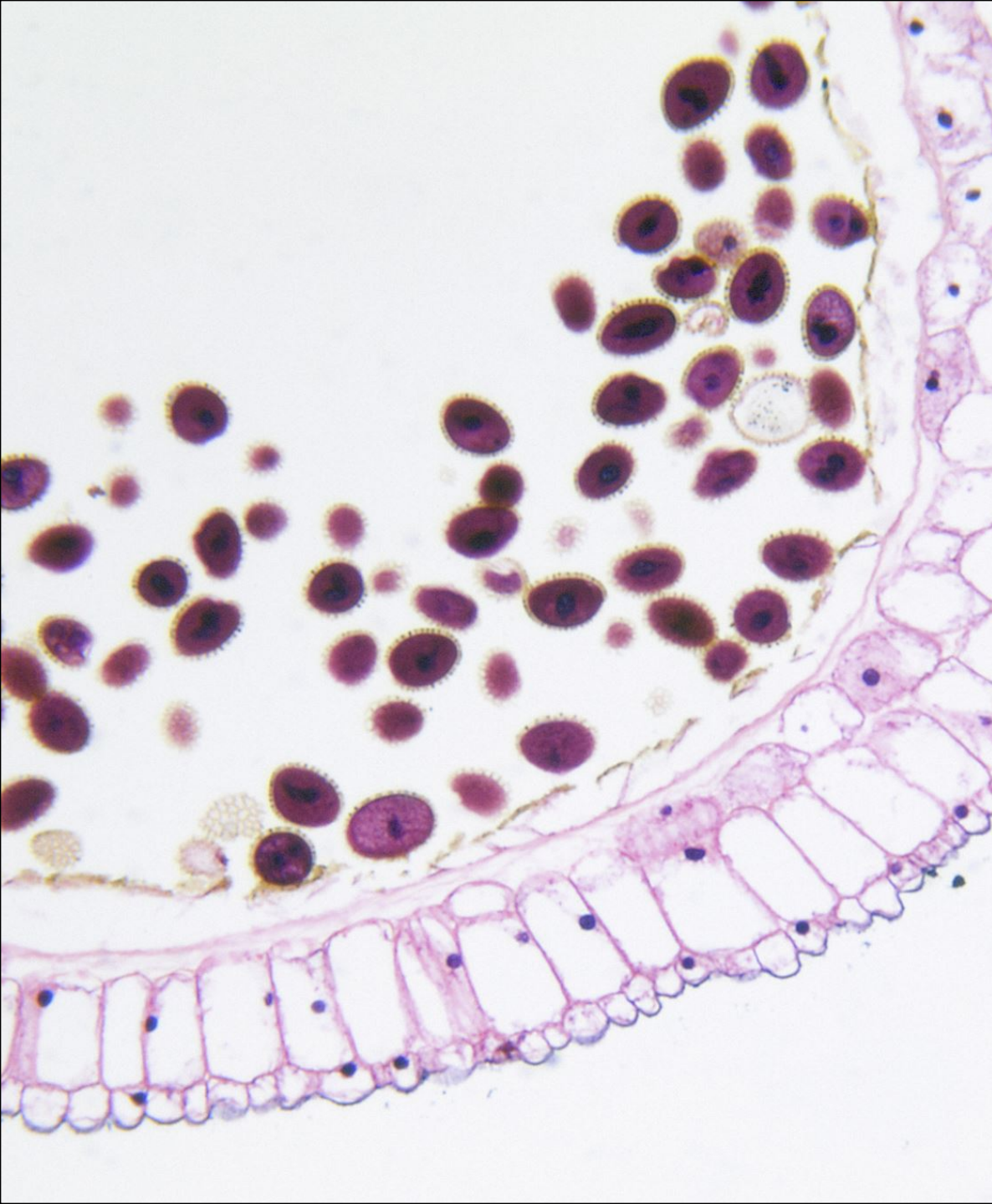


Management in General

Malignant lesions (secondary metastases):

1. Treat the primary tumor (by the oncologist).
2. Prevent SRE's (skeletal related events, i.e. pain and fractures):
 - Radiotherapy (e.g. in the spine).
 - Zometa (a bisphosphonate).
 - Prophylactically fix lesions with high risk of fractures.
 - Fix fractures if they occur.
 - Try to resect solitary metastases.

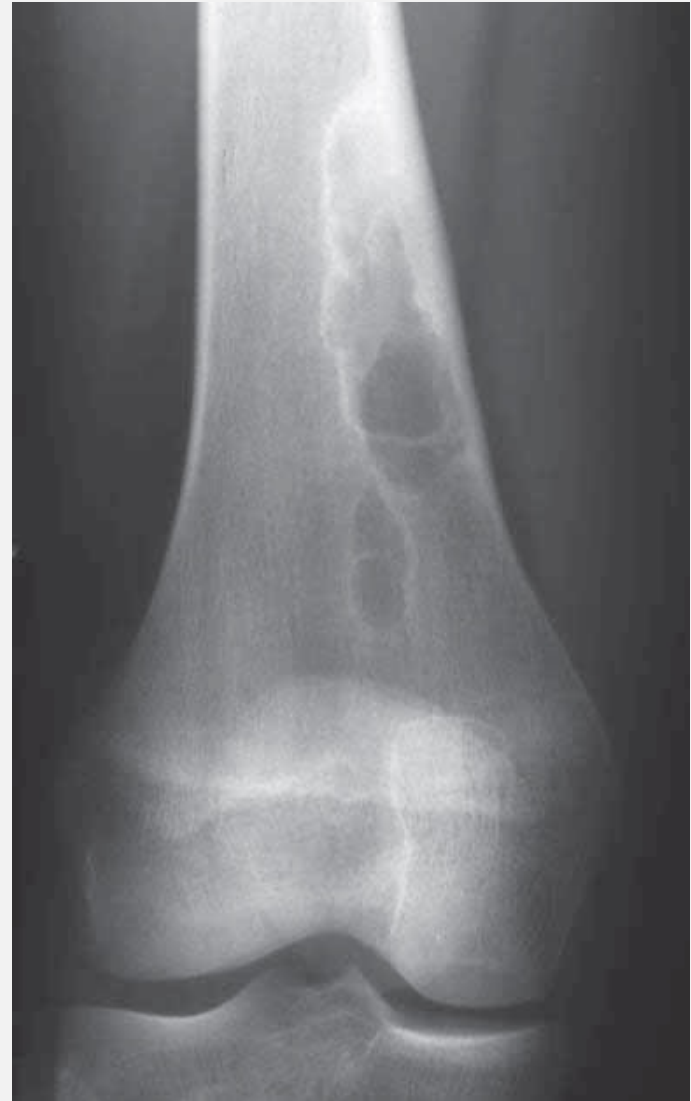



Some
Benign
Lesions

Histiocytic fibroma

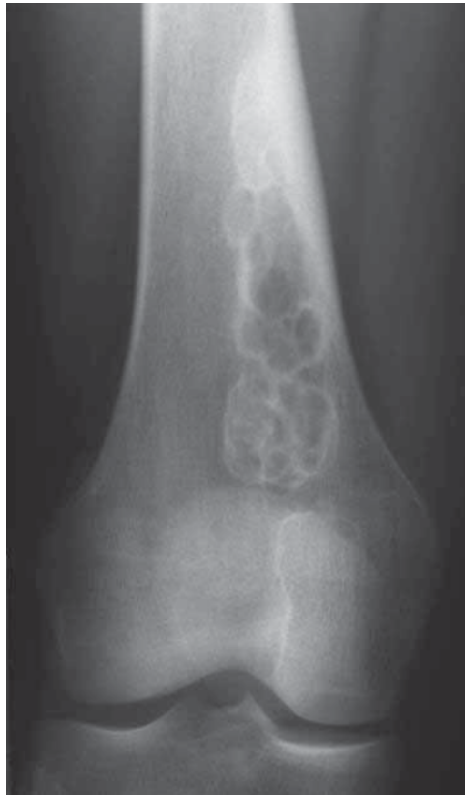-
- The most common lesion of bone.
 - Asymptomatic.
 - Old names include non-ossifying fibroma and fibrous cortical defect.
 - Notice the eccentric metaphyseal well defined mixed lytic and sclerotic lesion. A sclerotic rim is seen.
 - No cortical destruction or periosteal reaction are seen.



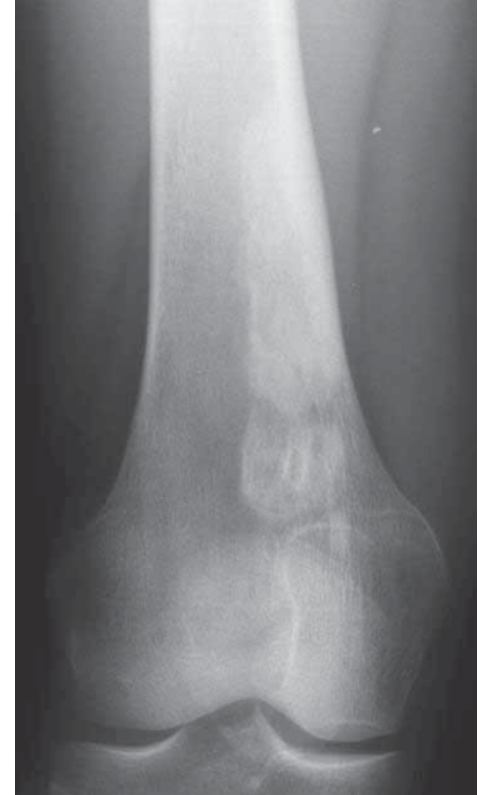Histiocytic fibroma

- No need for treatment as the lesion ossifies with time.
- Notice the progressive ossification of the lesion over the years.

After 2 years

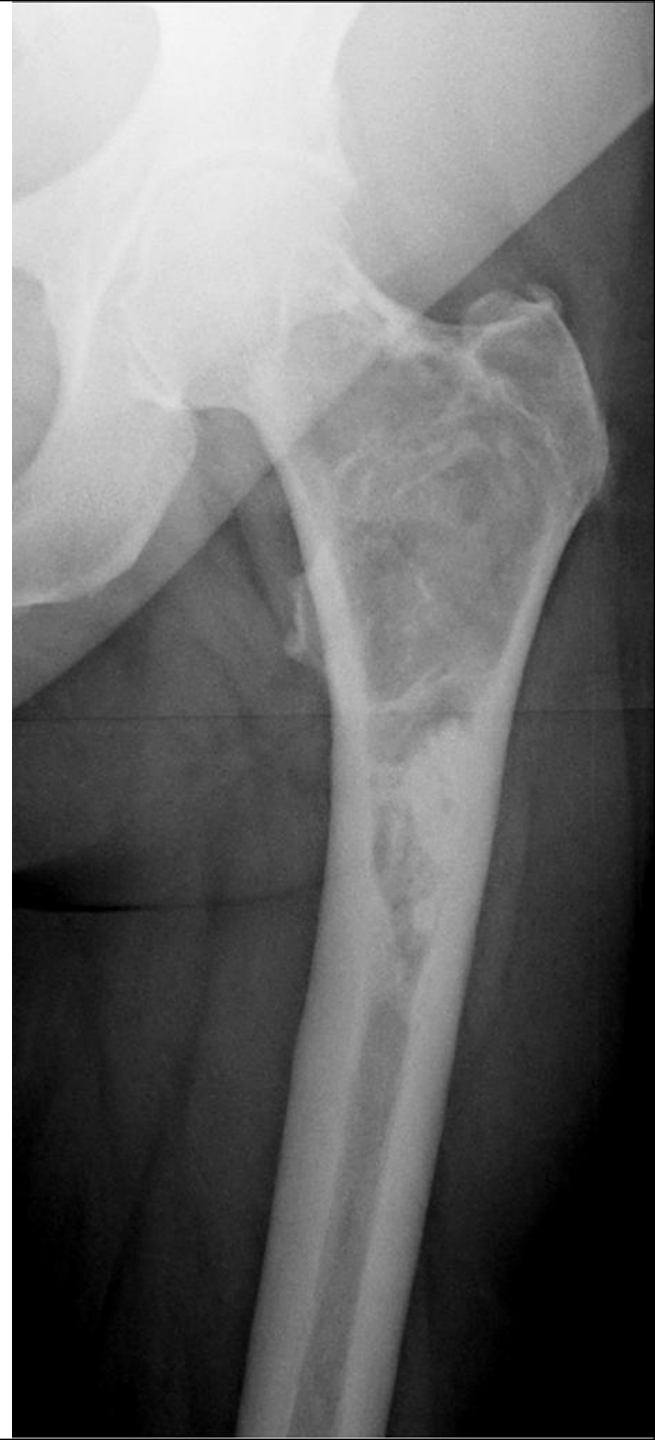

After 5 years



Fibrous Dysplasia

- Notice the central well defined lytic lesion with ground glass appearance (fine calcifications).
- Can affect any bone.
- Solitary lesions rarely transform into malignancy.

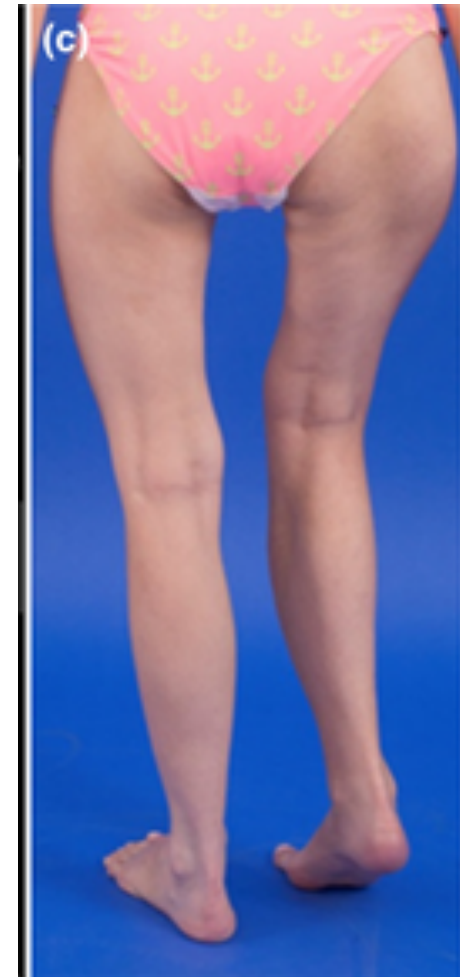
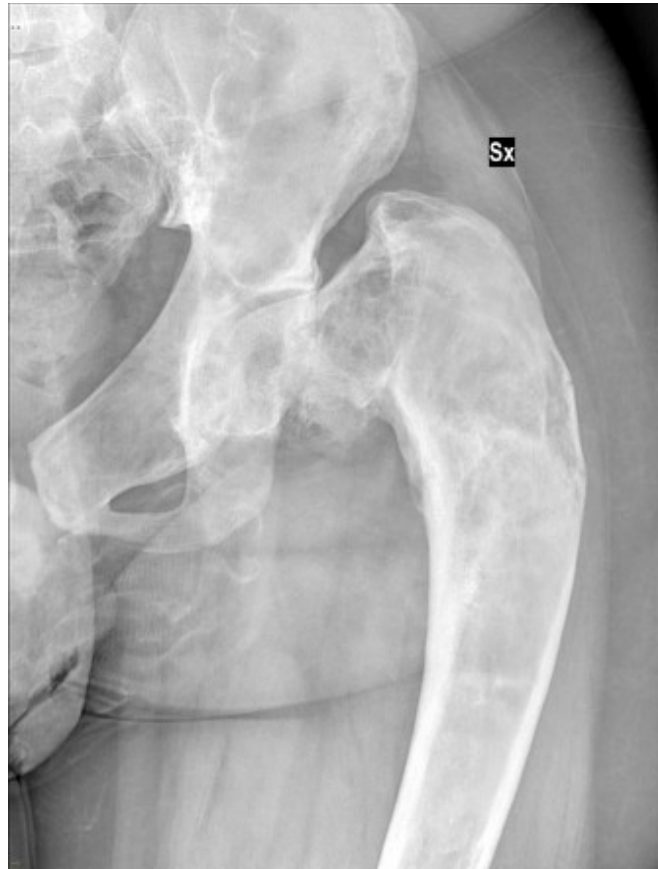

Fibrous Dysplasia

- Polyostotic (multiple bones) lesions have a higher risk of malignant transformation.
- Can be associated with McCune Albright syndrome (multiple café au lait spots and endocrine abnormalities).
- Proximal femoral deformity is apparent (shepherd's crook deformity).
- Treatment includes observation, bisphosphonates, and deformity correction.

Fibrous Dysplasia

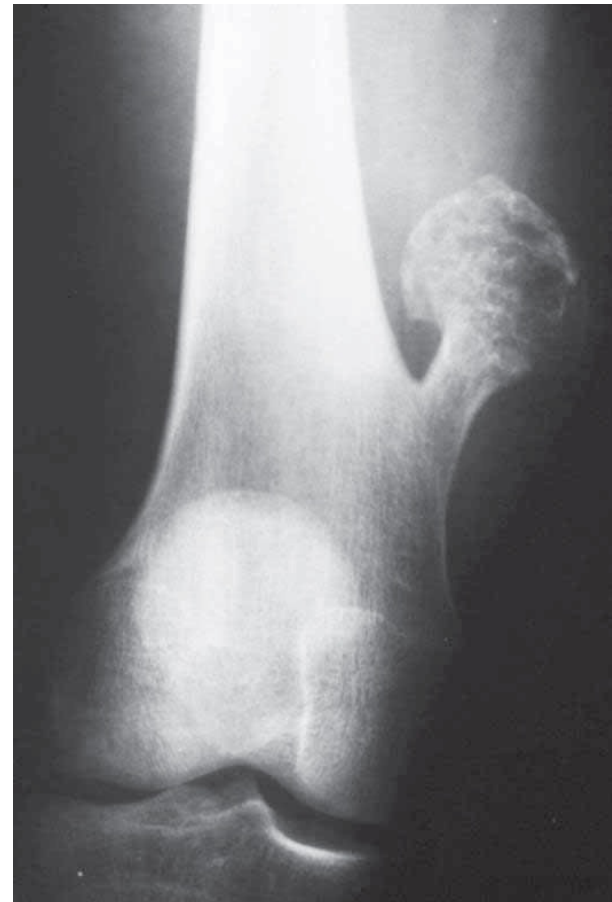- Shepherd's crook Deformity.



Osteochondroma

- The most common benign lesion of bone.
- Arises from aberrant growth of cells in the perichondreal ring
- Clinically larger than x-rays as they are covered with a cartilage cap that is not apparent on radiographs.
- Point toward the center of the bone.

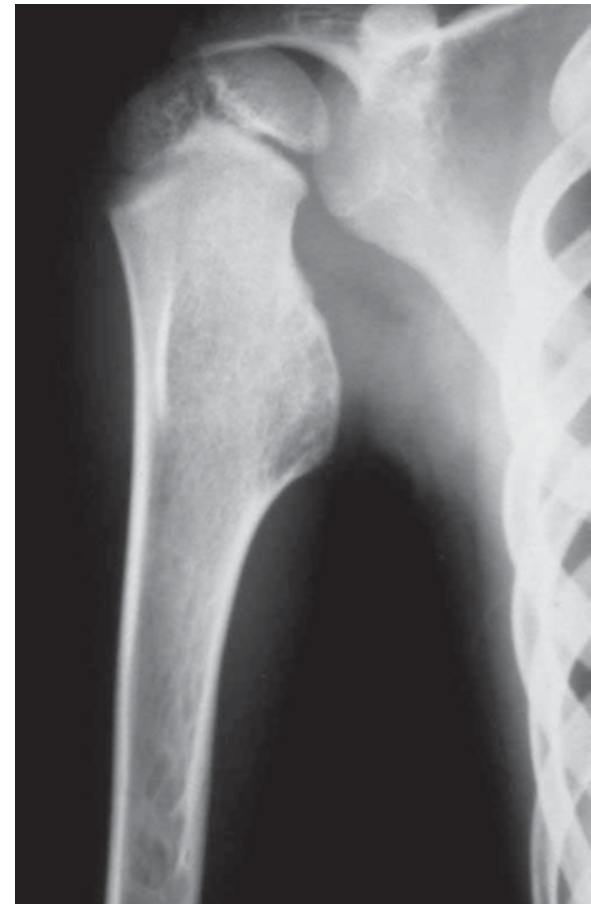
Pedunculated (stalked)



Osteochondroma

- Continues to grow with the child and stops growing at skeletal maturity.
- Growth beyond skeletal maturity can indicate malignant transformation.
- Malignancy is rare.
- Presentation: lump, pain (tendinitis or bursitis), or mechanical restriction of movement.

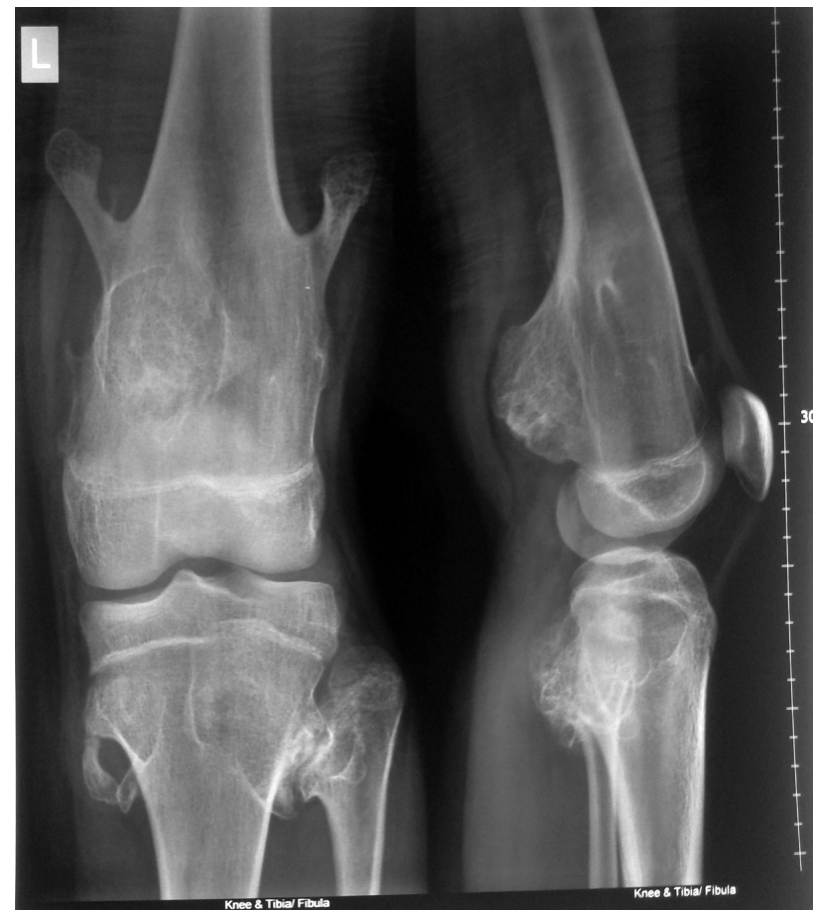Sessile (wide based)



Osteochondroma

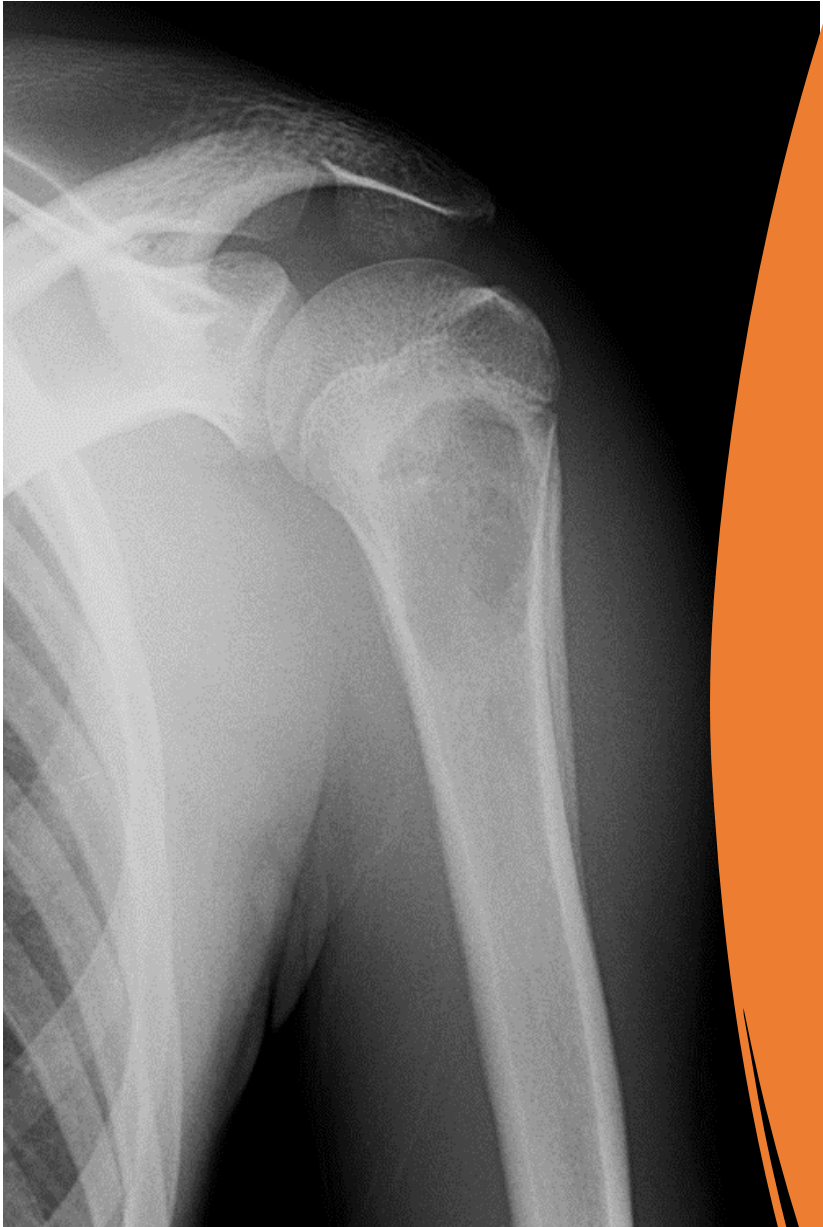- Treatment: observe if asymptomatic, otherwise resection.
- Multiple hereditary exostoses (MHE) is autosomal dominant and causes multiple deformities
- There is a higher risk of malignant transformation.

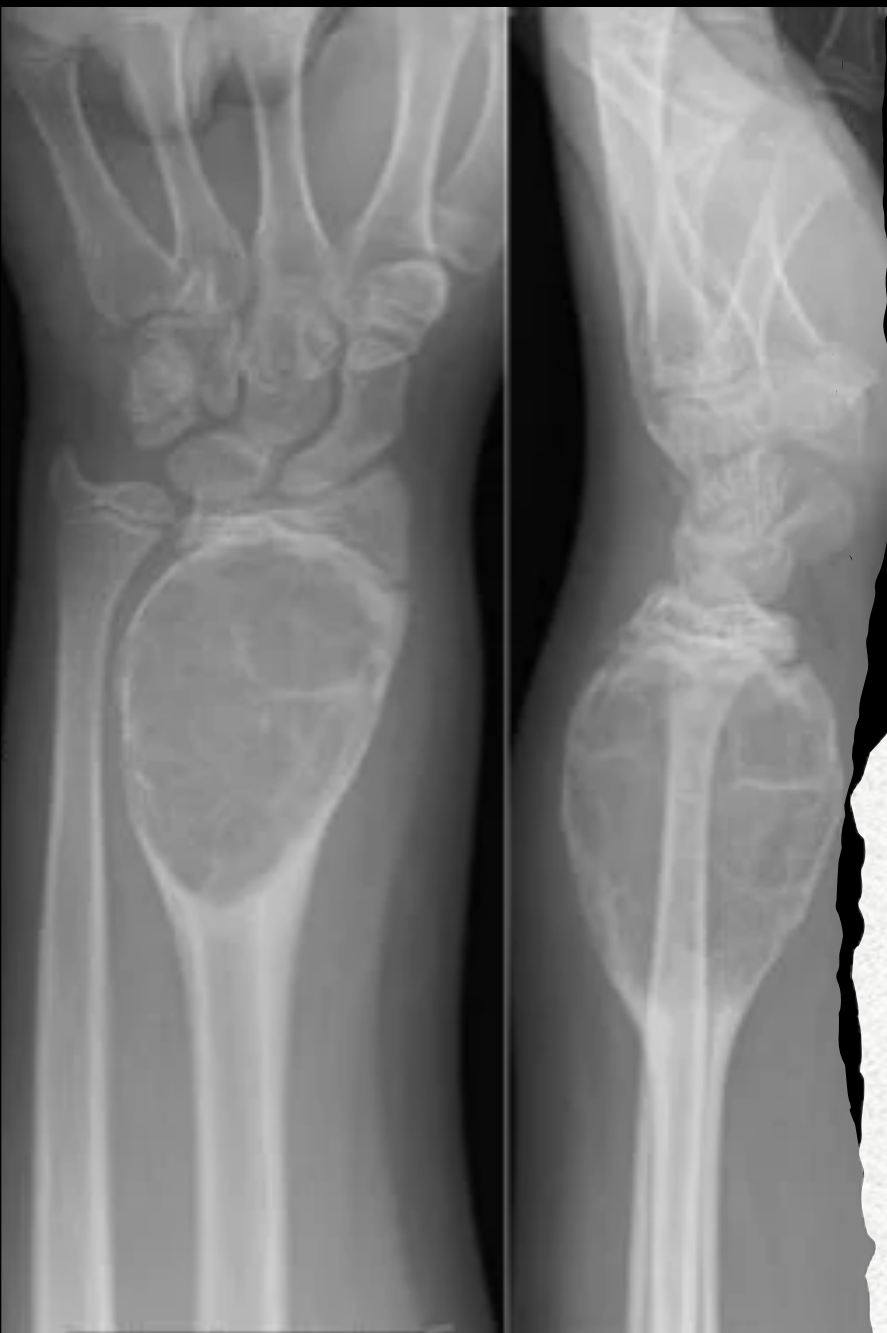MHE



Simple Bone Cyst

- Not a true cyst (fibrous lining) filled with clear fluid. Not neoplastic.
- Notice the well defined central purely lytic lesion.
- Occurs in children, very rare in adults.
- Most commonly in proximal humerus and proximal femur.
- Susceptible to fractures.
- Treatment: humerus observe or inject with steroids, femur curettage, grafting and instrumentation (high risk of fracture).



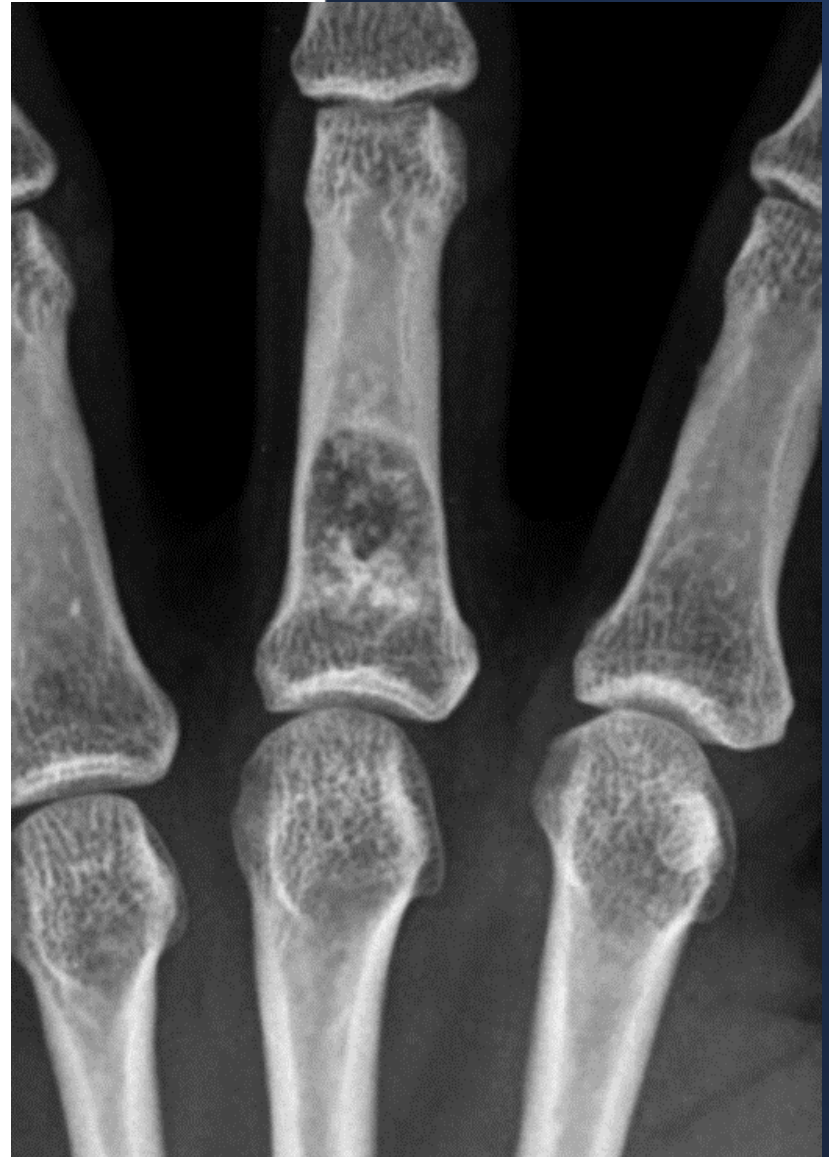

Aneurysmal Bone Cyst

- Now considered a tumor as a genetic translocation was discovered.
- Notice the well defined multiloculated lytic lesion causing significant ballooning and thinning of the cortex.
- Can be primary or secondary to other tumors.
- No risk of malignancy but growing lesion.
- Treatment: curettage and grafting.

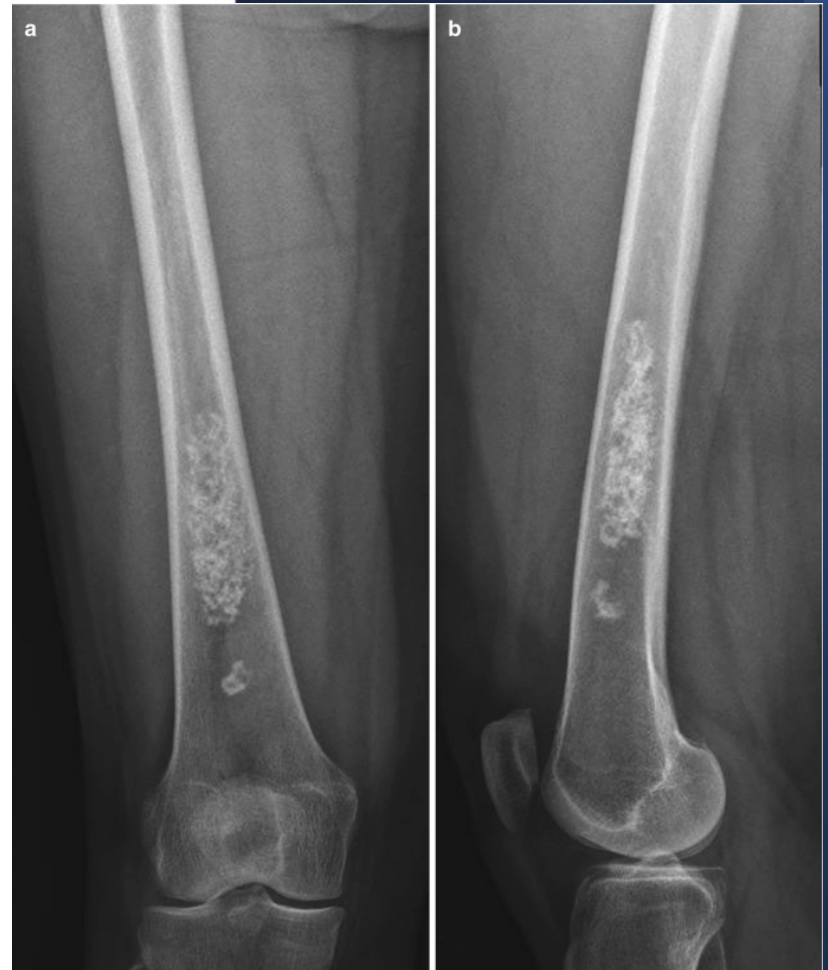Chondroma (Enchondroma)

- The most common benign bone lesion of the hand.
- Well defined lytic lesion with coarse calcifications (stippled/ popcorn).
- The cortex is thin → fracture.
- Benign and asymptomatic.



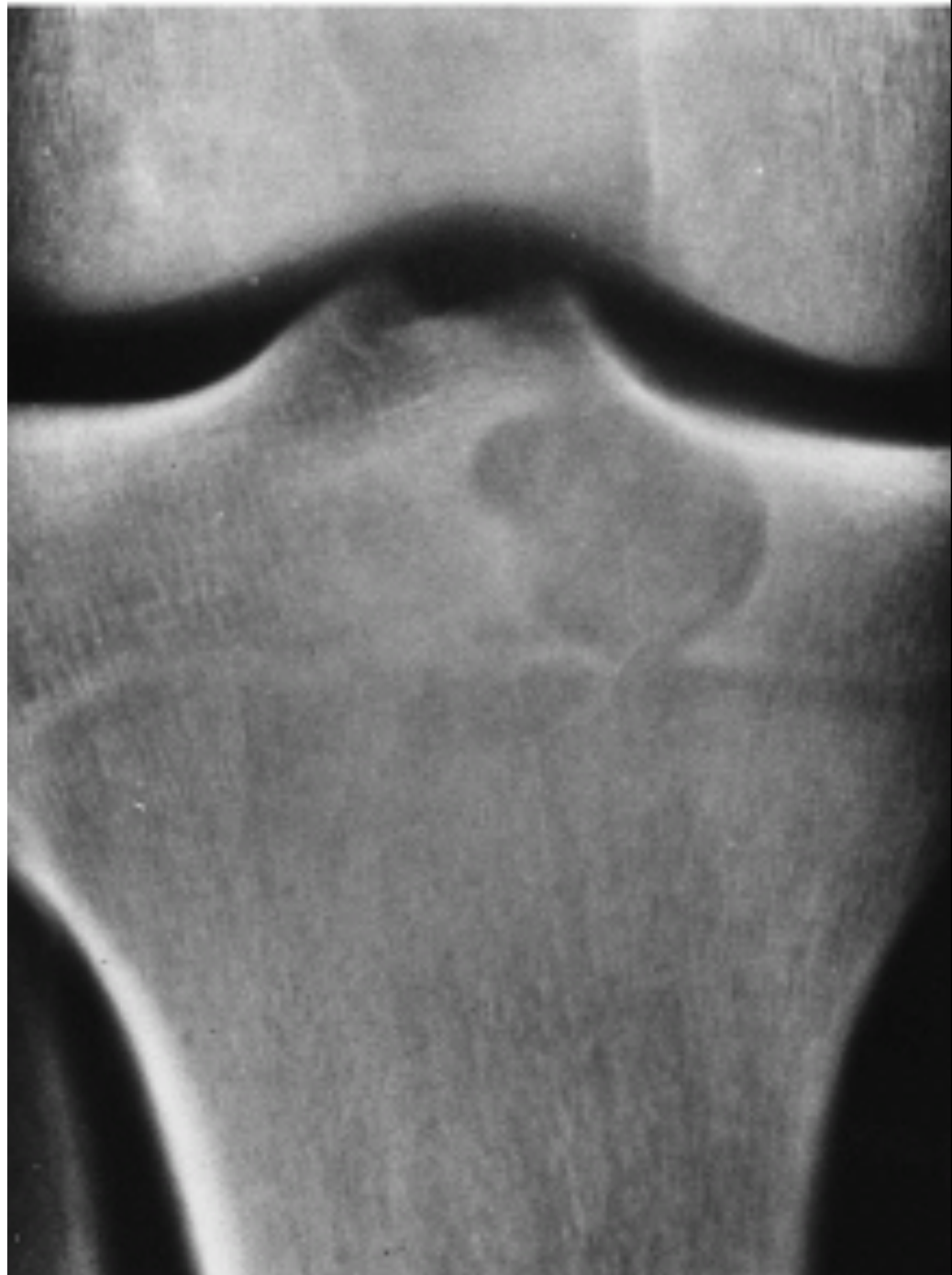Chondroma (Enchondroma)

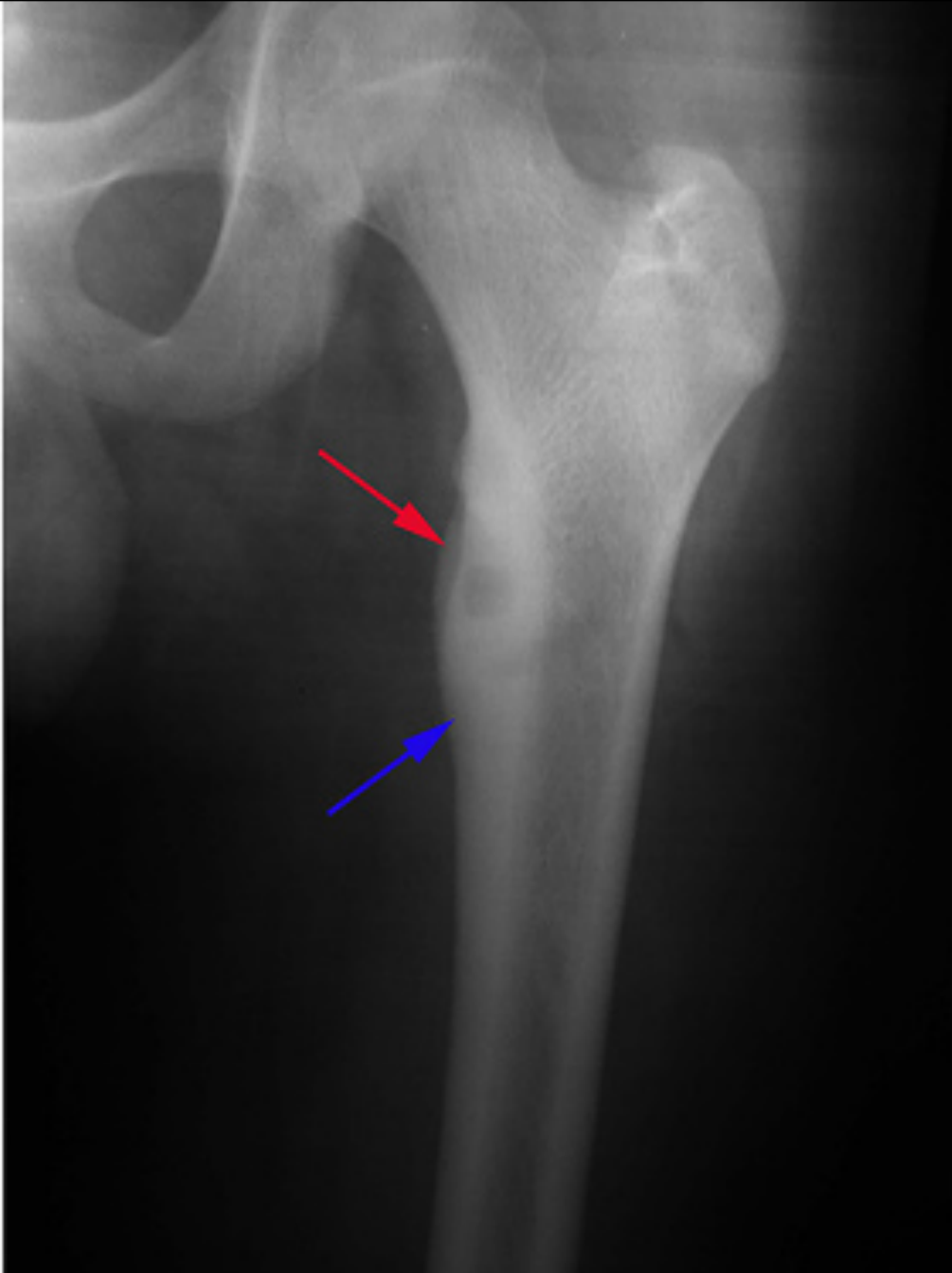
- Can occur in any bone.
- Note the florid popcorn calcifications in the distal femur, the lytic background is barely seen.
- Usually an incidental finding unless fractured.
- Treatment in the hand is curettage and grafting (high risk fracture).
- Elsewhere observe.



Chondroblastoma

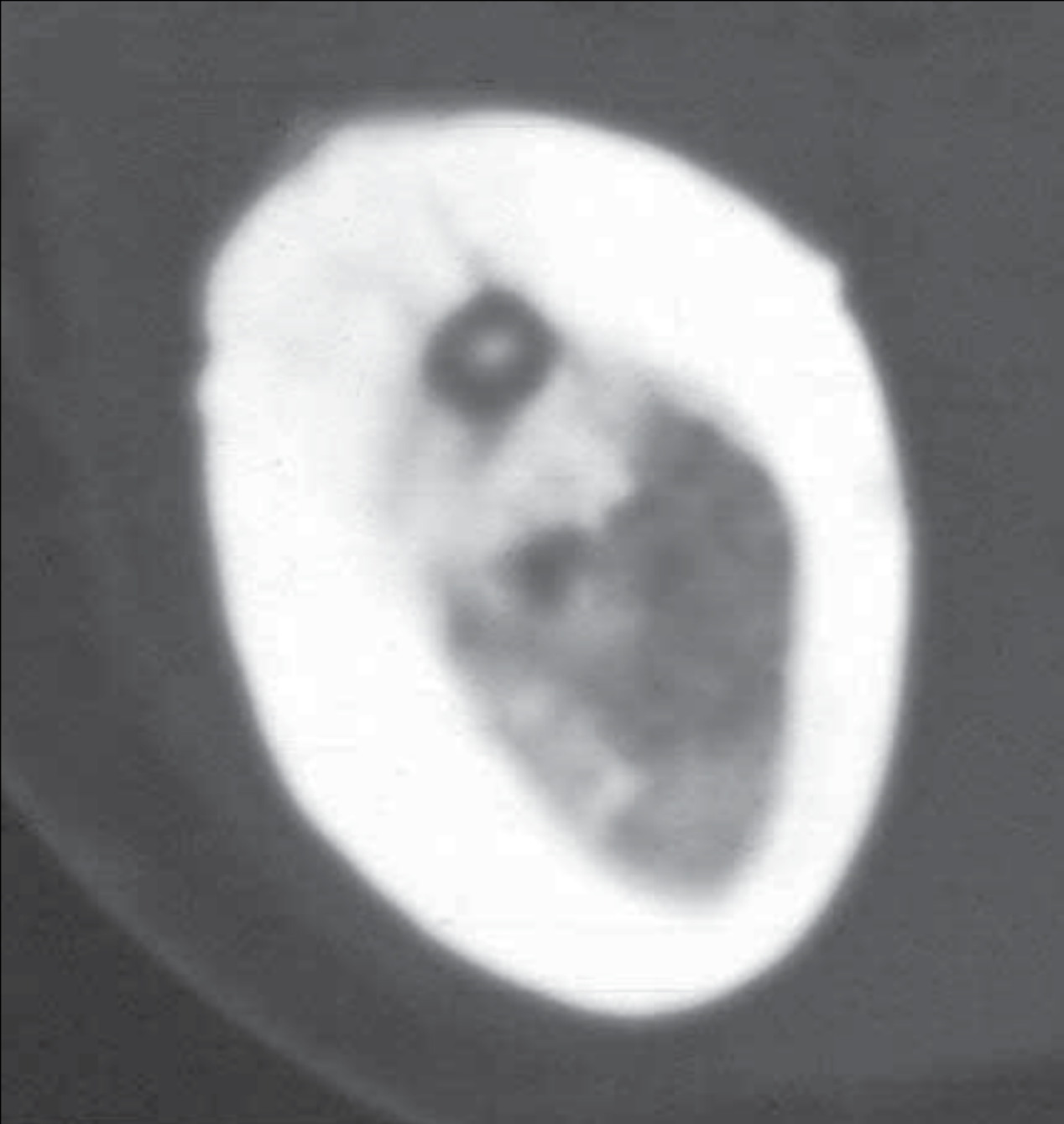
- Notice the well defined lytic lesion in the **epiphysis** of the proximal tibia, with some coarse calcifications.
- Patients usually present with pain, stiffness, and effusion.
- This lesion occurs in the **epiphysis of the immature skeleton**.
- Treatment is curettage and grafting.





Osteoid Osteoma

- A completely benign lesion that can occur anywhere in the bone.
- Note the small well defined lytic lesion (nidus) surrounded by thick sclerosis.
- Presents with pain especially at night. It responds to NSAID's but not paracetamol.
- This is explained by the release of prostaglandins from the tumor.
- The inflammation also explains the reactive sclerosis.



Osteoid Osteoma

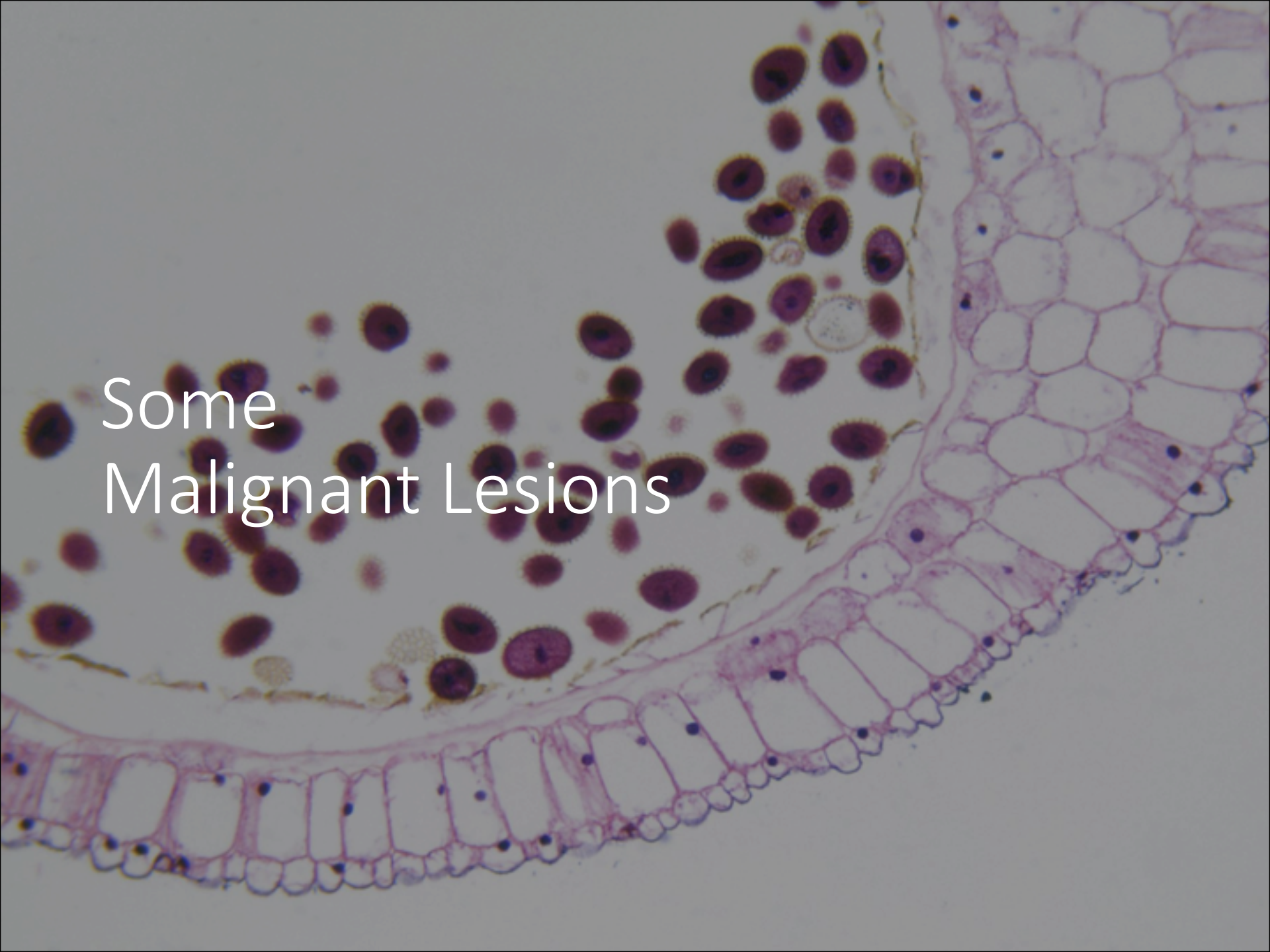- The nidus is smaller than 1.5 cm by definition.
- If not seen on the x-ray, a thin cut CT is performed (see picture).
- Treatment was classically surgical resection of the nidus.
- Recently it is treated by radiofrequency ablation of the nidus.



Giant Cell Tumor


- Notice the purely lytic well defined lesion in the subchondral area of the distal femur.
- This is a benign but usually aggressive lesion.
- It occurs in the **“epiphysis” of the mature skeleton.**
- High risk for fracture if around the knee.
- Treatment is curettage and cementing +/- instrumentation.

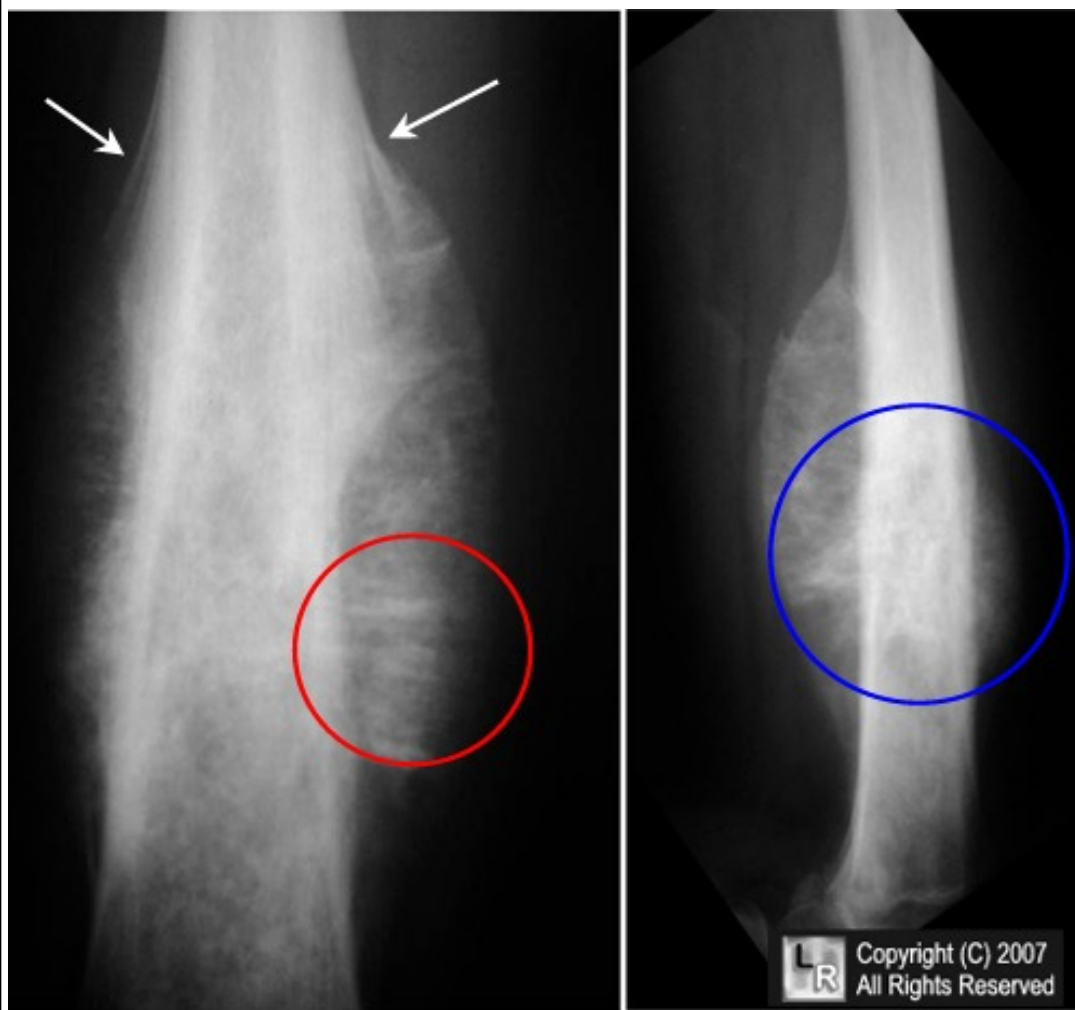
Some
Malignant Lesions



General Features

- Rapid growth, warmth, and tenderness.
- Have periosteal reaction on x-rays:
 - Codman's triangle (periosteal elevation).
 - Sunburst pattern/Sunrays appearance.
 - Onion skin appearance (Ewing's sarcoma).

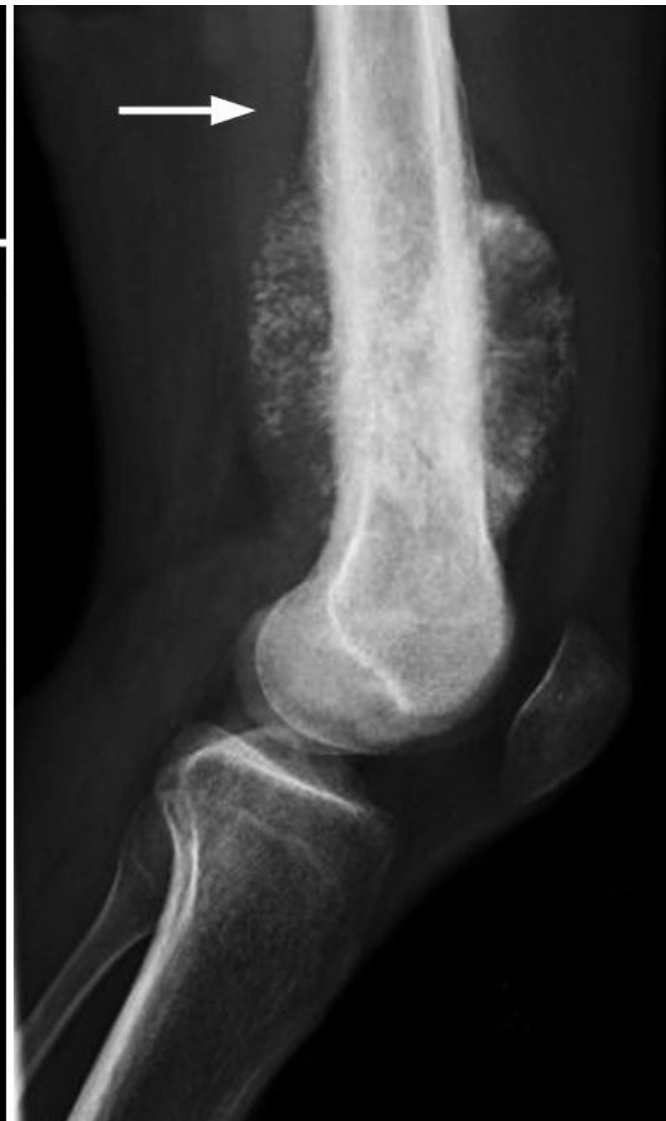
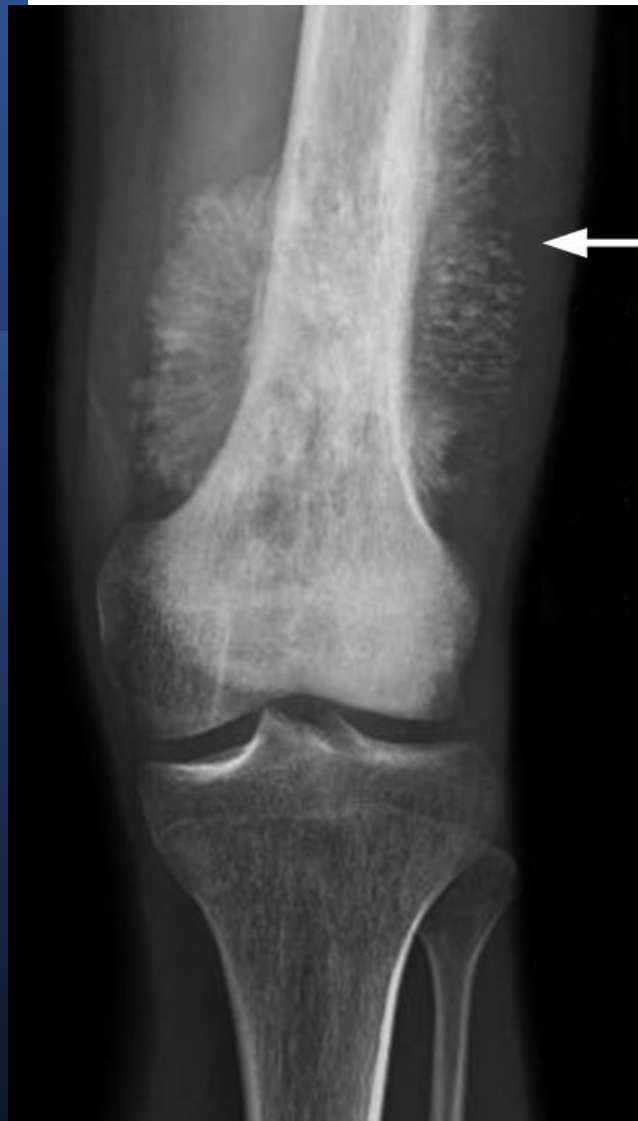


Osteosarcoma

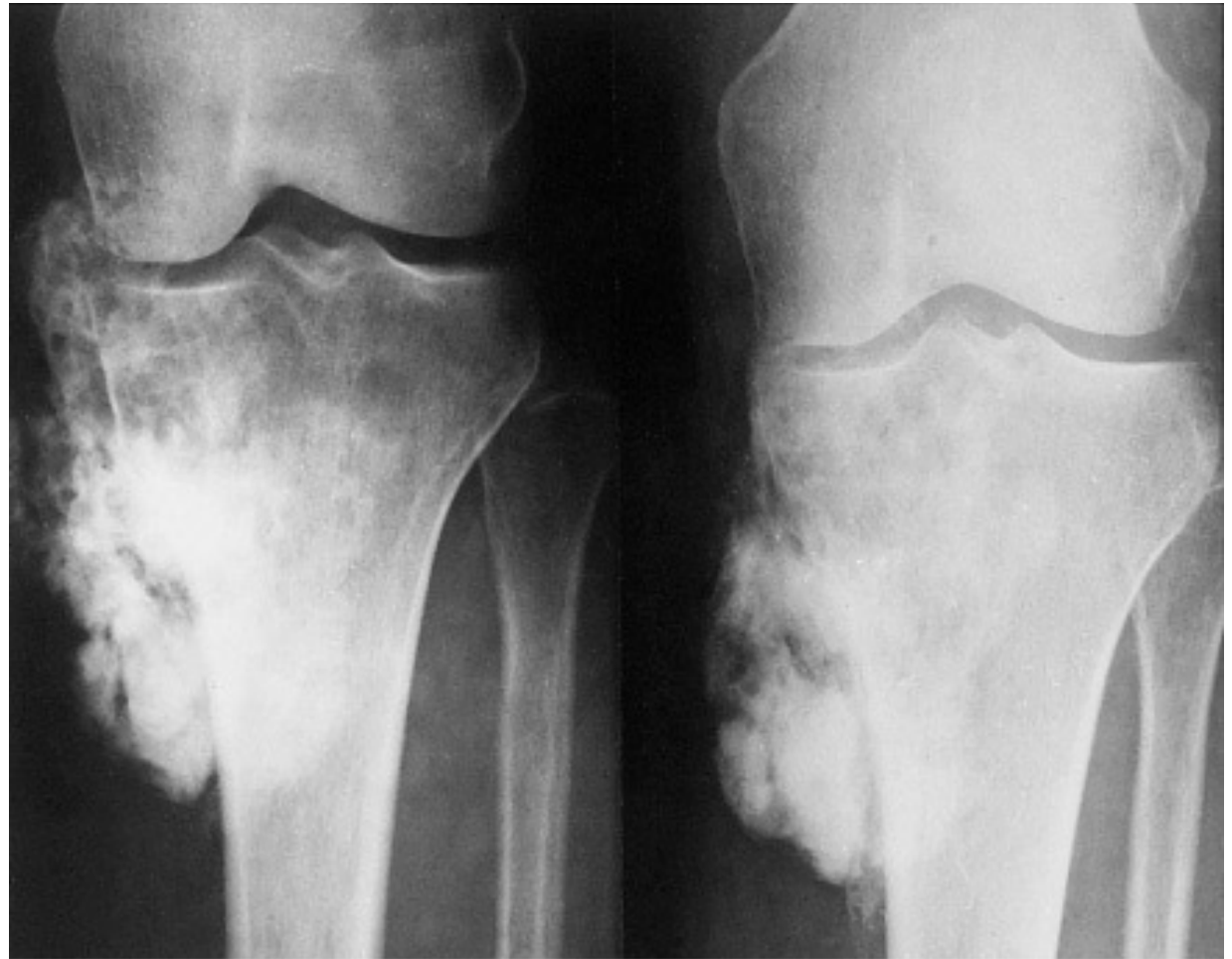- Typically occurs in the metaphysis around the knee in adolescents.
- Classically high grade lesions.
- Note the sunray appearance (red and green circles).
- Note also Codman's triangle (arrows).

Osteosarcoma



Osteosarcoma

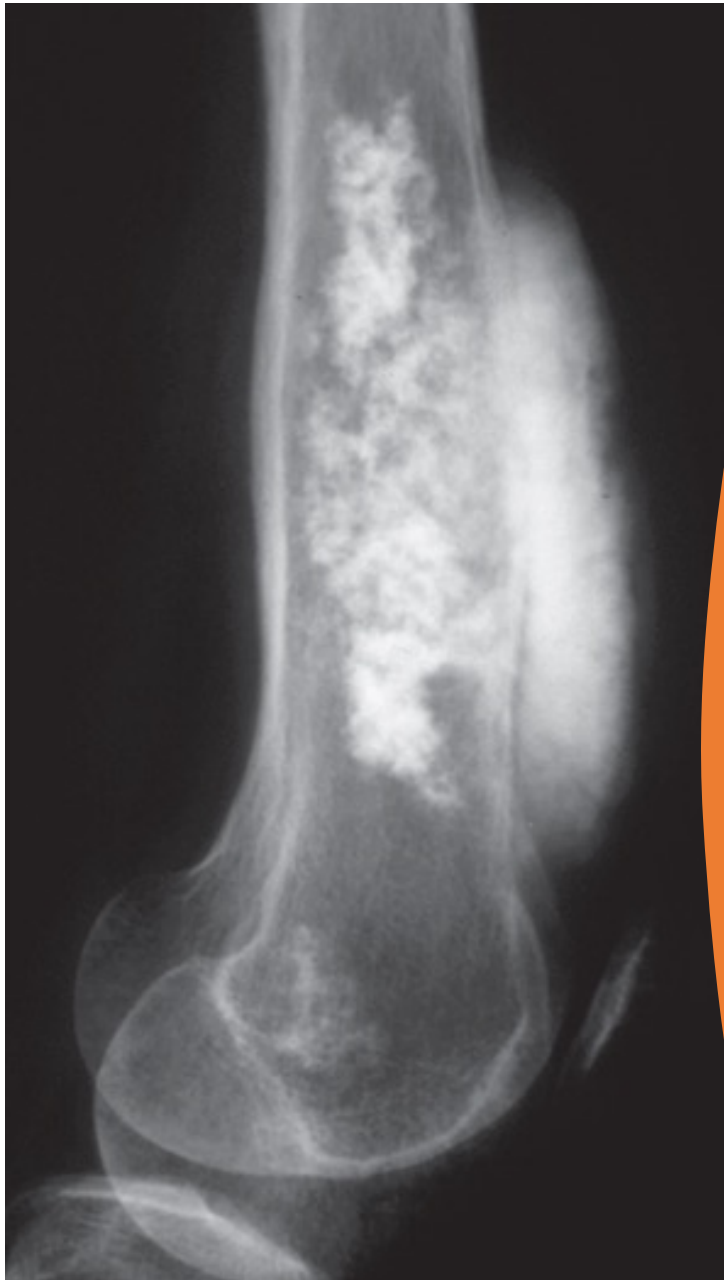- Notice the ill defined margins of this mainly sclerotic lesion.
- Note also the solid periosteal reaction.



Osteosarcoma

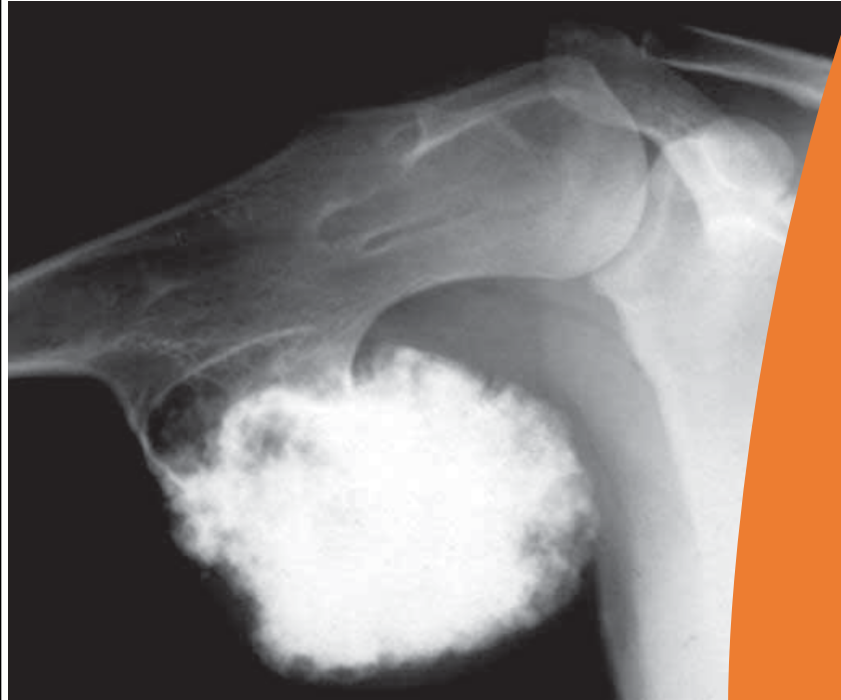
- Notice the tumor crossing the growth plate to the epiphysis.
- Note the cortical destruction and extension into the soft tissue.
- Note the periosteal elevation (Codman's triangle) at the proximal end of the tumor.





Chondrosarcoma

- Occur in adults.
- These are usually low grade lesions, so they do not respond to chemo- or radiotherapy.
- The first type is primary (central) arising de novo in the medullary canal.
- Notice the irregular coarse calcifications with tumor extension outside the bone.

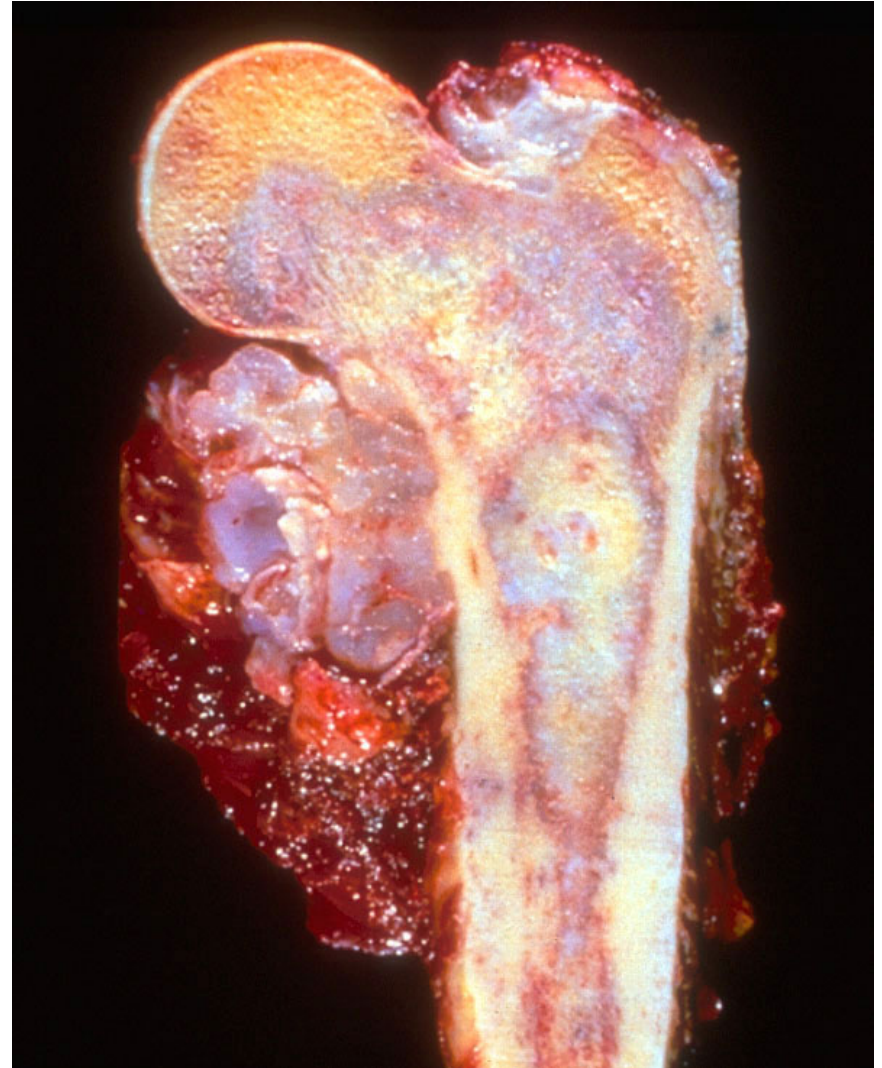


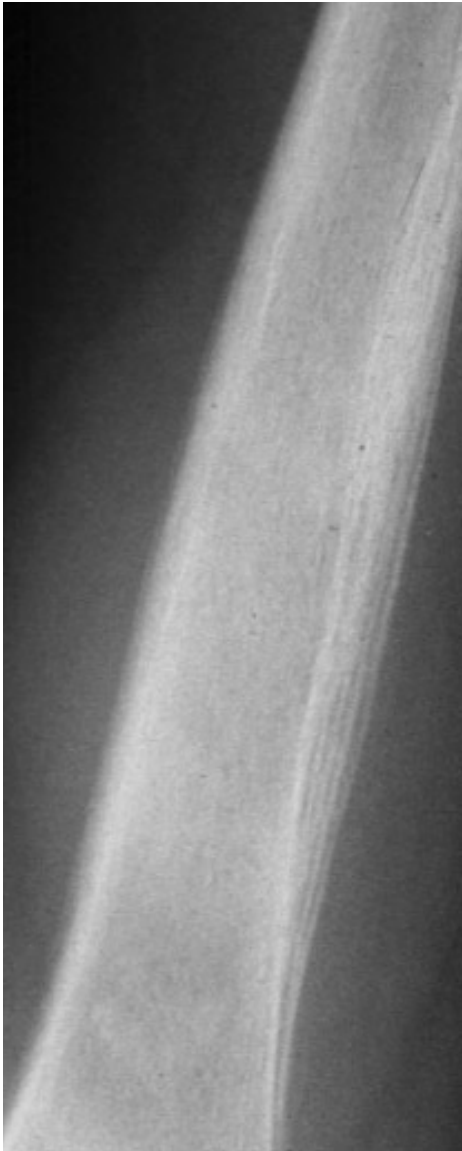
Chondrosarcoma

- The second type is secondary (peripheral), arising from a pre-existing osteochondroma.
- Note the large amount of calcification on top of the bony prominence.

Chondrosarcoma

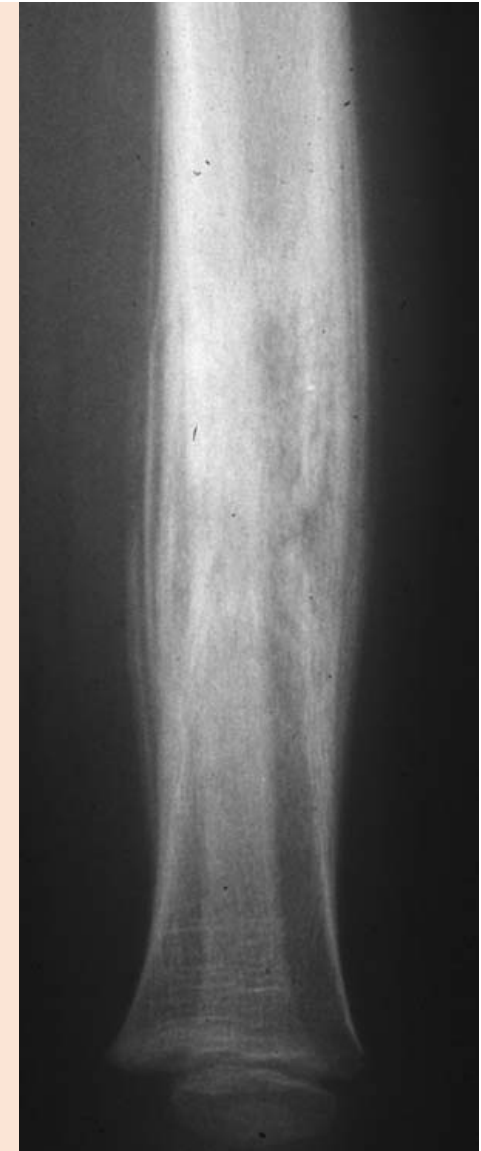- Notice the gross silvery appearance of the tumor.
- This specimen has involvement of the soft tissue.



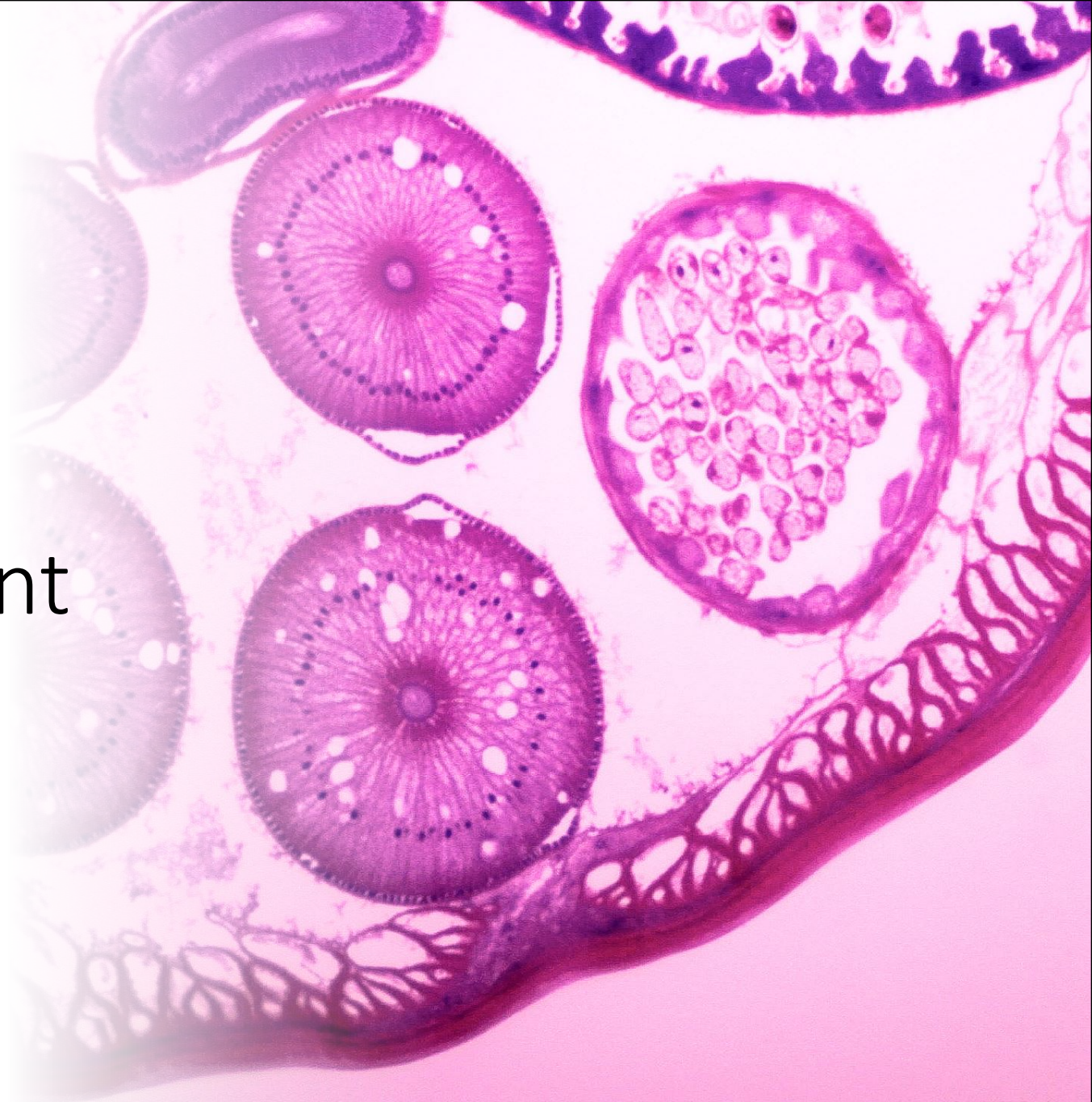

Ewing's sarcoma

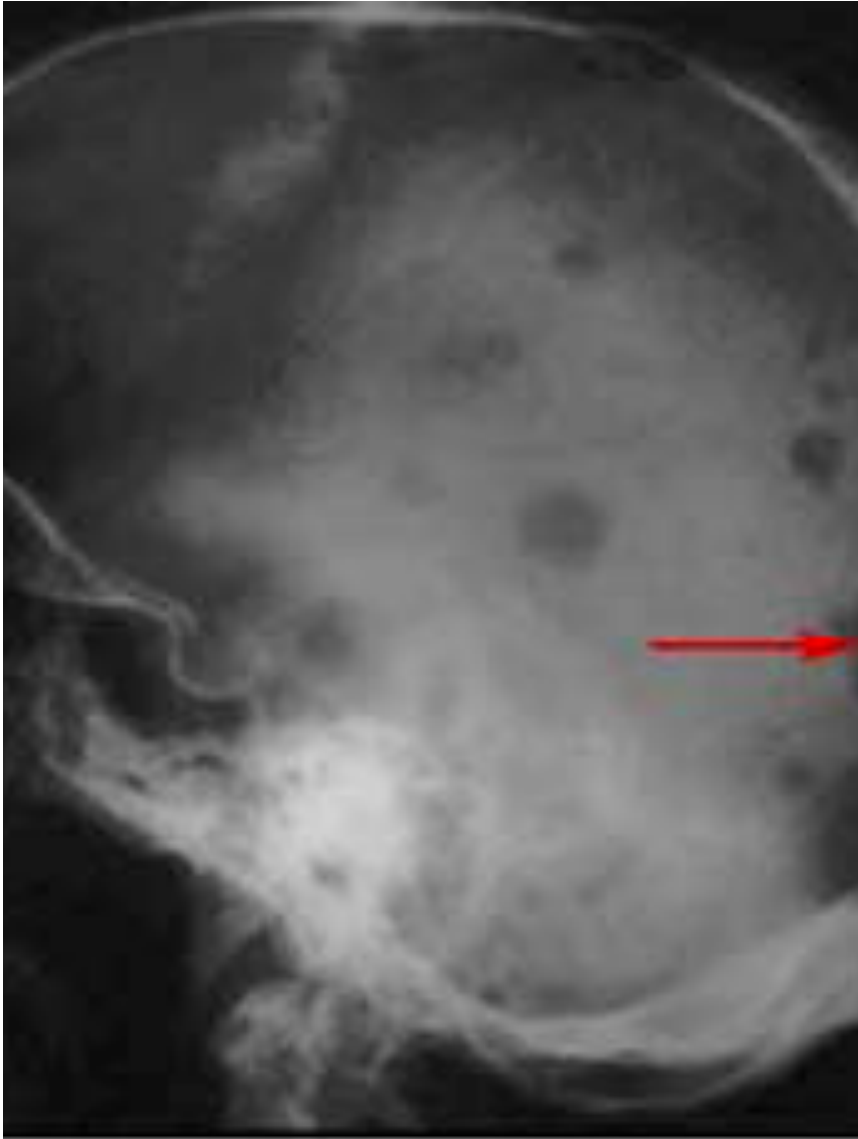
- Typically occurs in the shaft of very young patients (1st and 2nd decades).
- May have constitutional symptoms.
- Radio- and chemo-sensitive.
 - Notice the onion skin periosteal reaction.



Other
Malignant
Lesions



Multiple Myeloma



- Usually referred from oncologists after diagnosis.
- Note the purely lytic punched out lesions.
- 30% are cold on bone scan so imaging modality of choice is x-rays.
- Treatment is medical.
- Surgical treatment addresses complications such as fractures or impending fractures.

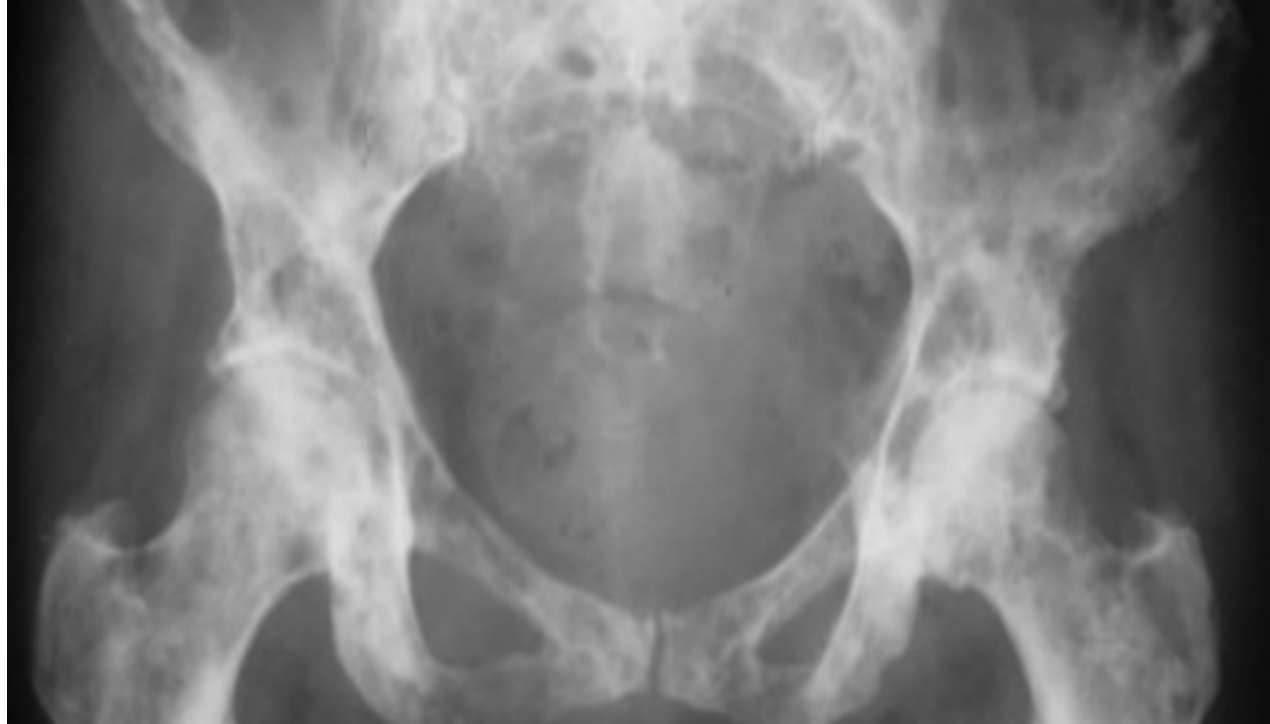

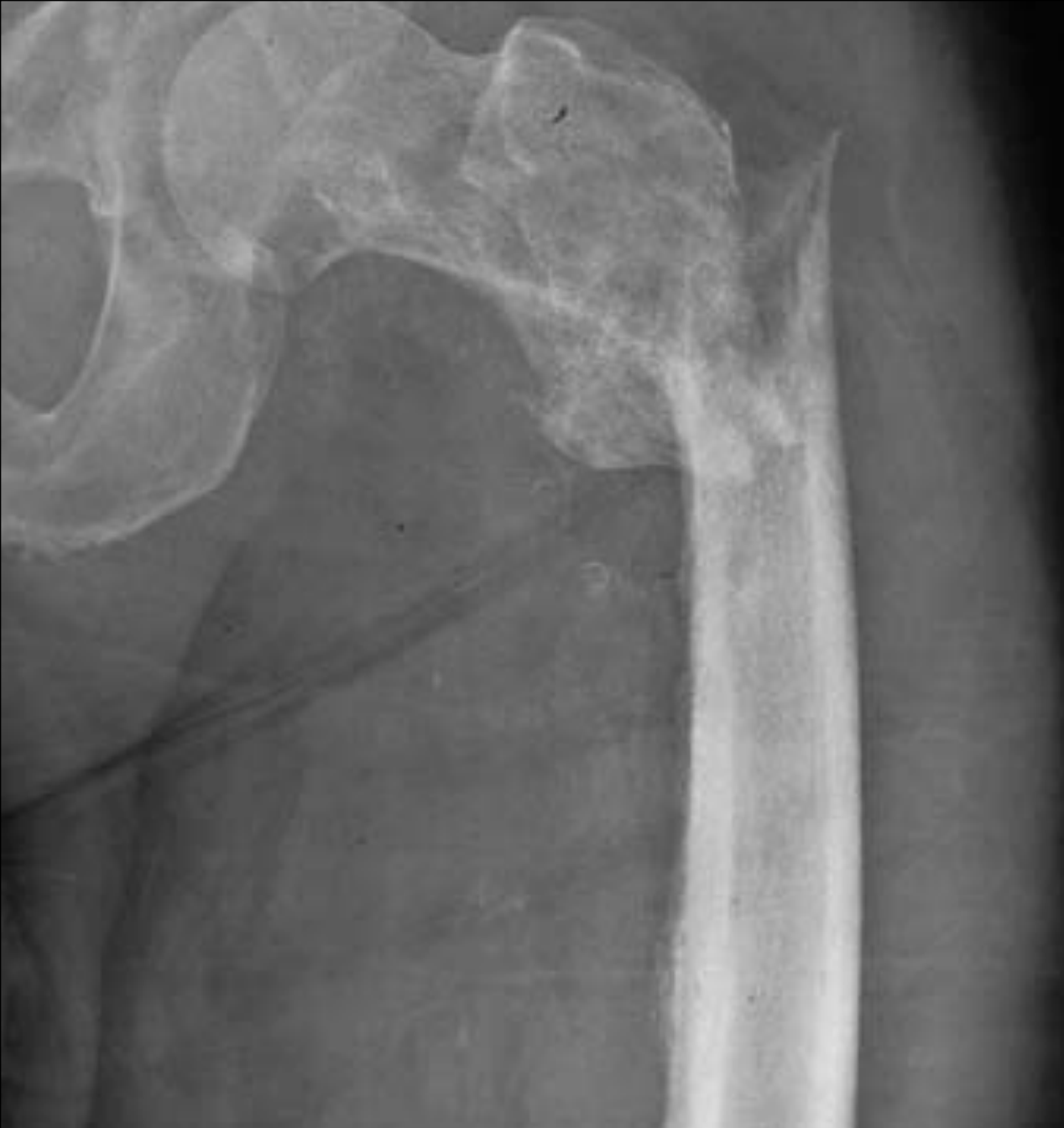Secondary Tumors (Metastases)

- More common than primary lesions.
- Occur mainly after the fifth decade.
- Usually in the axial skeleton.
- Most commonly from:
 - Lung: lytic lesions, can occur distal to the knee or elbow, poor prognosis.
 - Breast: mixed lesions, relatively good prognosis.
 - Prostate: sclerotic lesions, good prognosis.
 - Kidney: lytic hypervascular lesions.
 - Thyroid: poor prognosis.

Secondary Tumors (Metastases)

- Multiple lytic lesions in the pelvis and femurs.





Secondary Tumors (Metastases)

- A pathological proximal femur fracture through a lytic lesion.
- Here the proper evaluation of the lesion takes precedence over fracture treatment.

Secondary Tumors (Metastases)

- A bone scan showing multiple hot lesion throughout the axial skeleton.
- Each lesion should be x-rayed and evaluated for risk of fracture (especially in the proximal femur).

