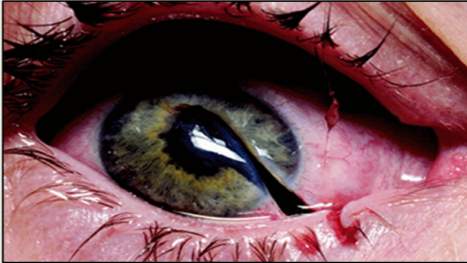

EYE INJURIES

Open globe laceration with a teardrop pupil



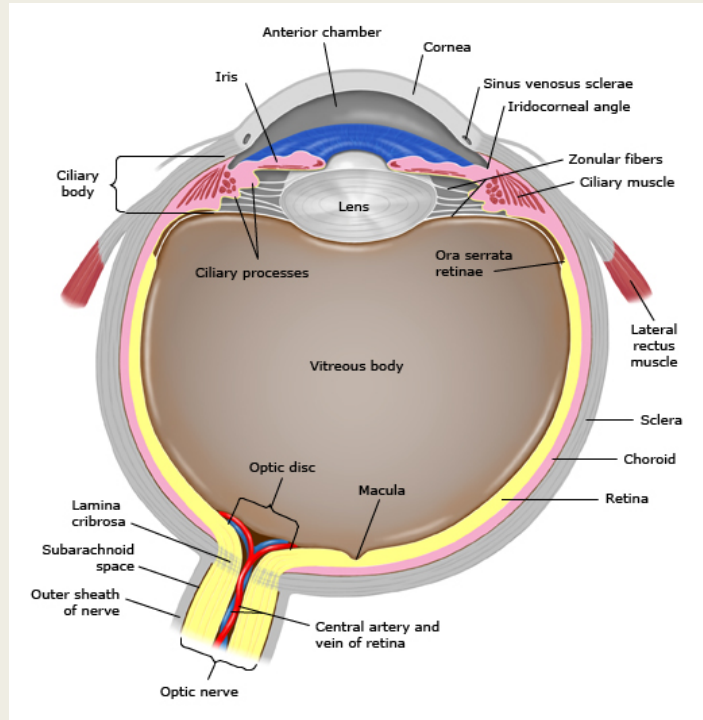
Dr Mouna Al Saad

Introduction

- The eyes are well protected, yet they are subject to injury.
- Eyes are located near vital regions such as the intracranial space, the cervical spine, and the airway.
- Life-threatening injuries need to be considered first.
- Eye injury includes trauma to the eye (ocular trauma), the orbit (periocular trauma), or both.
- Threats to vision need to be identified using a focused history and P/E.

Anatomy

- The eye is composed of three layers:
 - The external fibrous layer or outer wall (cornea and sclera)
 - The middle vascular layer (choroid, ciliary body, and iris)
 - The internal layer (retina)



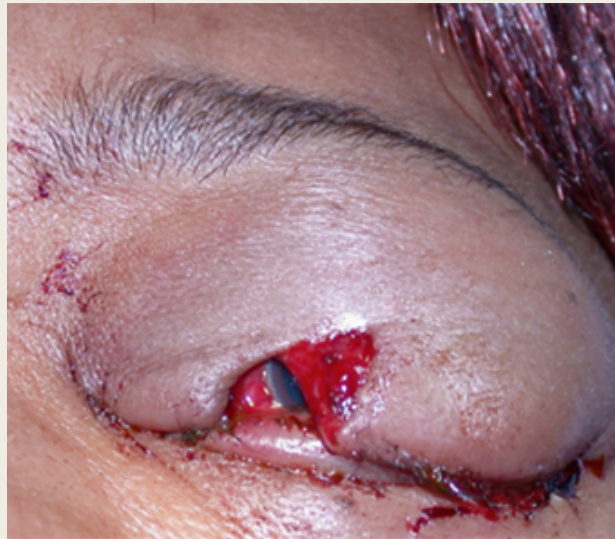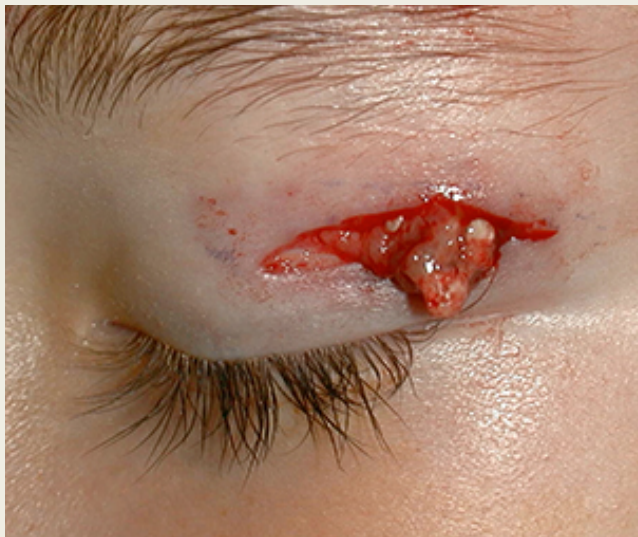Common eye injuries

- Eyelid lacerations
- Corneal abrasions and corneal foreign bodies
- Conjunctival injuries.
- Orbital fractures

below the eyebrow is the ophthalmologist's job
not for training, due to functional cosmetic wise

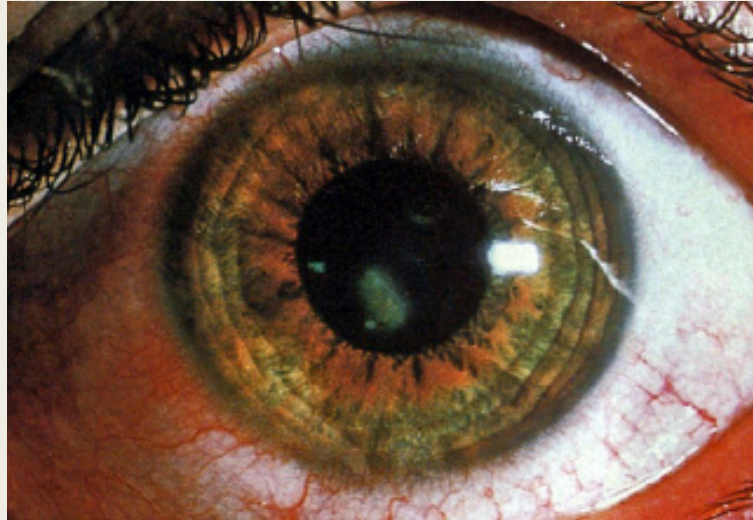Eyelid lacerations

- Ocular injury may accompany eyelid laceration in up to two-thirds of cases.
- **Types of eyelid lacerations:**
 - Full-thickness laceration of the eyelid
 - Lacerations with orbital fat prolapse
 - Lacerations through the lid margin
 - Lacerations involving the tear drainage system.
 - Lacerations with poor alignment and/or avulsion

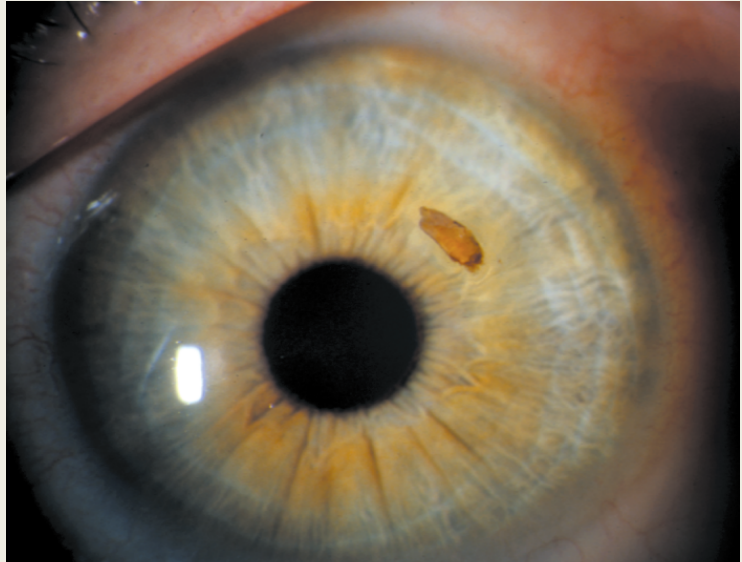

Corneal abrasions and corneal foreign bodies

- **Corneal abrasion:**
- Loss of the epithelial layer
 - Severe eye pain
 - Reluctance to open the eye due to photophobia
 - Foreign body sensation.
 - Normal visual acuity
 - Normal pupillary response
 - Staining defect on fluorescein examination



Corneal foreign bodies



Vision-threatening conditions

- Ocular chemical burns
- Orbital compartment syndrome
- Open globe injury
- Traumatic hyphema
- Vitreous haemorrhage
- Retinal trauma
- Optic nerve injury
- Periocular injuries that threaten vision

Ocular chemical burns

- Eye contact with acids or alkalis.
- Emergent evaluation and treatment to prevent permanent vision loss.
- Alkaline substances usually cause more severe damage than acids.

Patients present with:

Decreased vision

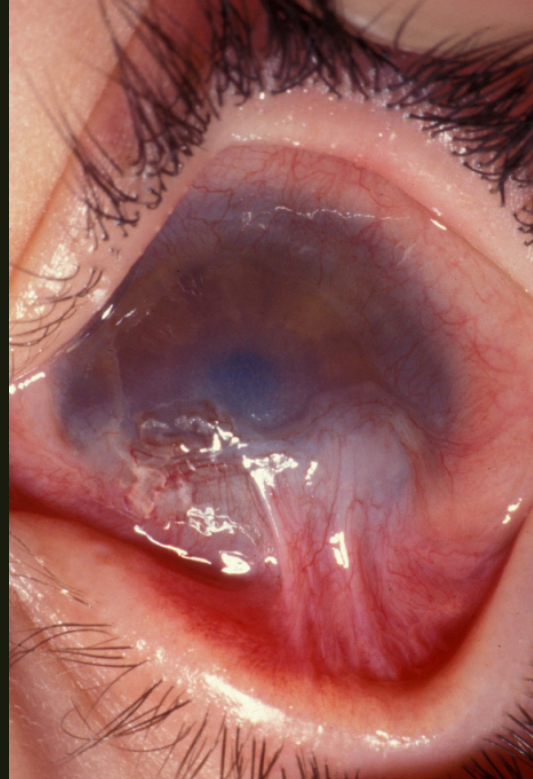
Moderate to severe eye pain,

Blepharospasm (inability to open the eyelids),

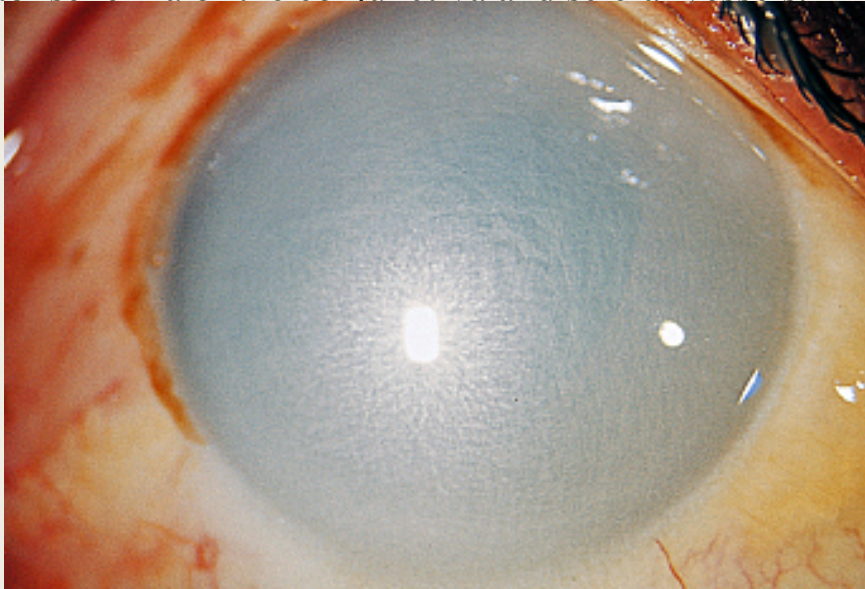
Symblepharon (lid attached to globe)

Conjunctival redness.

Photophobia



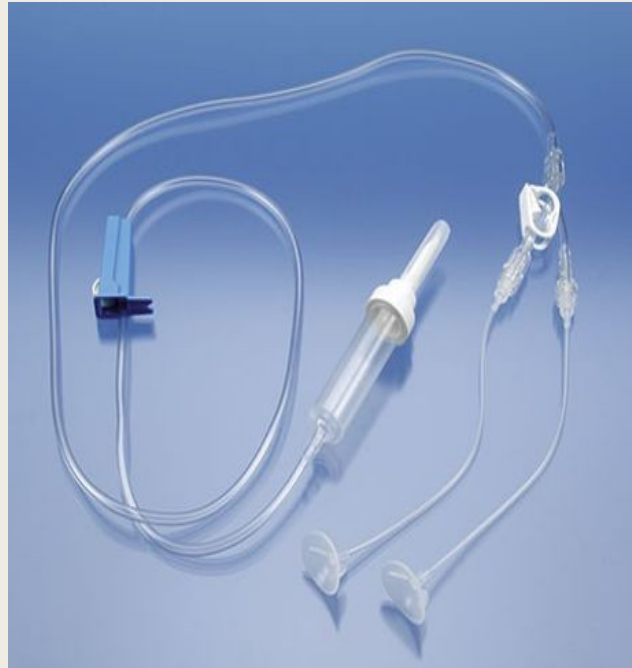- In severe cases of alkali exposure, the eye may appear white.
- Due to ischemia of the conjunctiva and scleral vessels.



ischemia is present
in 4 quadrants
→ cornea is damaged

Management

- Continuous irrigation with water or saline is recommended.
- Neutral pH in the eye must be achieved, usually takes 30 to 60 minutes.
- Morgan lens can be used.
- Irrigation should be less forceful if a concomitant globe rupture is suspected.

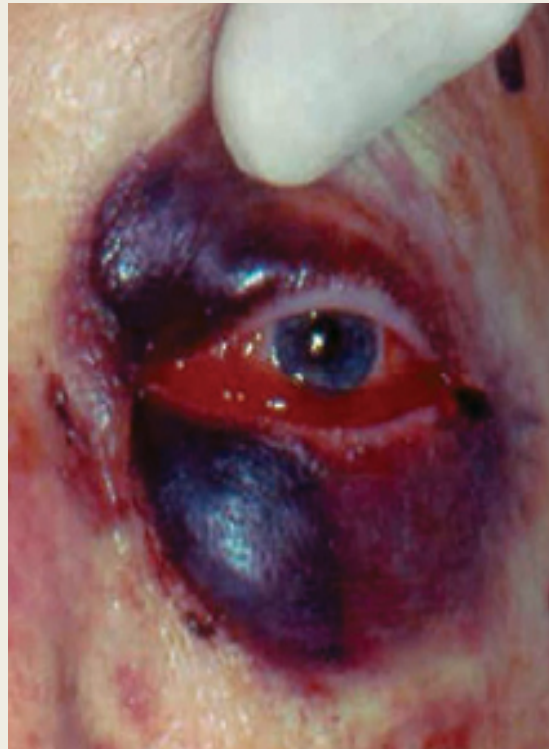


Orbital compartment syndrome

- True ophthalmologic emergency, requiring immediate intervention
- The orbit is a confined space with its surrounding bony walls
- Trauma and intraorbital hemorrhage cause rapidly elevated intraorbital pressure.
- Pressure is transmitted to the eye and optic nerve causing ischemia and an orbital compartment syndrome (OCS).
- It is diagnosed clinically.

Signs & Symptoms

- Acute onset of decreased vision
- Diplopia
- Eye pain
- Periorbital swelling/ hemorrhage
- Subconjunctival hemorrhage
- Chemosis
- Proptosis
- Ophthalmoplegia
- Afferent pupillary defect
- Tightness of the eyelids
- Decreased retropulsion (resistance to attempts to push the eye farther back into the orbit).



Management

- Decompression should NOT be delayed
- Lateral canthotomy and inferior cantholysis.
- Evaluation for and management of coagulopathy and orbital imaging (CT or MRI)
- MRI is contraindicated if a metallic intra-orbital or intraocular foreign body is suspected.

Additional management:

- Elevation of the head of the bed to at least 45 degrees
- Management of increased intraocular pressure
- Pain control
- Correction of any coagulopathy and/or cessation of anticoagulant therapy
- Prevention of sudden increased intraorbital pressure by:
 - Cough suppression
 - Antiemetic therapy (eg, ondansetron)
 - Stool softeners to prevent excess straining with bowel movements
- Hospitalization and definitive management of the underlying cause of OCS

Open globe injuries:

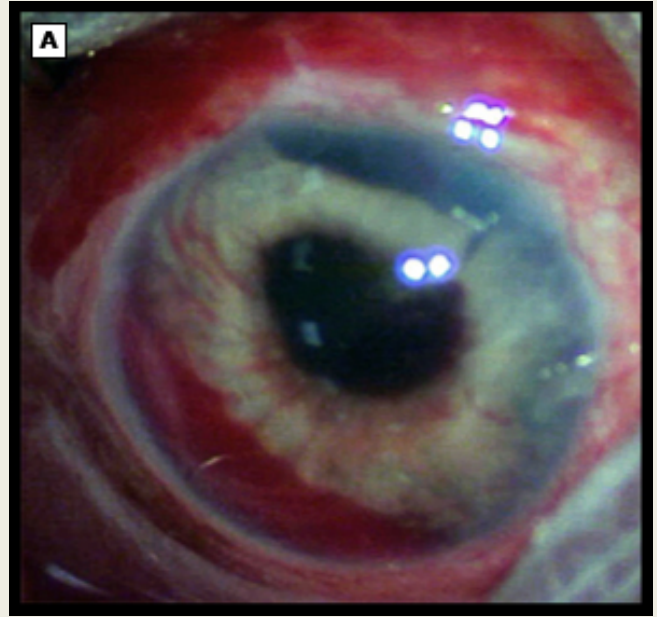
- **Open globe rupture:** Occurs following blunt eye injury.
- **Open globe laceration:** Refers to a penetrating injury to the eye by a sharp object.
 - penetrating (entry wound but no exit wound)
 - perforating (entry and exit wounds)
 - Corneal laceration
 - Corneal-scleral laceration
 - Scleral laceration

Signs & Symptoms:

- Markedly decreased visual acuity
- Relative afferent pupillary defect
- Eccentric or teardrop pupil.
- Extrusion of vitreous
- External prolapse of the uvea (iris, ciliary body, or choroid) or other internal ocular structures
- Tenting of the cornea or sclera at the site of globe puncture
- Low intraocular pressure (checked by an ophthalmologist only)
- Seidel sign

Blunt injury to the eye with:

- Subconjunctival hemorrhage superiorly
- Conjunctival laceration
- Hyphema (blood in the anterior chamber)
- Iridodialysis (separation of the iris from its insertion at the ciliary body) superiorly.

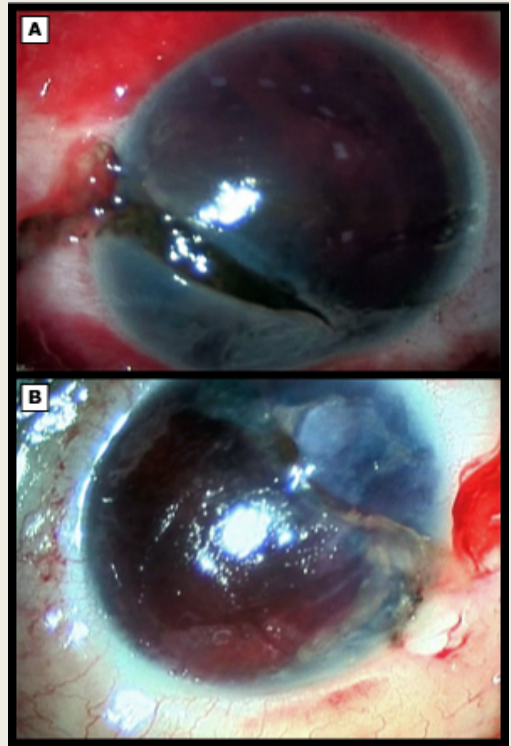


Penetrating Injury with:

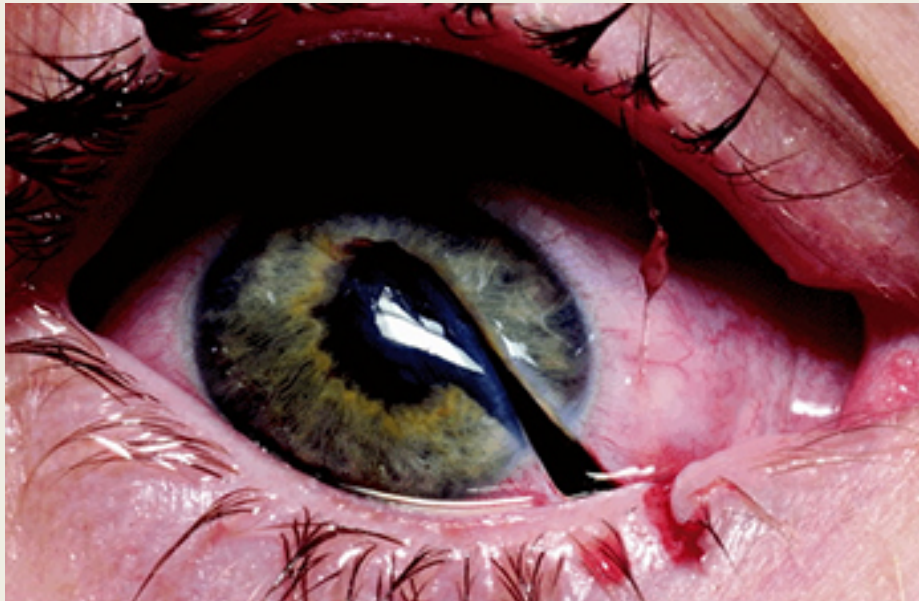- Full thickness corneal laceration from a fragment of glass.
- Uveal tissue and aqueous are seen prolapsing through the wound.

management → do not touch it, put eye shield

* CT scan is a diagnostic tool for eye globe injuries



Open globe laceration with a teardrop pupil



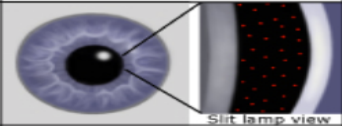




Management:

- Urgent ophthalmologic evaluation
- NPO state
- Prophylactic antibiotics to avoid posttraumatic endophthalmitis (Broad spectrum)
- Tetanus prophylaxis for ocular lacerations
- Rapid primary closure of an open globe injury, ideally within 24 hrs
- Rapid closure promotes the best visual outcome

Traumatic hyphema

- Grossly visible blood in the anterior chamber of the eye.
(macroscopic Hyphema)
- Microhyphema describes dispersed red blood cells in the anterior chamber that do not layer out to form a gross fluid level
- The anterior chamber is anatomically defined as the space bordered by the cornea, iris, angle, and the lens.
- Bleeding results from tears in the vessels of the ciliary body or iris.
- Caused by blunt trauma to the eye or high energy blow to the eye.

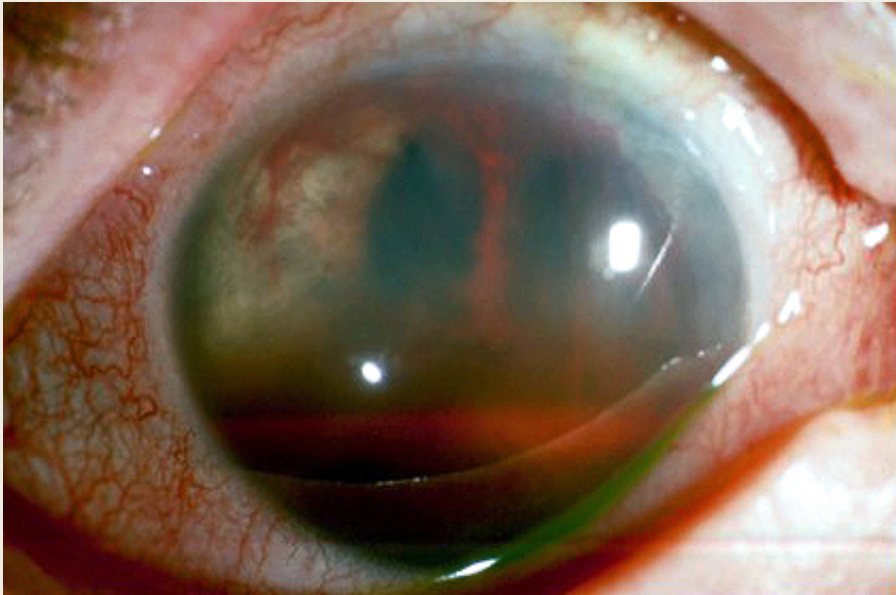
Traumatic hyphema: Grading and prognosis R/O

Grade	Anterior chamber filling	Diagram	Best prognosis for 20/50 vision or better
Microhyphema	Circulating red blood cells by slit lamp exam only		90 percent
I	<33 percent		90 percent
II	33-50 percent		70 percent
III	>50 percent		50 percent
IV	100 percent		50 percent

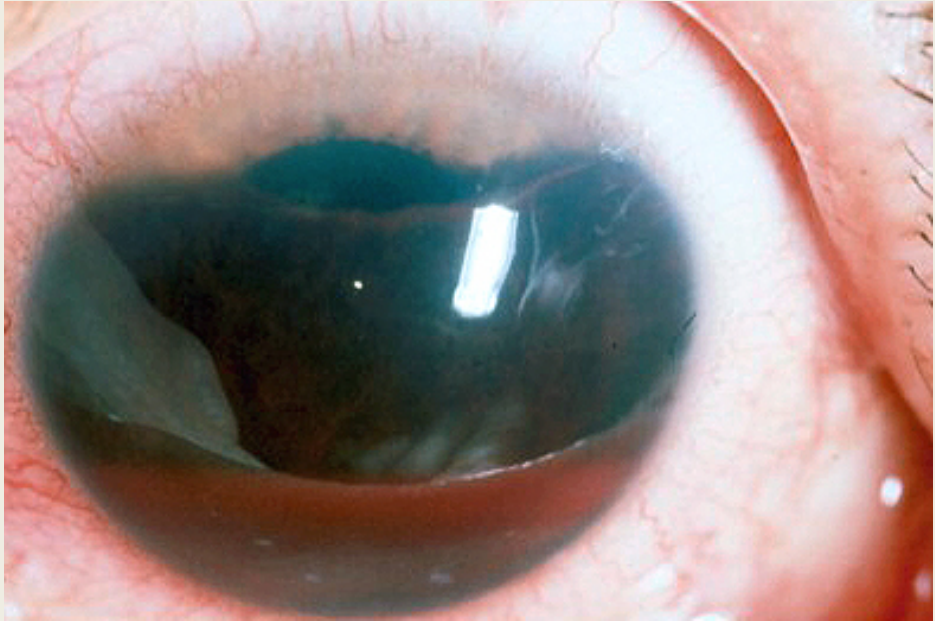
Signs & Symptoms:

- Grossly apparent layer of blood using a penlight.
- Microhyphema, detected by split lamp.
- Photophobia
- Decreased visual acuity
- Anisocoria
- Iridodialysis (tearing of the iris away from its insertion)
- Increased intraocular pressure

- Grade I to II hyphema inferiorly
- Active bleeding from the superior iris.



- Grade IV hyphema following blunt trauma.



Management:

Preventing secondary hemorrhage and intraocular hypertension, Glaucoma and corneal blood staining by:

- Monitoring of intraocular pressure
- Eye Shield
- Limitation of activity
- Cycloplegia to manage pain
- Glucocorticoid eye drops, to lower the risk of rebleeding.

Management:

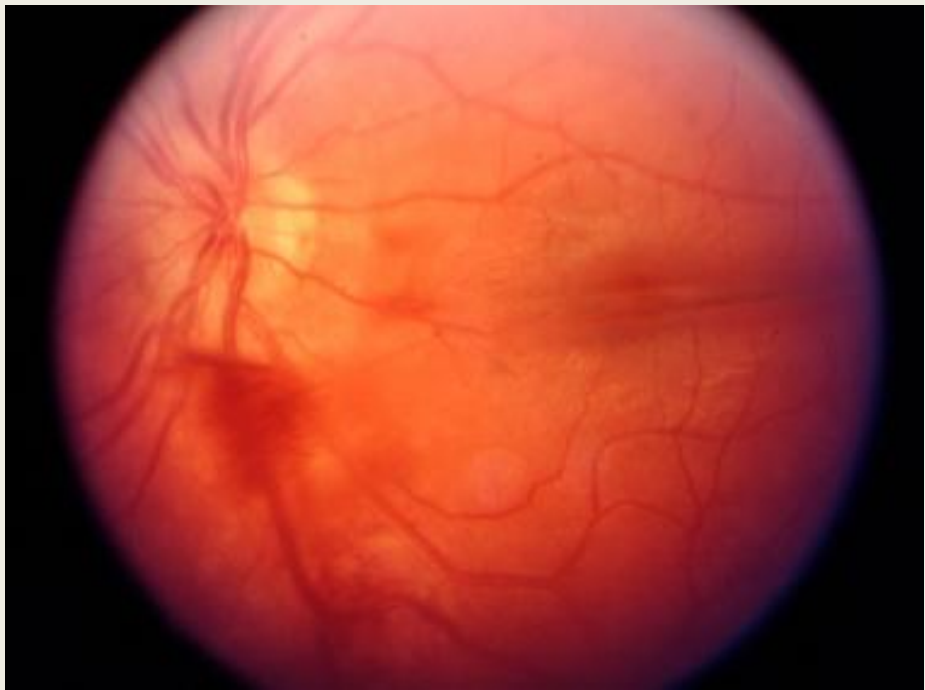- Surgical clot evacuation:

Indications:

- Large persistent hyphemas (\geq grade III for >10 days)
- Early corneal blood staining
- Uncontrolled intraocular pressure (ie, ≥ 50 mmHg for >5 days) despite maximal medical therapy

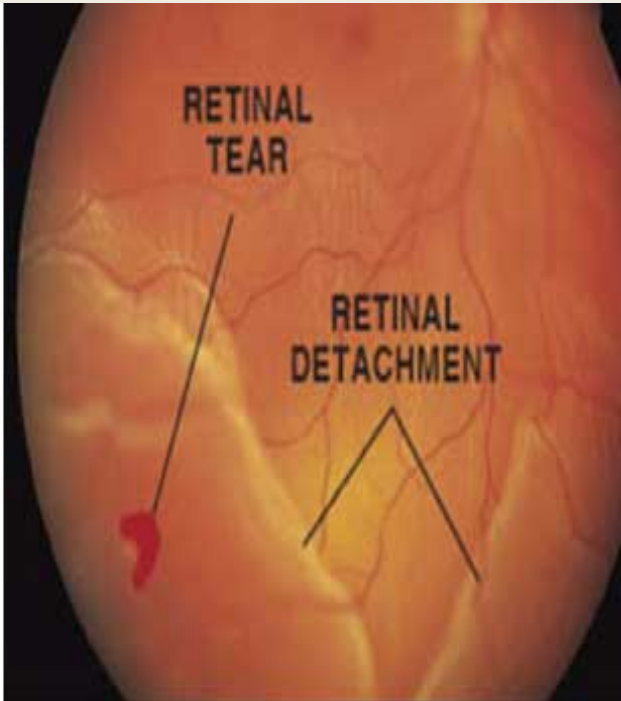
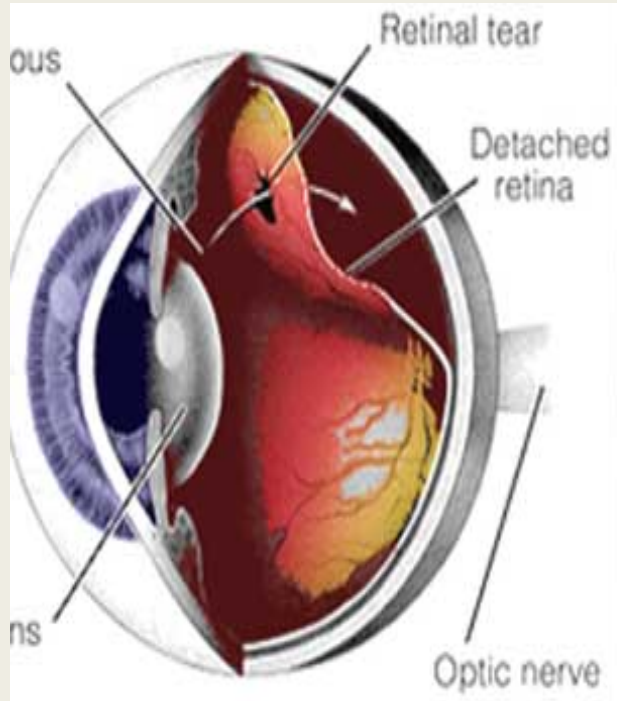
Vitreous hemorrhage

- It is extravasation of blood into one of the several potential spaces formed within and around the vitreous body.
- May indicate a retinal tear or detachment.
- May be associated with abusive head trauma in infants and young children.
- Subarachnoid or subdural hemorrhage in patients with significant head trauma.



Retinal trauma

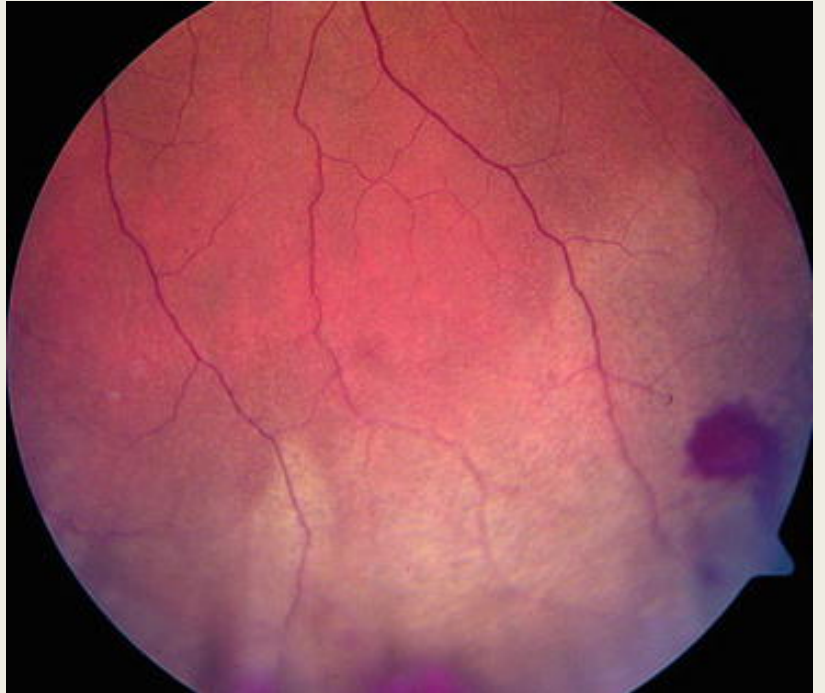- Traumatic retinal injuries result in loss of vision that may be partial, confined to a visual field, or complete.
- **Retinal detachment:**
 - May cause light flashes, floaters, visual disruption.
 - Patients require bed rest pending urgent surgical repair.
 - The timing of the repair is determined by the location of the detachment.
 - Detachments that threaten the macula and central vision warrant urgent repair.



■ **Commotio retinae:**

- Refers to retinal edema after blunt closed globe injury.
- May be asymptomatic or cause decreased vision in affected patients.
- Ophthalmoscopy shows retinal whitening with normal vessels.
- Retinal hemorrhage may also be seen.
- It typically resolves without intervention.
- Exclusion of associated retinal break or detachment is important

Commotio retinae



Optic nerve injury

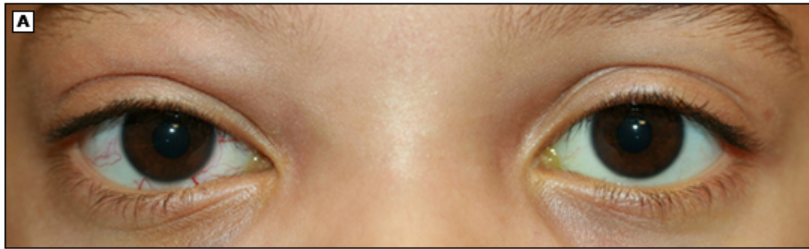- Known as traumatic optic neuropathy
- Causes decreased vision, including desaturation of red color or decreased color vision in the affected eye
- Afferent pupillary defect.

- Mechanisms of injury are as follows:
 - **Direct nerve injury:** uncommon, due to a lacerating injury
 - **Indirect nerve injury:** more common, results from contusion of the nerve within the optic canal. The usual cause is a forceful blow to the temple or the brow.

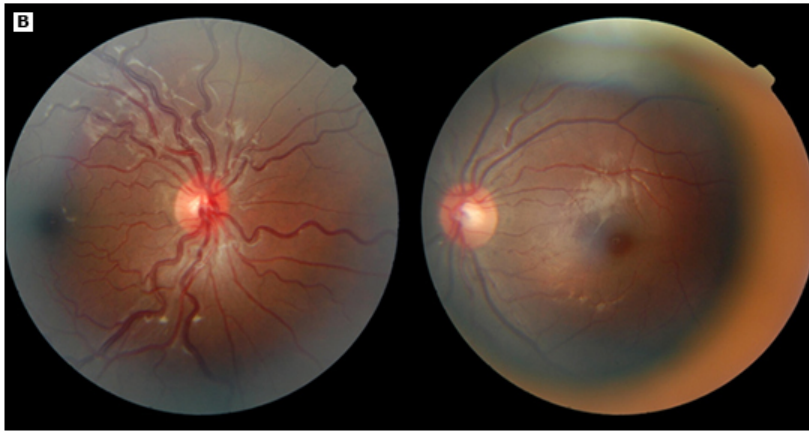
Periocular injuries that threaten vision

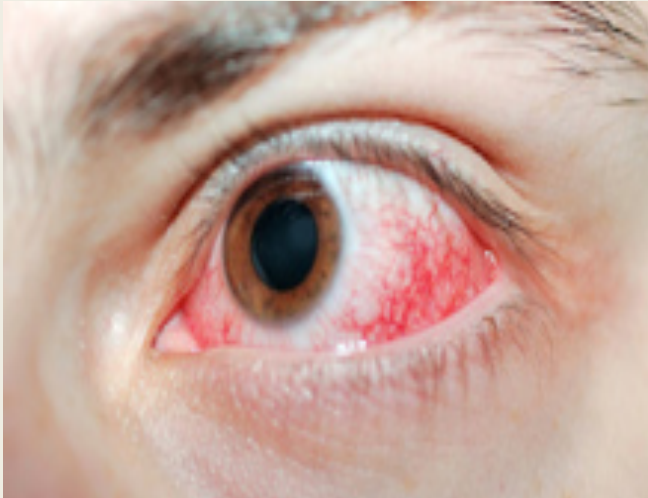- Head trauma can cause a carotid cavernous sinus fistula.
- Ocular surface vessels appear tortuous (termed "corkscrew") and dilated with concomitant chemosis (edema of the conjunctiva).
- Retinal vessel distension and high intraocular pressure.

- Mild proptosis and engorgement of the episcleral vessels.



- Dilatation of the retinal vasculature



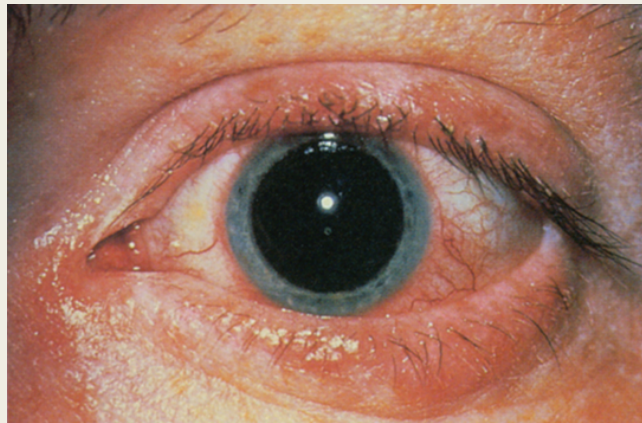
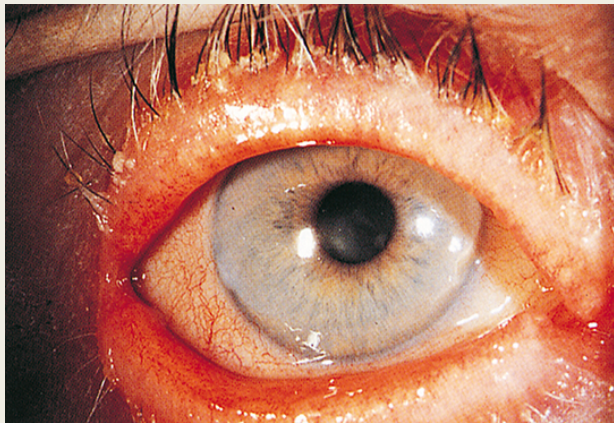

RED EYE

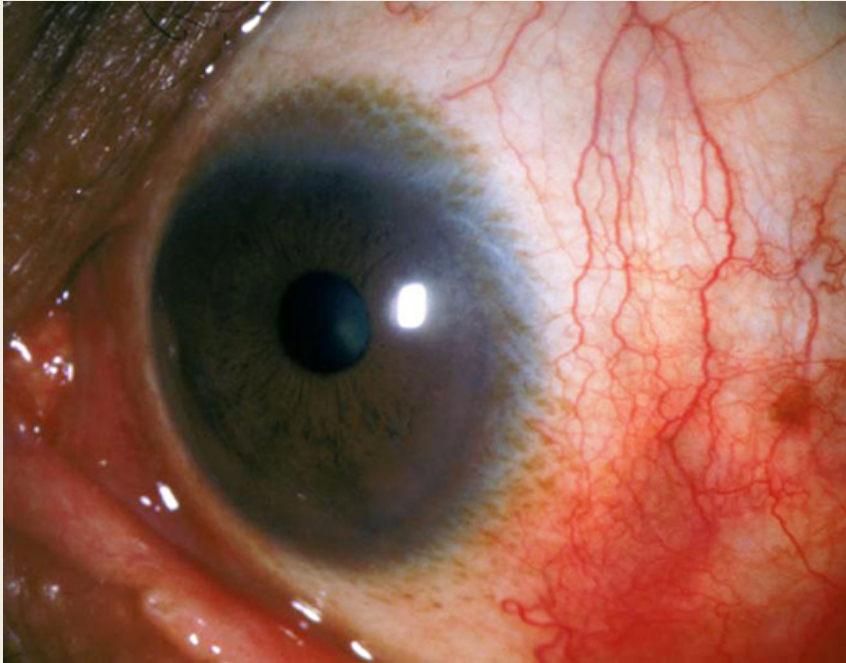
DDx of Red eye: Benign conditions

- Stye (hordeolum)
- Chalazion
- Blepharitis
- Subconjunctival hemorrhage
- Conjunctivitis
 - Bacterial
 - Viral
 - Allergic
- Corneal abrasion (urgent follow-up if not better in 24 to 48 hours)
- Corneal foreign body (urgent follow-up if not better in 24 to 48 hours)
- Contact lens overwear (urgent follow-up if not better in 24 to 48 hours)
- Dry eye syndrome

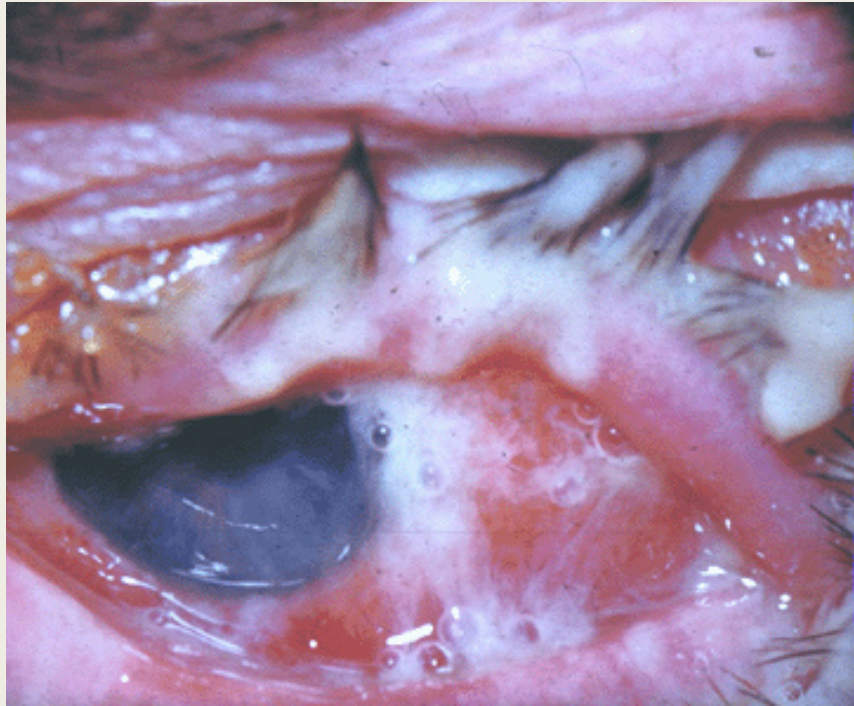
Blepharitis



Episcleritis



Bacterial conjunctivitis

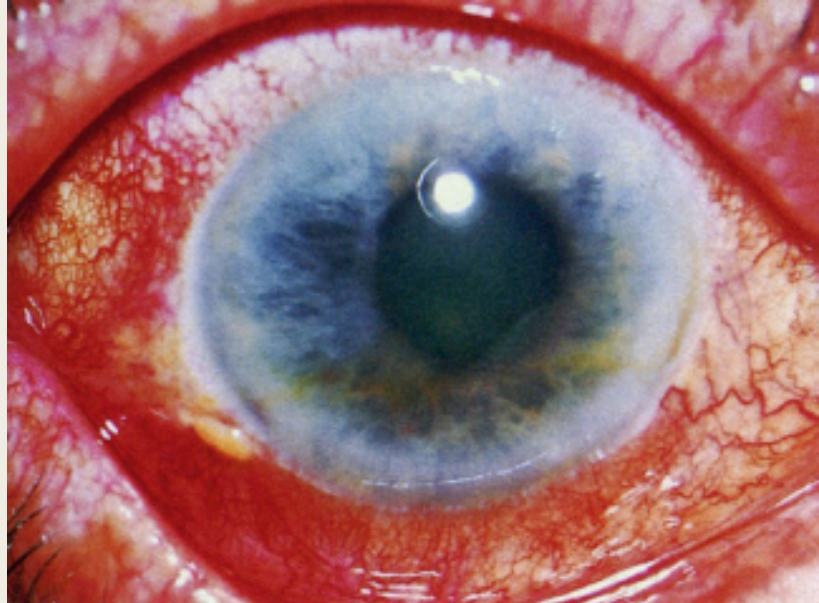


DDx of Red eye: Serious conditions

● Angle-closure glaucoma	Emergency
● Hyphema	Emergency
● Hypopyon	Emergency
● Iritis	Urgent
● Infectious keratitis	
● Bacterial	Emergency
● Viral	Urgent
● Scleritis	Urgent

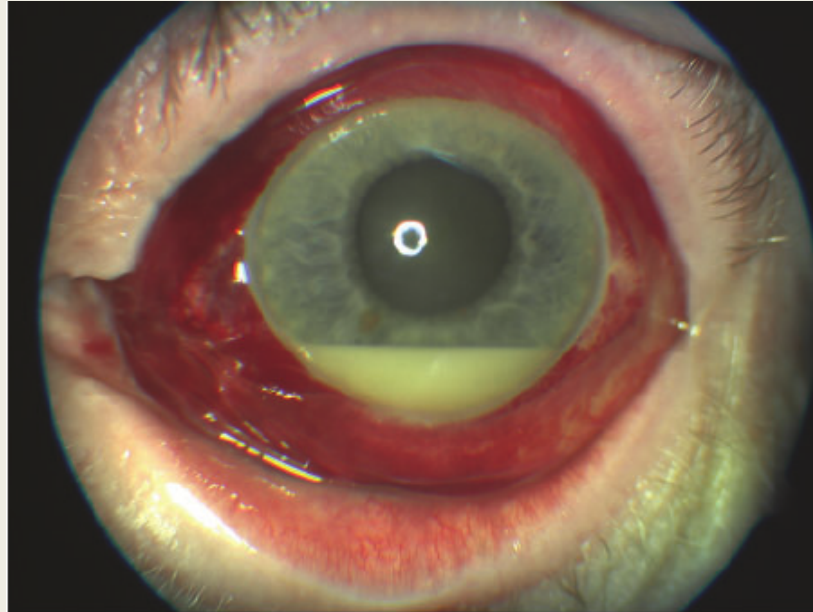
Acute angle-closure glaucoma

- The conjunctival vessels are dilated, especially near the cornea (ciliary flush).
- The cornea is slightly hazy (edematous).



Hypopyon

- Leukocytic exudate seen in the anterior chamber.



Reference:

- <https://www.uptodate.com/contents/overview-of-eye-injuries-in-the-emergency-department>

Thank you