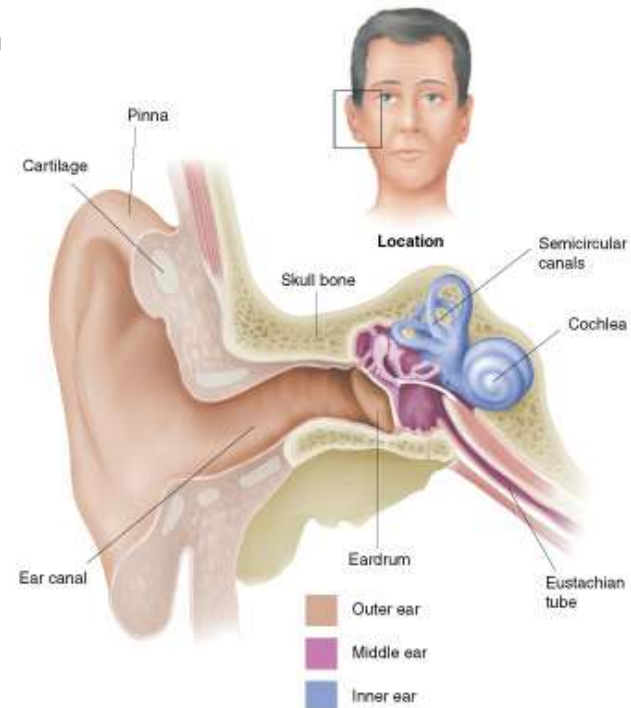
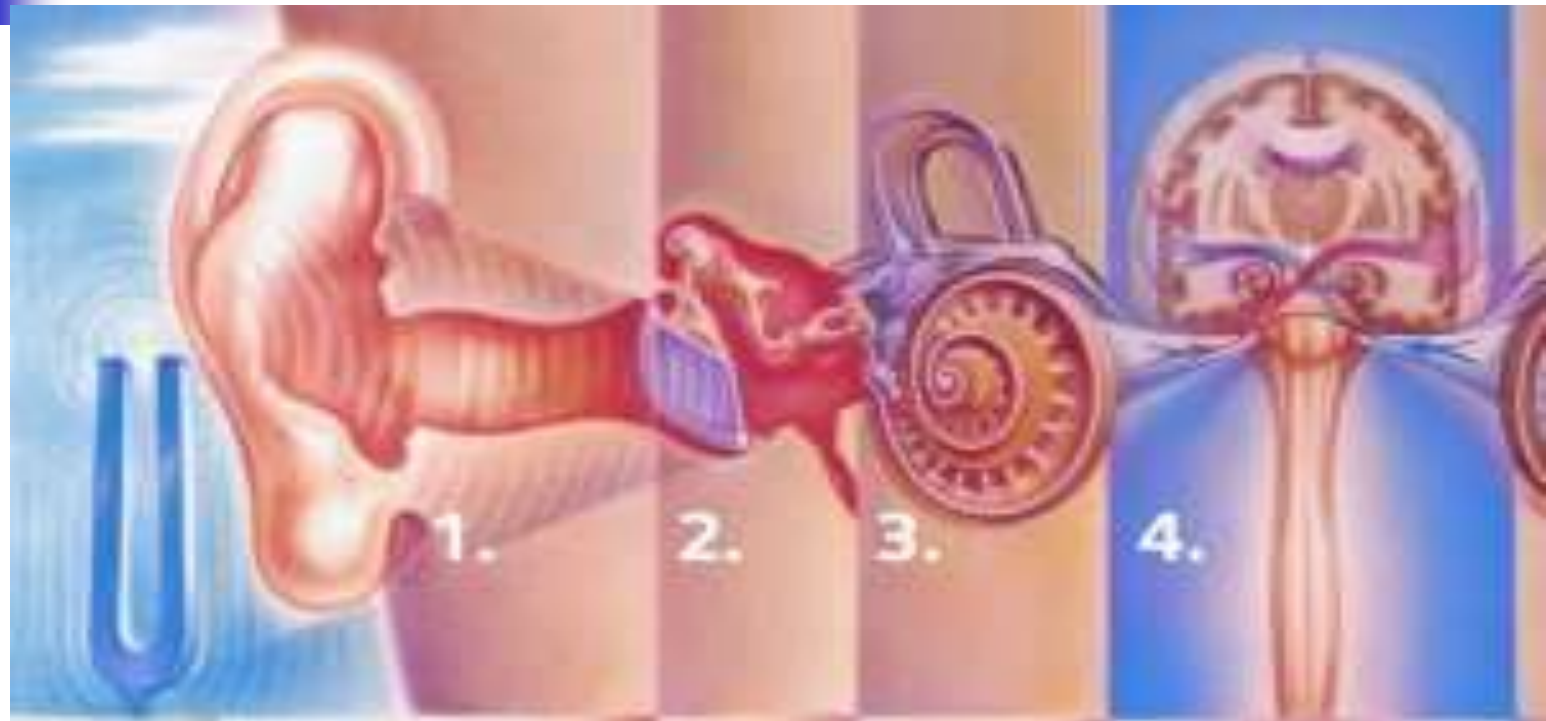


Gross Anatomy and Physiology of Hearing





- The auditory system is divided into peripheral and central components



Peripheral Portion

Consists of :

- The outer ear.
- The middle ear.
- The inner ear.
- The Auditory nerve (VIII cranial nerve).

Central Portion

- It deals with the processing of auditory information as it is carried up to the brainstem & auditory cortex of the brain (parietal lobe).

Auditory Pathways and Hypothesized Functions

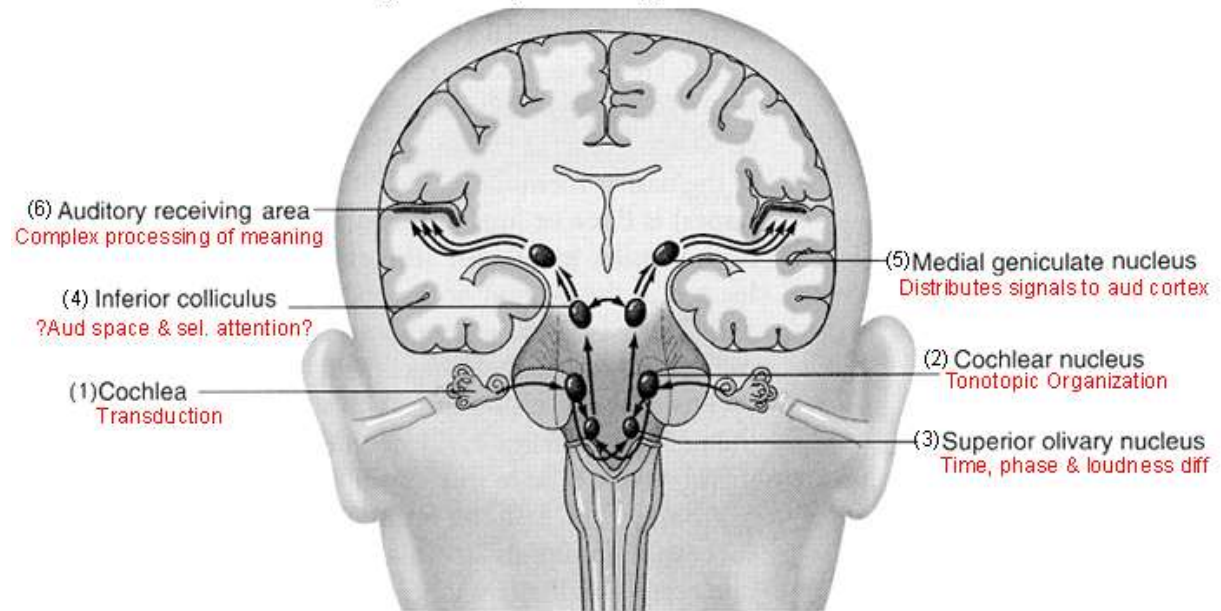


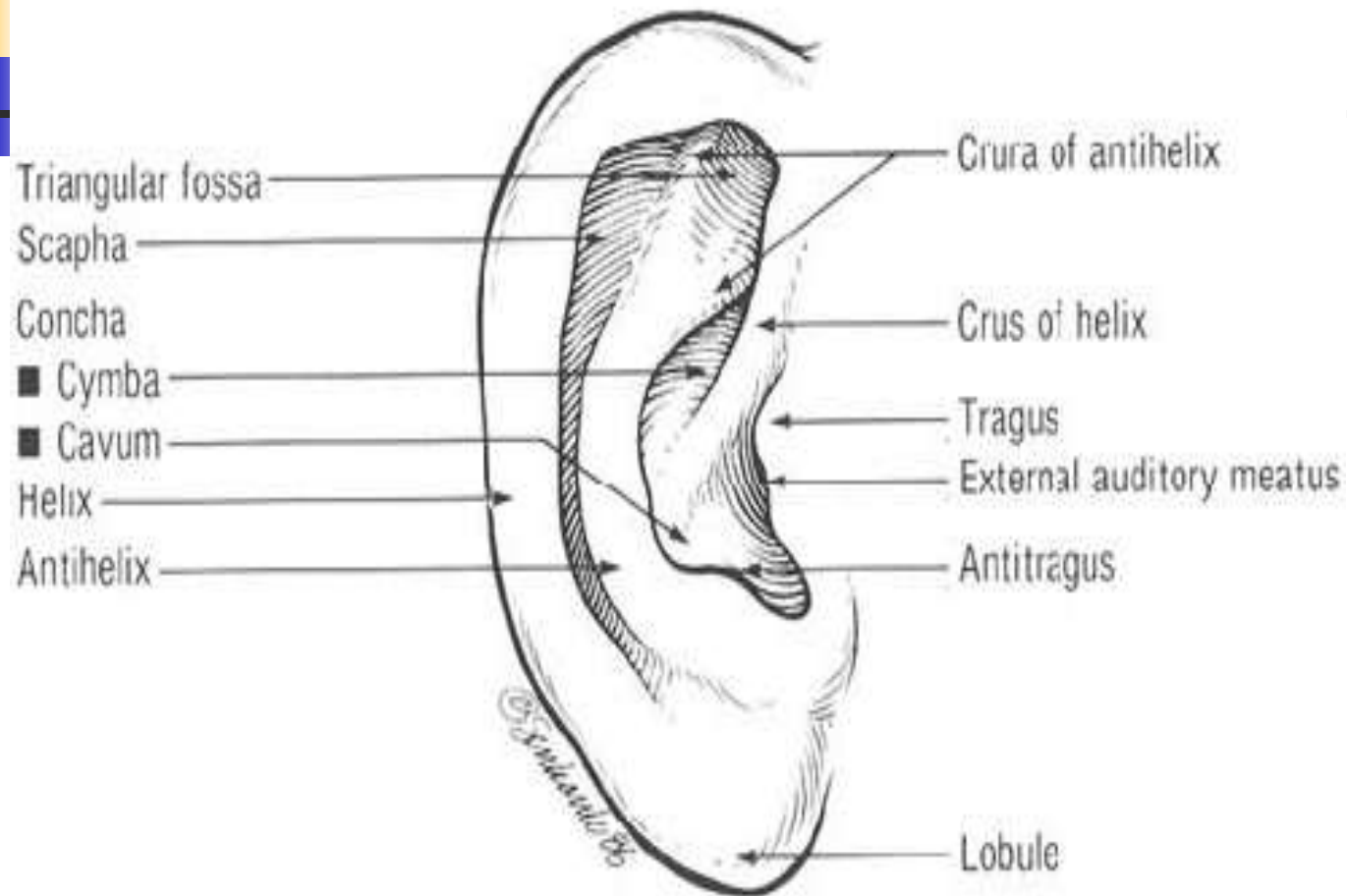
Figure 10.24



The Outer Ear

1) The Auricle (pinna)

- varies in size and shape.
- provided by cartilage, except the lobule
- covered with a layer of epithelial tissue.
- Lobule or ear lobe is the bottom most portion of the auricle.



Landmarks of the auricle



The Auricle (continue..)

- Helix is marking the most distal border.
- Antihelix
- Tragus projects immediately in front of the ear canal
- Antitragus
- Concha is divided into two parts the lower cavum concha, and the upper cymba concha



The Outer Ear

2) External Auditory Canal (EAC)

- External Auditory Meatus (EAM)
- S-shaped
- it's approximately 0.7 cm in diameter, and 2.5 cm long.



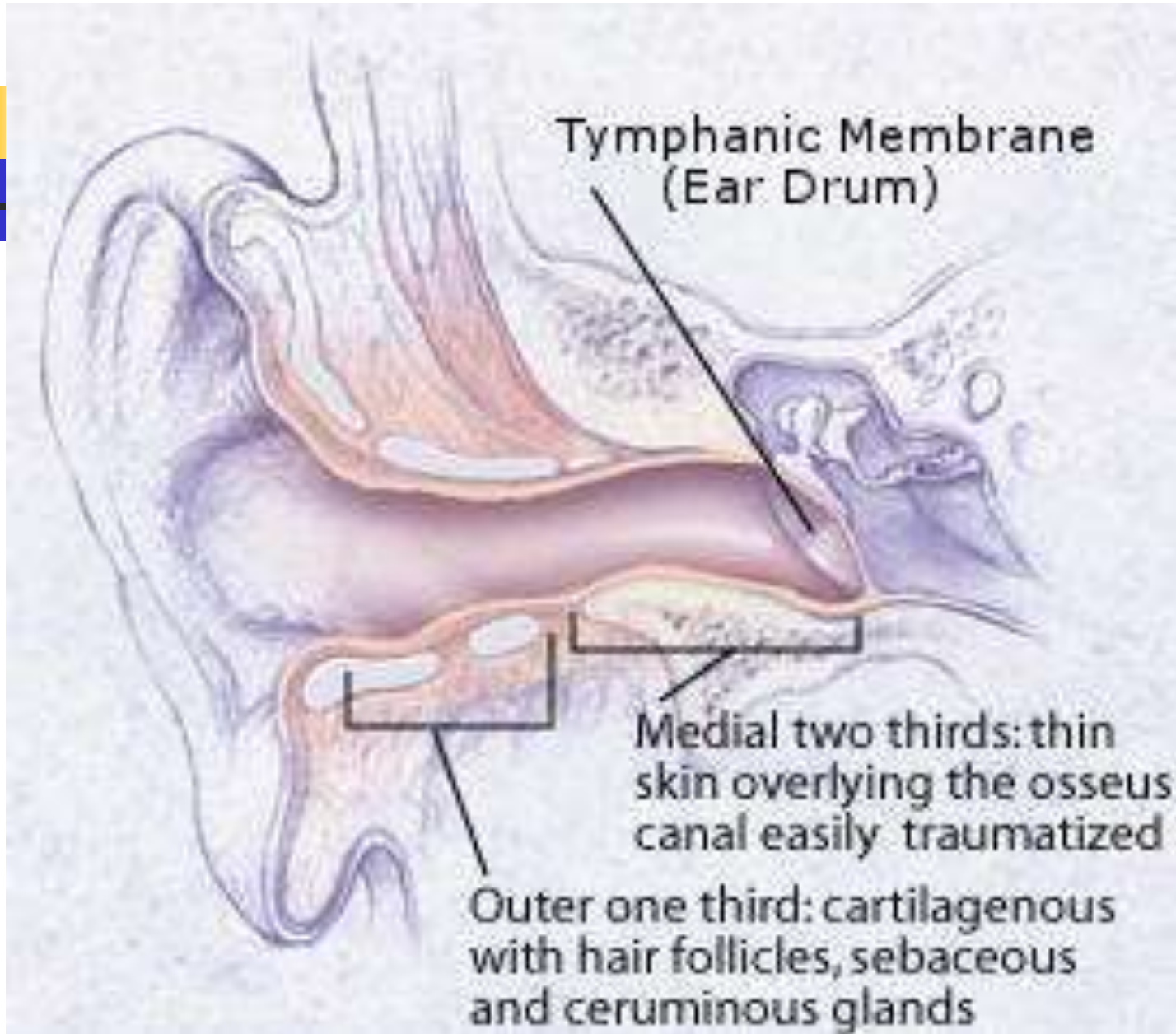
External Auditory Canal

- The outer 1/3 portion passes through cartilage, which is lined with hairs, and has sebaceous glands & cerumen or wax.
- The inner 2/3 portion passes through the tympanic portion of the temporal bone.




External Auditory Canal

- There are two constrictions in the EAC
 1. osseocartilaginous junction.
 2. isthmus, is about 0.5 cm from the tympanic membrane.





Functions of EAC

- The auricle collects and conducts sound to EAC
- The EAC Amplify the sound around 13 dBs by its resonance frequency. (The 13 dB amplification of sound will be in the range of 3 to 6 kHz =around 4 kHz depending on the length of EAC).
- Protects the tympanic membrane from trauma, insects & FBs. by shape & wax(cerumen).

- Self cleancing property(immigration characteristic of epithelium outwards and during chewing or speaking by the movement of the jaw bone (mandible))



- Malformation of pinna and EAC

Atresia → absence of the EAC

stenosis → narrowing of the EAC

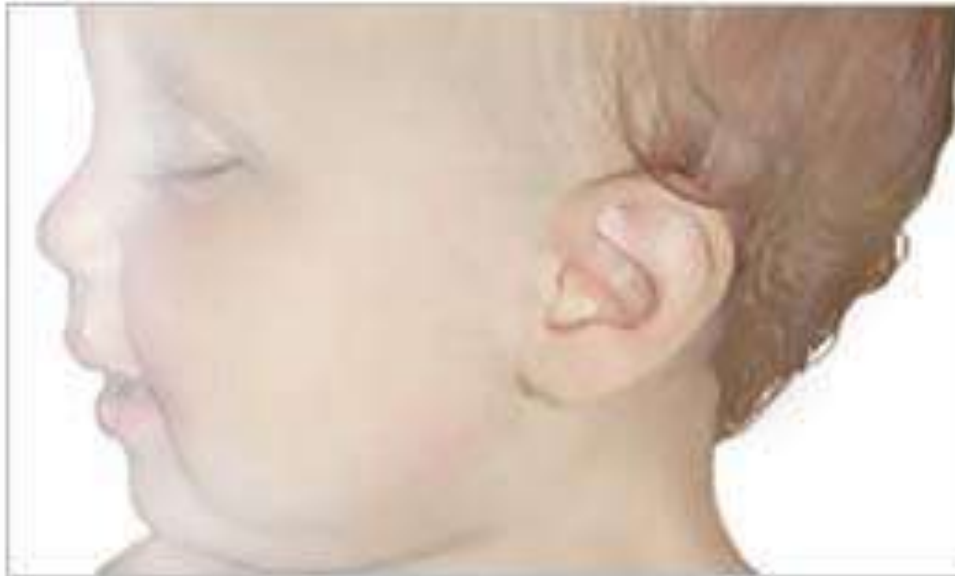Microtia → abnormally small auricle

Aplasia → abnormally developed auricle

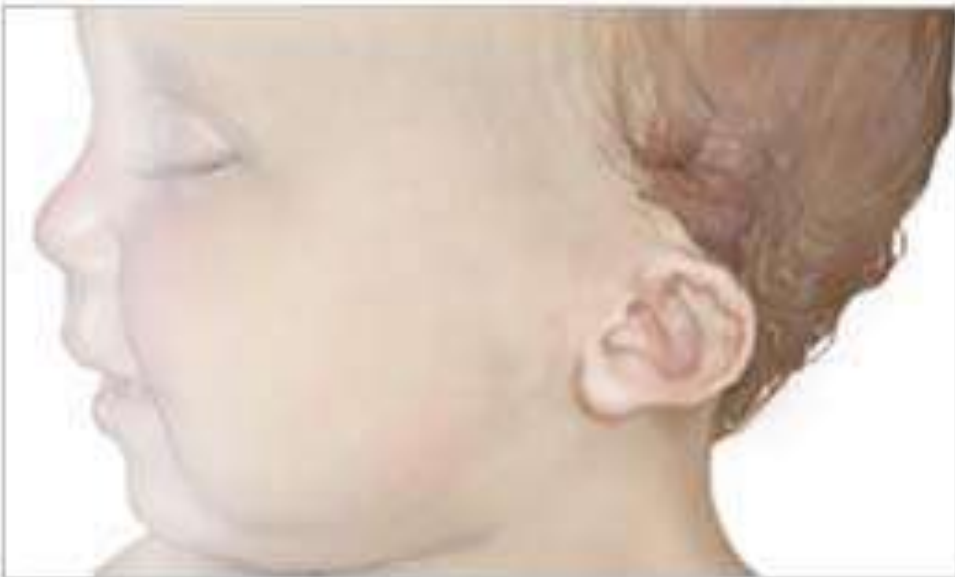Anotia → absent auricle

- Otorrhea: Ear discharge

- Otalgia: Pain in the ear

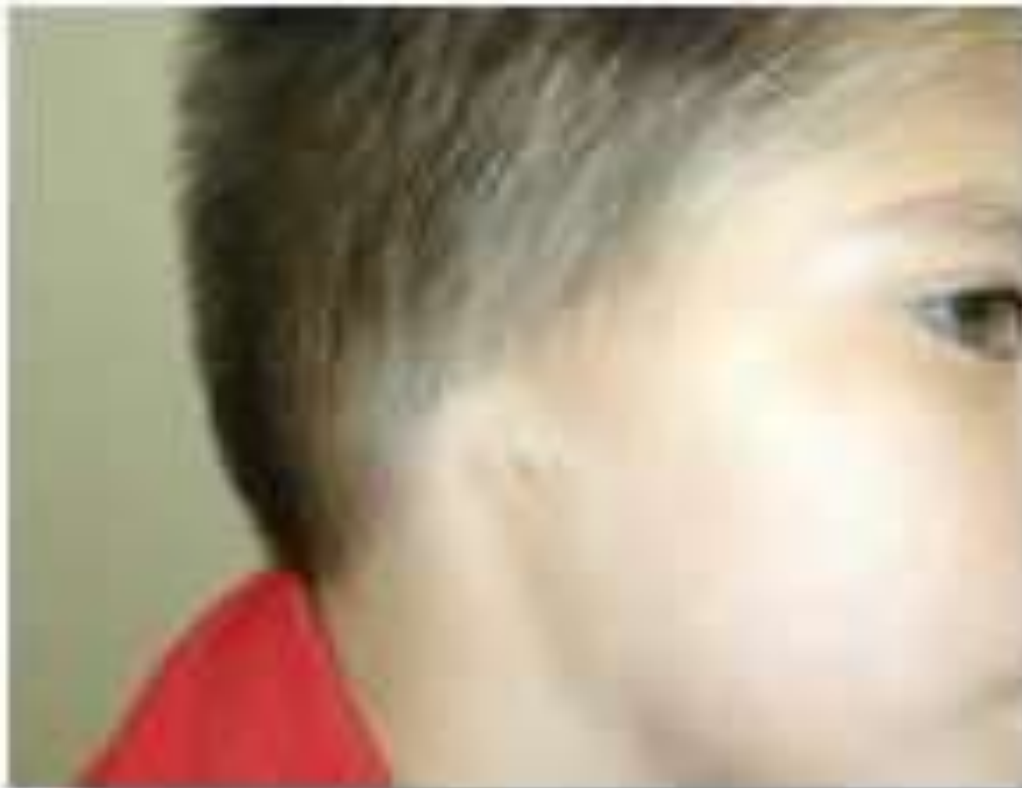

Normally
developed
outer ear
(pinna)



Abnormal size,
shape, rotation
and/or location
of pinna

[Low set ear](#)



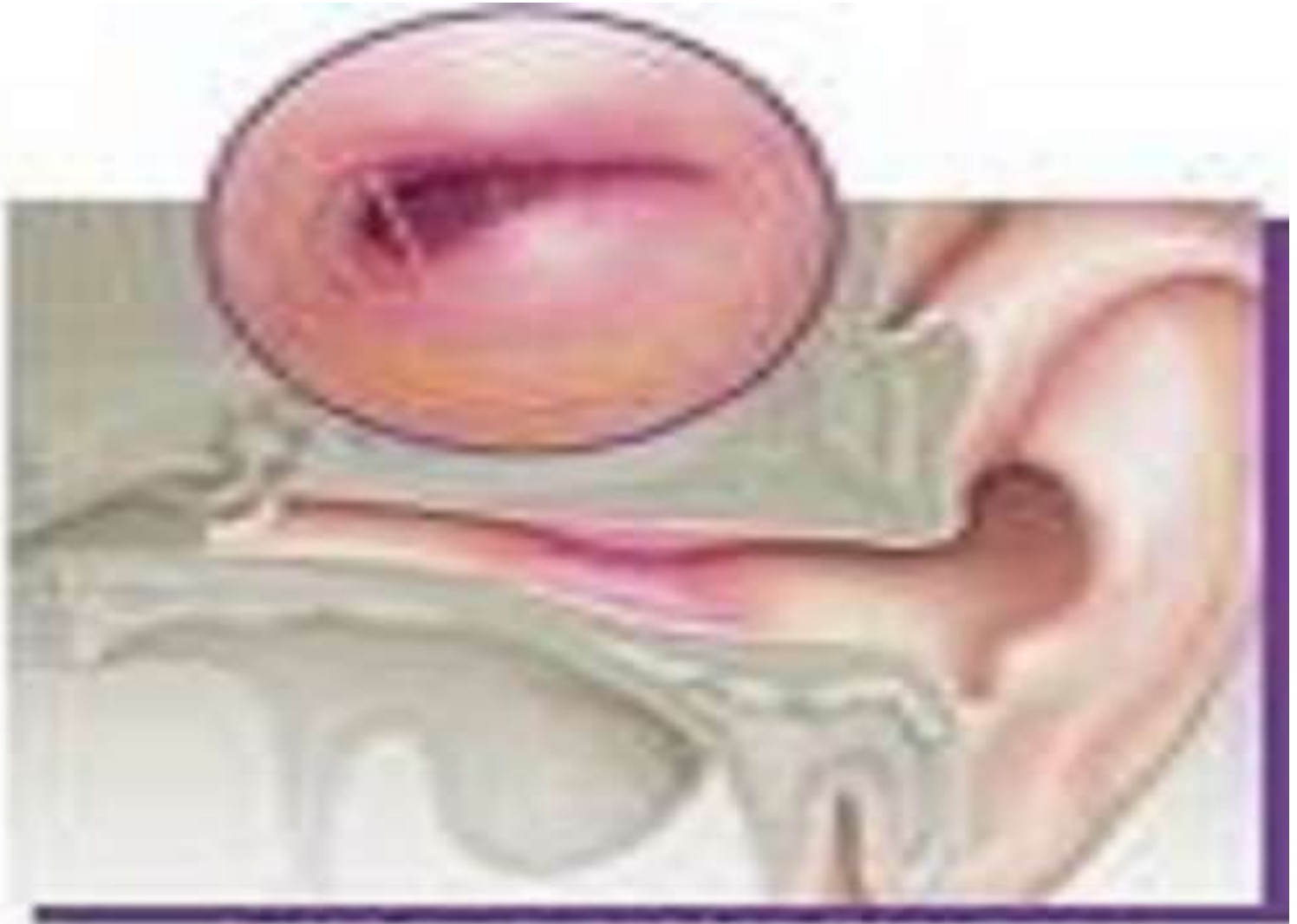Anotia- absent auricle



Otitis Externa

- Inflammation of the skin of the external ear.
- The tissue responds to the inflammation by edema or swelling, redness & otalgia.
- The swelling increases the tension on the epithelium making it quiet painful.

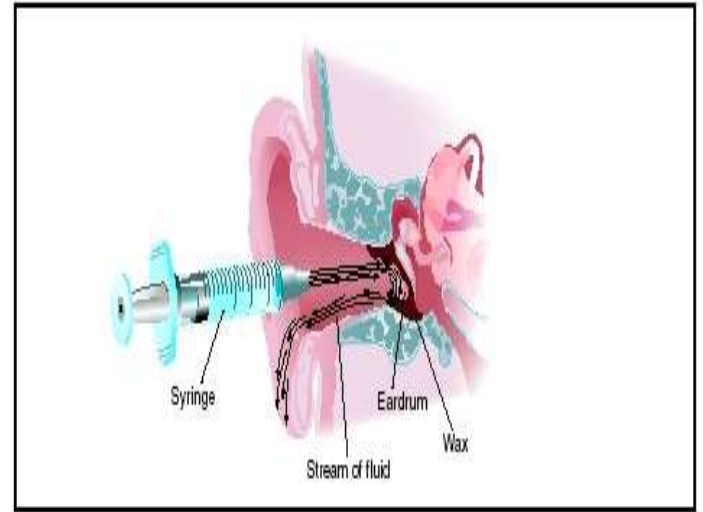
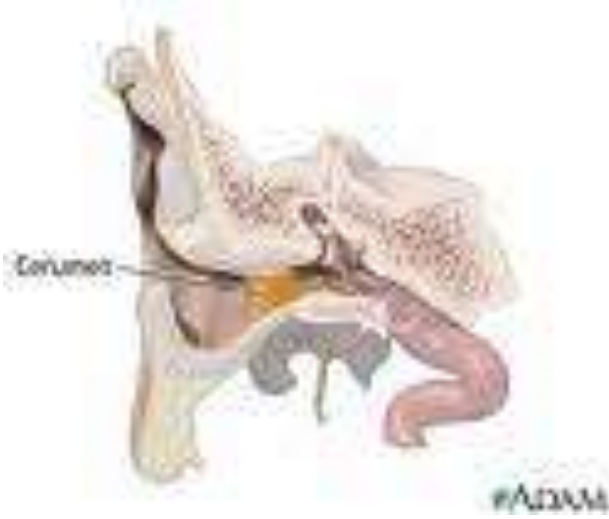
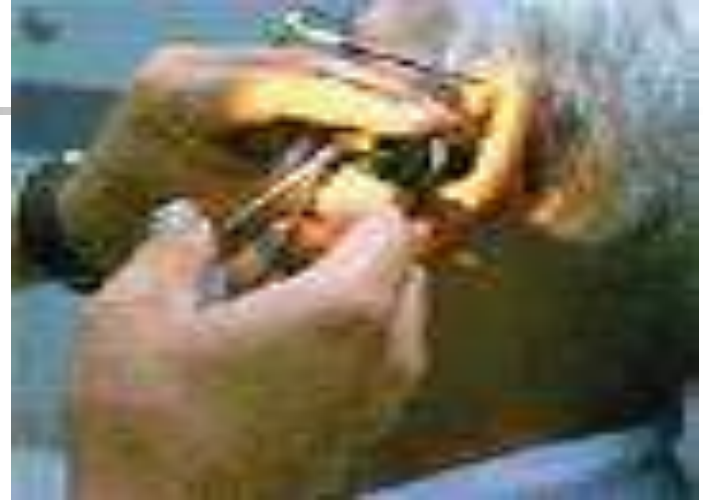
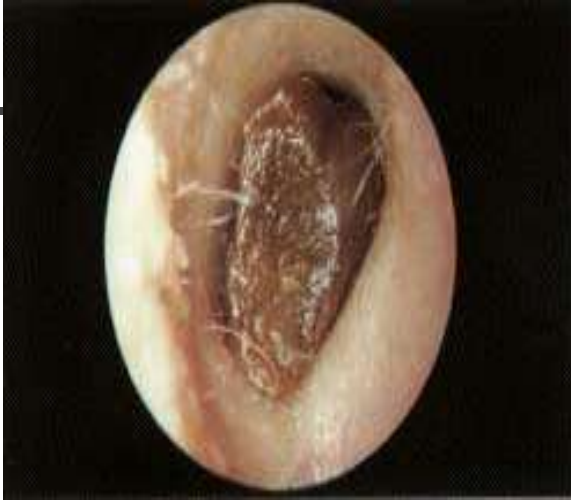Otitis Externa





Ear Wax

- Wax is the most common cause of conductive hearing loss in adults.
- Some people have extremely active wax glands.
- improper use of ear cotton swaps or buds, pushing the wax to the bony portion.Contraindicated
- Some times water pressure during diving may push the wax further in the canal
- Symptoms may include itching, otalgia, and sensation of fullness in the ears.
- Amount of hearing loss depends on the amount of ear canal occlusion and impaction to TM.





Tympanic membrane

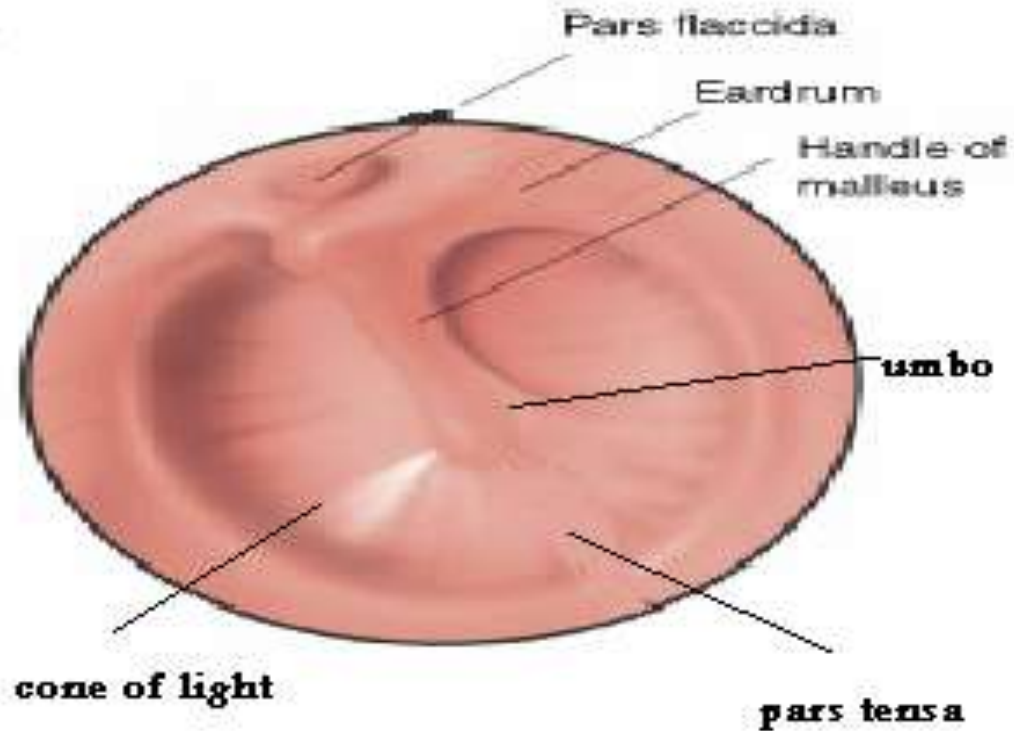
- It marks the boundary between the outer and middle ear.
- Concave, and slightly oval structure.
- Approximately 55 mm² in area.
- Semi-transparent.



Tympanic membrane

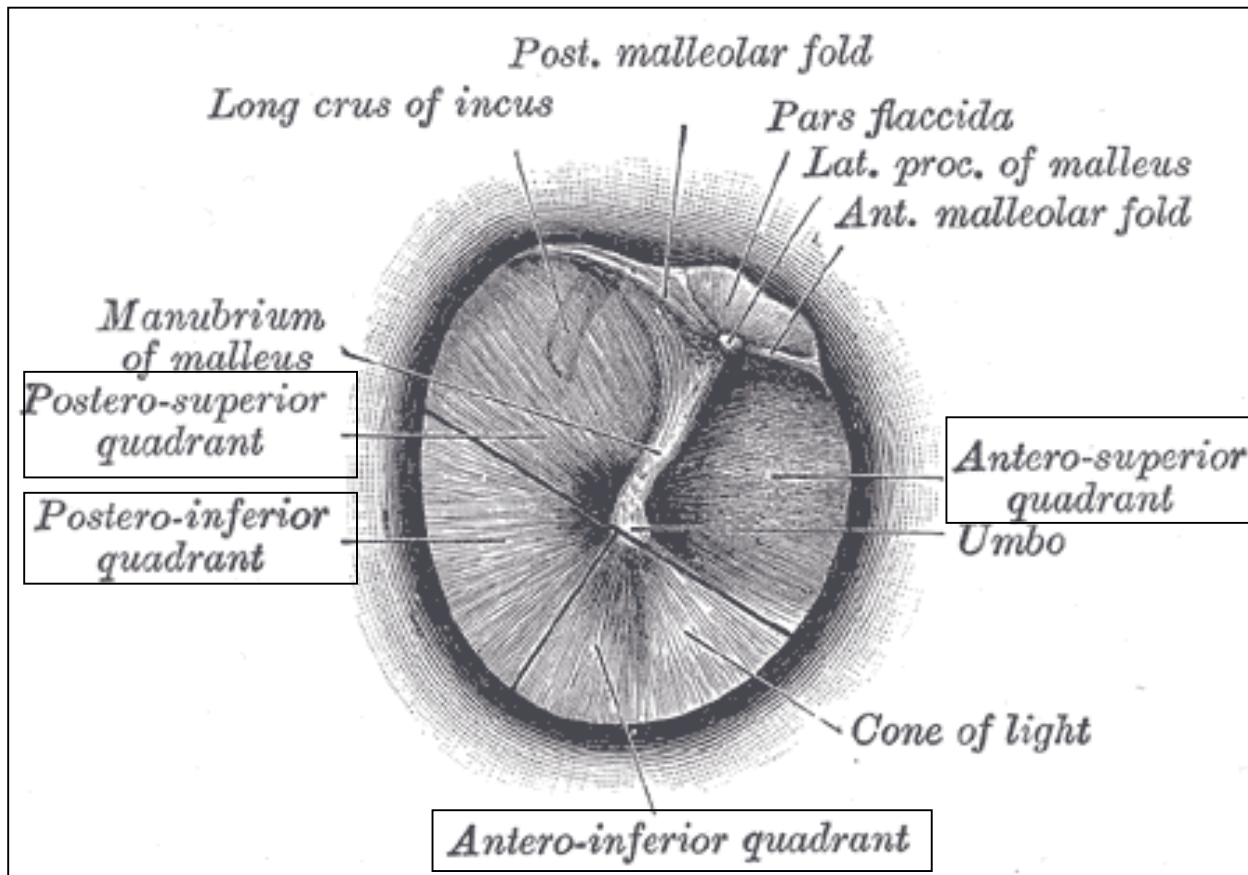
- Composed of 3 layers of tissue:
 1. Outer (Cuticular) layer → epithelium
 2. Intermediate (fibrous) layer → fibrous connective tissue.
 3. Inner (mucous) layer.

Tympanic membrane



Left tympanic membrane


Land marks of T.M.





Land marks of T.M.

- Umbo is the most depressed portion.
- The light reflex is cone shaped.
- Pars falccida on the upper portion of the TM lacks the fibrous layer.
- Pars Tensa is the greatest surface of the TM.
- Tympanic annulus is a ring of tissues that hold the TM in position at the end of EAC.

- 
-
- The direction of the cone of light and the handle of malleus give an indication of which ear is being tested.
 - The handle of malleus runs at 11 o'clock in the left ear.



Functions of the TM

- The vibration of acoustic energy in air in EAC is transmitted into mechanical energy by T.M. and ossicles of middle ear to footplate of the stapes.
- Amplification of sound by :
 - 1-aerial (space) factor between TM & footplate of stapes and
 - 2-lever function of ossicles. The overall will be around 20-23 dBs.
- Protection of INNER Ear by acoustic stapedius muscle reflex (ASMR)



Function of Inner Ear & 8th Nerve

-The footplate of the stapes will convert the sound into hydrolic energy in peri & endo lymph moving the basilar membrane & organ of Corti. The sound energy will be in form of chemico-electrical in Hair Cells and these will be transduced into electrical form in the dendrites of the cochlear nerve. this process is called transduction of the inner ear (transducer)

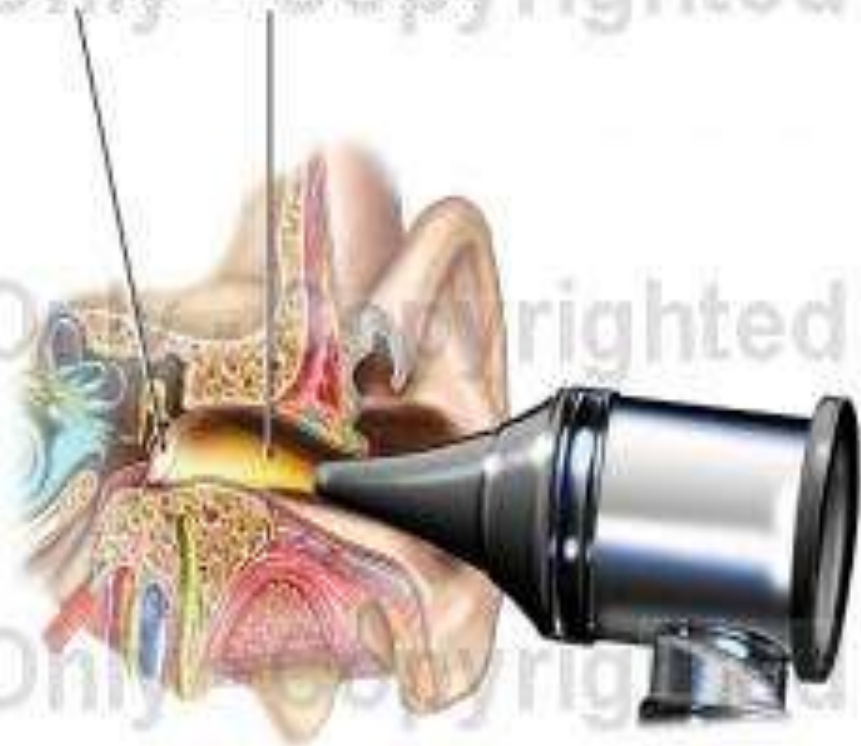Otoscopic examination

Ear examination



Ear drum

Ear canal



Otoscope

