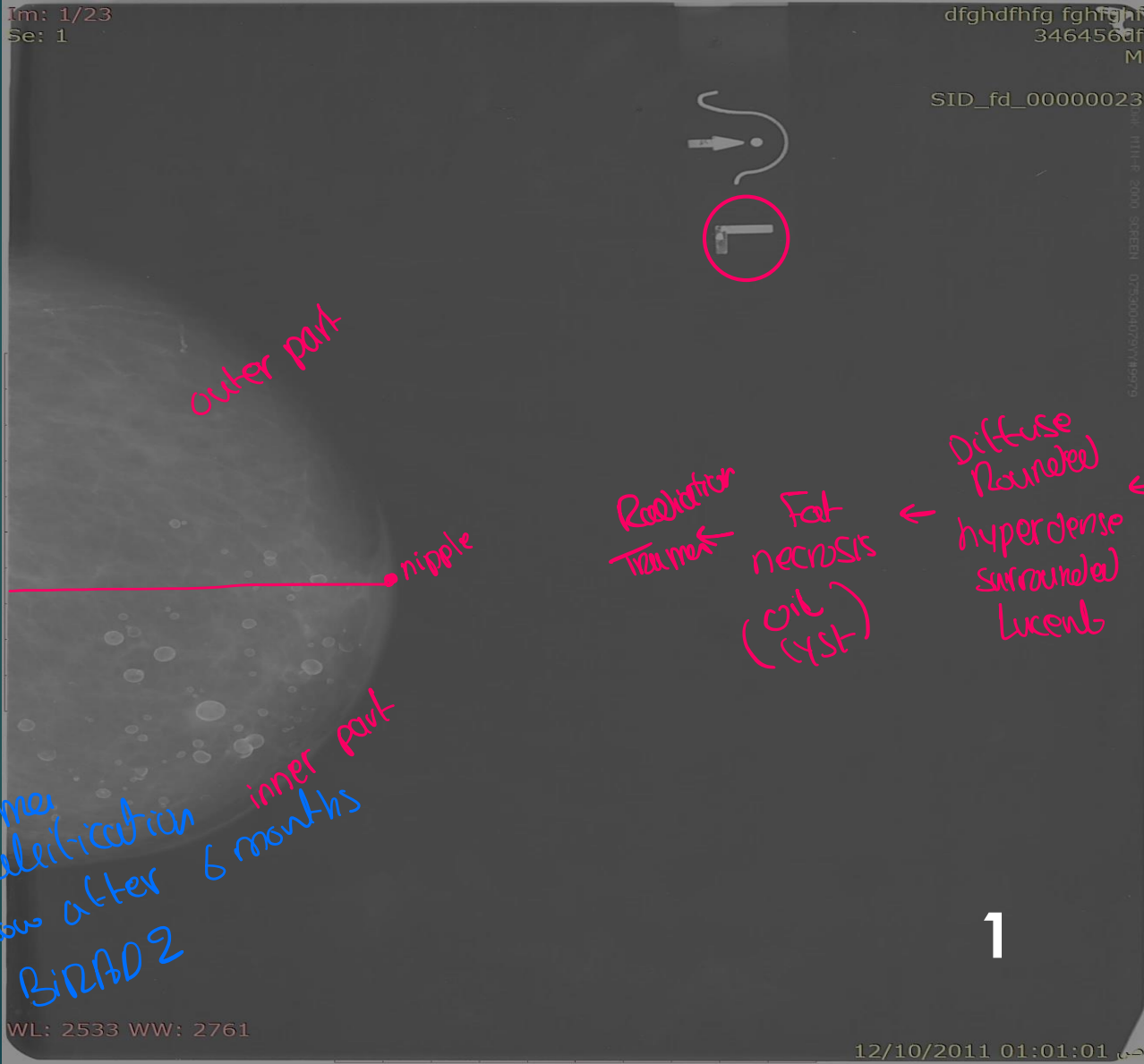


LN normally presented as ringi form



outer part

nipple

inner part

Radiation Trauma

Fat necrosis (oil cyst)

Diffuse Rounded hyperdense surrounded lucent

- 1) CC
- 2) Left Breast
- 3) Skin calcification [egg shell]

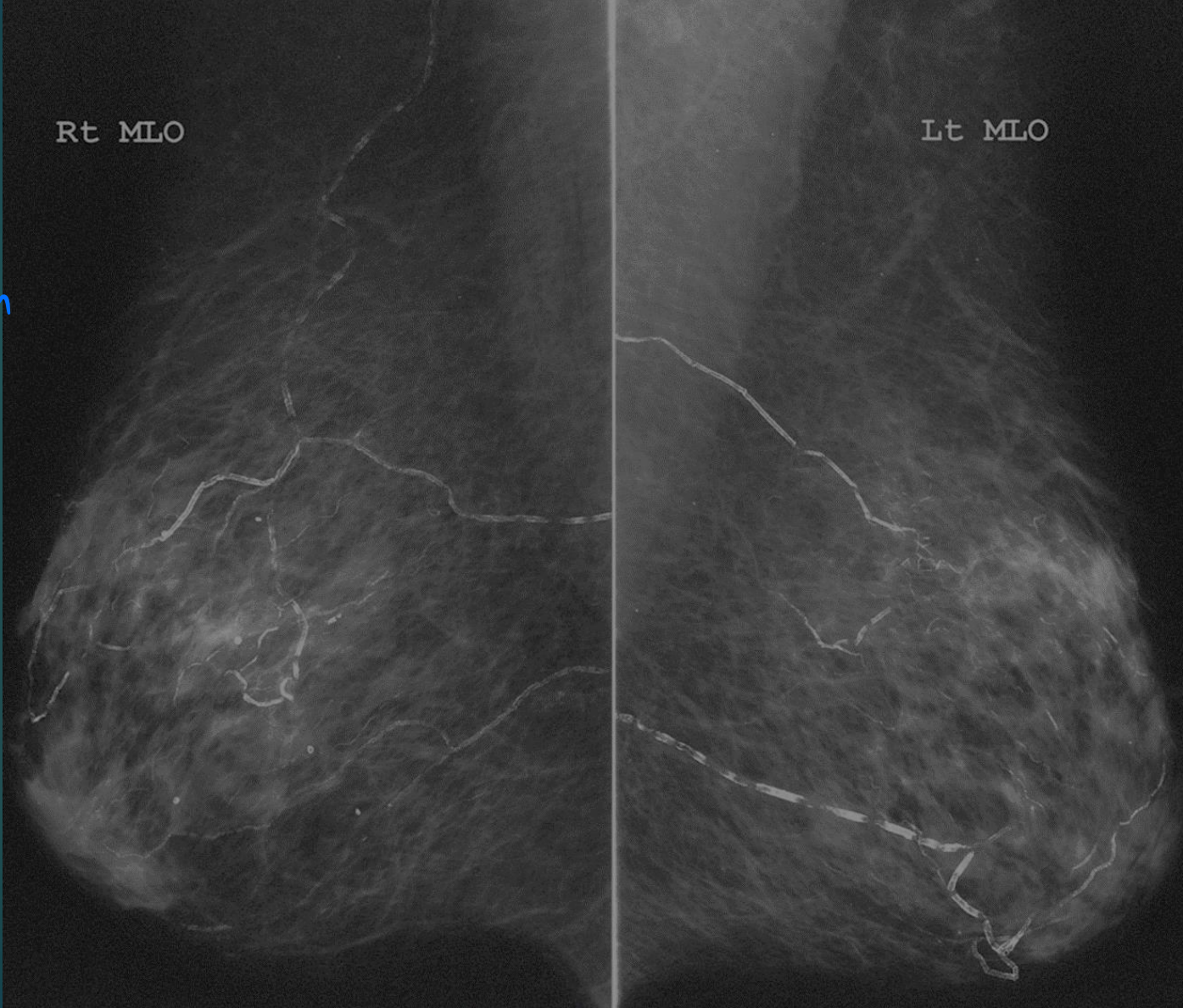
4) inner half

5) BIRAD 3
need follow up
BIRAD 2 here

*Fibroadenoma
Very tiny calcification
BIRAD 3 follow up after
macro calc BIRAD 2

Rt MLO

It MLO



-MLO
-vascular
calcification

-BI-RAD 2

-Axn 3

-< 55 yo
alarm to
coronary artery
diseases

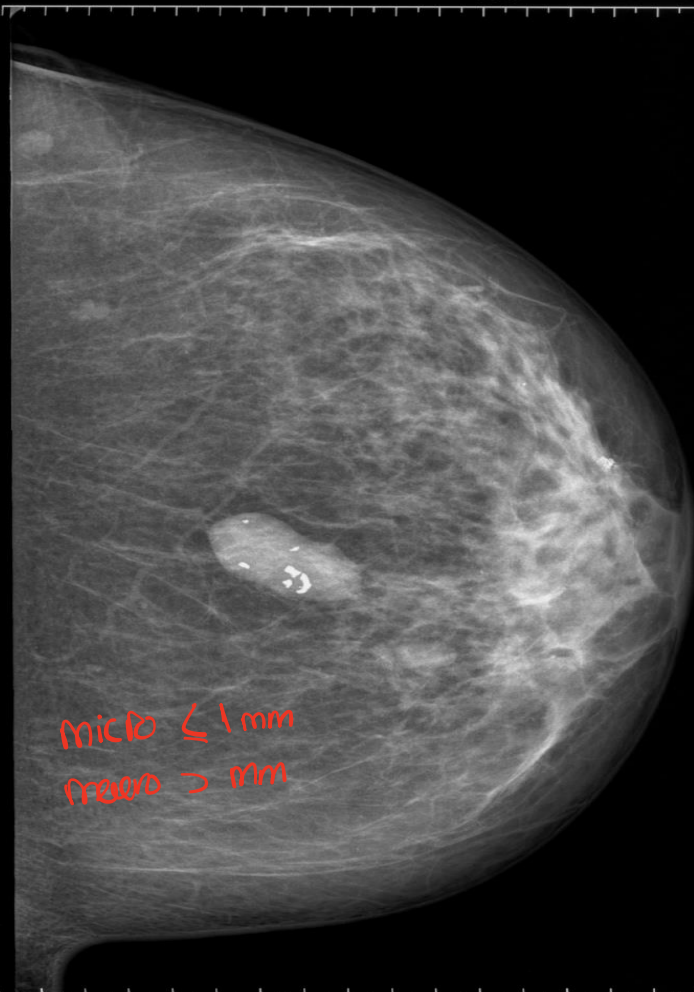


○
Ovale (Bilobe)
w/ central lucency
isodense
with LN inferomedial

CC
left Breast
ACR 1
outer part
BIRAD 2

5

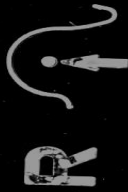L-cc



CC
Left Breast
ab Janelton
axilla
well defined
isodense
inside calcification
involving fibroadenoma
BIRADS 2
amorphous

micro \leq 1mm
macro $>$ 1mm

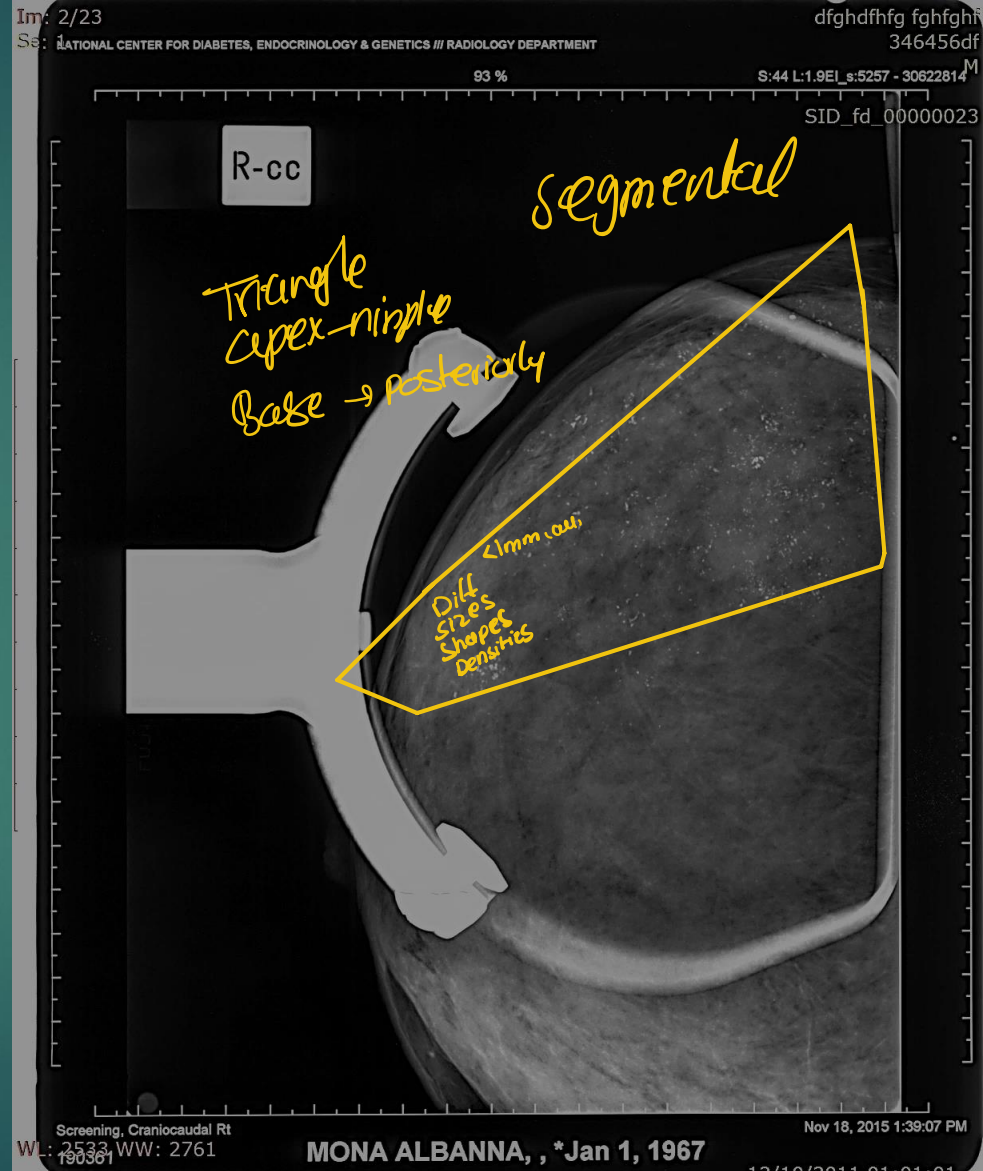
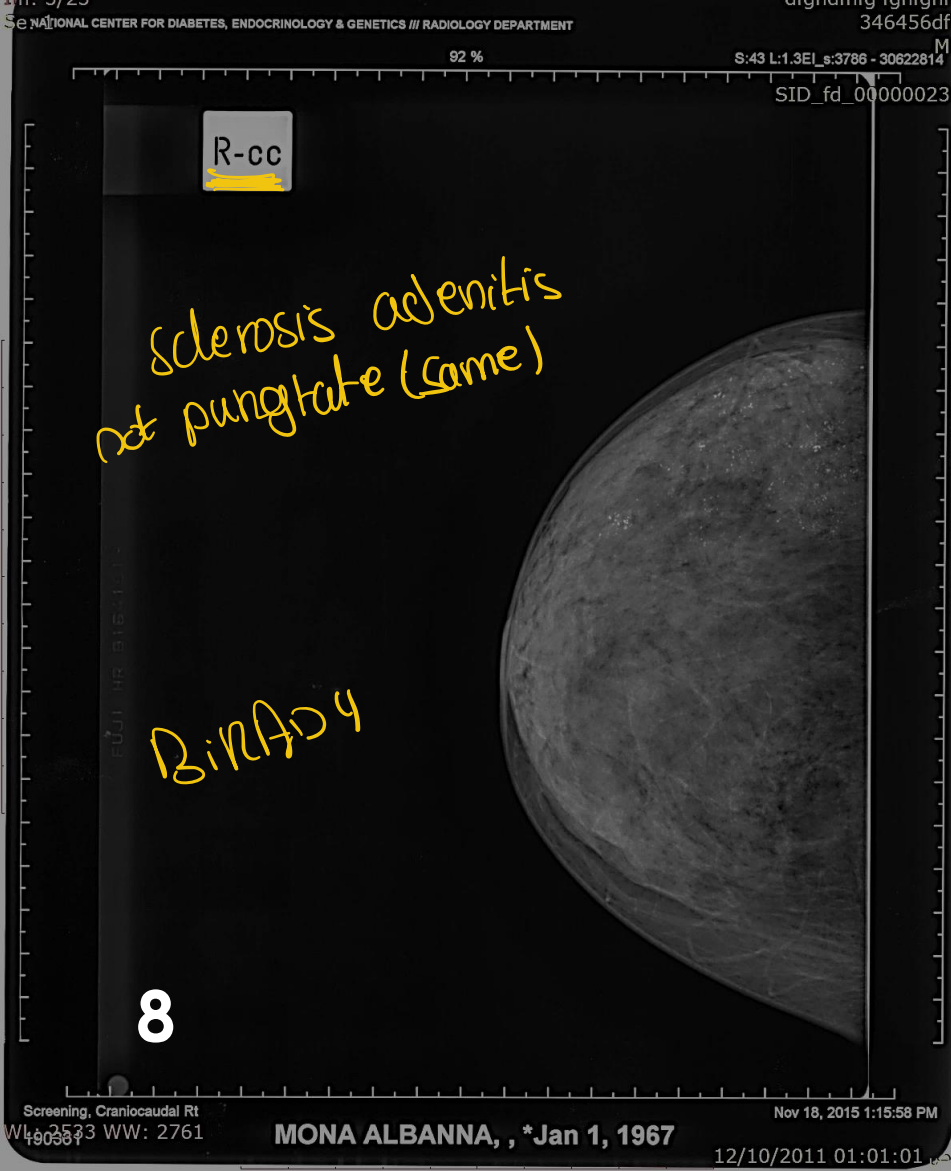
tiny fibroadenoma
calcifications



KODAK MIN-R 2000 SCREEN 0753004075YV#9577

7

- CC
- Right
- inner
- spiculated
- hyperdense
- BirADS
- shape not matter



NATIONAL CENTER FOR DIABETES - X-RAY

NATIONAL CENTER FOR DIABETES - X-RAY

73 %

73 %

S:115 L:2.4E1_s:1208 - 30453319
SID_fd_00000023

S:325 L:2.4E1_s:583 - 30455870
SID_fd_00000023

L-cc

L-mlo

- fat equivalent
 - oval well circ
 - lipoma
 - inner lower part
 - BIRADS 2

benign
 LN

9

Screening, Craniocaudal Lt

Screening, Oblique Lt

126231
WL: 2780 WW: 2028 [D]
SAFA' MAHMUD ALMOMANI, *Jan 1, 1959
Jul 18, 2012 4:20:27 PM

126231
WL: 2813 WW: 2198 [D]
SAFA' MAHMUD ALMOMANI, *Jan 1, 1959
Jul 18, 2012 4:18:58 PM

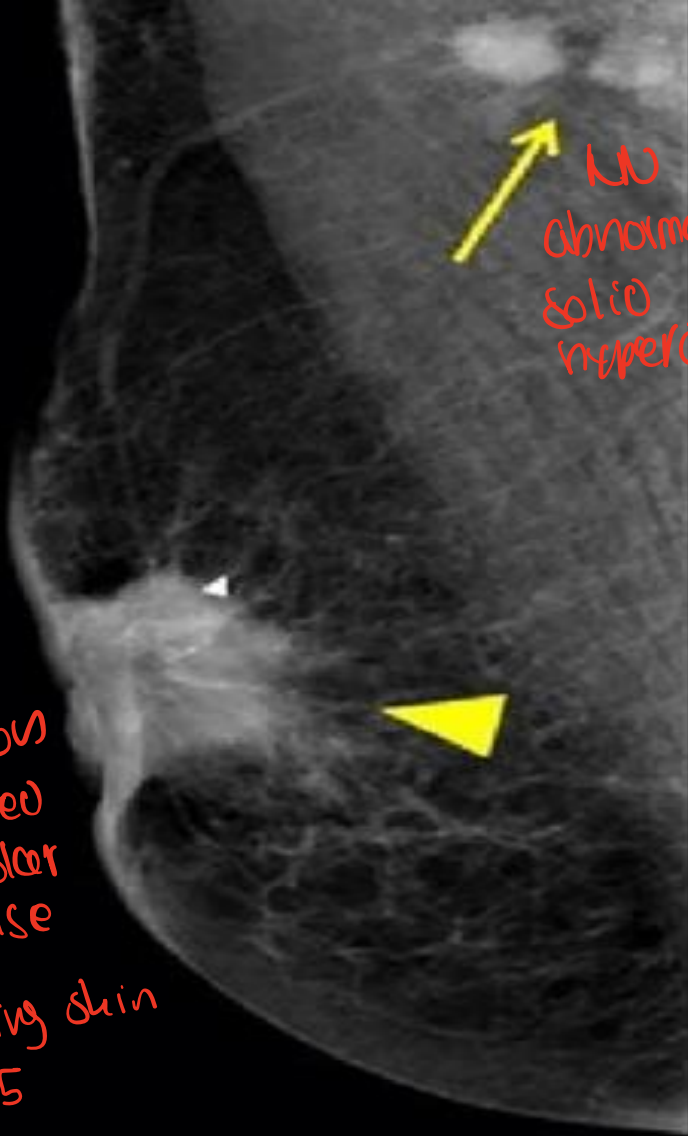
12/10/2011 01:01:01

12/10/2011 01:01:01

Best modality
to see LN → US

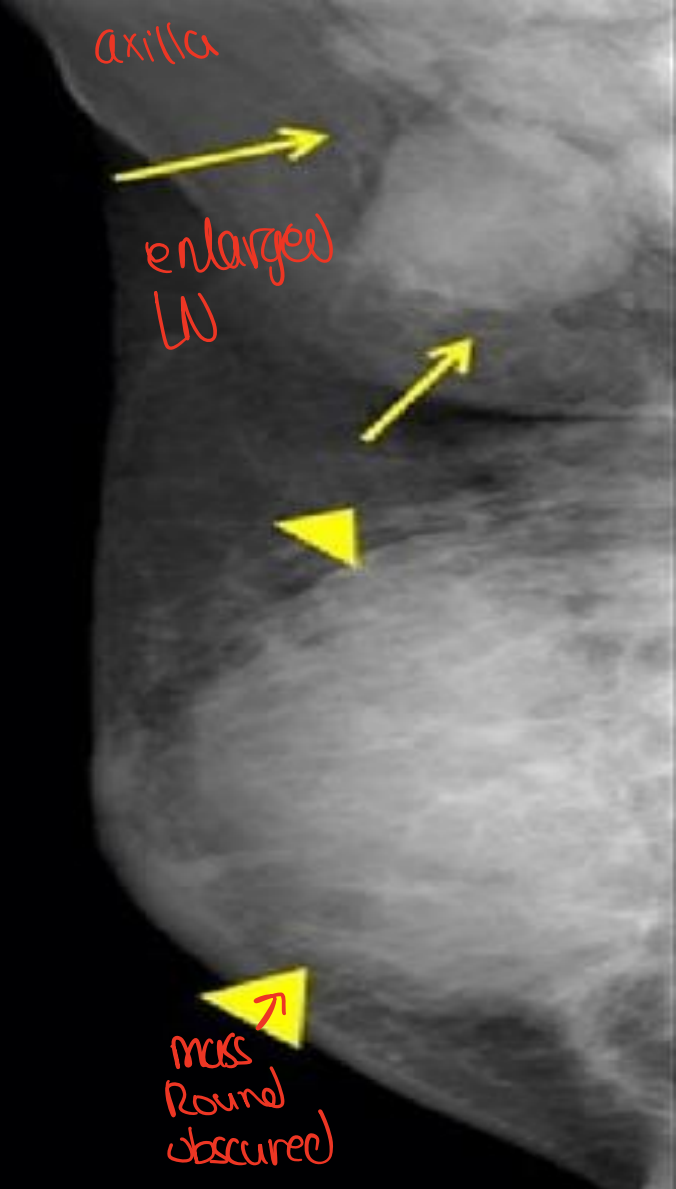2 different pts

- Nipple inversion
- Spiculated retroareolar hyperdense
- Thickening skin
- BI-RADS



LN
abnormal
solid
hyperechoic

B

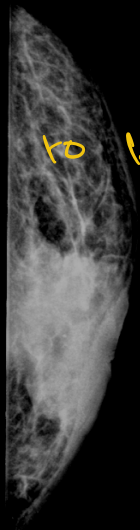


axilla

enlarged
LN

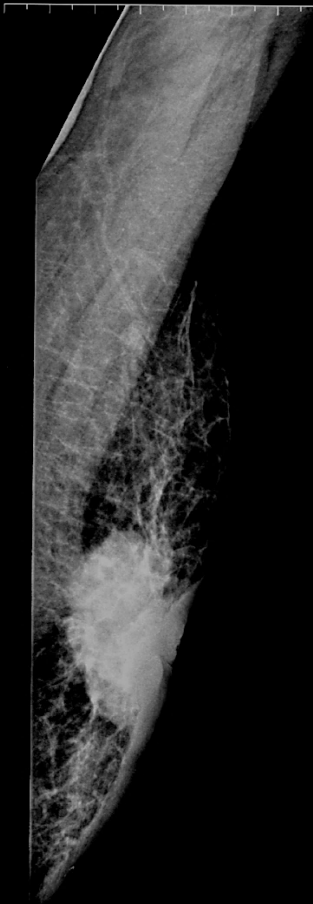mass
Round
obscured

L-cc



male Breast
increase risk
1st+2nd degree relative's female breast CA
regardless of
the male age

L-mlo



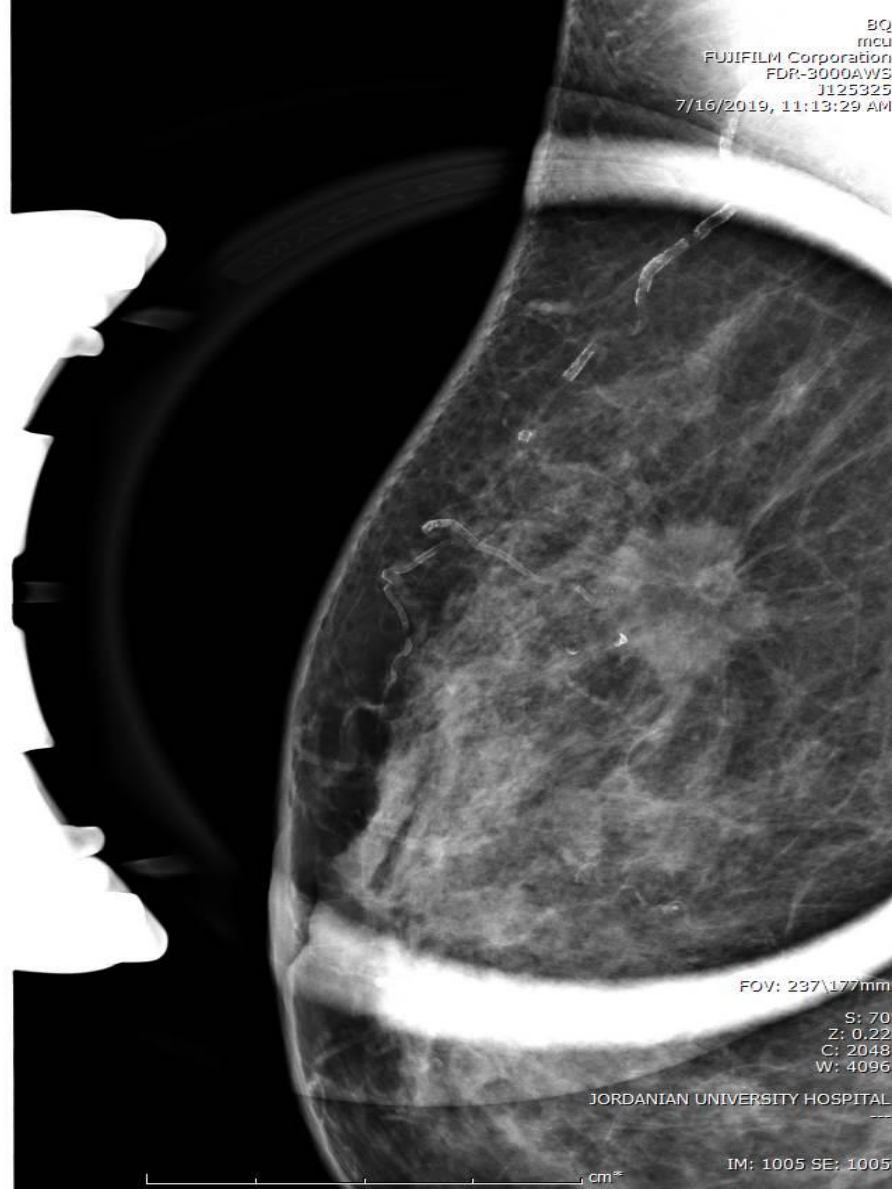
10

Iftikhar Gazi, Salamah
1170635
219090134\XR0010
7/1/1961
58 YEAR
F
RCC M

BQ
mcu
FUJIFILM Corporation
FDR-3000AWS
J125325
7/16/2019, 11:13:29 AM

Study:CAD SR object not available

Compressed 27:1
Page: 1 of 1



FOV: 237\177mm

S: 70
Z: 0.22
C: 2048
W: 4096

JORDANIAN UNIVERSITY HOSPITAL

IM: 1005 SE: 1005

cm

Im: 7/23

Se: 1

dfghdfhfg fghfghf

346456df

NATIONAL CENTER FOR DIABETES - X-RAY

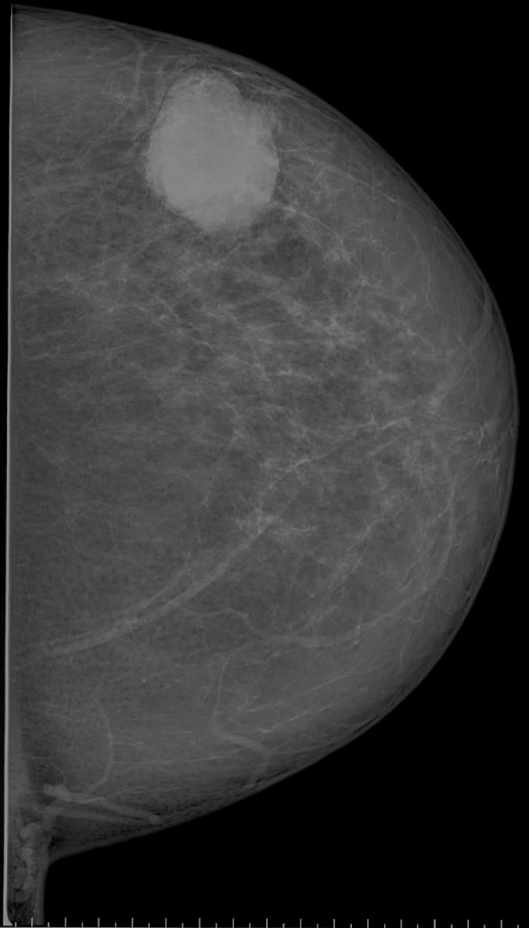
73 %

S:139 L:2.4E1_s:973 - 30453319

SID:fd_00000023

L-cc

Spiculated
BIRADS 5



Screening, Cranio-caudal Lt

Feb 10, 2013 2:00:30 PM

110811
WL: 2533 WW: 2761

FAWZEYEH MAHMOUD, *Jan 1, 1952

12/10/2011 01:01:01

Im: 6/23

Se: 1

dfghdfhfg fghfghf

346456df

NATIONAL CENTER FOR DIABETES - X-RAY

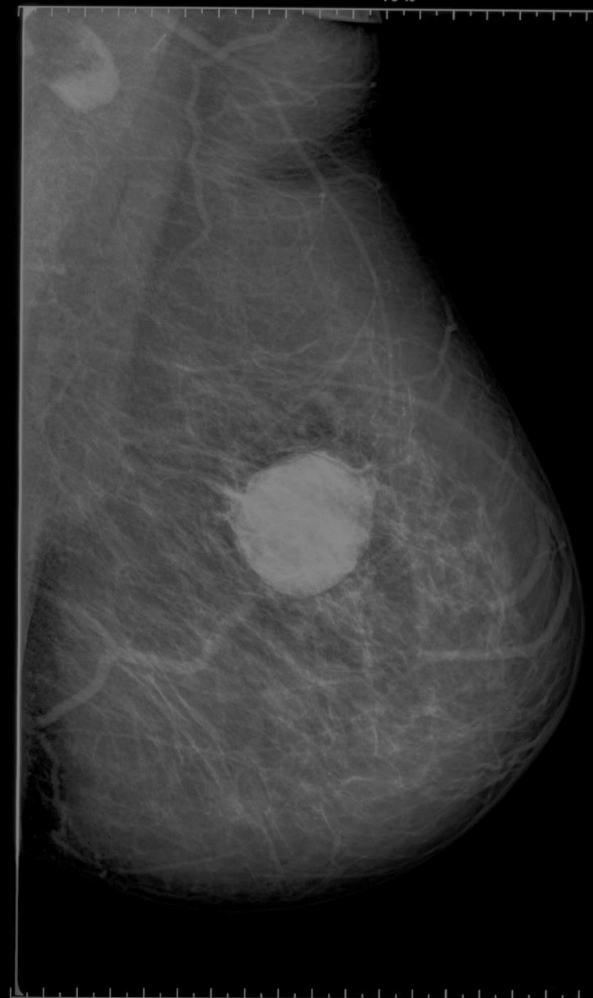73 %

S:348 L:2.4E1_s:469 - 30453173

SID:fd_00000023

L-mlo

2



Screening, Oblique Lt

Feb 10, 2013 1:58:59 PM

110811
WL: 2533 WW: 2761

FAWZEYEH MAHMOUD, *Jan 1, 1952

12/10/2011 01:01:01

- MLO
 - calcified vessel
 - popcorn calcification
- BI-RADS 2
(involuting fibroadenoma)

