

# Lids and Lacrimal

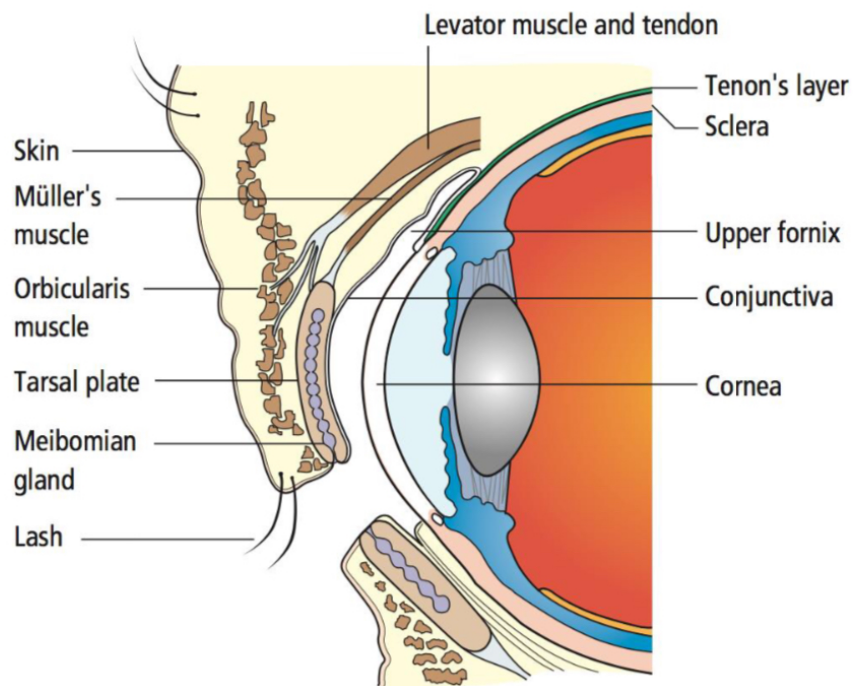
Osama H. Ababneh, MD  
The University of Jordan

## 16-22 blinks/min Anatomy of the eyelid

Eyelid structures :

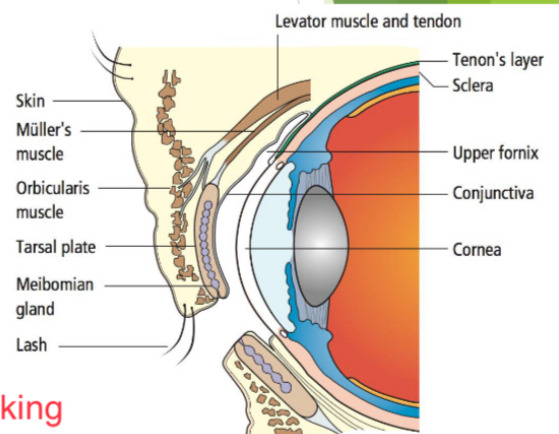
- 1-Skin Thinnest skin in the body (no subcutaneous tissue)
- 2-Orbital septum Adv.: facilitates movement  
Dis.: grafting is difficult (best graft donor site is the other eyelid)
- 3-Orbital fat
- 4-Muscles;  
  - A- Orbicularis oculi muscle
  - B- Levator palpebrae superioris muscle
  - C- Superior tarsal muscle (Muller muscle)
- 5- Tarsal plates with Meibomian glands
- 6-Conjunctiva
- 7-Eyelashes

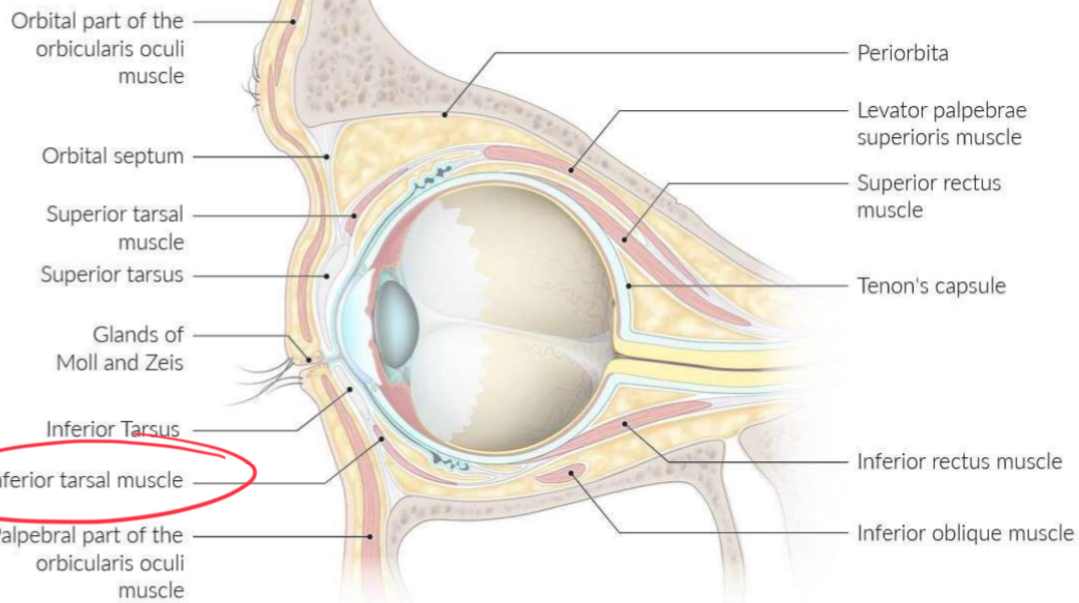
# Eyelids (Tarsus)



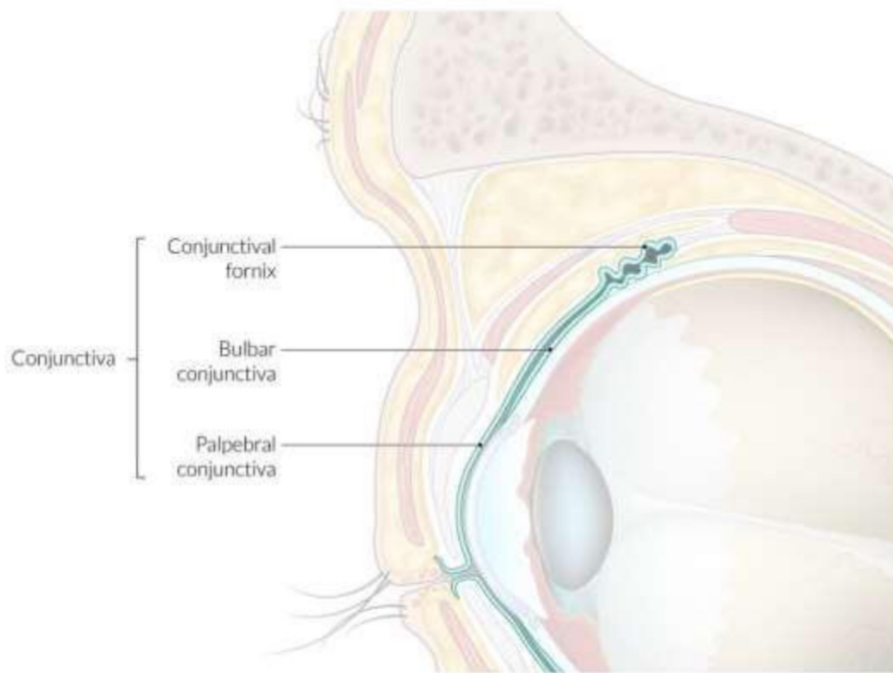
## Eyelids

- ▶ **Levator muscle:** main elevator of the upper lid, supplied by the 3rd CN.
- ▶ **Müller's muscle:** weaker elevator and supplied by sympathetic system
- ▶ **Orbicularis muscle:** for Lid closure, supplied by the 7th CN.
- ▶ **Meibomian glands:** embedded in the tarsal plates, produce oily secretions to stabilize the tear film and PREVENT EVAPORATION. + smooth blinking
- ▶ **Mucocutaneous junction.**





Pseudo-enophthalmus ( upper eyelid ▾ lower eyelid ▲)



The conjunctiva can be divided into the palpebral conjunctiva (covering the eyelids), the bulbar conjunctiva (covering the globe with its sclera), and the conjunctival fornix. The conjunctival fornices (superior and inferior; here only the superior fornix is depicted) feature numerous folds and connect the palpebral and bulbar parts of the conjunctiva. The border of sclera and cornea is called the corneal limbus.

# Eyelids

## ► Functions of the eyelids:

- 1- Physical protection to the eyes
- 2- Tear drainage
- 3- Maintaining normal tear film

Lacrimal pump failure: epiphora due to reduced tear outflow in the presence of patent lacrimal system and well positioned puncta (e.g: eyelid laxity)

# Pathologies;

- 1- Abnormal Lid Positions
- 2- Blepharitis
- 3- Benign Lumps and Bumps
- 4- Malignant Lumps
- 5- Lash Abnormalities
- 6- Lacrimal system



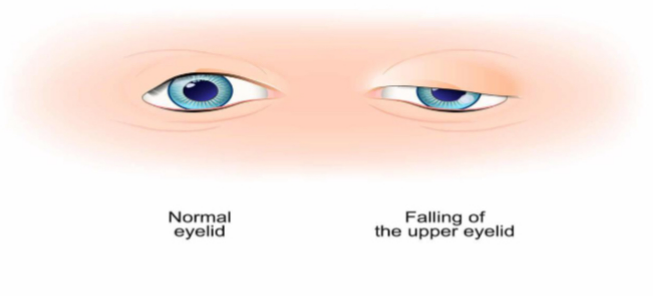
# I. Abnormal lid position

1. Ptosis
2. Entropion
3. Ectropion

## 1-Ptosis

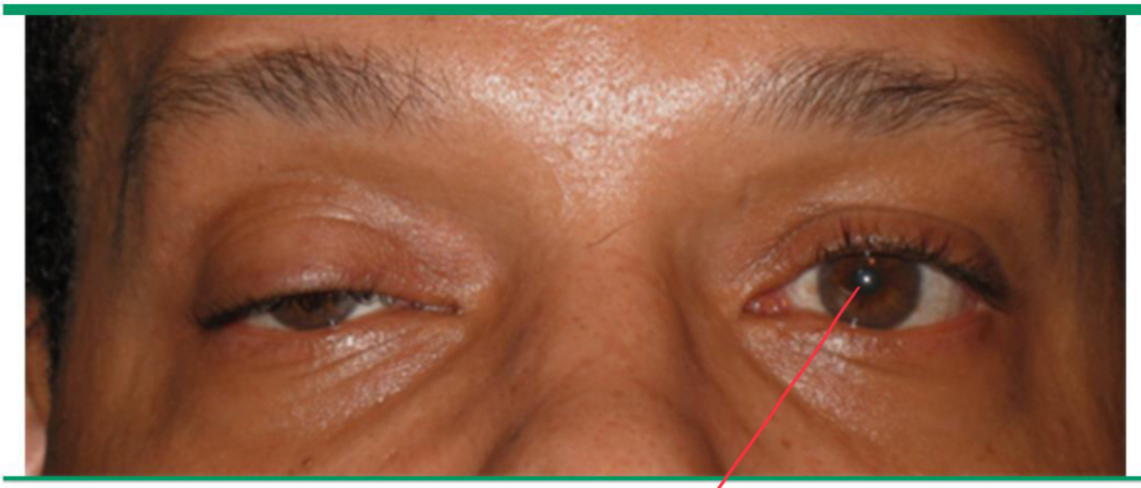- ▶ Normally the upper lid covers 1-2 mm of the upper limbus.
- ▶ **Ptosis** is abnormally low position of the upper lid.
- ▶ Patients present due to cosmetic reasons, vision impairment or due to the underlying cause.

### PTOSIS



# Ptosis

MRD1: the distance in (mm) between the reflex of light on the cornea & the upper eyelid



Cornel light reflex

# Ptosis

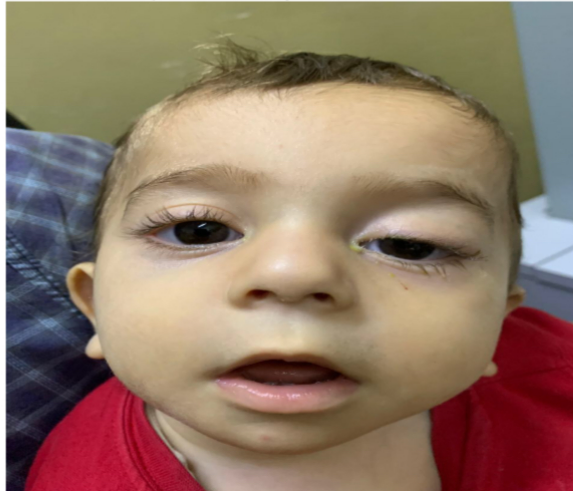## Causes:

1. Mechanical (anything preventing full eyelid opening):
  - ▶ Lid lumps (Excessive weight on the upper eyelid, e.g., hemangioma, hematoma, infections, tumors of the upper eyelid)
  - ▶ Lid edema
  - ▶ Lid scarring
2. Disinsertion of the aponeurosis of the levator muscle from its insertion on tarsus in elderly (most common cause of acquired ptosis) **Senile potsis**
3. Neurological:
  - ▶ 3rd CN palsy
  - ▶ Horner's
4. Myogenic:
  - ▶ Most common cause of congenital ptosis (Malformation of the levator **Fibrosis** palpebrae superioris muscle)
  - ▶ Myasthenia gravis
  - ▶ Muscular dystrophy
  - ▶ botulism

# Ptosis

## ► Signs:

1. palpebral aperture size reduction
2. Lid creases are absent or in abnormal position.
3. Horner's syndrome signs ( small pupil, anhydrosis )
4. 3rd CN palsy (large pupil, Diplopia)
5. Myasthenia Gravis (fatigue after repeated movements)

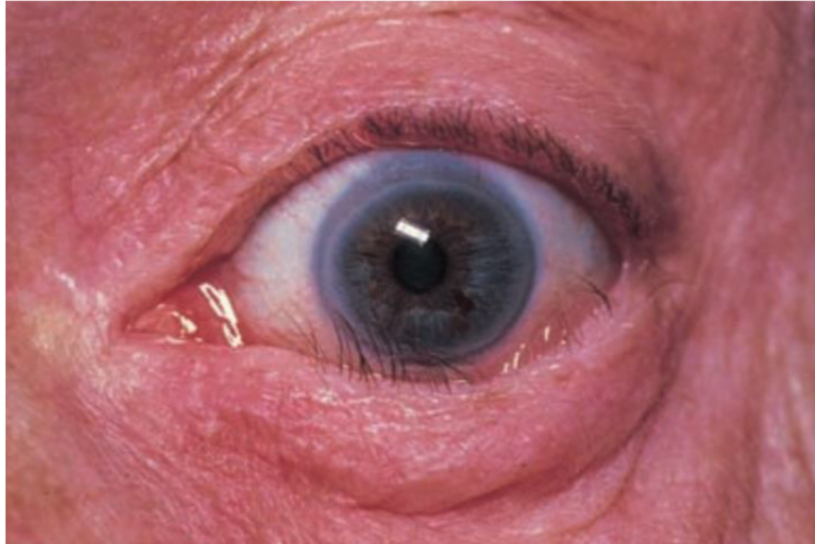


# Ptosis

## Management:

- Medical management for medically treated diseases such as Myasthenia gravis or of underlying cause.
- Otherwise --> Surgery
- In children, if visual axis is covered it may cause amblyopia (Lazy eyes).

## 2-Entropion: in turning of the eyelid



## Entropion

- ▶ Inward turning of the lid margin and lashes into the globe, usually the lower lid.
- ▶ May be induced by tightly closing the eye (spastic entropion).
- ▶ Patients complain of red, irritated eyes.
- ▶ **Involitional Entropion:** in elderly due to weakening of the lower lid retractors, so the **preseptal part of the orbicularis muscle override the pretarsal muscle**.
- ▶ **Cicatricial Entropion:** due to conjunctival scarring.  
Chemical injuries ( emergency )

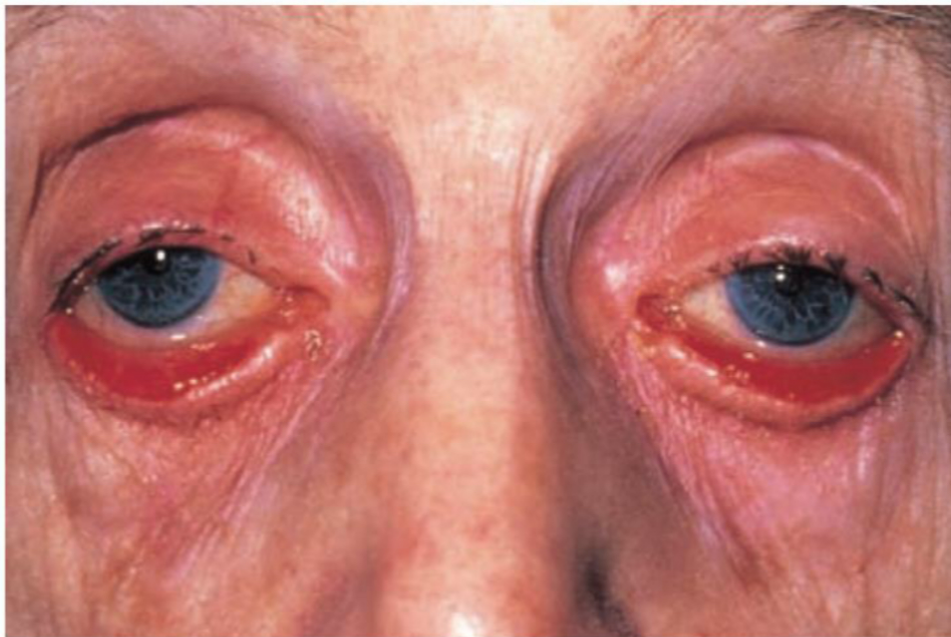

# Entropion

**Management: ( Treatment of the underlying cause)**

- ▶ Taping of the lower lid and Lubrication
- ▶ Botulinum toxin into the orbicularis muscle (palpebral part)
- ▶ Surgery

## 3-Ectropion

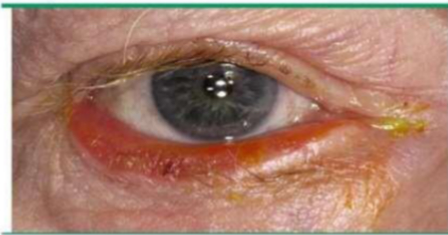



# Ectropion

- ▶ Eversion of the lid away from the globe.
- ▶ Causes:
  1. age related orbicularis laxity
  2. 7th CN palsy
  3. scarring of the periorbital skin
- ▶ Dry irritable eyes due to excessive exposure and tearing due to decreased tear drainage. **Dislocated puncta**
- ▶ Surgical management.

Ectropion



Outward turning of the lower eyelid with increased exposure of the ocular surface and sensitive mucous membrane of the inner lid, as well as disruption of normal tear drainage patterns.

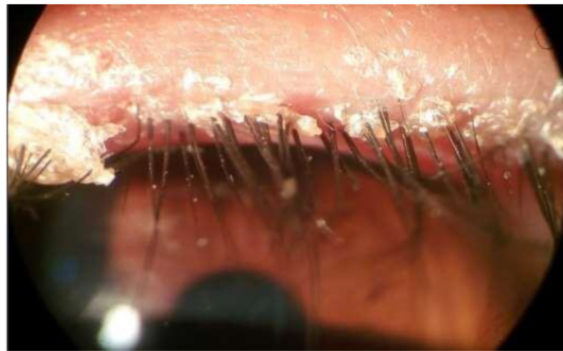UpToDate™

## II. Blepharitis; inflammation of the eyelid margins

- ▶ **Chronic** inflammation of the lid margins.
- ▶ Symptoms are red, itchy, sore eyes, worse in the morning. Accumulation of the *Staphylococcus* toxin ( no blinking to wash it off ) unlike dryness that gets worse at night (tear evaporation)
- ▶ **Anterior** vs. **Posterior** Blepharitis.
- ▶ Both are associated with atopic eczema, seborrheic dermatitis and rosacea.
- ▶ Chronic condition that require long term treatment.

## A- Anterior Blepharitis

- ▶ Inflammation concentrated along the eyelashes accompanied with squamous debris and collarettes around eyelashes.
- ▶ **Blepharokeratitis** occurs when the cornea is involved.
- ▶ Associated with Staphylococcus overgrowth which can cause **marginal keratitis** (ulceration of the peripheral cornea)

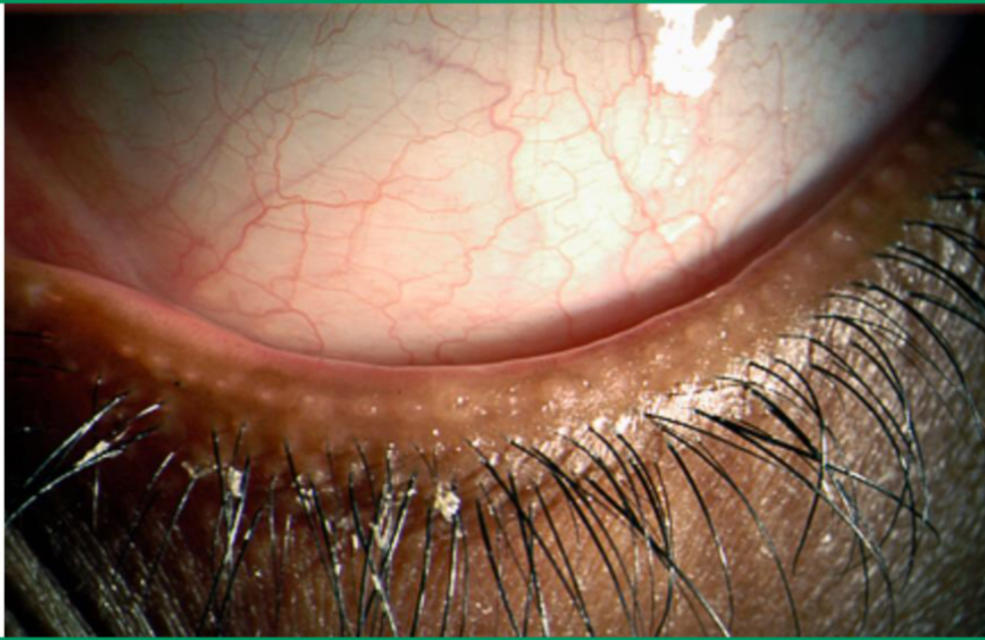


## Anterior Blepharitis

### ▶ Signs:

1. Scaling and redness of the lid margin
2. Ulceration : Staph infection
3. Collarettes formation (cylindrical dandruff)
4. Reduction in the number of eyelashes  
*Blepharitis is the most common cause*

# Anterior Blepharitis



Lower lid with inflammation with characteristic scales on the eyelashes.

## Anterior Blepharitis

### ► Management:

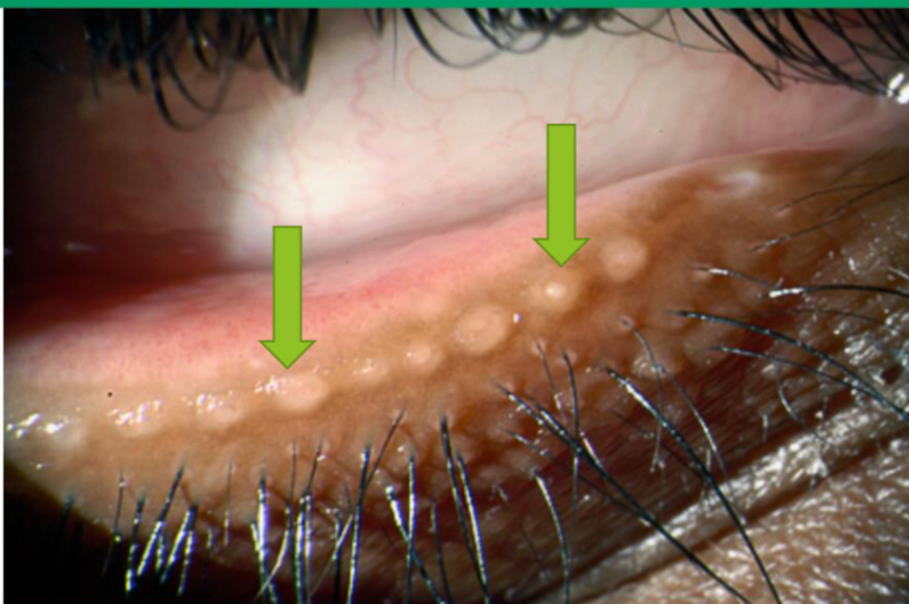
1. Lid toilet with bicarbonate solution or baby shampoo.
2. Topical steroids.
3. Topical antibiotics (fusidic acid eye ointment) or if necessary systemic (in case of long standing Staph infection).



## B- Posterior Blepharitis

- ▶ Usually caused by Meibomian gland dysfunction (MGD), where these glands are obstructed by squamous debris and the lipid secretions become viscous and cloudy.
- ▶ Lid margin and Conjunctiva may be injected.

## Posterior Blepharitis



Lower eyelid with characteristic posterior lid inflammation and oily white plugs visible at the meibomian gland openings.

# Posterior Blepharitis

## ► Management:

1. Lid massage after hot bathing.
2. systemic Azithromycin
3. Oral Doxycycline or tetracycline **Improves oil composition**
4. Artificial tears in case of eye dryness due to decreased oil secretions.

## III. Benign lid lumps

1. Chalazion
2. Molluscum contagiosum
3. Cysts
4. Squamous cell papilloma
5. Xanthelasma
6. Keratocanthoma
7. Naevus

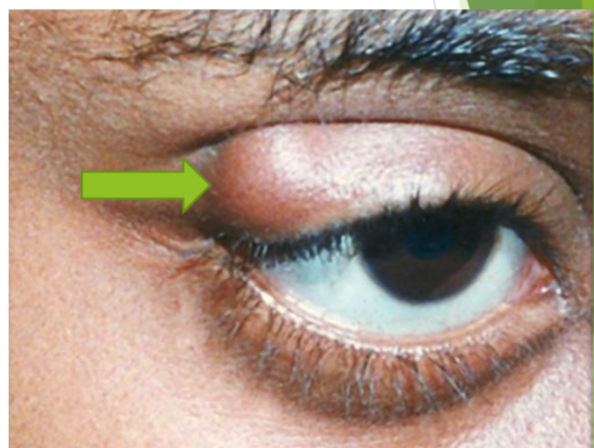
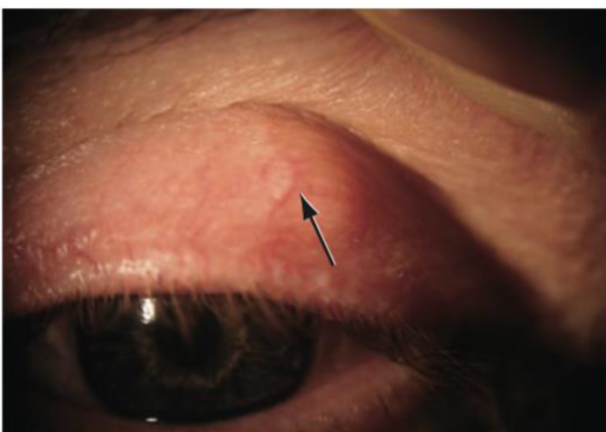


# 1- Chalazion

- ▶ Lipo-Garnuloma within the tarsal plate due to meibomian gland obstruction.
- ▶ Common and painless condition. → Obstruction no infection
- ▶ Resolves within 6 months, if persistent it is incised and curetted through the conjunctiva.

## Chalazion

There're multiple glands so it can happen to different ones at different times



RFs: acne / PCOS (and other diseases of hormonal disturbances)

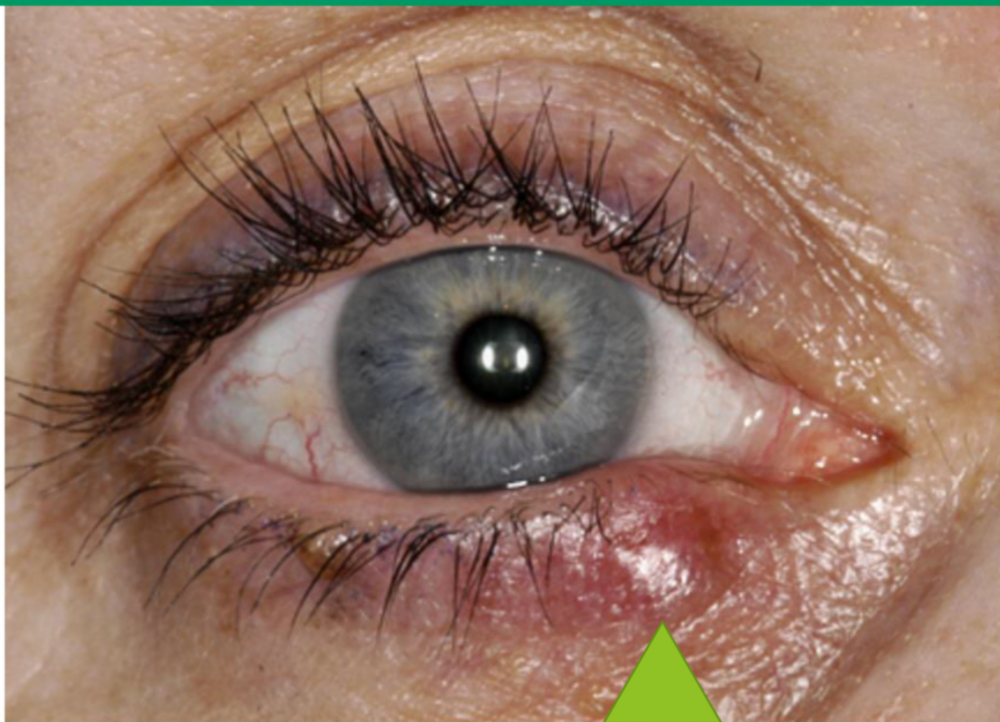
## 2- Hordeolum *Staphylococcus*

- ▶ **Abscess (*Internal hordeolum*):** painful abscess within the meibomion gland, managed by drainage and antibiotics.
- ▶ **Stye (*External hordeolum*):** very painful abscess of an eyelash follicle, managed by removal of the eyelash, hot compressors and topical antibiotics.

سكتا

Sometimes systemic

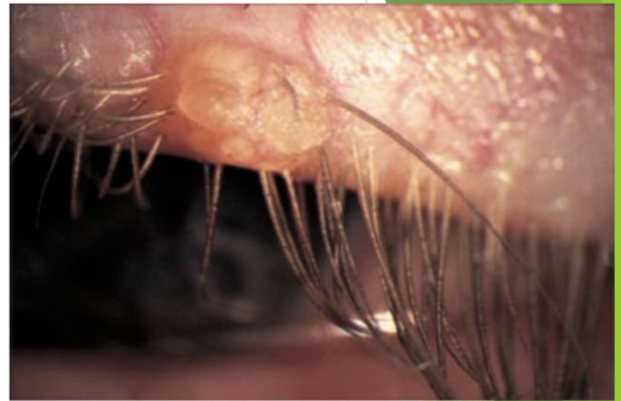### Hordeolum / Stye



# 3- Molluscum Contagiosum

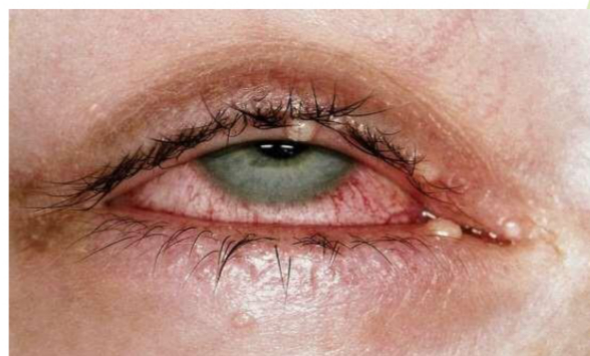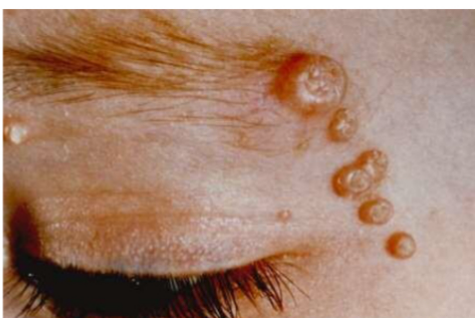Highly contagious

- ▶ Lesion on the lid margin caused by **Pox virus**.
- ▶ Irritated red eye.
- ▶ **Follicular conjunctivitis:** when lymphoid tissue forms on the tarsal conjunctivitis.
- ▶ Treated by excising the lesion.



## Molluscum Contagiosum

- ▶ Sex: ♂ > ♀
- ▶ Age: most common in childhood (peak incidence < 5 years of age) and early adolescence
- ▶ More common in warm and humid climates or areas with poor hygiene
- ▶ Up to 20% of HIV-positive patients have symptomatic infection





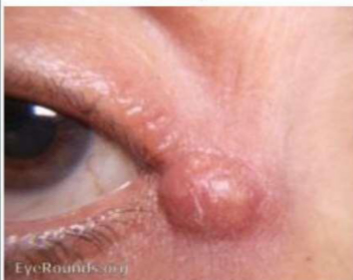# Molluscum Contagiosum

- ▶ **Pathogen:** a DNA poxvirus
- ▶ (molluscum contagiosum virus)
- ▶ **Transmission:**
- ▶ Direct skin contact (contact sports, sexually transmitted)
- ▶ Autoinoculation (scratching or touching lesion, e.g., while shaving)
- ▶ Fomites (e.g., on bath sponges/towels)
- ▶ **Risk factors:**
- ▶ **Regardless; it infects immunocompetent individuals especially kids**
- ▶ immunosuppression, active atopic dermatitis (in children),
- ▶ hot and humid climates, crowded living conditions.

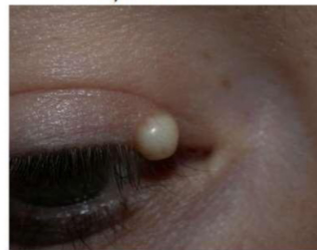## 4- Cysts

- ▶ **Sebaceous cysts:** cysts of the sebaceous gland
- ▶ **Cyst of Moll:** cyst of the eyelid **Close to the eyelashes**
- ▶ **Cyst of Zeis:** Opaque cyst due to obstructed accessory sebaceous gland.

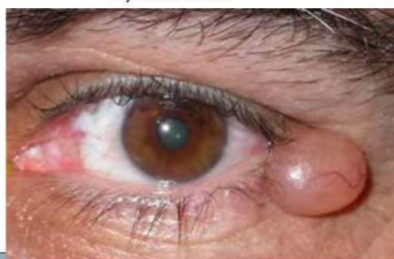Sebaceous cyst



Cyst of zeis



Cyst of moll



## 5- Squamous Cell Papilloma (Skin Tags)

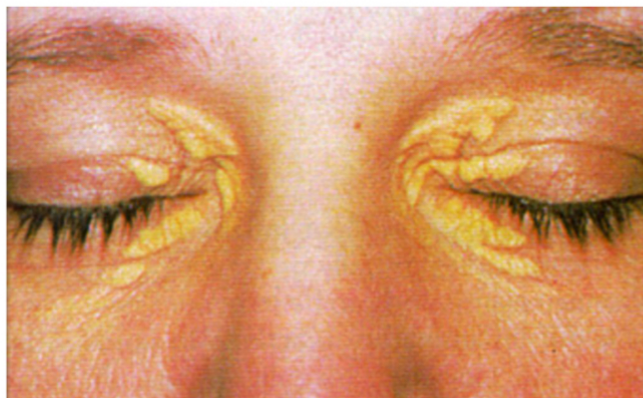- ▶ Frond like lesion
- ▶ Caused by Human papilloma virus
- ▶ Fibrovascular core and thickened squamous epithelium
- ▶ Excised for cosmetic reasons

Could be pedunculated or sessile



## 6- Xanthelasmas 30% hypercholes. 70% others

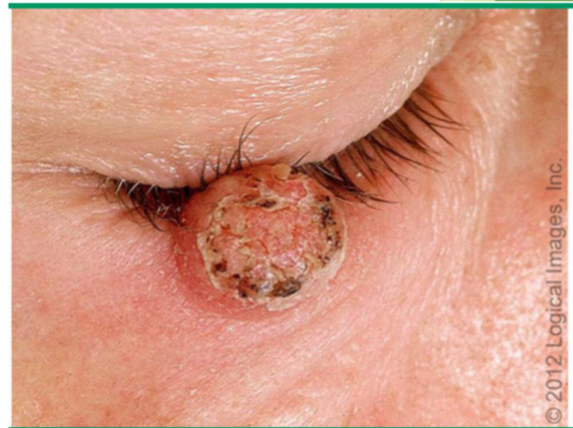
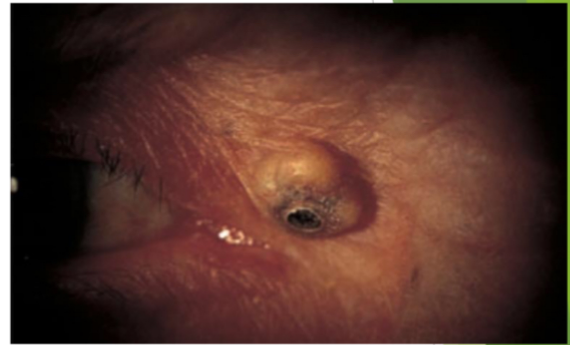
- ▶ Lipid bilateral lesions.
- ▶ Associated with hypercholesterlaemia.
- ▶ Check Blood Cholesterol.
- ▶ Excised for cosmetic reasons





## 7- Keratocanthoma

- ▶ Brownish, fast growing lesion with central crater filled with keratin. Growth over 3-6 weeks in contrast to malignancies ( months to years). *VS basal cell carcinoma (much slower growth (over 3 years))*
- ▶ Excision and Histology because it may have malignant features, and spontaneous regression will lead to scar formation.

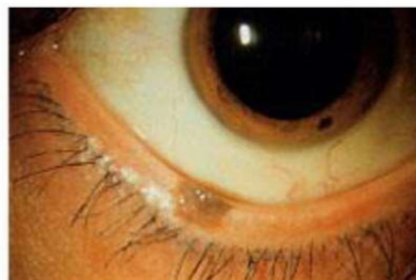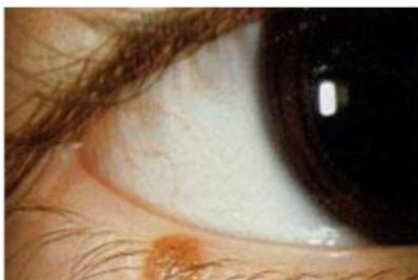


## 8- Nevus

*Appears in childhood/ grows and darkens with time*

Naevus (mole):

- \*Lesion that derived from the naevus cell (altered melanocytes)
- \*Can be pigmented or not
- \*No treatment is necessary



## IV. Malignant tumors

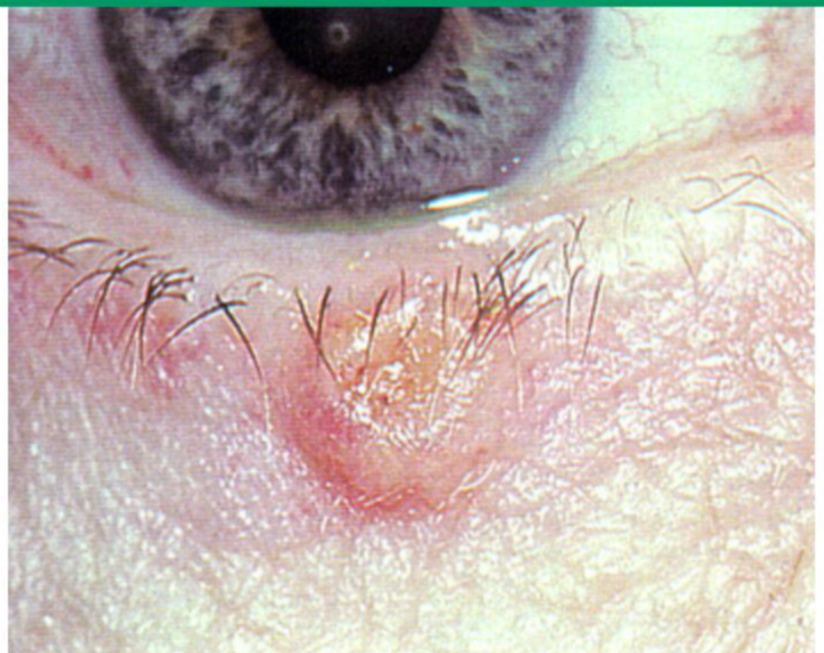### 1. Basal cell carcinoma (BCC):

- ▶ M.C malignant tumor of eyelids. 90% of eyelid tumors are BCC, and 10% of all BCC occur in the eyelids.
- ▶ Slowly growing, **locally invasive** and non-metastasizing tumor.
- ▶ **Painless** lesion that can be nodular, scaly or ulcerative (*Rodent Ulcer*)
- ▶ Therapy: -Excision biopsy with safe margins or Mohs Surgery. Other treatment modalities;
  - Cryotherapy
  - Radiotherapy
- ▶ Good prognosis.

## Basal Cell Carcinoma

### ▶ Risk factors :

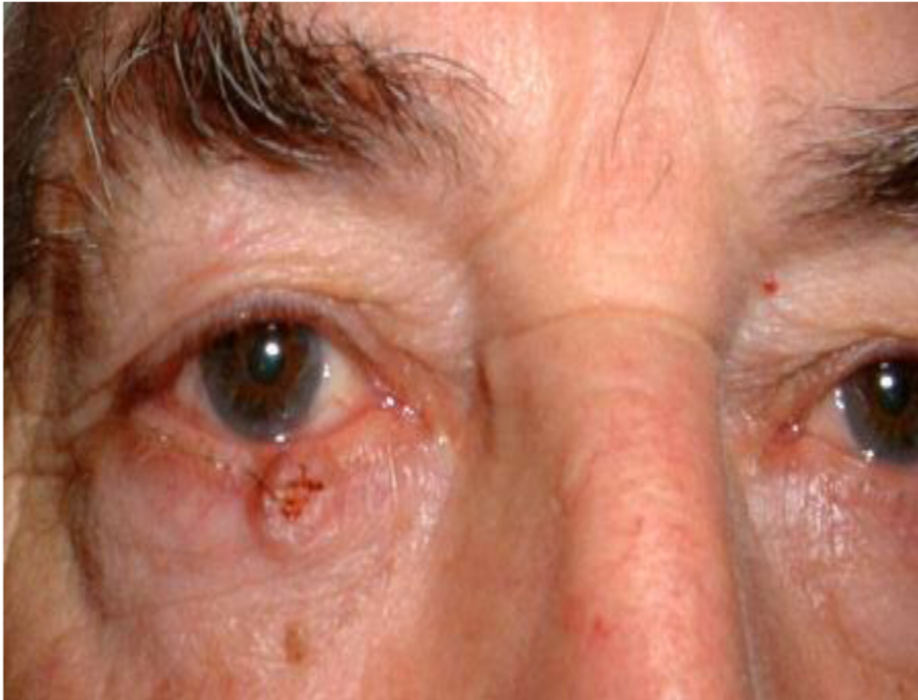- Fair-skinned individuals
- history of prolonged sun exposure.





Problems of excision:

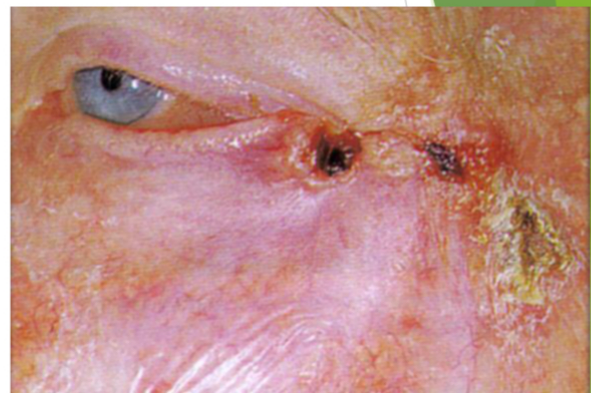- 1- the special nature of eyelids' skin
- 2- the scarcity of eyelid structures (unique to the eyelid)



## IV. Malignant tumors

### 2. Squamous cell carcinoma (SCC): 5%

- ▶ Less common but faster growing and more malignant which metastasize to regional lymph nodes
- ▶ Hard nodule or scaly patch
- ▶ Excisional biopsy with safety margin
- ▶ Squamous cell carcinoma can arise de novo or from preexisting actinic keratosis.

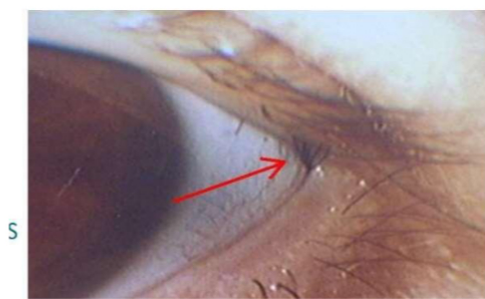


## V. Lashes abnormalities

### Trichiasis:

Eyelashes are directed towards the globe and the lid margin is normal (**Vs Entropion**).

- ▶ Lashes rub against the cornea and cause irritation and abrasion.
- ▶ Associated with **trachoma** (Chlamydia trachomatis) in the developing world.
- ▶ Managed by epilation of the offending lashes and local surgical resection. Electrolysis or cryotherapy for recurrent cases.



## The lacrimal system

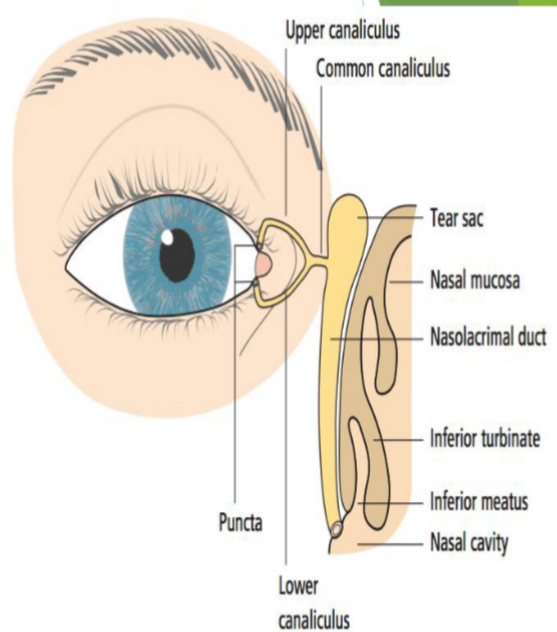
# The lacrimal system

- The lacrimal glands normally produce about 1.5  $\mu\text{l}$  of tears per minute.
- Some tears are lost by evaporation while the remainder drain via the nasolacrimal system into the nose.
- The tear film reforms with each blink.

## The Lacrimal System

Tears drains into:

1. upper and lower puncta
2. upper and lower canaliculi then into the common canaliculus
3. lacrimal sac then
4. The nasolacrimal duct then passes into the nose

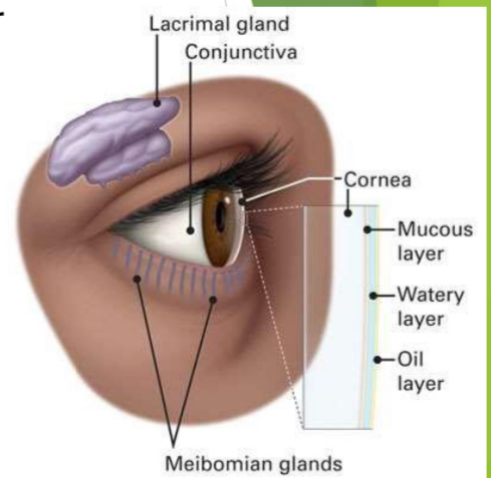




# The tear film

The tear film (10Um thick) covers the exposed ocular surface and comprises three layers:

- 1- A thin **mucin** layer in contact with the ocular surface and produced mainly by the conjunctival goblet cells
- 2- **Aqueous layer** produced by the lacrimal gland
- 3- A surface **oil layer** produced by the tarsal meibomian glands and delivered to the lid margins.

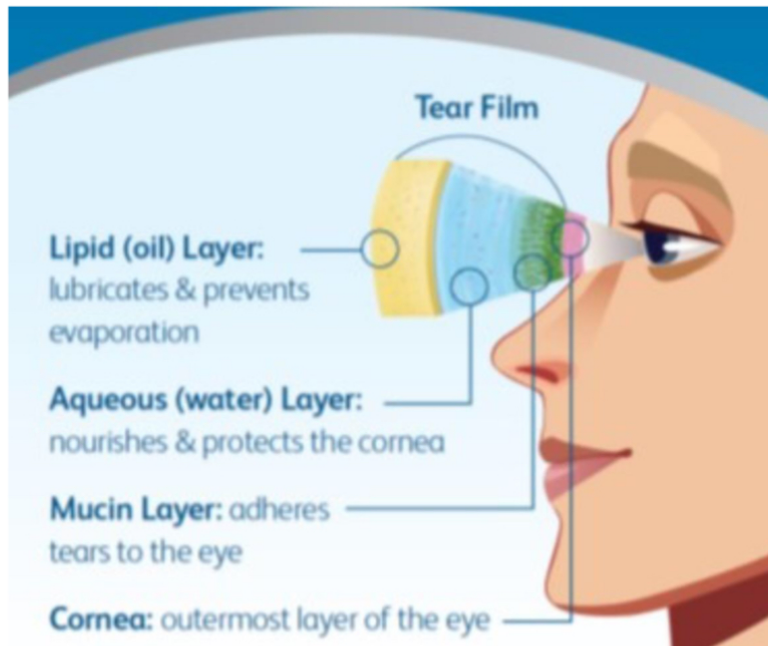


## The Lacrimal System

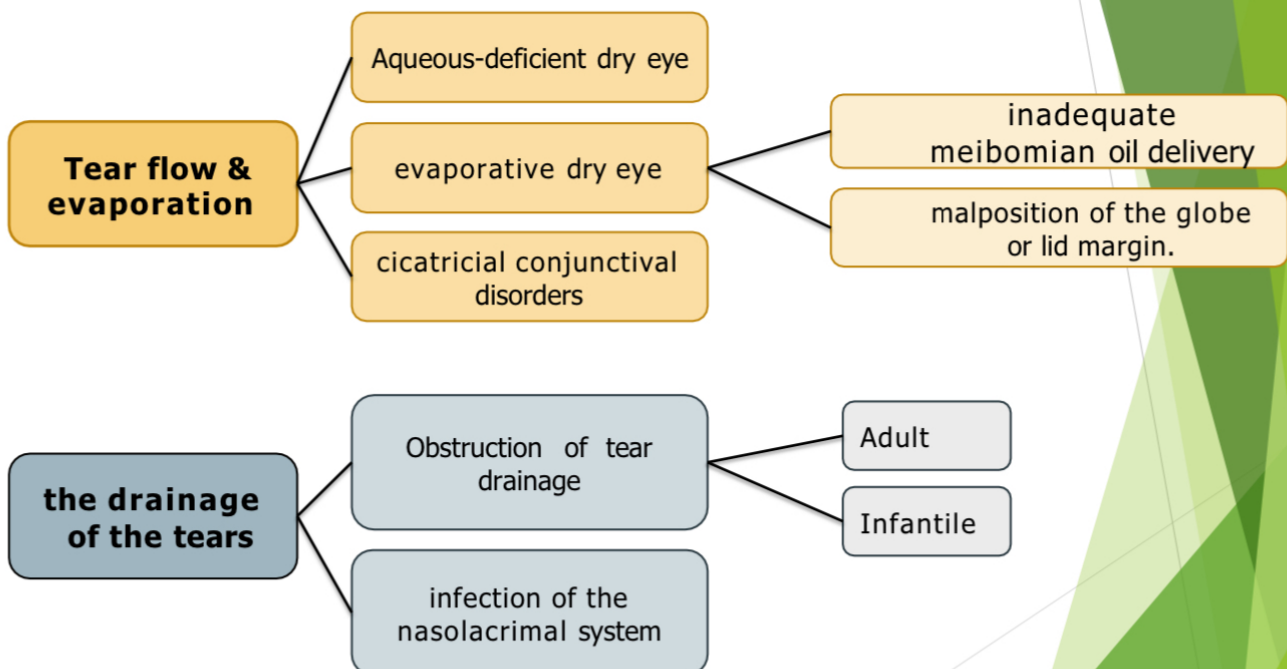
### ► Functions of the tear film:

1. Moistens the eye and prevent dehydration.
2. Provides smooth air/tear interface for distortion free refraction. **Mainly: the mucin layer**
3. Transmits Oxygen to the cornea.
4. Removes debris and foreign bodies.
5. Antibacterial (Iga, lysozyme, lactoferrin)

# The Lacrimal System



## Abnormalities of lacrimal system



# 1- Tear flow and evaporation problems → Dryness

- ▶ Deficiency of tear flow and volume and/or excessive evaporation lead to tear deficiency and ocular surface *hyperosmolarity*.
- ▶ This results in ocular surface damage, inflammation, discomfort and visual loss (**Keratoconjunctivitis Sicca**)

## Aqueous-deficient dry eye

- ▶ Occur due to deficient Lacrimal gland secretions.
- ▶ More common in elder women.
- ▶ Mainly due to **Sjogren's syndrome** (Primary or Secondary)

# Aqueous-deficient dry eye

- ▶ **Primary Sjogren's syndrome:** autoimmune disease which causes inflammation and dysfunction of glands.
- ▶ Associated with Dry mouth and MGD.
- ▶ **Secondary Sjogren's syndrome:** accompanied with other autoimmune diseases (Rheumatoid arthritis, SLE, Scleroderma)
- ▶ Dx: decreased salivary and lacrimal functions, T-cell infiltrates in minor salivary gland bx, anti-Rho and anti-La titers.

# Aqueous-deficient dry eye

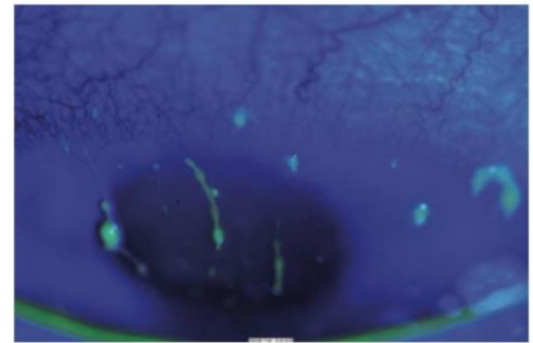
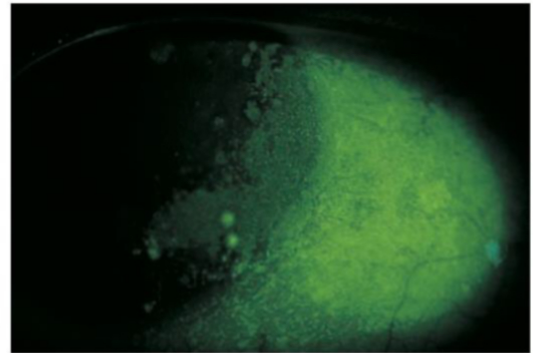
- ▶ **Symptoms (Non-Specific):**
  1. Burning eyes
  2. Photophobia
  3. Heaviness of the lids
  4. Ocular fatigue
  5. Grittiness (sand sensation)
  6. Worse in the evening
  7. Visual acuity affected due to corneal damage.



# Aqueous-deficient dry eye

## ► Signs with fluorescein stain:

1. Early break up of the tear film after 5 seconds of blink suppression
2. Punctate staining of the eye with fluorescence will show small dots of fluorescein over the exposed corneal or conjunctival surface
3. Filamentary keratitis (tags of abnormal mucus)



# Aqueous-deficient dry eye

## Management:

1. Artificial tears
2. Shielded spectacles
3. Puncta plugs or surgical occlusion
4. Topical anti-inflammatory (cyclosporin)

## Prognosis:

- Mild cases respond to artificial tears.
- Severe cases may be difficult to treat

## 2-Evaporative Dry Eye

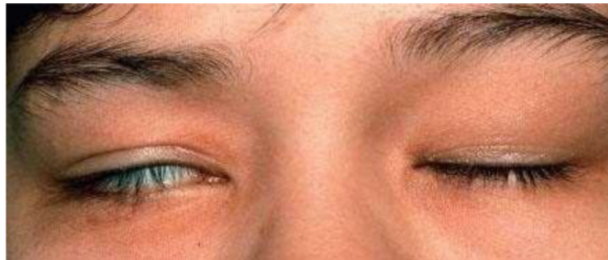**A-** Inadequate Meibomian oil delivery (MGD):

Extensive Meibomian gland obstruction → deficient tear film lipid layer → ↑ water loss from eyes.

treatment as in posterior blepharitis.

**B- Malposition of the globe or lid Margin:**

- ▶ Ectropion
- ▶ Lagophthalmos: Incomplete lid closure as in 7th CN palsy.
- ▶ Proptosis
- ▶ Infrequent blinking (Parkinson's)



## Cicatricial conjunctival disorders

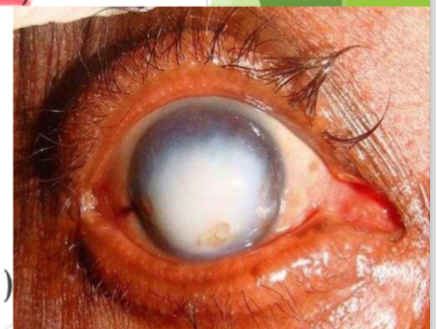- Loss of goblet cells occurs in most forms of dry eye, but particularly in cicatricial conjunctival disorders such as erythema multiforme (Stevens-Johnson syndrome).
- 'target' lesions on the skin and discharging lesions on the eye, mouth and vulva
- In the eye this causes conjunctival shrinkage with adhesions forming between the globe and the conjunctiva (symblepharon)

Goblet cells are lost also in:

- 1- chemical burn of the eye
- 2- Trachoma

3- vit A deficiency-xerophthalmia

(corneal melting and perforation "keratomalacia")



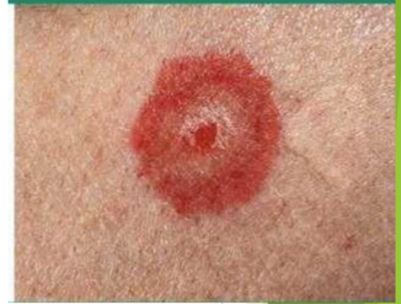# Cicatricial conjunctival disorders

## Symptoms & signs

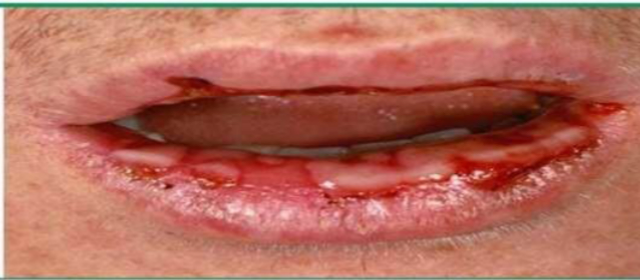Similar to aqueous deficiency  
Examination may reveal scarred abnormal conjunctiva and area of fluorescein staining

**Treatment:** artificial lubricant

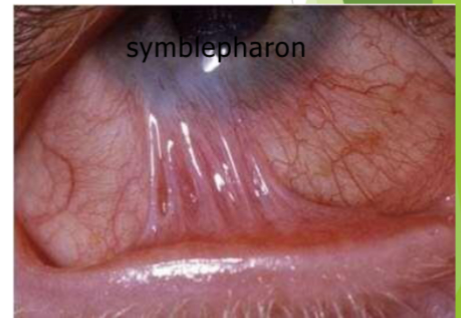Typical target lesion of erythema multiforme



Erythema multiforme



Mucosal erosions and crusts on the lips of a patient with erythema multiforme.



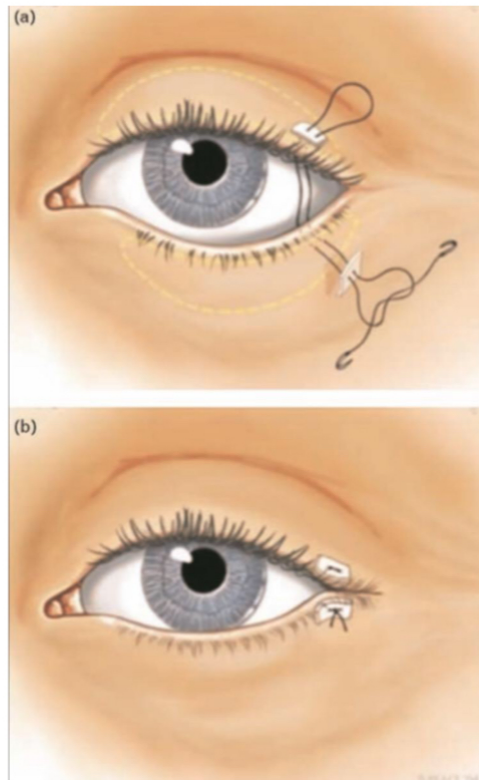
# Evaporative Dry Eye

## Management:

- ▶ Correction of lid deformity
- ▶ Artificial tears and lubricants
- ▶ Local Botulinum toxin injection into the levator muscle in case of incomplete closure **Dis.: unpredictable outcome**
- ▶ Lateral Tarsorrhaphy

# Lateral Tarsorrhaphy

e.g: TED



## Tear Drainage Disorders

➔ Tearing

- ▶ Either due to irritation of the ocular surface or due to occlusion of the drainage system (**Epiphora**)



# Infantile Drainage Obstruction

- ▶ The nasolacrimal system canalizes and become patent near Term period.
- ▶ Watery eyes will result from failure of the distal end of the nasolacrimal duct to canalize.
- ▶ Obstructed canaliculi may result in mucocele or Dacryocystitis.
- ▶ **The conjunctiva is not inflamed.**
- ▶ Dx: pressure over lacrimal sac → discharge from puncta
- ▶ Treatment: mostly resolves spontaneously in the 1<sup>st</sup> year of life
- ▶ If not → probing to perforate the occluded membrane through the lacrimal duct

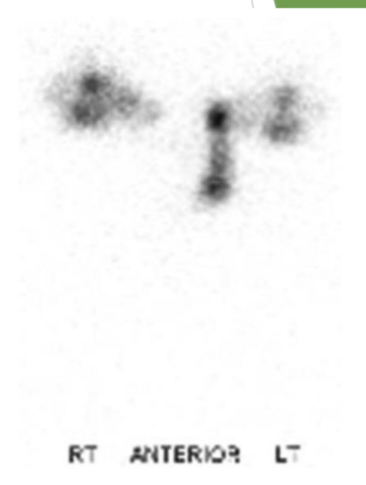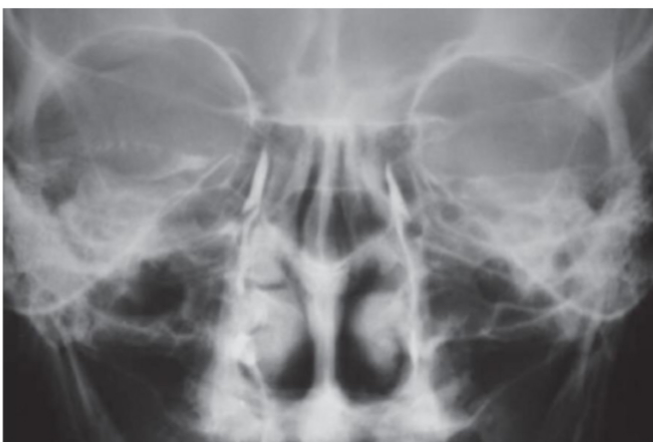
# Adult Drainage Obstruction

- ▶ Most common site of obstruction is the nasolacrimal duct, but can be present anyway in the tract.
- ▶ **Causes:**
  1. Infections
  2. Direct Trauma, Fractures
  3. Topically applied drugs
- ▶ Present with watery eyes, stickiness and white eyes, worse in cold or windy weather.

# Adult Drainage Obstruction

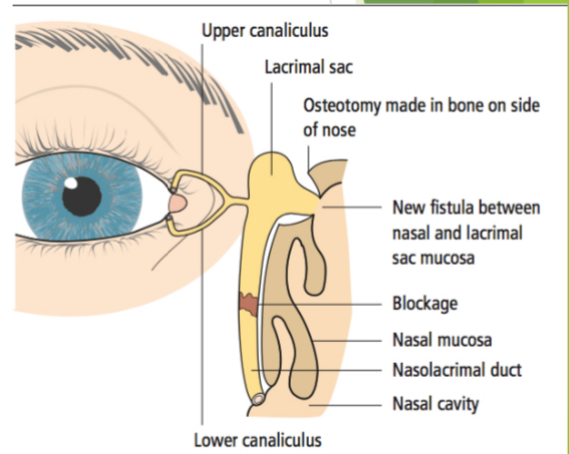
- ▶ Stenosed punctum can be seen on slit lamp.
- ▶ **Patency of the Nasolacrimal system can be assessed by:**
  1. Syringing normal saline into the canaliculi.
  2. Fluorescein dye disappearance after 5 minutes.
  3. **Dacryocystogram:** radio-opaque dye followed by X-ray
  4. **Dacroscintogram:** Radioactiveisotope followed by gamma camera

# Adult Drainage Obstruction



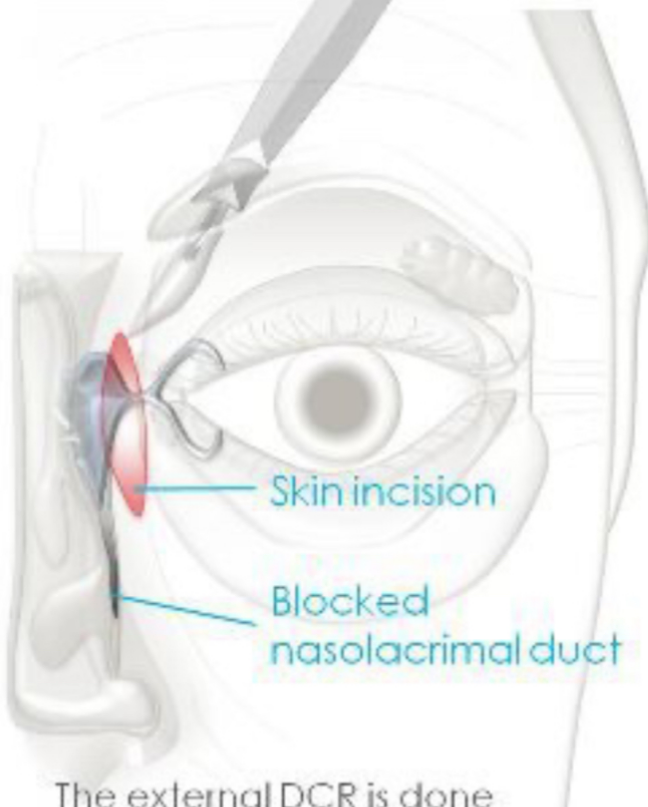
# Adult Drainage Obstruction

- ▶ **Management:**
- ▶ Exclude other ocular diseases causing watery eyes.
- ▶ Dacryocystorhinostomy (DCR):



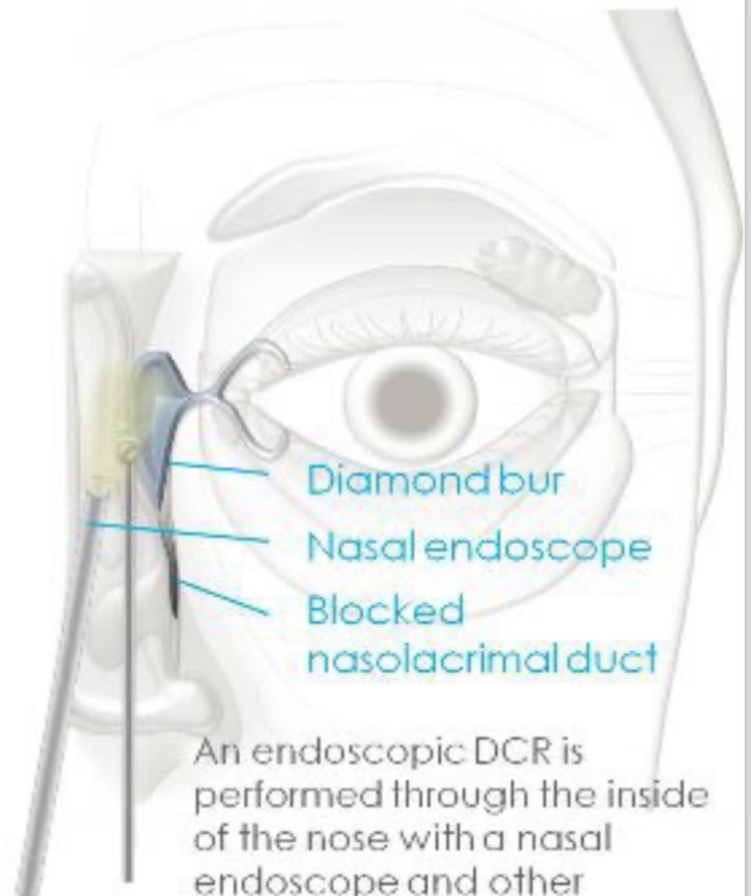
To make the tears drain directly into the nose

External DCR



The external DCR is done through a small incision in the skin, between the eye and the nose.

Endoscopic DCR



An endoscopic DCR is performed through the inside of the nose with a nasal endoscope and other instruments.

# Nasolacrimal system infections

- ▶ **Dacryocystitis:** mostly due to obstruction of the system.
- ▶ Staph. or Strep. infection.
- ▶ Presents with painful swelling on the medial side of the orbit
- ▶ Treated with systemic antibiotics.
- ▶ **Mucocele:** collection of mucus in an obstructed sac, usually painless (not infected).
- ▶ DCR is done in both cases.

## Acute Dacryocystitis

No ciliary injection

