

Stridor

Dr. Lubna khreesha
Associate professor
Head of Otolaryngology-
Head & Neck Surgery
The University of Jordan

Introduction

- ▶ Stridor is a noisy breathing due to turbulent airflow while passing through a partially obstructed airway at the level of the supraglottis, glottis, subglottis, and/or trachea
- ▶ Not a disease... It is a symptom or a sign.
- ▶ Stridor may be inspiratory, expiratory, or biphasic depending on its timing in the respiratory cycle.
- ▶ flexible and/or rigid endoscopy is required to adequately evaluate the etiology of stridor, and additional imaging studies may be required.

Pathophysiology

- ▶ **How does stridor occur?**
- ▶ When air passes through a narrowed flexible airway in a child, the lateral pressure that holds the airway open can drop precipitously (the Venturi principle) and cause the tube to close. This process obstructs airflow and produces stridor.

How to approach stridor ?

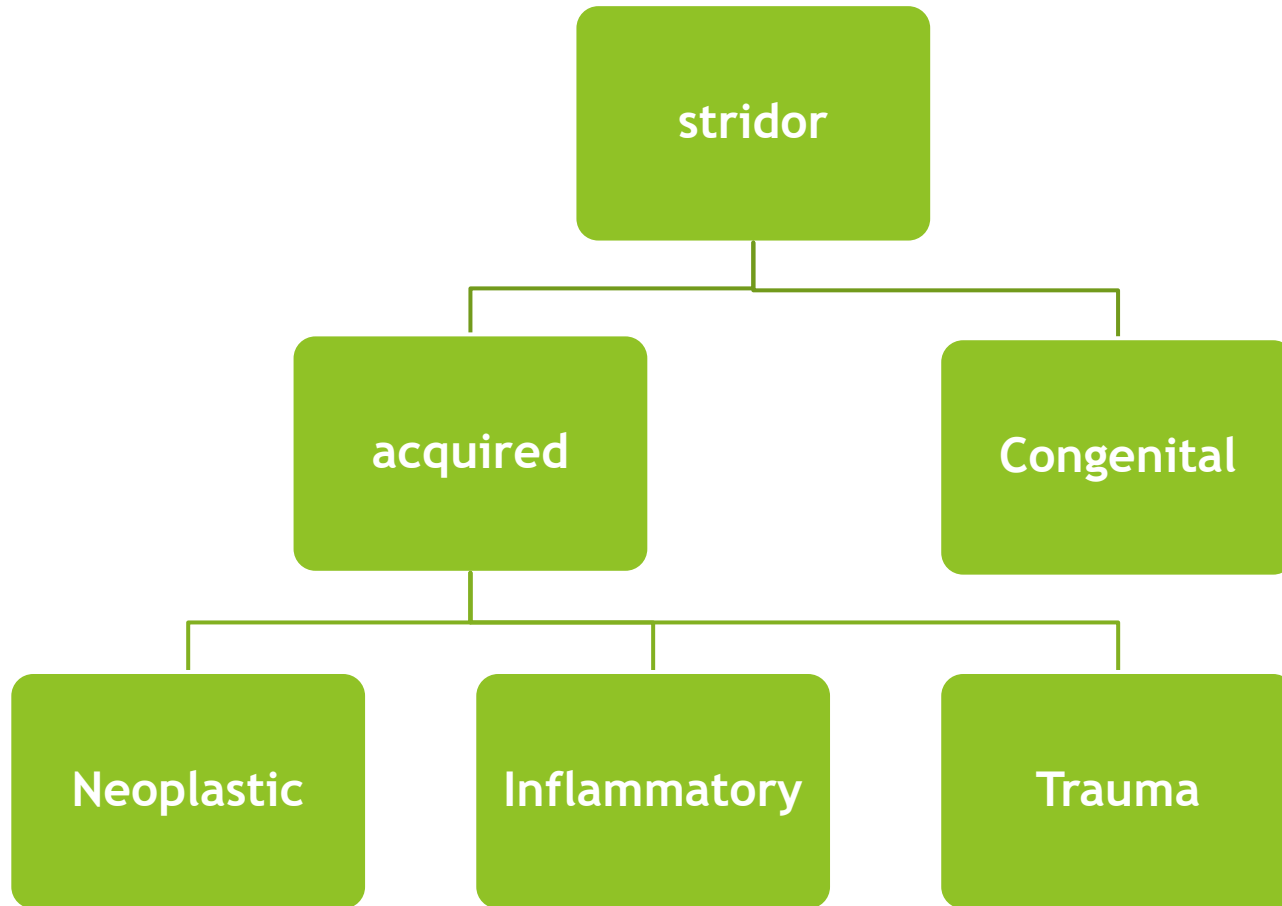
- ▶ **History:**

- In relation to stridor
- To the patient

- ▶ **Physical examination:**

- Look always for signs of distress
- Proper assessment include laryngoscopy

Causes



Congenital Stridor

- Laryngomalacia (most common cause of inspiratory sounds in infants in general)
- Vocal cord paralysis.
- Subglottic stenosis.
- Laryngeal webs.
- Hemangiomas and Lymphangiomas.
- Vascular causes, e.g. double aortic arch
- Laryngeal Cysts.

Laryngomalacia

- It is the most common cause of inspiratory stridor in the neonatal period and early infancy and accounts for up to 75% of all cases of stridor.

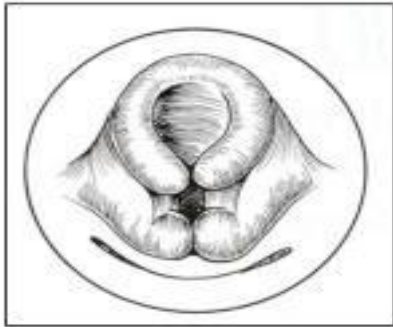- Delayed cartilage development characterized by

- Softening of the laryngeal cartilage

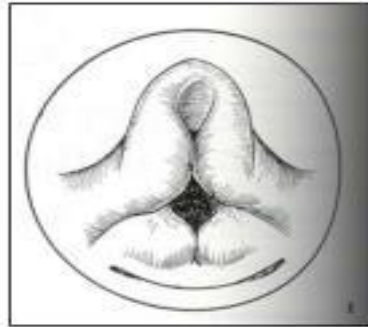
- Omega-shaped epiglottis.

- Due to inadequate support, there will be severe enfolding of the epiglottis and aryepiglottic folds during inspiration resulting in stridor.

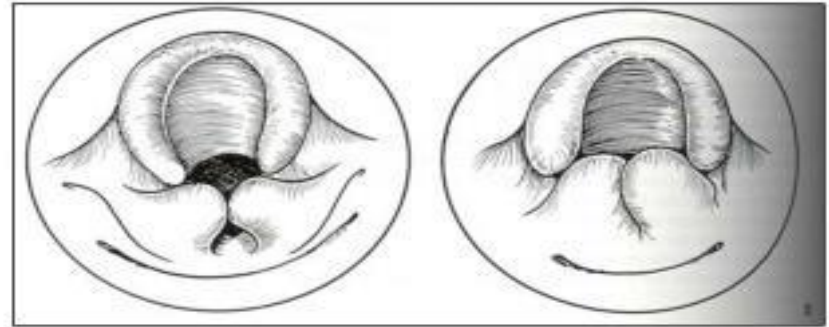
Laryngomalacia Classification



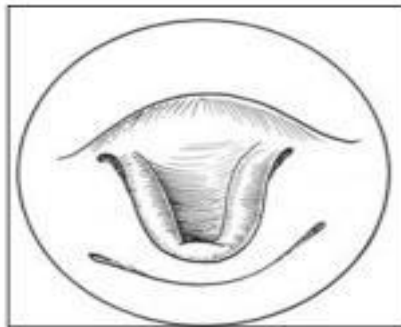
Type I



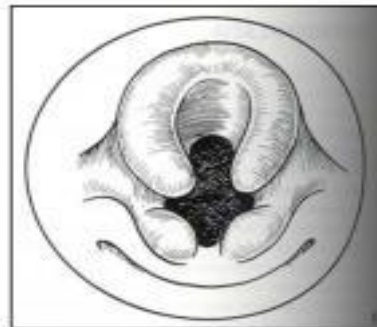Type II



Type III



Type IV



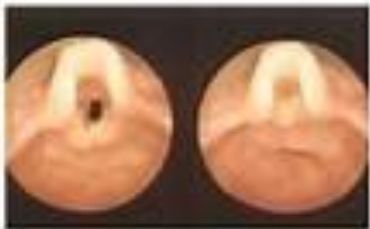Type V

Kay DJ, Goldsmith AJ. Laryngomalacia: A Classification System and Surgical Treatment Strategy. *Ear Nose Throat J.* 2006 May;85(5):328-31, 336.

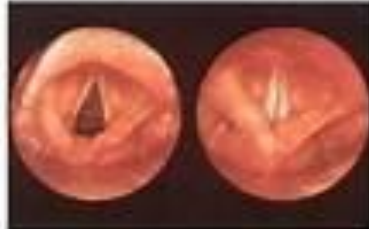Laryngomalacia

LARYNGOMALACIA

Laryngomalacia

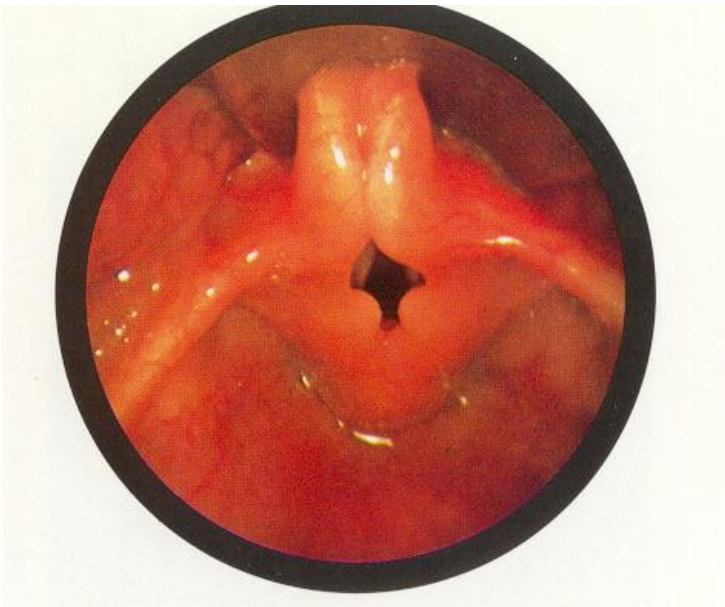


Normal larynx



- ▶ Clinical picture. Stridor aggravated. By supine position and head flexion, relieved by prone position and head extension.
- ▶ Definite Dx is through laryngoscope exam.

Laryngomalacia



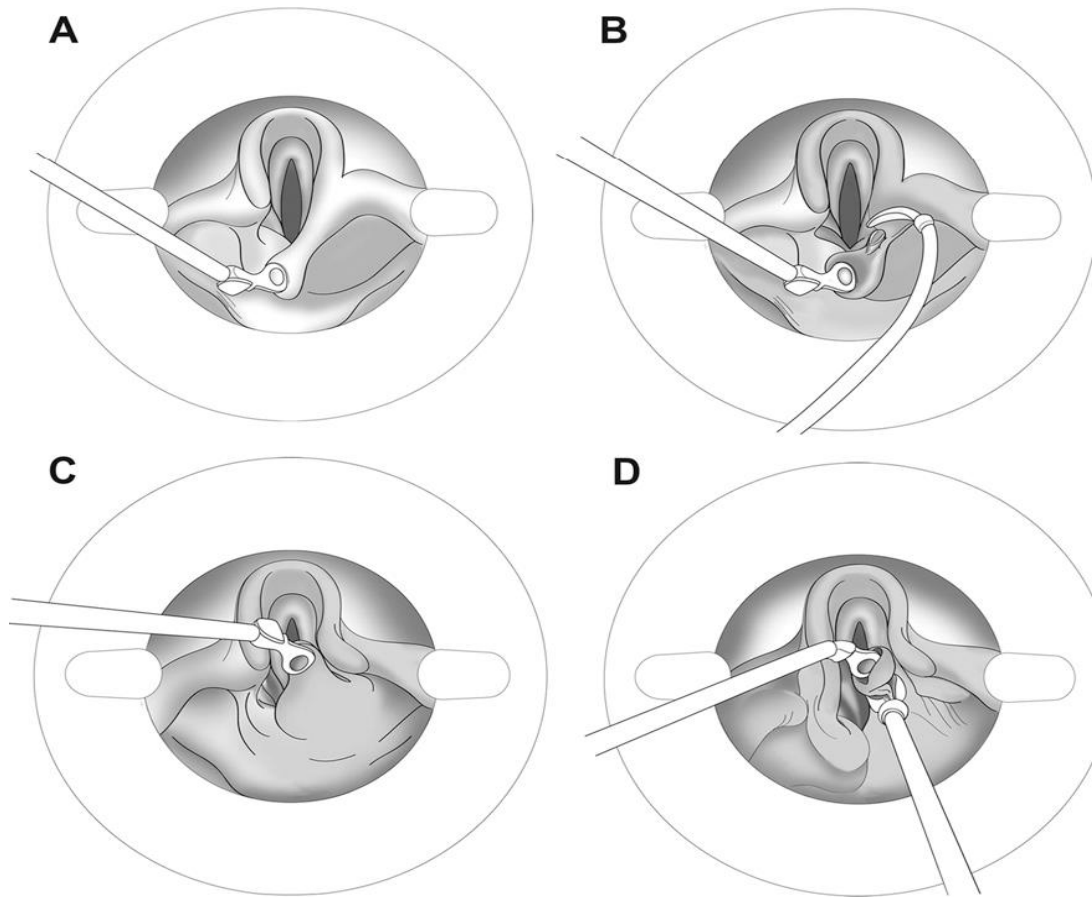
- ▶ **Laryngomalacia:** The epiglottis is small and curled on itself (omega-shaped). Approximation of the posterior edges of the epiglottis contributes to the inspiratory obstruction

Laryngomalacia

► Management

- Laryngomalacia is usually benign and self-limiting and improves as the child reaches the age of 1 year, sometimes till 2 years
- For severe cases, a tracheostomy may be needed till it resolves spontaneously.
- surgical correction or supraglottoplasty may be considered if tight mucosal bands are present holding the epiglottis close to the true vocal cords or redundant mucosa is observed overlying the arytenoids.

Supra-glottoplasty



Vocal Cord Paralysis

- Probably the second most common cause of stridor in infants.
- Could be either unilateral or bilateral.
- Patients with unilateral paralysis present with a weak cry and biphasic stridor that is louder when awake and improves when lying with the affected side down.
- It is usually associated with CNS abnormalities

Subglottic Stenosis

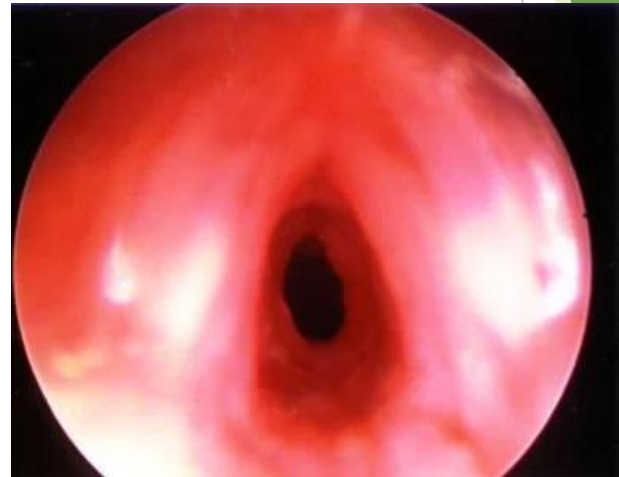
- ▶ Narrowing of the area below the VC, which is usually the narrowest in the URT in children
- ▶ subglottic stenosis can present with inspiratory or biphasic stridor. Symptoms can be evident at any time during the first few years of life.
- ▶ Can be congenital or Acquired

Acquired subglottic stenosis causes

- ▶ Idiopathic
- ▶ Autoimmune (Wegener's granulomatosis)
- ▶ Trauma
- ▶ Prolonged intubation
- ▶ GERD

Medical treatment

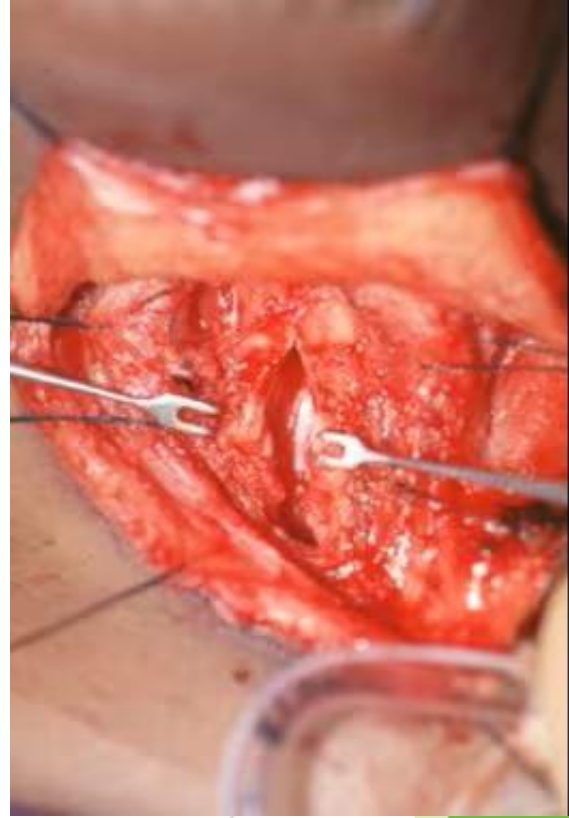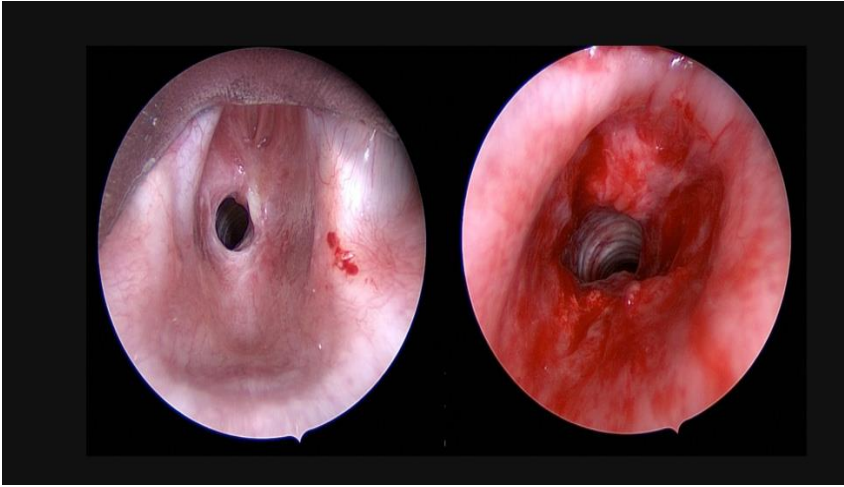
- ▶ If a granular or immature subglottic stenosis (SGS) treatment of the inflammatory process with oral or inhaled steroids sometimes can decrease the severity of disease.
- ▶ Findings from animal studies have shown that treatment with antibiotics and steroids can help improve an immature or granular subglottic stenosis (SGS)
- ▶ Once subglottic stenosis (SGS) is mature, medical therapy is almost always unsuccessful.
- ▶ However, suspected GER must receive aggressive medical treatment for optimal surgical results.



Surgical treatment

- ▶ In grade 1 and 2
- ▶ Endoscopic dilation: metal scopes, lasers (to cut open the narrowing), balloons (to stretch the narrowed area), or stents
- ▶ In grade 3 and 4
- ▶ First tracheostomy then At age of 4
- ▶ Cricotracheal resection: narrow segment is removed, and the ends of the airway sewn back together

Scar tissue  multiple procedures

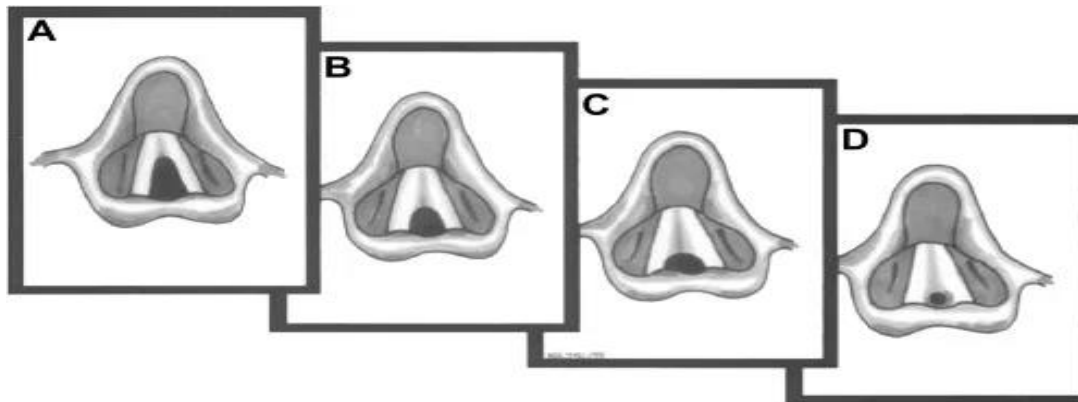


Laryngeal Web

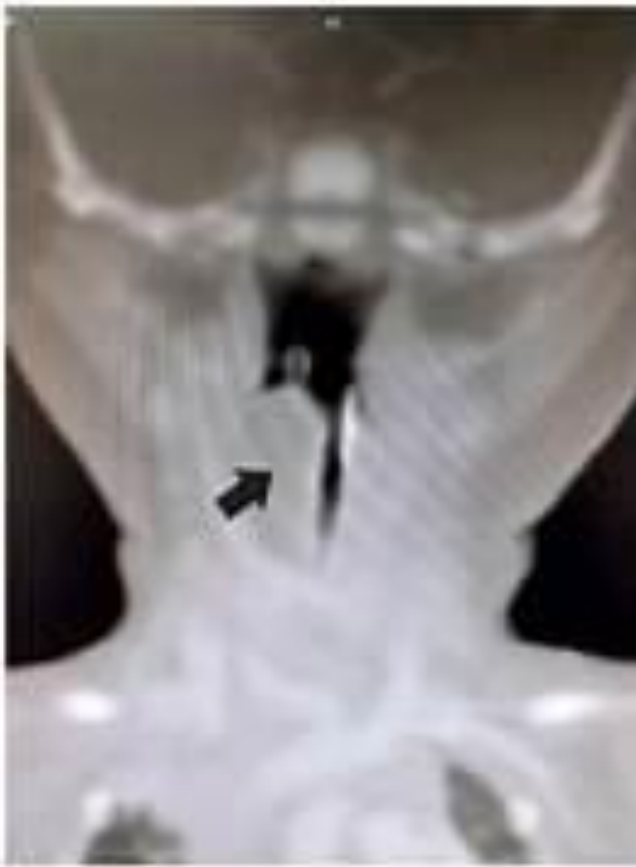Laryngeal webs are caused by an incomplete recanalization of the laryngeal lumen during embryogenesis.

Most (75%) are in the glottic area.

Infants with laryngeal webs have a weak cry and biphasic stridor.



Congenital Laryngeal Cyst



- ▶ Laryngeal cysts are a less frequent cause of stridor. They are usually found in the supraglottic region in the epiglottic folds. Patients may present with stridor, hoarse voice, or aphonia, or cysts may cause obstruction of airway lumen if they are very large.



Acquired Stridor

- ▶ Inflammation
- ▶ Trauma
- ▶ tumors

Acquired Stridor

❖ Inflammation

- Acute inflammation:
- Chronic Inflammation:
- Chronic inflammation usually not ass. With stridor except for TB that can also be ass. With dysphagia.

Acute Inflammation

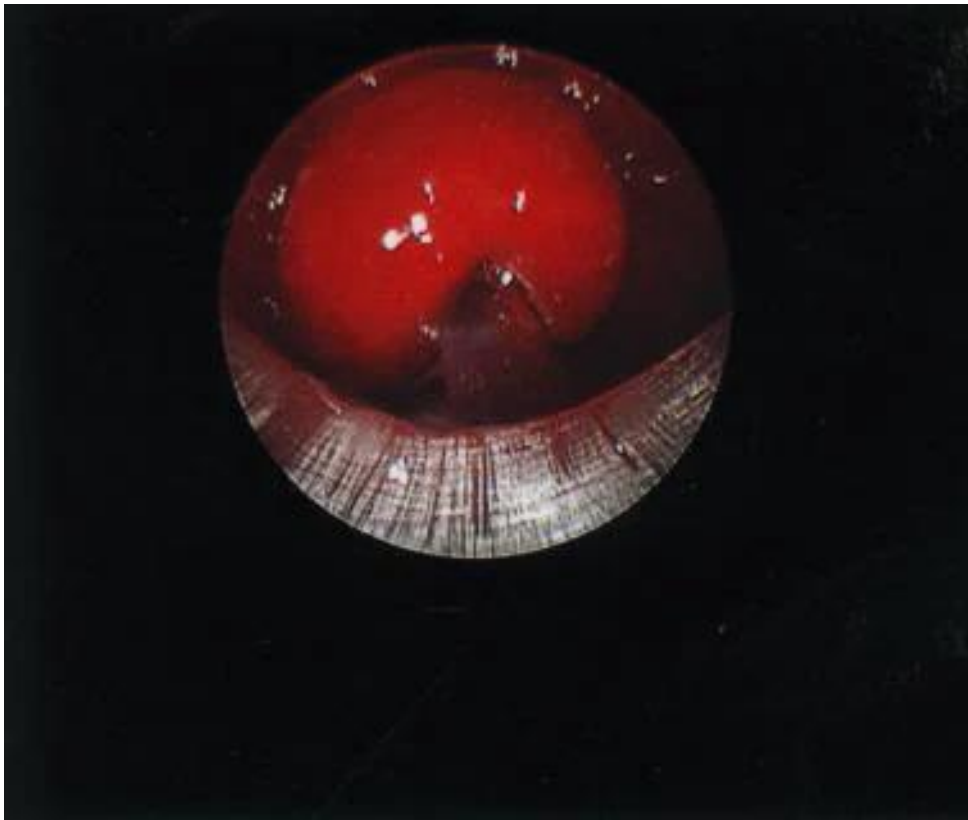
- Laryngotracheobronchitis
- Acute epiglottitis
- Acute laryngitis
- Inhalation of foreign body
- Bacterial tracheitis (is a secondary infection (most commonly due to *Staphylococcus aureus*) following a viral process (commonly croup or influenza).
- Peritonsillar abscess
- Spasmodic croup

Acute epiglottitis

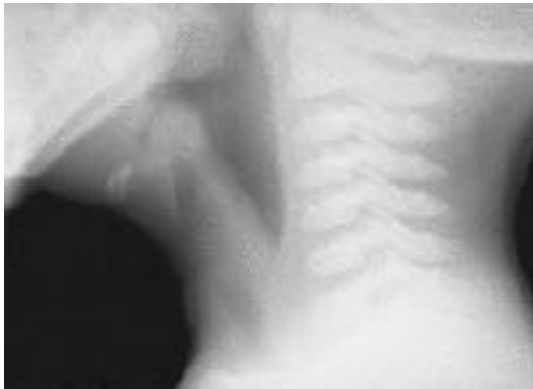- **Symptoms:**

- Sore throat (95%)
- Odynophagia/dysphagia (95%)& drooling of saliva
- Muffled voice (54%) - "Hot potato voice," as if the patient is struggling with a mouthful of hot food
- Adults may have preceding upper respiratory tract infection (URTI) symptoms
 - Severe stridor with the pt sitting in air hunger position.
 - Very high fever, >40 c.
 - Pt looks very toxic, tachycardic and tachypnic

Laryngoscope of Epiglottitis



Epiglottitis: Thumb sign



- ▶ **Soft-tissue lateral neck radiograph reveals edema of epiglottis consistent with acute epiglottitis.**

Acute epiglottitis

- **Management:**
 - Airway management is the most urgent consideration, and patients should first be assessed for level of distress, before any other workup
 - Radiographic evaluation for suspected epiglottitis is being replaced by direct visualization of the epiglottis using nasopharyngoscopy/laryngoscopy as the preferred method of diagnosis.
 - IV fluids.
 - IV antibiotics, ampicillin and chloramphenicol.
 - IV steroids, to relieve the edema.
 - Nebulizers with epinephrine.

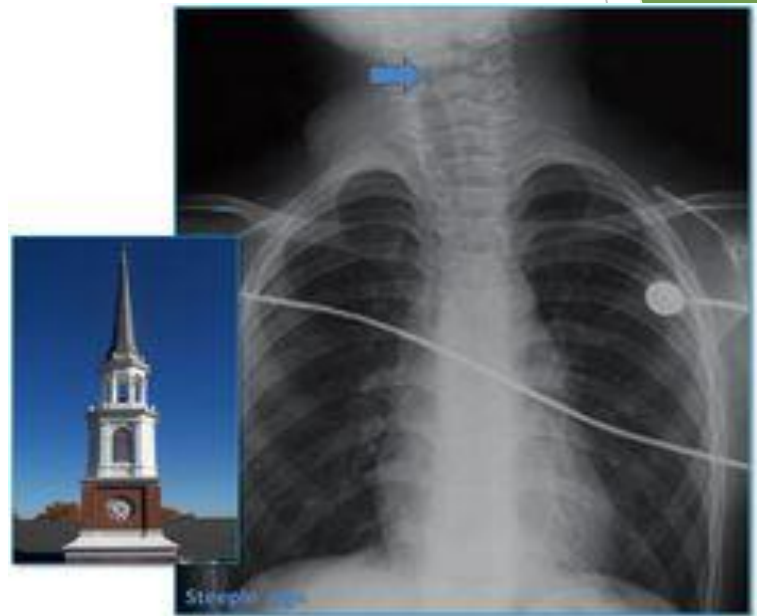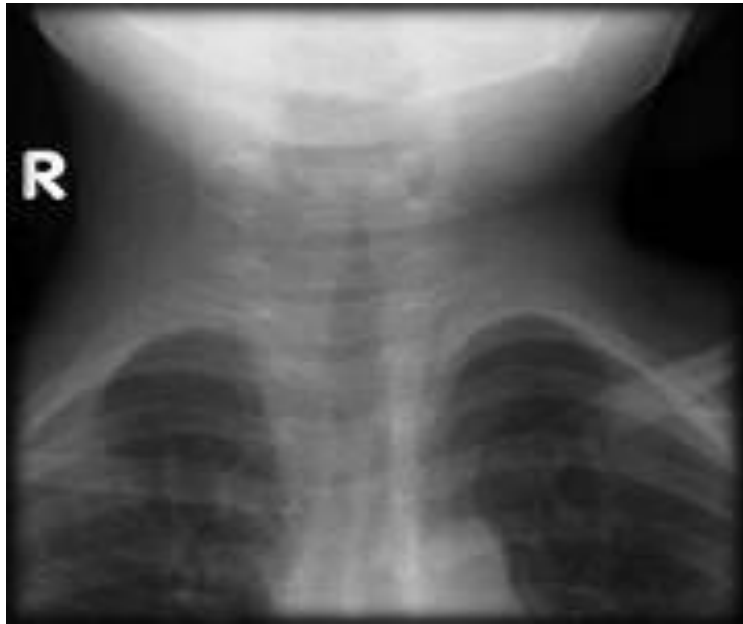Acute Laryngotracheobronchitis

- it's the most common cause of acute stridor in children, especially children aged 6 months to 2 years.
- Viral infection.
- Most caused by Para influenza virus.
- Affects children <2 years.

Acute Laryngotracheobronchitis

- ▶ **Symptoms:**
 - Stridor.
 - Barking cough.
 - Wheezes.
 - Crepitation.
 - Low grade fever .
 - Pt looks ill but not toxic.

Steeple sign

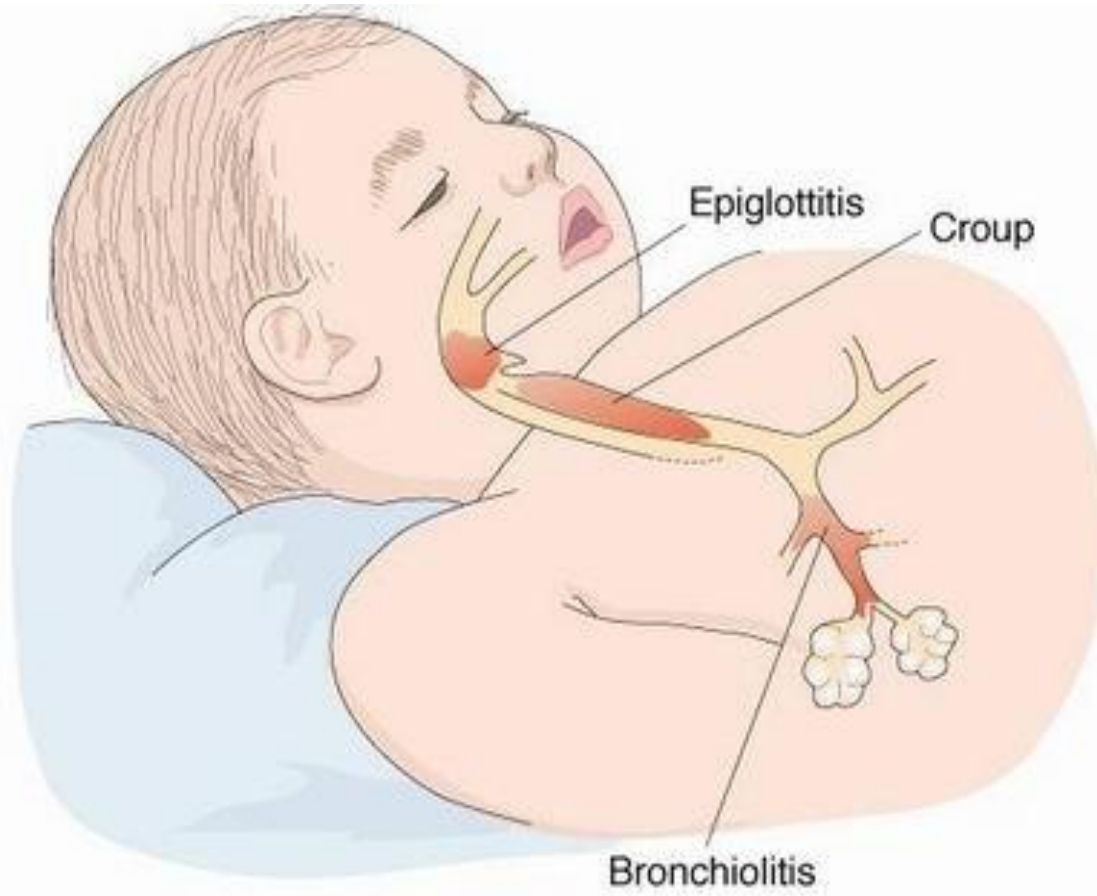


Acute Laryngotracheobronchitis

- ▶ **Management(supportive)**
- ▶ humidifiers
- Secure the airways if compromised.
- IV steroids
- Nebulizers with epinephrine.



Epiglottitis, Croup and Bronchiolitis



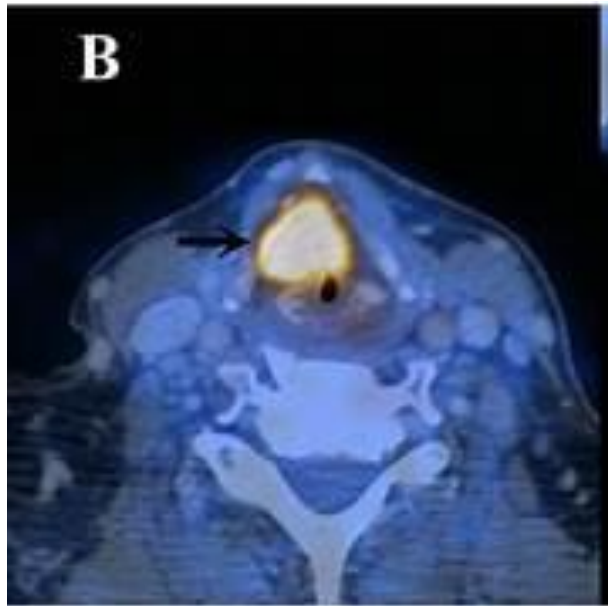
Acute Laryngitis

- Most commonly URTI ,usually viral .
- Swelling and inflammation at the level of the vocal cords.
- Seen in children less than 12 years old.
- Self limiting and doesn't cause significant morbidity and mortality

Acute Laryngitis

- **Symptoms:**
 - Stridor.
 - Cough.
 - Hoarseness of voice.
- **Management(supportive)**
 - Secure airways.
 - Nebulizers, preferring cold stream with epinephrine.
 - Steroids.

Tumors



- ▶ Tumors of the pharynx and larynx

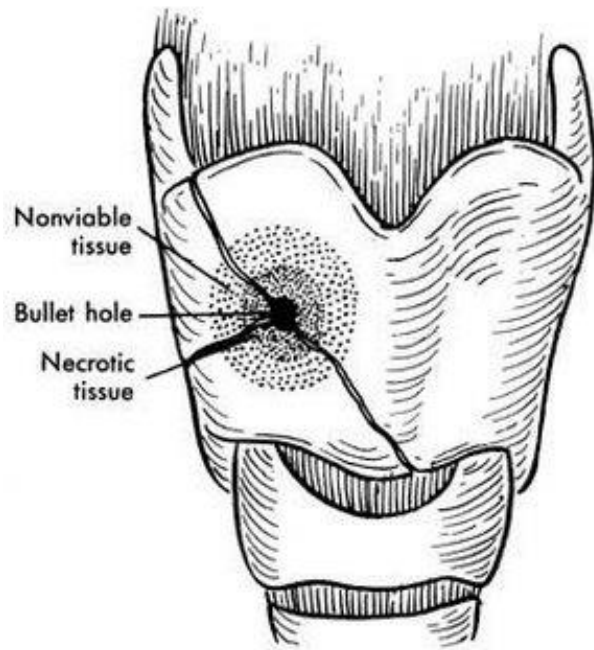
Trauma

- Fortunately, not common since the larynx is a well-protected organ.

► Classification:

- I. According to the mechanism.
- II. According to the severity.
- III. According to the cause.

Trauma



- ▶ According to the Mechanism:
 - ▶ Thermal, hot fumes ass. With burns.
 - ▶ Chemical, aspiration of chemicals.
 - ▶ Physical, either blunt or penetrating.
- ▶ According to the Severity:
 - ▶ Mild.
 - ▶ Moderate.
 - ▶ Severe.

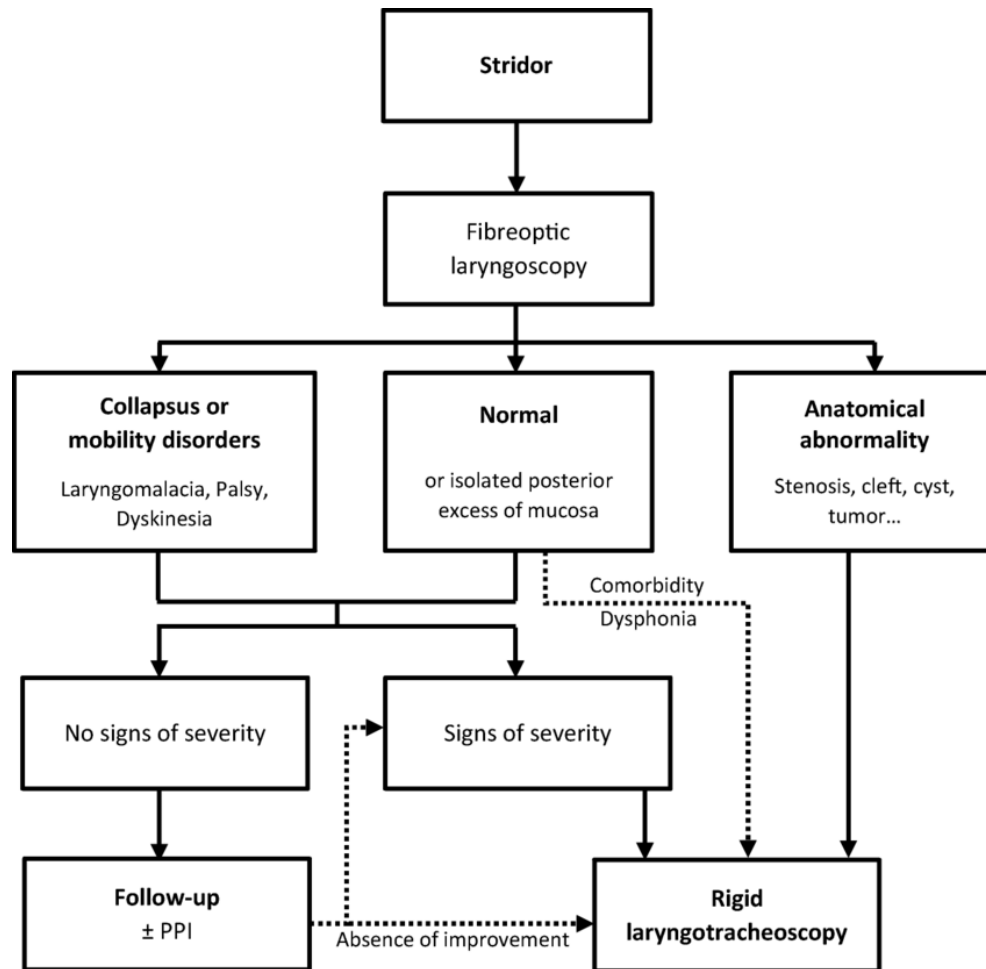
Trauma

- ▶ **According to the Cause:**
 - Accidental.
 - Personal assaults.
 - RTAs.
 - Sport injuries, esp. Hockey.
 - Gun shots.

Trauma

► Management:

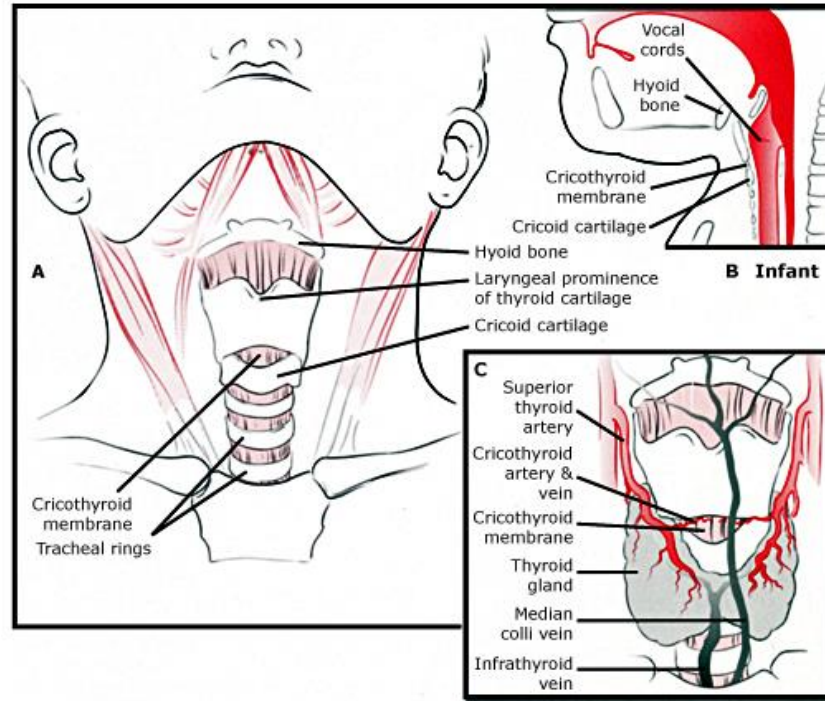
- Secure airways. Most of the times tracheostomy.
- Exploration. Done in case of obvious penetrating injury. Intact larynx should NOT be opened to explore it.
- High resolution CT scan. Fractures and other injuries.
- Remember to rule out any cervical injuries before intubation or tracheostomy.
- For cut wounds do NOT suture, just put a stent to prevent stenosis.
- Reduction of displaced fractures.
- Treat other ass. Injuries.



Treatment of stridor (only in hospital!)

- I degree
 - Fresh air access, oxygen therapy, warm bath for legs and hands, adequate basic drinking, decongestants for nose Physiologic solution, hydrocortisone inhalations
- II degree
 - Listed above +prednisone IM or IV 2-5 mg/kg, constant oxygen therapy
 - Berodual, salbutamol inhalations through nebuliser or bebihaler
 - Expectorants
- III degree
 - Listed above +prednisone 5-10 mg/kg per day, naso-tracheal intubation (or tracheostomy)

“



”

	Tracheostomy	Cricothyroidotomy
Timing	Elective	Emergent
Anatomical Location	2 nd or 3 rd tracheal ring	Cricothyroid membrane
Duration	Long-term	Short-term or temporary
Technique	Open or percutaneous	Open or needle
Geography	OR or ICU	ER, OR, ICU, ward
Equipment	++++	+

